



# Heavy Load of Intestinal Fluke in a Four-Year-Old Child with Severe Acute Malnutrition: A Case Report

Sangeeta Deka<sup>1</sup> Deepjyoti Kalita<sup>2</sup> Naba Kumar Hazarika<sup>3</sup>

<sup>1</sup> Department of Microbiology, Fakhruddin Ali Ahmed Medical College & Hospital (FAAMCH), Barpeta, Assam, India

<sup>2</sup> Department of Microbiology, All India Institute of Medical Sciences, Rishikesh, Virbhadrha Road, Rishikesh, Uttarakhand, India

<sup>3</sup> Department of Microbiology, Gauhati Medical College & Hospital (GMCH), Guwahati, Assam, India

**Address for correspondence** Deepjyoti Kalita, MD, Department of Microbiology, All India Institute of Medical Sciences, Virbhadrha Road, Rishikesh 249203, Uttarakhand, India (e-mail: dkalita@gmail.com; deep.micro@aiimsrishikesh.edu.in).

J Lab Physicians 2023;15:139–141.

## Abstract

Fasciolopsiasis, a food-borne intestinal parasitosis, occurs focally, and remains a significant public health problem in endemic areas. However, due to the wide spectrum of clinical presentation and unclear diagnosis or even misdiagnosis, it often goes unreported. The correlation between trematode infection and malnutrition is also often debated. We report a case of heavy infection of *Fasciolopsis buski* in a 4-year-old girl with severe acute malnutrition (SAM). The patient presented with a passage of many adult worms per stool following the consumption of some herbal concoction. A wet mount of the stool revealed ova of *Fasciolopsis buski*. She was treated successfully with praziquantel and food supplements. It raises the possibility of unidentified cases in this region and necessitates more extensive studies in the targeted population. This will also help raise awareness of fasciolopsiasis among clinicians, especially in vulnerable populations such as malnourished children.

## Keywords

- ▶ trematode infections
- ▶ *Fasciolopsis buski*
- ▶ malnutrition
- ▶ children

## Introduction

*Fasciolopsis buski*, a digenean trematode, is the largest of all flukes parasitizing humans. It inhabits the small intestine of the definitive mammalian host (pigs and humans), and snails act as the intermediate host.<sup>1</sup> Its geographical distribution is restricted to Asia and is endemic in some regions of the Far East, Southeast Asia, and southern Asia.<sup>1–3</sup> In India, *F. buski* is prevalent in many regions of Bihar, Uttar Pradesh, West Bengal, and Assam.<sup>2,4</sup> However, as most infections are asymptomatic or present as non-specific symptoms, they are often not diagnosed or sometimes even misdiagnosed.

Thus, there are limited reports of human infection, and thus fasciolopsiasis remains underreported.<sup>1,2</sup>

Fasciolopsiasis is not transmitted directly from human to human. After the infected definitive host pass feces in the water, the eggs undergo further development in water. Ciliated miracidium comes out of the egg and penetrates a suitable snail host. After further development in the snail, the cercariae emerge and encyst on water plants as metacercariae. Humans get the infection as a result of eating these contaminated water plants raw (or undercooked).<sup>2,4</sup>

In endemic areas, the prevalence of fasciolopsiasis in children ranges from 10 to 60%.<sup>5</sup> The disease occurs more

article published online  
July 26, 2022

DOI <https://doi.org/10.1055/s-0042-1748830>.  
ISSN 0974-2727.

© 2022. The Indian Association of Laboratory Physicians. All rights reserved.

This is an open access article published by Thieme under the terms of the Creative Commons Attribution-NonDerivative-NonCommercial-License, permitting copying and reproduction so long as the original work is given appropriate credit. Contents may not be used for commercial purposes, or adapted, remixed, transformed or built upon. (<https://creativecommons.org/licenses/by-nc-nd/4.0/>)

Thieme Medical and Scientific Publishers Pvt. Ltd., A-12, 2nd Floor, Sector 2, Noida-201301 UP, India

commonly in school-aged children; however, many authors often controvert its association with macronutrient deficiency.<sup>5–8</sup> Here, we report a case of spontaneous expulsion of a large number of adult *Fasciolopsis buski* worms by defecation in a 4-year old girl with severe acute malnutrition and wasting.

### Case Presentation

A 4.2-year-old child was brought to the pediatric outpatient department (OPD) with the chief complaint of epigastric pain, severe diarrhea, weight loss, and passage of pink-colored flesh-like material in the stool. According to the parents, for the past 2 days, the child passed stools four to five times/day, which was pale-colored and watery liquid; and the stool matter consisted of only the flesh-like material (around 10–15/bout). Before that, she suffered from chronic intermittent diarrhea, on and off pain in the abdomen, and decreased appetite for around 3 months. The parents gave a history of going to a local bez (quack/traditional medicine practitioner) and consuming some herbal concoction 5 days prior to visiting the OPD. Following this, the child stopped eating entirely and 2 days later started passing the flesh-like material in the stool. The family of the patient was a permanent resident of the Pamohi region in the outskirts of Guwahati city and have not traveled to or migrated from other areas. The parents were daily wage laborers and the family also depended on vegetable farming and fishing in the nearby localities. On examination, the child had a generalized cachectic look and was irritable. She had pallor and pitting pedal edema. She was afebrile (37°C) and had no hepatomegaly, splenomegaly, or skin lesions. Her weight was 10.7 kg, her height was 99 cm, and her mid-arm circumference was 11 cm. She was found to have severe wasting with less than –3 z-score of the median World Health Organization (WHO) growth standard and was classified to have severe acute malnutrition (SAM).<sup>9</sup> Following hospitalization, a detailed history was taken, and the parents of the child denied any history of travel, the passage of any parasites in stool in the past, severe illnesses such as viral hepatitis, tuberculosis, or intake of any anti-helminthic medicines. Her stool was collected, and on macroscopic examination, the adult form of *Fasciolopsis buski* was identified (→ Fig. 1). The adult worm was around 5.5 cm long and 1.5 cm broad, with a large acetabulum close to the ventral oral sucker. The consistency of the stool was watery, and mucus was present; however, no gross presence of blood was noticed. Microscopic examination of the fluid part of the stool in a normal saline wet mount revealed unsegmented, bile-stained, ellipsoidal, finely operculated eggs (→ Fig. 2). Routine blood examination showed mild leucocytosis with eosinophilia. She was treated with intravenous fluids and antibiotics. As the child was anorexic, dietary treatment with F-75 and mineral mix was given via a nasogastric tube, which was shifted to cup and spoon-feed after 3 days. Vitamin A, iron, and folic acid supplements were also given to the child. Oral praziquantel (25 mg/kg body weight) was given in three divided doses for 1 day. Repeat stool examination was done on the sixth and

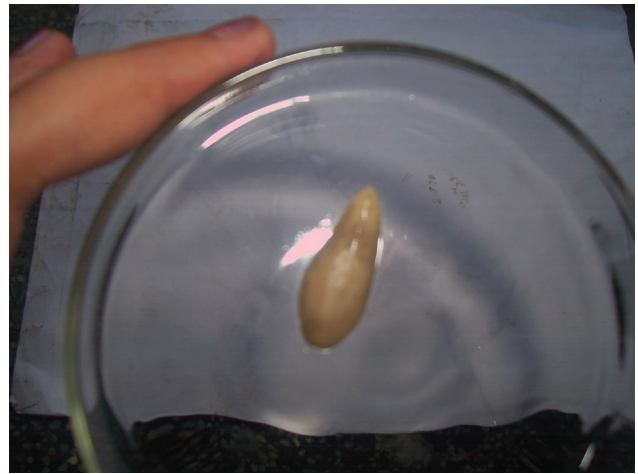

Fig. 1 Adult *Fasciolopsis buski* expelled with defecation.

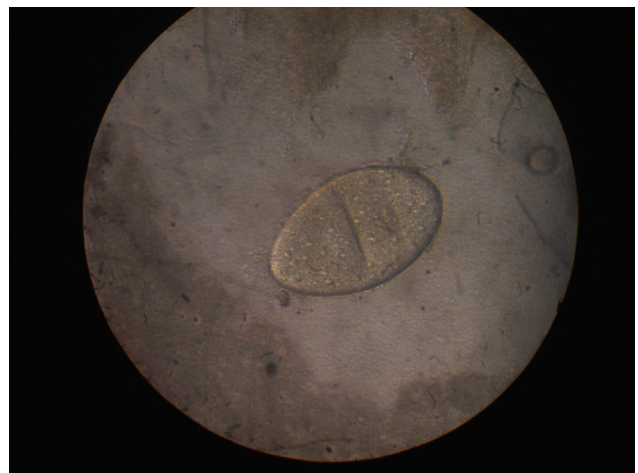


Fig. 2 Ova of *Fasciolopsis buski* on stool examination.

ninth days of admission, and the patient was discharged following steady weight gain and two consecutive negative stool reports.

### Discussion

Fasciolopsiasis is not uncommon in Assam, as there are many water bodies and water-filled low-lying areas. Century-old traditions such as open-air defecation, eating raw or undercooked water plants such as parts of water lily, lotus plant, and water caltrop are responsible for augmenting fluke infections. However, areas in and around Guwahati were not known to be endemic, and after a literature search, we could not find any case reports from this region.

Intestinal parasites could affect the nutritional status of their host by various mechanisms, by feeding on host tissue or contents of the gut, by causing mal-digestion and mal-absorption of nutrients, by reducing appetite due to inflammatory response, or by diverting the use of nutrients or energy due to contingent response (fever, immune response, etc.).<sup>7</sup> In contrast, malnutrition impairs both innate and

acquired immunity, thus weakening the defense against parasitic infections, leading to heavy worm infestation, creating a potentially lethal cycle of worsening infection and deteriorating nutritional status.<sup>8</sup> In the current case, we encountered severe wasting in the child, which might have resulted from chronic heavy worm burden. As the adult worm does not multiply in a human host, there might have been repeated infections due to chronic exposure and weakened immunity, further enhancing the parasitic habitation, creating a vicious cycle. However, robust evidence-based data showing direct association of fluke infection with deficiency of macronutrients is not available because fluke infection is not a very common occurrence, and not many types of studies have been done in this field.<sup>7,8</sup> Nonetheless, Webb et al reported a higher prevalence of stunting in children with chronic *Fasciola* infection.<sup>9</sup> Although protein-losing enteropathy is uncommon in parasitic intestinal infection, Balekuduru et al observed it in a case heavily infested with *F. buski*.<sup>10</sup>

Classically, the spontaneous passage of live adult worms with defecation is rare. However, cases of passing adult worm in stool had been reported in heavy infections.<sup>7</sup> As for the expulsion of worms, an environment must be created that is too hostile for the worm to continue developing and maintain its position.<sup>11</sup> Thus, there is a possibility that severe malnutrition might be detrimental to parasite survival due to a lack of essential micro/macronutrients. Moreover, as the patient gave a history of taking some herbal drugs 5 days before the expulsion of the worms, it might be another possibility of killing or anesthetizing the adult worms. But this might be a mere coincidence.

To conclude, this case may hint at many other undiagnosed cases in this region. This will also help sensitize clinicians regarding the need to screen for trematode infection in vulnerable populations such as malnourished children.

#### Author's Contributions

S.D. contributed to conceptualization, data curation, formal analysis, investigation, methodology, software, validation, visualization, writing: original draft. D.K. contributed to conceptualization, project administration, investigation, data curation, visualization, software, review and editing, supervision. N.K.H. contributed to resources,

supervision, investigation, visualization, review and editing, visualization.

#### Funding

None.

#### Conflict of Interest

None declared.

#### Acknowledgments

The authors would like to thank the principal-cum-chief superintendent and administration of Gauhati Medical College and hospital for allowing us to carry out this study.

#### References

- Mas-Coma S. Helminth-trematode: fasciolopsisbuski. In: Yasmine Motarjemi, ed. Encyclopedia of Food Safety. Amsterdam: Academic Press; 2014:146–157. Available at: <https://doi.org/10.1016/B978-0-12-378612-8.00155-4>
- Mewara A, Jain N, Malla N. Human intestinal trematodiasis in India: an overview. *J Gastrointest Infect* 2018;8(01):39–45
- Wu X, Wang W, Li Q, Xue Q, Li Y, Li S. Case report: surgical intervention for *Fasciolopsis buski* infection: a literature review. *Am J Trop Med Hyg* 2020;103(06):2282–2287
- Sarkar K, Gonjhu D, Pramanik N. Two case reports of rare *Fasciolopsis buski* infestation. *Int J Med Res Prof.* 2016;2(01):80–81
- Graczyk TK, Gilman RH, Fried B. Fasciolopsiasis: is it a controllable food-borne disease? *Parasitol Res* 2001;87(01):80–83
- Saurabh K, Ranjan S. Fasciolopsiasis in children: clinical, socio-demographic profile and outcome. *Indian J Med Microbiol* 2017; 35(04):551–554
- Hall A, Hewitt G, Tuffrey V, de Silva N. A review and meta-analysis of the impact of intestinal worms on child growth and nutrition. *Matern Child Nutr* 2008;4(01, Suppl 1):118–236
- Hughes S, Kelly P. Interactions of malnutrition and immune impairment, with specific reference to immunity against parasites. *Parasite Immunol* 2006;28(11):577–588
- Webb CM, Morales ML, Lopez M, et al. Stunting in pre-school and school-age children in the Peruvian highlands and its association with *Fasciola* infection and demographic factors. *PLoS Negl Trop Dis* 2021;15(06):e0009519
- Balekuduru AB, Venkateshappa LL, Jalihal U, Subbaraj SB. Protein-losing enteropathy–vomiting the diagnosis. *Indian J Gastroenterol* 2014;33(04):400
- Bundy DA, Medley GF. Immuno-epidemiology of human geohelminthiasis: ecological and immunological determinants of worm burden. *Parasitology* 1992;104(Suppl):S105–S119