Article published online: 2022-06-14

Transorbital Intracranial Penetrating Injury from a Homemade Gun: A Case Report

Avika Trakulpanitkit[1] Kanisorn Sungkaro[1]

[1] Division of Neurosurgery, Department of Surgery, Faculty of Medicine, Prince of Songkla University, Songkhla, Thailand

J Health Allied Sci[NU] 2023;13:141–143.

Address for correspondence Kanisorn Sungkaro, MD, Division of Neurosurgery, Department of Surgery, Faculty of Medicine, Prince of Songkla University, Songkhla, Thailand 90110 (e-mail: kanisorn7640@gmail.com).

Abstract

A transorbital intracranial penetrating injury (TOPI) is an unusual traumatic brain injury that requires multidisciplinary management. TOPI may cause traumatic cerebrovascular injury (TCVI) and fatal brain damage with a high mortality rate. Herein, the authors described an 8-year-old male patient who was injured from a handmade gun; a projectile (marble) had penetrated the left frontal base via the left orbit. TOPI caused left anterior cerebral artery compression. A transorbital approach with an intraoperative transcranial approach on standby was performed to remove the foreign body. Postoperative intensive broad-spectrum antibiotics were administrated, and the patient made an uneventful recovery. In summary, TOPI is an uncommon TBI that risks TCVI. Intracranial vascular investigation should be performed before surgical management, and postoperative complications, such as meningitis, brain abscess, and delayed pseudoaneurysm, should be monitored.

Keywords
- penetrating brain injury
- orbital injury
- traumatic cerebrovascular injury
- traumatic brain injury

Introduction

A transorbital intracranial penetrating injury (TOPI) is an unusual traumatic brain injury (TBI) that could be fatal. From the literature review, TOPI was found in 0.04% of all TBI cases.[1] TOPI leads to serious damage when a foreign object penetrates the cranium, thus requiring multidisciplinary management. Traumatic cerebrovascular injury (TCVI), accounting for 0.8 to 1.7% of TBI, is one of the injuries that should be concerned in TOPI.[2,3] The authors report on a case of TOPI due to a penetrating injury from a handmade gun that caused a projectile to enter through the left orbit and compress the left anterior cerebral artery.

Case Presentation

An 8-year-old male patient was transferred to our hospital because of TOPI caused by a handmade gun that penetrated through the left orbit. Examination showed mild ptosis with blindness in the left eye. There was no neurological deficit. A computerized tomography (CT) scan of the brain revealed a round-shaped foreign body through the left medial orbit plane that caused a left orbital fracture and entered the left frontal lobe, as shown in ►**Fig. 1A**. In addition, CT angiography of the brain that was performed for evaluation of TCVI demonstrated the foreign body had compressed the left anterior cerebral artery, as shown in ►**Fig. 1B**. In addition, extravasation of contrast was not seen from images. We chose a transorbital approach with an intraoperative transcranial approach on standby to remove the foreign body. Firstly, enucleation of the left eye was performed by an ophthalmologist. Consequently, the foreign body was observed on the medial side of the left orbit and removed by a neurosurgeon, as shown in ►**Fig. 2A**. The foreign body was a marble 1.5 centimeter in diameter that was used as a projectile, as shown in ►**Fig. 2B**. Fibrin glue was applied at

article published online
June 14, 2022

DOI https://doi.org/10.1055/s-0042-1748759.
ISSN 2582-4287.

Thieme Medical and Scientific Publishers Pvt. Ltd., A-12, 2nd Floor, Sector 2, Noida-201301 UP, India

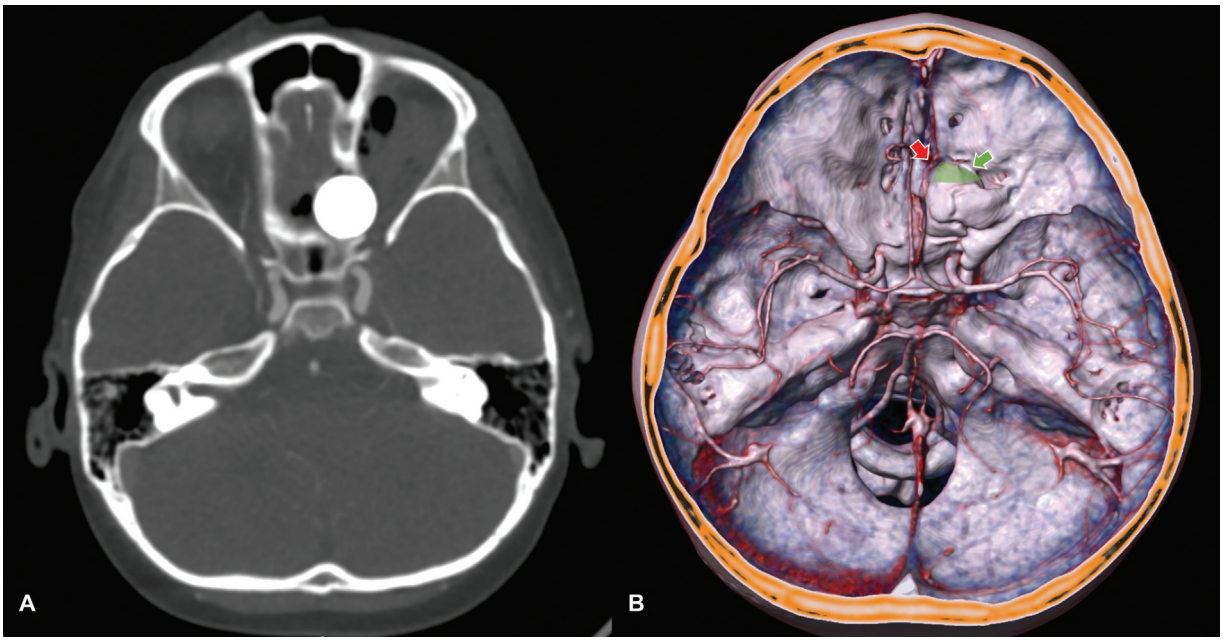

Fig. 1 Image of a patient injured by a handmade gun. (**A**) Axial computed tomography (CT) head bone-window image showing a round-shaped foreign body through the left orbit that entered the left frontal lobe. (**B**) Three-dimensional (3D)-reconstruction CTA of the brain showing a foreign body (green arrow) that caused a left orbital fracture and compressed left anterior cerebral artery (red arrow).

the surgical site although no cerebrospinal fluid leakage was apparent. After the procedure, antibiotics were administered continuously for 14 days, and there were no complications such as cerebrospinal fluid leakage. At a 3-month follow-up, the patient appeared to have had an uneventful recovery and there was no delayed pseudoaneurysm on the CTA of the brain.

Discussion

TOPI following a penetrating injury is uncommon in TBI. From a prior study, the incidence of TOPI has been reported in 0.04% of TBI cases. Various foreign bodies have been reported to have entered through the orbit to the cranium, including metal bars[4,5] and wooden sticks.[6] Complete ophthalmological and neurological examinations are important in TOPI. Because patients with TOPI can present both obvious and occult ocular injuries, intracranial injury cannot be excluded.[7]

CT scan imaging is important for the evaluation of the trajectory of a projectile and orbitocranial injuries, while magnetic resonance imaging (MRI) of the brain is useful for evaluating injuries caused by wooden foreign bodies.[4,8,9] Cerebral angiography should be concerned when a projectile or foreign body has entered the adjacent base of the skull, orbit, and facial bones.[5,8,9] Therefore, TOPI is a high risk to TCVI from the penetrating mechanism. Moreover, a foreign body is often positioned near intracranial vessels. In an acute setting, less invasive investigations such as CT angiography may be appropriate for the initial preoperative evaluation of TCVI.[10,11]

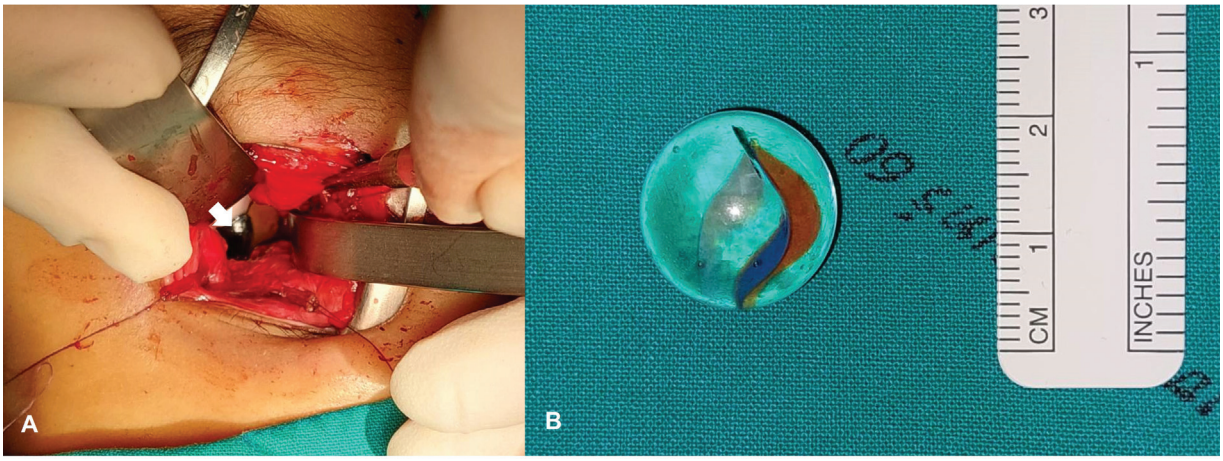

Fig. 2 Image of intraoperative findings. (**A**) The projectile placed at the left medial orbit (arrow). (**B**) Marble projectile 1.5 centimeter in diameter removed via the transorbital approach.

The most common trajectory of entry is the superior orbital roof, which may cause injury to the frontal lobe and intracranial vessel. If such penetration has sufficient force, deep intracranial structures may be damaged such as the cavernous sinus, temporal lobe, and brainstem. Arslan et al reported a fatal case of TOPI, which involved a long metal bar penetrating from the right orbit to the left occipital bone.[1]

Management of TOPI typically involves foreign body removal that may lead to serious intracranial infection later. However, intraoperative bleeding from the intracranial vessel should be considered because the foreign body compresses and adheres to vascular structures during foreign body removal. Three surgical approaches have been described to remove a foreign body: anterior orbitotomy, subcranial craniotomy, and frontotemporal craniotomy.[8] The surgical approach is selected depending on the location of the foreign body.

In the present case, we removed the marble projectile via the transorbital approach with a transcranial approach ready if active bleeding occurred following the removal of the foreign body. If the foreign body mainly involves intracranial structures, the transcranial approach would be preferable in this situation.[9,10] Additionally, debridement of bone fragments, hematoma evacuation, control bleeding, and repair of dural defects are required to avoid potentially infectious complications later.

Postoperative intensive broad-spectrum antibiotics should be administered to prevent subsequent infection. *Staphylococcus*, *Bacillus*, and *Clostridium* species have been reported TOPI cases. Therefore, appropriate tetanus immunization is needed.[12,13] For long-term complications, postoperative cerebral angiogram or less-invasive vascular studies including MR angiography or CT angiography should be performed 1 to 3 months after the injury to evaluate delayed pseudoaneurysm.[9,10]

Authors' contributions

KS: admitted and investigated the case. AT: investigated the case. KS: wrote the case report. AT: wrote and edited the case report. KS: revised, edited, and wrote the case report. All authors read and approved the final manuscript.

Conflict of Interest

None declared.

Acknowledgment

The authors would like to offer their special thanks to Dr. Wantanee Dangboon for advice about manuscript preparation.

References

1 Arslan M, Eseoğlu M, Güdü BO, Demir I. Transorbital orbitocranial penetrating injury caused by a metal bar. J Neurosci Rural Pract 2012;3(02):178–181. Doi: 10.4103/0976-3147.98228
2 Tunthanathip T, Phuenpathom N, Saehaeng S, Oearsakul T, Sakarunchai I, Kaewborisutsakul A. Traumatic cerebrovascular injury: prevalence and risk factors. Am J Emerg Med 2020;38(02): 182–186. Doi: 10.1016/j.ajem.2019.01.055
3 Kobata H. Diagnosis and treatment of traumatic cerebrovascular injury: pitfalls in the management of neurotrauma. Neurol Med Chir (Tokyo) 2017;57(08):410–417. Doi: 10.2176/nmc.oa.2017-0056
4 Agrawal A, Reddy VU, Kumar SS, Hegde KV, Rao GM. Transorbital orbitocranial penetrating injury with an iron rod. Craniomaxillofac Trauma Reconstr 2016;9(02):145–148. Doi: 10.1055/s-0035-1551545
5 Agrawal A, Pratap A, Agrawal CS, Kumar A, Rupakheti S. Transorbital orbitocranial penetrating injury due to bicycle brake handle in a child. Pediatr Neurosurg 2007;43(06):498–500. Doi: 10.1159/000108794
6 Borkar SA, Garg K, Garg M, Sharma BS. Transorbital penetrating cerebral injury caused by a wooden stick: surgical nuances for removal of a foreign body lodged in cavernous sinus. Childs Nerv Syst 2014;30(08):1441–1444. Doi: 10.1007/s00381-014-2364-0
7 Abdulbaki A, Al-Otaibi F, Almalki A, Alohaly N, Baeesa S. Transorbital craniocerebral occult penetrating injury with cerebral abscess complication. Case Rep Ophthalmol Med 2012; 2012:742186. Doi: 10.1155/2012/742186
8 Tunthanathip T. Translational Medicine in Neurosurgery. In: Tunthanathip T, ed. Translational Medicine in Neurosurgery. Bangkok: Sahamit Pattana printing; 2022:1–16
9 Tunthanathip T. Traumatic cerebrovascular injury. In: Oearsakul T, ed. Traumatic brain injury and cervical spine injury. Bangkok: Sahamit Pattana printing; 2022:373–384
10 Schreckinger M, Orringer D, Thompson BG, La Marca F, Sagher O. Transorbital penetrating injury: case series, review of the literature, and proposed management algorithm. J Neurosurg 2011; 114(01):53–61. Doi: 10.3171/2010.8.JNS10301
11 Tunthanathip T. Penetrating brain injury. In: Oearsakul T, ed. Traumatic brain injury and cervical spine injury. Bangkok: Sahamit Pattana printing; 2022:91–103
12 Bert F, Ouahes O, Lambert-Zechovsky N. Brain abscess due to Bacillus macerans following a penetrating periorbital injury. J Clin Microbiol 1995;33(07):1950–1953
13 Hansen JE, Gudeman SK, Holgate RC, Saunders RA. Penetrating intracranial wood wounds: clinical limitations of computerized tomography. J Neurosurg 1988;68(05):752–756

