



# Dynamic Upper Eyelid Reconstruction for Total Periorbital Soft Tissue Loss

Madhubari Vathulya, MS, MCh<sup>1</sup> Nishank Manohar, MS<sup>1</sup> Manish Pradip Jagtap, MS<sup>1</sup>   
Vishal Mago, MS, MCh<sup>1</sup> Praveen A. Jayaprakash, MS<sup>1</sup>

<sup>1</sup> Department of Burns and Plastic Surgery, All India Institute of Medical Sciences, Rishikesh, Uttarakhand, India

Arch Plast Surg 2022;49:319–323.

Address for correspondence Nishank Manohar, MS, Department of Burns and Plastic Surgery, All India Institute of Medical Sciences, Veerbhadra Marg, Rishikesh, Uttarakhand 249203, India (e-mail: nishankmanohar@gmail.com).

## Abstract

Total eyelid defect comprises full-thickness loss of both upper and lower eyelids in a patient. It is a rare and devastating condition with serious implications related to vision, which mandates early and functional reconstruction when associated with intact globe. The primary goal is to give a stable coverage for orbital protection but at the same time provide a functional reconstruction of the defect, to allow for adequate mobility of the eyelids so that the patient's vision is restored to normal with minimal disability. When the defect is massive, and in the absence of loco-regional flaps, microvascular tissue transfer is needed. In this report we describe a radial-artery-based microvascular tissue transfer with a unique innovation utilizing the contralateral frontalis muscle to reconstruct a case of unilateral total upper and lower eyelid loss.

## Keywords

- ▶ reconstructive
- ▶ eyelids
- ▶ tendon
- ▶ degloving injury
- ▶ free tissue

Total eyelid defect comprises full-thickness loss of both upper and lower eyelids in a patient. It is a rare and unanticipated condition which may occur due to burns, trauma, or periocular tumor.<sup>1</sup> This is a devastating condition, not only cosmetically but also functionally, as it leads to exposure keratopathy and eventually loss of vision. Surgical reconstruction of such a defect is challenging because of the restricted local tissues available for reconstruction. The primary goal of periorbital reconstruction is to not only give a stable coverage for orbital protection but also provide a functional reconstruction of the defect which is to allow for adequate mobility of the eyelids to allow patient's vision is with minimal disability.

We present one such complex defect wherein a patient presented with a complete full-thickness loss of unilateral upper and lower eyelids due to a wild bear attack leaving her eyeball exposed. The defect was resurfaced using a radial artery forearm microvascular tissue transfer and

functionality was provided using the contralateral frontalis muscle.

## Case Report

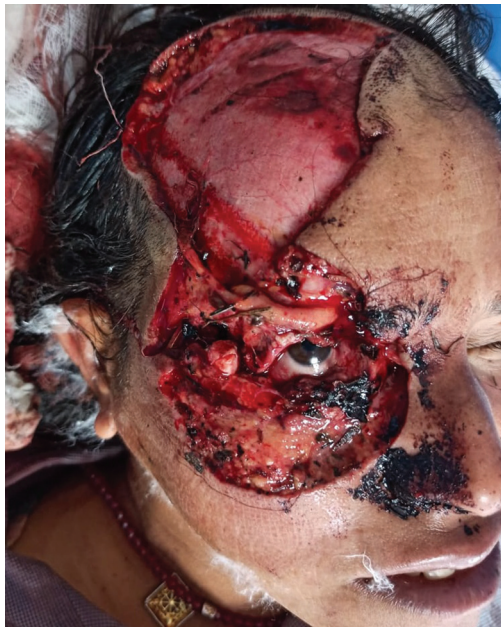A 34-year-old otherwise healthy female presented to our center with history of bear attack while she was grazing her cattle. On admission she was maintaining stable vitals and had no history of loss of consciousness, seizures, or vomiting. Systemic examination was also unremarkable. Local examination revealed degloving injury over the right-side face and frontal, parietal scalp region measuring approximately 15 × 20 cm. Superiorly the wound extended into the right parietal region, with total loss of both upper and lower eyelids along with the frontalis muscle on the right side. Medially it extended to the central forehead, inferiorly to the malar eminence, and laterally up to the temporal triangle. The edges were well defined and the pericranium was visible

DOI <https://doi.org/10.1055/s-0042-1748639>.  
ISSN 2234-6163.

© 2022. The Korean Society of Plastic and Reconstructive Surgeons. All rights reserved.

This is an open access article published by Thieme under the terms of the Creative Commons Attribution-NonDerivative-NonCommercial-License, permitting copying and reproduction so long as the original work is given appropriate credit. Contents may not be used for commercial purposes, or adapted, remixed, transformed or built upon. (<https://creativecommons.org/licenses/by-nc-nd/4.0/>)

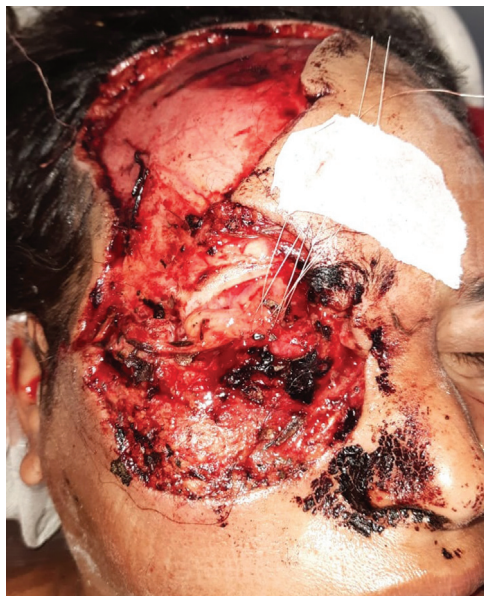Thieme Medical Publishers, Inc., 333 Seventh Avenue, 18th Floor, New York, NY 10001, USA



**Fig. 1** Clinical photograph of a patient at the time of presentation in the emergency department. A large area of skin avulsion with exposure of the underlying eyeball and intact periosteum is visualized.

on the floor of the defect. The right eyeball was completely exposed (►Fig. 1). There was also a fracture of the right lateral orbital rim, a fragment of which was exposed on the lateral margin of the eyeball which was confirmed on computerized tomography of the facial skeleton.

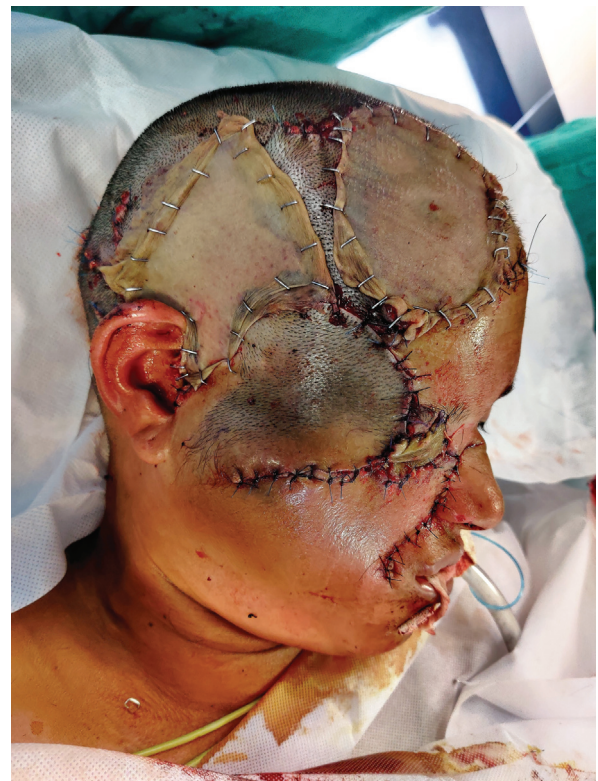Ophthalmologic examination revealed a dry cornea with absence of normal sheen and preserved vision. Immediate corneal protection was given with the help of tagging sutures given on the soft tissue around the eye after giving generous lavage and carboxymethyl cellulose, antibiotic eye drops were started (►Fig. 2).



**Fig. 2** Use of tagging sutures to provide temporary corneal protection.

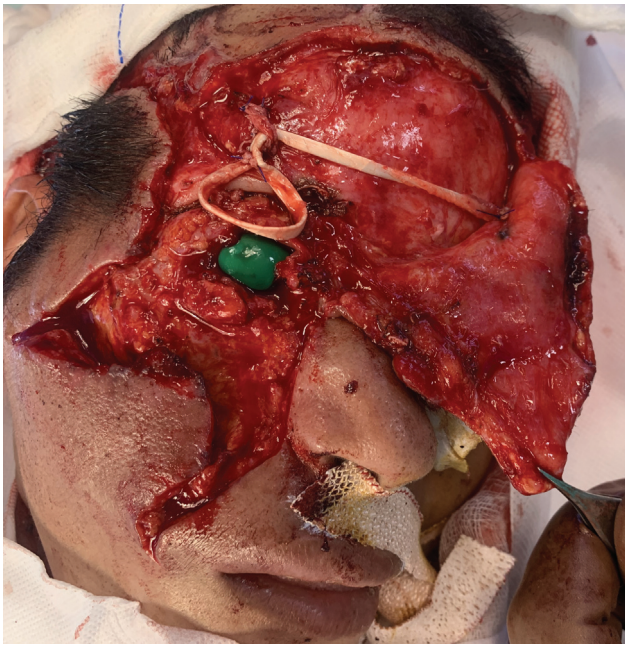All relevant preoperative investigations were done and the patient was planned for staged eyelid reconstruction. In the first stage the wounds were washed, and necrotic edges and the debris were removed from the wound. The raw areas over the scalp were grafted with split-thickness skin harvested from the thigh and the temporal skin was rotated into the defect along with advancement of the cheek and remnant forehead skin to allow for total coverage of the eyeball, which was the primary goal of the surgery. Using polypropylene 2-0, suture fixation was done for the fractured lateral orbital rim, and the exposed bone was covered with the transposed temporal skin. A small aperture was left over the eyeball to allow for instillation of necessary eye medications (►Fig. 3).

Thereafter once the grafts healed and there was no evidence of any infection or keratopathy in the eye, the patient was again taken for the second-stage surgery after 2 weeks. In this stage the previous sutures were opened and a defect of 6 × 6 cm was created over the eyeball which was resurfaced with a free radial artery forearm fasciocutaneous flap harvested from the left forearm. Recipient vessels chosen were the right facial artery, right facial vein, and tributaries of the right external jugular vein. Along with the fasciocutaneous flap, the palmaris longus tendon was also harvested from the same forearm. The palmaris longus tendon was attached to the left-side frontalis muscle at a distance of 2.5 cm above the left eyebrow and via a mechanical pulley created using a small piece of the tendon in the right supra brow region (2.5 cm above the right eyebrow), it was directed inferiorly and sutured to the neo tarsal plate

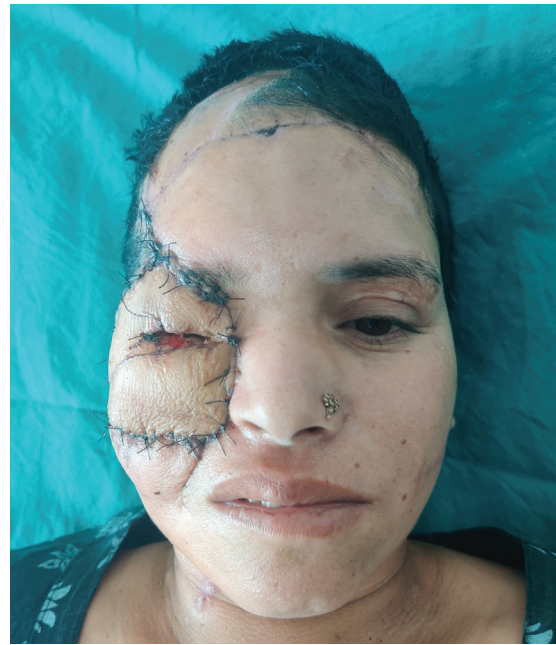

**Fig. 3** Clinical photograph depicting the use of local flaps and split thickness skin grafts to provide eyeball protection in first stage.





**Fig. 4** Intraoperative photograph depicting the tendon-pulley system which is thereafter attached to the upper eyelid tarsal plate allowing eye opening.



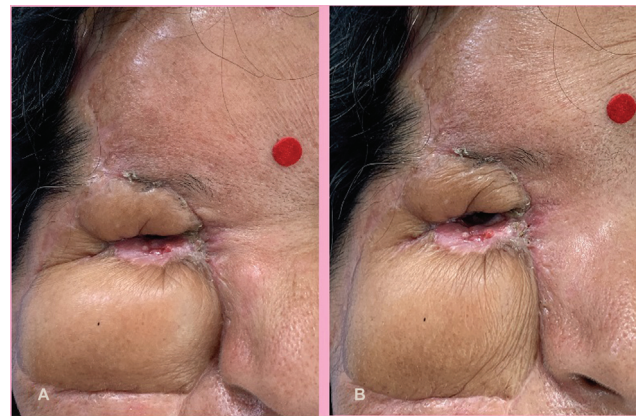**Fig. 5** Clinical photograph of the postoperative status after free radial forearm flap coverage in second stage showing complete flap survival.

(which was reconstructed using a small conchal graft with perichondrium for the conjunctival surface, harvested from the right ear) in a “hanger”-like fashion (→ Fig. 4). The tendon length was kept equal to the interpupillary distance which was measured as 7 cm. Theoretically it was calculated using the Pythagoras theorem that a 1 cm lift in the left frontalis attachment would be able to achieve a 6 to 7 mm pull on the tendon bringing an equivalent eye opening. All tendon attachments were fixed in their positions using polypropylene 3-0 sutures. A 3 cm incision was also made within the flap to form the eye aperture and the edges were sutured to the upper and lower bulbar conjunctiva to provide support to the eyeball. Artificial tear eye drops and antibiotic eye ointments were continued.

The free flap healed with no complications (→ Fig. 5) and the eyeball was assessed regularly by the ophthalmology team to prevent any corneal pathology. A temporary bandage contact lens was placed to prevent desiccation.

Subsequently after 3 weeks, the patient was again taken up for surgery wherein the palmaris longus sling was readjusted and tightened. Also the aperture was elongated along with medial and lateral canthoplasty so as to provide a more aesthetic look to the patient's face. Postoperative rehabilitation with mirror exercises, wherein she was taught to lift the contralateral eyebrow which resulted in the gradual opening of the neo-upper eyelid on the right side, was started.

Prior to discharge, approximately 2 weeks after the last surgery, the patient was able to lift the upper eyelid just enough to allow complete normal binocular vision with an eye opening measured around 3 mm and was very satisfied with the cosmetic outcome of the entire reconstructive process (→ Fig. 6A, B). In a 2-month follow-up, after regular physiotherapy including ultrasonic therapy and with further



**Fig. 6** Clinical photographs after revision surgery. (A) At rest with closed palpebral fissure. (B) With raised upper eyelid allowing vision.

contraction of the tendon-pulley system, an increase in eye opening to approximately 5 mm was observed. Long-term sustainability of this method is yet to be seen and confirmed, but till date, after approximately 6 months from the procedure the patient is able to maintain the achieved eye excursion and perform all activities of daily living with no discomfort.

## Discussion

Total eyelid defects are rare and reconstruction of unilateral full-thickness upper and lower eyelids is a formidable task. Thin pliable skin, mucosal layer, mechanical support, and mobility should ideally be provided.<sup>2</sup> Corneal protection is the urgent concern in the reconstruction of large eyelid defects. If there is any delay in reconstruction, corneal

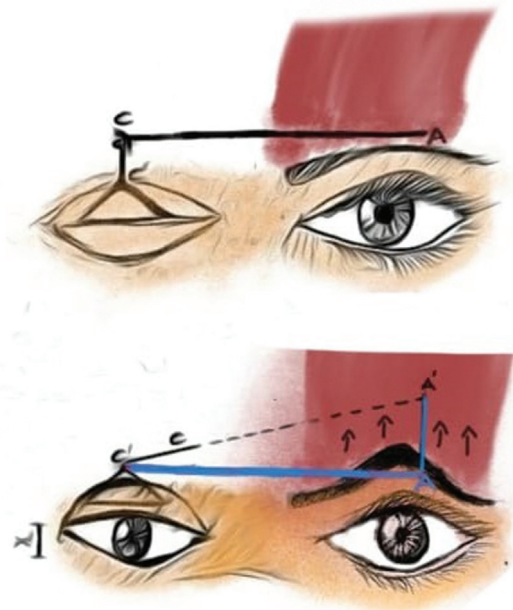
lubrication and moist chambers should be started immediately,<sup>1</sup> as was done in our case.

Eyelid reconstructions are traditionally based on the percentage of the defect involved. The reconstructions are based on the components involved, namely partial or full-thickness defect. Various techniques have been described for the reconstruction of total eyelid defects using local flaps with or without use of a cartilage graft such as superficial-temporal-artery-based local flaps, forehead flaps,<sup>3</sup> regional options such as deltopectoral flap,<sup>2</sup> and modified postauricular flaps like Olympic Torch flap.<sup>4</sup> Many sandwich flap techniques have also been documented in the literature which utilize the local orbicularis muscle and use avascular skin or mucosal grafts to provide a lamellar reconstruction of the eyelid.<sup>5</sup> However, most of these techniques have been described in relation to periocular or orbital tumors where the regional anatomy is undisturbed providing multiple local reconstructive options, which was not the case in our patient. Free tissue transfer is indicated when the soft tissue loss is massive and was the only reliable option in our case to provide thin, pliable skin so as to cover the defect. Previously flaps like the anterolateral thigh flap,<sup>6</sup> radial forearm flap,<sup>7,8</sup> and dorsalis pedis flap<sup>9</sup> have been described for microvascular tissue transfer to reconstruct large defects of eyelids.

The reconstructions so far described in the literature merely help in resurfacing the defect but do not offer any functional role leaving a ptotic eye. Injuries which involve upper periorbital muscles that help in opening or closure of the eyelids especially levator aponeurosis, orbicularis oculi, and frontalis with intact vision mandate functional soft tissue reconstruction. In a region like the orbit bringing in more than one free tissue is again tough due to limited recipient vessels in the area. Out of the two functions of eye opening and closure, eye opening is more difficult if the ipsilateral frontalis is not functional. Hence the options for addressing this issue are very few.

The main goal in such situations is to provide the periorbital region with soft tissue that closes the palpebral aperture at rest and opens when the patient wants to use that eye for seeing. The muscles that normally help in eye opening are levator aponeurosis and frontalis. In these defects where the effect of trauma is widespread and large, it is highly improbable to expect the levator to be intact. Moreover, this muscle due to the violent nature of trauma is more likely to get detached from its insertion and gets pulled in to the orbital cavity becoming unavailable for any reconstruction. In this case there was already loss of frontalis on the ipsilateral side and hence could not be used.

Using a tendon-pulley system for contralateral upper eyelid opening has not been described before. This article has for the very first time suggested this technique for such complex defects. The soft tissue defect was first resurfaced with a free radial forearm fasciocutaneous flap. The second part of the procedure involves using the action of contralateral frontalis action to elevate the ipsilateral upper eyelid to enable opening of eye (► Fig. 7). Revision surgeries were then needed for providing a more aesthetic palpebral aperture.



**Fig. 7** Schematic diagram (author's own creation) to explain the action of the tendon-pulley system to recreate a functional upper eyelid. The line A–C–C' represents the tendon and the point C represents the site of the pulley. Vertical excursion of the right upper eyelid is brought about by the pull generated by the action of the contralateral frontalis muscle.

This procedure can also act as an internal splinting in a way described for nerve injuries of upper limb by providing an interim solution to enable drainage of secretions from the affected eye and prevent amblyopia by allowing eye opening until the function of ipsilateral frontalis takes over in cases with such severe injuries and temporary paresis of frontalis or following nerve repair of frontal branch of facial nerve. In conclusion, eyelid protection, restoration of vision, and cosmesis are the main goals of reconstruction of the total eyelid defect. We have described a method which is effective and cosmetically and functionally satisfying to the patient using a fasciocutaneous free flap and utilization of the contralateral frontalis muscle via a tendon-pulley system.

#### Author Contributions

Conceptualization, data curation, formal analysis, visualization: M.V. Methodology: All authors. Project administration: M.V., N.M., and V.M. Writing-original draft: N.M. Writing-review and editing: N.M., M.J., and P.A.J.

#### Patient Consent

Informed written consent has been taken from the patients on whom surgeries were performed as per the hospital protocol.

#### Funding

None.

#### Conflict of Interest

None declared.

## References

- 1 deSousa JL, Leibovitch I, Malhotra R, O'Donnell B, Sullivan T, Selva D. Techniques and outcomes of total upper and lower eyelid reconstruction. *Arch Ophthalmol* 2007;125(12):1601–1609
- 2 Gujjalanavar RS, Girish AC. Total upper and lower eyelid reconstruction using deltopectoral flap. *Indian J Plast Surg* 2013;46(03):581–583
- 3 Ozdemir R, Sungur N, Sensöz O, et al. Reconstruction of facial defects with superficial temporal artery island flaps: a donor site with various alternatives. *Plast Reconstr Surg* 2002;109(05):1528–1535
- 4 Vathulya M, Chattopadhyay D, Koyama K. Olympic torch flap: one-stop option for simultaneous brow, upper and lower lid reconstruction in post burn patients. *Ann Burns Fire Disasters* 2017;30(02):143–145
- 5 Naugle TC Jr, Levine MR, Carroll GS. Free graft enhancement using orbicularis muscle mobilization. *Ophthalmology* 1995;102(03):493–500
- 6 Rubino C, Farace F, Puddu A, Canu V, Posadinu MA. Total upper and lower eyelid replacement following thermal burn using an ALT flap—a case report. *J Plast Reconstr Aesthet Surg* 2008;61(05):578–581
- 7 Watanabe T, Furuta S, Hataya Y, Yuzuriha S, Otsuka Y. Reconstruction of the eyelids and nose after a burn injury using a radial forearm flap. *Burns* 1997;23(04):360–365
- 8 Ghadiali LK, Patel P, Levine JP, Gold KG, Lisman RD. Microvascular free flap for total eyelid reconstruction with a visually useful eye. *Ophthalm Plast Reconstr Surg* 2016;32(05):e109–e111
- 9 Thai KN, Billmire DA, Yakuboff KP. Total eyelid reconstruction with free dorsalis pedis flap after deep facial burn. *Plast Reconstr Surg* 1999;104(04):1048–1051