



# Gender Determination by Measuring Maxillary Sinus Volume Using Computed Tomography

Sashisaroj Tarkeshwar Tiwari<sup>1</sup> Shrikrishna U.<sup>1</sup> Jaseemudheen M.M.<sup>2</sup>

<sup>1</sup>Department of Radiodiagnosis and Imaging, K.S. Hegde Medical Academy, Mangalore, Karnataka, India

<sup>2</sup>Department of Medical Imaging Technology, K.S. Hegde Medical Academy, Mangalore, Karnataka, India

Address for correspondence Jaseemudheen M.M., MSc, Department of Radiodiagnosis and Imaging, K.S. Hegde Medical Academy, Deralakatte, Mangalore, Karnataka 575018, India (e-mail: jaseemudheen12@gmail.com).

J Health Allied Sci<sup>NU</sup> 2023;13:64–72.

## Abstract

**Rationale and Objectives** Skeleton analysis based on age and gender is of great importance since it is an initial step in personal identification and can be used to rebuild biological profiles and narrow down diagnosis toward correct possibilities of any unknown skeletons. Different dimensions of the maxillary sinus (MS) can be used to differentiate between gender. This study aims to evaluate and compare the dimensions and volume of MS among age and genders.

**Materials and Methods** Ninety patients (male 49, female 41) were studied. Different dimensions of MS, like anteroposterior (AP), superioinferior (SI), mediolateral (ML) diameter, volume of MS, and the distance between two MS were measured on computed tomography (CT) paranasal sinus images using an inbuilt electronic caliper on Digital Imaging and Communications in Medicine viewer software.

**Statistical Analysis** Independent *t*-test and analysis of variance were used for data analysis in genders and age groups. Paired *t*-test was used for comparison of right and left MS.

**Results** The dimensions and volume of MS were higher in males than females. Dimensions such as AP, SI diameter ( $p < 0.005$ ), and volume of MS ( $p < 0.001$ ) were significantly different in genders. The ML diameter and the distance between two MS were statistically insignificant in genders. No significant difference between MS dimensions and volume was noted in different age groups, but age group 3 (41–55 years) showed higher mean values for all the measurements. A consistency was noted in the measurements in both two-dimensional (2D) and three-dimensional (3D) images.

**Conclusion** MS dimensions are greater in males compared with females. The different dimensions and volumes of the MS using 2D or 3D CT scan images can be used along with other methods for gender determination in forensic anthropology.

## Keywords

- ▶ forensic anthropology
- ▶ maxillary sinus
- ▶ paranasal sinus

article published online  
May 29, 2022

DOI <https://doi.org/10.1055/s-0042-1748633>.  
ISSN 2582-4287.

© 2022. Nitte (Deemed to be University). All rights reserved.  
This is an open access article published by Thieme under the terms of the Creative Commons Attribution-NonDerivative-NonCommercial-License, permitting copying and reproduction so long as the original work is given appropriate credit. Contents may not be used for commercial purposes, or adapted, remixed, transformed or built upon. (<https://creativecommons.org/licenses/by-nc-nd/4.0/>)  
Thieme Medical and Scientific Publishers Pvt. Ltd., A-12, 2nd Floor, Sector 2, Noida-201301 UP, India

## Introduction

The rapid urbanization and development of big cities and towns have led to an increase in the graph of crime rate; as a result, we come across unknown dead bodies or skeletons with unknown causes of death, few skeletons are badly disfigured or fragmented, as such medico-legal cases are of great concern and are dealt by forensic medicine. Despite rapid progress in various diagnostic methods, identifying skeletons and decomposing human remains is one of the most challenging tasks in forensic medicine. The primary concern of any skeleton analysis is the determination of gender and age.<sup>1</sup> It is of great importance since it is an initial step in personal identification, and it can be used to rebuild biological profiles and narrow down diagnosis toward correct possibilities of any unknown skeletons.<sup>2</sup> When bones that were used conventionally for estimation of gender are recovered in fragmented, incomplete, or in a mixed state, gender and age determination can be done using structures protected by denser bones and recovered intact. Thus, the maxillary sinus (MS) can be used to estimate age and gender since it is undamaged even if the skull or other bones are poorly disfigured.<sup>3</sup>

The anatomy of MS varies from person to person. The environmental conditions, genetic diseases, and any past infections may affect the pneumatization process of MS; thus, these complications lead to the anatomic and pathologic variation of MS.<sup>4</sup> An uncommon condition such as hypoplasia of MS may be seen unilaterally in 7 to 8% of cases and bilaterally in 2% of adults, and an extremely rare condition, aplasia can also be seen in some cases.<sup>5</sup>

MSs differ significantly in shape, position, and size in different individuals, on each side of the same individual, and in people with varying groups of age.<sup>6,7</sup> The MS extends to the roof of permanent teeth after deciduous teeth fall off. It originates as an evagination of nasal mucosa into the maxilla; thus, such development leads to an enormous quantity of anatomical variation in the MS of individuals.<sup>8</sup>

The sinuses develop within the bone of the viscerocranium and the MS is the first paranasal sinus (PNS) to form. They are small at birth and after birth, enlarge with the growing maxilla, and fully develop after the eruption of permanent dentition.<sup>9</sup>

Different dimensions of the MS can differentiate between gender and different age groups.<sup>10</sup> The radiological modalities are considered as a gold standard for evaluation of the actual anatomy of sinuses and are commonly used in forensic anthropology for gender and age determination as they are very simple, cheap, and take less time compared with conventional biochemical and histopathological methods.<sup>11</sup> The MS can be investigated by different imaging techniques and modalities, including cone-beam computed tomography (CBCT), CT, and clinical examination of MS by either intra- or extraoral methods.

CT is a noninvasive method that acquires an image using an X-ray. It can be used for the evaluation of the MS. CT images are used to locate the anatomic structure and give information about the different dimensions of the bone and

its morphology.<sup>4</sup> It overcomes all the limitations of CBCT, like reducing CB-related artifacts in images, providing higher resolution images, and decreasing scan time. It substitutes the traditionally used X-ray imaging like plain radiographs, fluoroscopy, or dental radiographs.<sup>12</sup>

CT scan provides an accurate assessment of PNS and craniofacial bones and gives a precise measurement of the different dimensions of MS, that is, its width, height, length, and volume. It also produces a three-dimensional (3D) image that allows complex evaluation of the MS anatomy.<sup>13</sup>

MS dimensions by CT tools can reveal age and gender when other methods are indecisive. CT is a magnificent imaging modality in recognizing unknown remains because it produces higher resolution images and thus can evaluate sinus anatomy and provide precise measurements of MS.<sup>14,15</sup>

This study was designed to adjudge the usefulness of MS volume for gender determination using CT in forensic anthropology. Two-dimensional (2D) and 3D images were used for measuring different dimensions of the MS and the sinus volume was measured to find the variation in volume concerning different age groups and gender.

## Materials and Methods

It was a retrospective study performed in the Department of Radiodiagnosis, Justice K.S. Hegde Charitable Hospital, after receiving ethical clearance from the institutional ethical committee. The study included a total of 90 patients (male 49 [54.4%] and female 41 [45.6%]) from 18 to 55 years of age referred for CT PNS in our institute. Patients were excluded based on the history of trauma related to MS. All scans were performed on GE Elite Bright Speed (16-slice multidetector CT), and data was collected from the Digital Imaging and Communications in Medicine (DICOM) software. Patients were categorized into three different age groups: 18 to 25, 26 to 40, and 41 to 55 years of age.

The measurements were taken on 2D and 3D reconstructed images of both MSs. Measurements were done using an inbuilt electronic caliper into a DICOM viewer software. The largest linear measurements of the diameters like anteroposterior (AP), superoinferior (SI), and mediolateral (ML) and distance between right (RMS) and left MS (LMS) were performed on coronal and sagittal planes, and volume of the sinus was calculated using the formula  $AP \times ML \times SI \times 0.625$ .

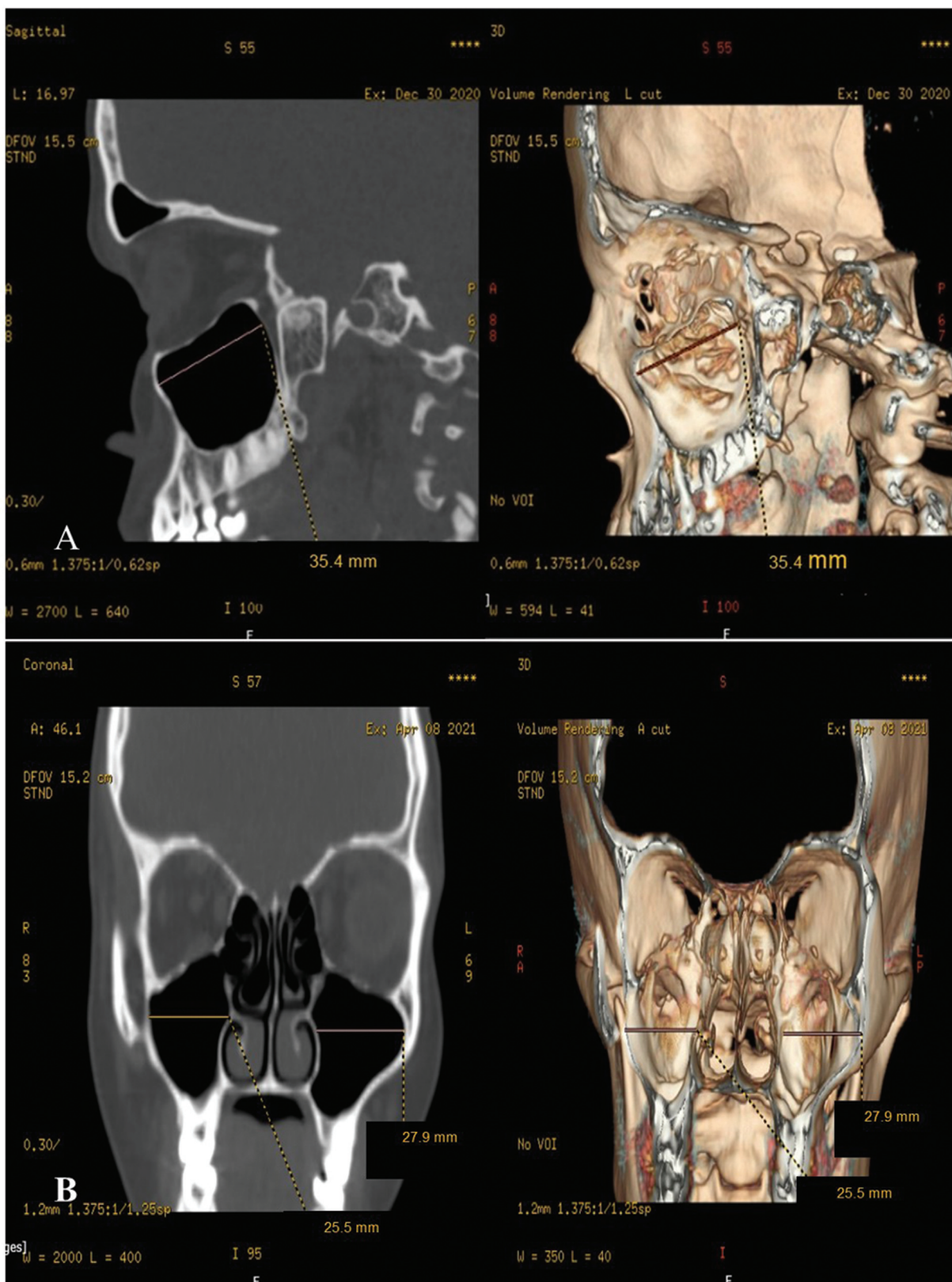
The measurements were as follow:

**AP diameter** was measured on the sagittal images from the most anterior point to the most posterior point of the RMS and LMS on 2D and 3D images.

**ML diameter:** It was measured on coronal images from the longest distance perpendicular from the medial wall of the MS to the outermost point of the lateral process of both RMS and LMS on 2D and 3D images (► **Figs. 1 and 2**).

**SI diameter:** It was measured on coronal images from the longest point of sinus floor to sinus roof of both MS on 2D and 3D images.

**Distance between two MSs:** Measured on coronal planes of both 2D and 3D images.

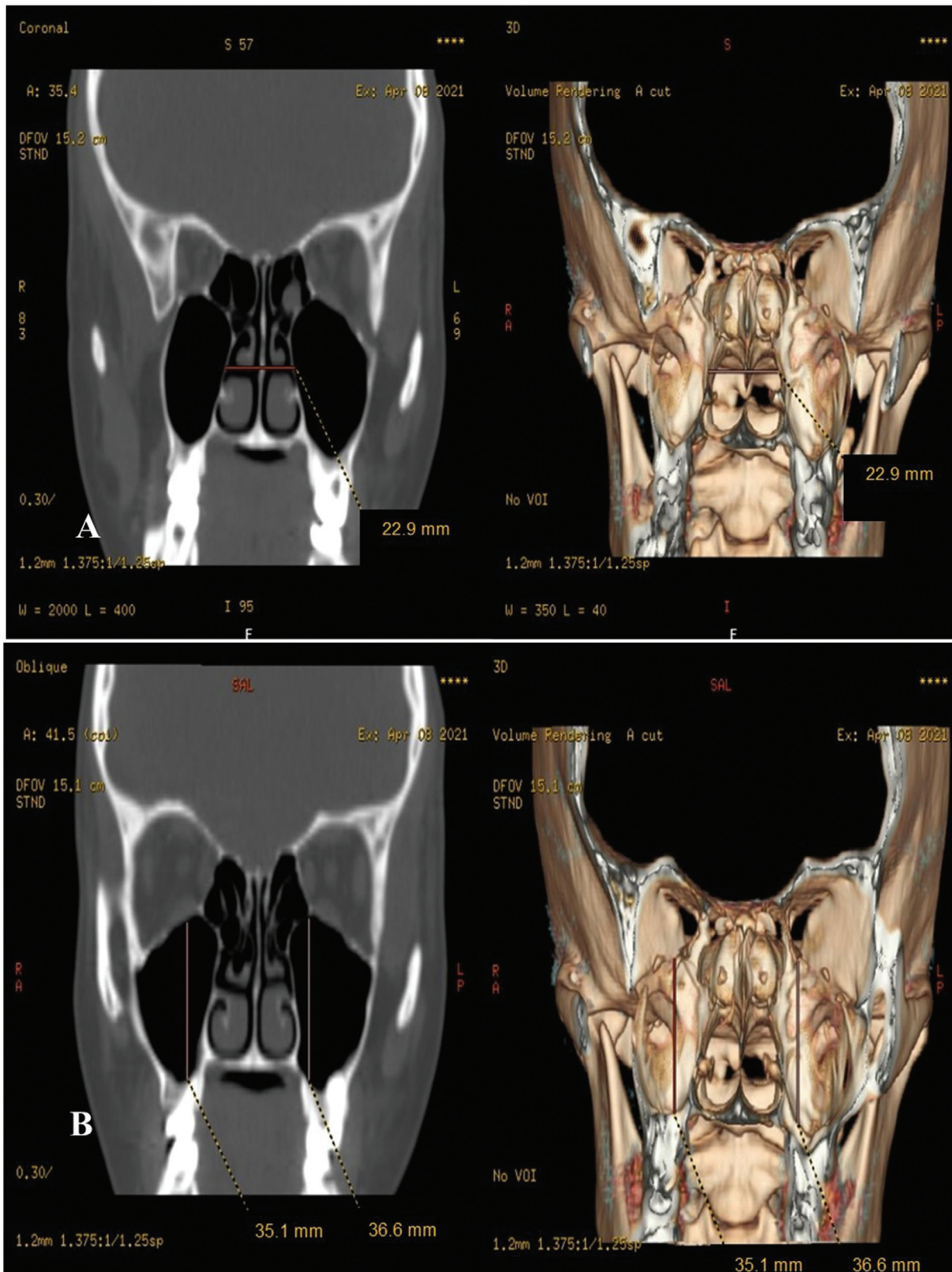


**Fig. 1** (A) Measurement of anteroposterior (AP) diameter on two-dimensional (2D) and three-dimensional (3D) images. (B) Measurement of mediolateral (ML) diameter on 2D and 3D images.

**Data and Statistical Analysis**

The collected data was computed on Microsoft Excel 2010 and was analyzed using a Statistical Package for Social

Science version 20.0 (SPSS-IBM). The mean and standard deviation of all individuals were calculated. An independent *t*-test was performed to compare dimensions and volume in



**Fig. 2** (A) Measurement of distance between right and left maxillary sinus (MS) on two-dimensional (2D) and three-dimensional (3D) images. (B) Measurement of superioinferior (SI) diameter on 2D and 3D images.

males and females. Comparison of dimensions and volume in different age groups using analysis of variance and a paired t-test were used to compare LMS and RMS in both genders.

## Result

The dimensions and volume of both the MS were greater in males than in females on 2D and 3D measurements. A

**Table 1** Analysis of different parameters of maxillary sinus in genders

Parameters	Males (49)	Females (41)	MD	t-Value	p-Value
	Mean	Mean			
AP right MS (2D)	37.15 ± 3.23	35.30 ± 2.40	1.855	3.115	0.002
AP left MS (2D)	37.22 ± 3.23	35.33 ± 2.41	1.889	3.167	0.002
AP right MS (3D)	37.50 ± 3.13	35.71 ± 2.54	1.788	2.934	0.004
AP left MS (3D)	37.58 ± 3.12	35.76 ± 2.52	1.824	3.006	0.003
ML right MS (2D)	27.00 ± 4.16	25.86 ± 3.34	1.145	1.419	0.159
ML left MS (2D)	27.05 ± 4.15	25.91 ± 3.34	1.144	1.422	0.159
ML right MS (3D)	26.10 ± 3.38	25.60 ± 2.81	0.501	0.754	0.453
ML left MS (3D)	26.19 ± 3.39	25.64 ± 2.80	0.549	0.826	0.411
SI right MS (2D)	34.94 ± 3.15	32.66 ± 4.15	2.283	2.959	0.004
SI left MS (2D)	35.00 ± 3.17	32.70 ± 4.15	2.298	2.975	0.004
SI right MS (3D)	34.39 ± 3.67	33.18 ± 4.07	1.215	1.487	0.141
SI left MS (3D)	34.46 ± 3.67	33.22 ± 4.05	1.239	1.519	0.132
Volume right MS (2D)	21.87 ± 4.95	18.37 ± 3.49	3.498	3.655	< 0.001
Volume left MS (2D)	21.87 ± 4.95	18.37 ± 3.49	3.498	3.655	< 0.001
Volume right MS (3D)	21.20 ± 4.7	18.95 ± 2.25	3.498	3.655	< 0.001
Volume left MS (3D)	21.20 ± 4.7	18.95 ± 2.25	3.498	3.655	< 0.001
Distance between right and left MS (2D)	29.37 ± 3.78	28.21 ± 4.32	1.162	1.361	0.177
Distance between right and left MS (3D)	29.45 ± 3.79	28.27 ± 4.31	1.180	1.379	0.171

Abbreviations: 2D, two-dimensional; 3D, three-dimensional; AP, anteroposterior; MD, mean difference; ML, mediolateral; MS, maxillary sinus; SI, superioinferior.

significant difference was noted in the AP diameter of both MS, in males and females on 2D and 3D images ( $p < 0.005$ ). The mean AP diameter was greater in males than females, with a mean difference of around 1.8 mm. The ML diameter was statistically insignificant in males and females on both sides ( $p > 0.005$ ). A significant difference was also noted in SI diameter in males and females on a 2D image with a mean difference of 2.283 mm. The mean distance between the male RMS and LMS was  $29.37 \pm 3$  and  $29.45 \pm 3.79$  mm on 2D and 3D, respectively. Females had a mean of  $28.21 \pm 4.32$  mm on 2D and  $28.27 \pm 4.31$  mm on 3D; the distance was greater in males than females but was statistically insignificant in genders. The MS volume showed a significant difference in genders with  $p < 0.001$ , larger MS volume was seen in males than females. The mean volume of both the MS on 2D was  $21.87 \pm 4.95$  and  $18.37 \pm 3.94$  cm<sup>3</sup> for males and females, respectively (mean difference of  $3.98$  cm<sup>3</sup> between genders). The mean volume of RMS and LMS on 3D was  $21.206 \pm 4.7$  and  $18.956 \pm 3.94$  cm<sup>3</sup> for males and females, respectively, with a mean difference of  $2.25$  cm<sup>3</sup> in genders (**Table 1**).

Patients were classified into three different age groups. A total of 28 patients were included under the age group of 18 to 25 years (male = 14, female = 14). The mean value for all the dimensions is found to be least in this age group, suggesting that MS is growing. A total of 35 patients were included in 26 to 40 years of age (male = 19, female = 16). A partial increase in the mean value of the dimensions is noted

in this age group. The third group included 27 patients of 41 to 55 years (male = 16, female = 11). Showing a maximum means value resulting from maximum growth of MS in that age compared with all other age groups. No statistically significant difference was noted in the parameters of both the MS in different age groups on 2D and 3D images (**Table 2**).

Comparison between RMS and LMS in males and females was done using paired *t*-test. A significant side difference was noted in AP, ML, and SI diameter on 2D and 3D images ( $p < 0.005$ ). No significant side differences were seen regarding the MS volume, either in males or females. The LMS showed a higher value in all dimensions compared with the right side (**Table 3**).

## Discussion

In our study, the sizes of all dimensions of MS were found to be greater in males. However, significant differences were noted in gender only concerning SI, AP diameter, and volume of MS. The mean AP diameter in the present study for RMS was  $37.155 \pm 3.23$  and  $35.3 \pm 2.4$  mm in males and females, respectively. The mean for LMS was  $37.266 \pm 3.23$  mm in males and  $35.336 \pm 2.4$  mm in females. In a study performed by Sharma et al, having 102 individuals of 20 to 40 years of age from the Gwalior region of India was found to have a slight variation in mean AP diameter. It was  $34.89 \pm 3.2$  and  $35.03 \pm 3.5$  in RMS and LMS in males. The females showed a

**Table 2** Analysis of maxillary sinus in different age groups

Parameters	Age groups	Mean	F	p
AP right MS (2D)	18-25	35.68 ± 2.73	1.593	0.209
	26-40	36.18 ± 2.87		
	41-55	37.11 ± 3.38		
AP left MS (2D)	18-25	35.72 ± 2.71	1.604	0.207
	26-40	36.26 ± 2.91		
	41-55	37.16 ± 3.39		
AP right MS (3D)	18-25	36.09 ± 2.99	1.321	0.272
	26-40	36.62 ± 2.75		
	41-55	37.40 ± 3.26		
AP left MS (3D)	18-25	36.14 ± 2.98	1.392	0.254
	26-40	36.69 ± 2.73		
	41-55	37.47 ± 3.26		
ML right MS (2D)	18-25	25.91 ± 4.08	0.439	0.646
	26-40	26.76 ± 3.80		
	41-55	26.71 ± 3.67		
ML left MS (2D)	18-25	25.96 ± 4.07	0.449	0.640
	26-40	26.81 ± 3.80		
	41-55	26.76 ± 3.65		
ML right MS (3D)	18-25	26.07 ± 2.75	0.390	0.678
	26-40	26.06 ± 2.90		
	41-55	25.42 ± 3.78		
ML left MS (3D)	18-25	26.12 ± 2.75	0.402	0.670
	26-40	26.15 ± 2.90		
	41-55	25.49 ± 3.78		
SI right MS (2D)	18-25	34.03 ± 3.62	1.432	0.244
	26-40	34.55 ± 3.79		
	41-55	32.92 ± 3.93		
SI left MS (2D)	18-25	34.07 ± 3.63	1.430	0.245
	26-40	34.62 ± 3.79		
	41-55	32.98 ± 3.94		
SI right MS (3D)	18-25	33.88 ± 4.28	0.162	0.851
	26-40	33.58 ± 3.87		
	41-55	34.14 ± 3.58		
SI left MS (3D)	18-25	33.90 ± 4.27	0.151	0.860
	26-40	33.65 ± 3.86		
	41-55	34.20 ± 3.57		
Volume right MS (2D)	18-25	19.38 ± 4.58	0.716	0.492
	26-40	20.79 ± 4.54		
	41-55	20.54 ± 5.44		
Volume left MS (2D)	18-25	19.38 ± 4.58	0.716	0.492
	26-40	20.79 ± 4.54		
	41-55	20.54 ± 5.44		
Volume right MS (3D)				

(Continued)

**Table 2** (Continued)

Parameters	Age groups	Mean	F	p
Volume left MS (3D)	18-25	19.87 ± 3.85	0.303	0.740
	26-40	19.99 ± 4.15		
	41-55	20.72 ± 5.24		
	18-25	19.87 ± 3.85	0.306	0.737
	26-40	19.99 ± 4.15		
	41-55	20.73 ± 5.24		
Distance between right and left MS (2D)	18-25	28.56 ± 3.75	0.850	0.431
	26-40	29.53 ± 4.16		
	41-55	28.25 ± 4.22		
Distance between right and left MS (3D)	18-25	28.61 ± 3.77	0.879	0.419
	26-40	29.61 ± 4.17		
	41-55	28.31 ± 4.22		

Abbreviations: 2D, two-dimensional; 3D, three-dimensional; AP, anteroposterior; ML, mediolateral; MS, maxillary sinus; SI, superioinferior.

mean of  $33.20 \pm 2.9$  and  $33.59 \pm 2.9$  for the right and left sides. The mean values were comparatively higher in our study, and this variation might be due to differences in the study population concerning geographical factors.<sup>10</sup> Another similar study by Urooge and Patil in the Indian population of Karnataka state, including a total of 100 patients, showed almost similar results like the present study having a mean AP of RMS as  $38.1 \pm 0.33$  in males and  $37.6 \pm 0.23$  in females and LMS mean as  $37.8 \pm 0.33$  and  $37.1 \pm 0.29$  in males and females, respectively.<sup>16</sup>

Comparison of the study by Teke et al performed on the Turkish population showed a considerable variation in mean AP diameter.<sup>17</sup> The mean AP for males was  $47.63 \pm 6.4$  mm for RMS and  $47.21 \pm 6.5$  mm for LMS. In females, it was  $45.11 \pm 4.6$  and  $43.64 \pm 4.4$  for RMS and LMS. A wide variation was noted in the Indian and Turkish populations, suggesting that Turkish people possess a larger AP diameter

for MS. This variation might be due to racial and ethnic factors.

The study by Uthman et al on the Iraq population showed a minimal difference in AP diameter.<sup>18</sup> In males, it was  $39.3 \pm 3.8$  and  $39.4 \pm 3.7$  in RMS and LMS. The diameter was  $36.9 \pm 3.8$  and  $37 \pm 4$  in females' RMS and LMS. Indian and Iraq population do not show a massive difference in the AP diameter.

The SI diameter in the present study was also significantly different in males and females. The Turkish population showed the largest SI diameter with a mean of  $42.58 \pm 7.9$  and  $43.71 \pm 7.7$  of RMS of males and females. Whereas LMS mean was  $37.819 \pm 5.6$  and  $37.60 \pm 6.04$  in males and females. The present study showed the least SI value with a mean of  $34.94 \pm 3.15$  and  $32.66 \pm 4.15$  mm of RMS in both males and females. The mean for LMS was  $35 \pm 3.17$  mm in males and  $32.7 \pm 4.15$  mm in females. The mean height of MS

**Table 3** Analysis of parameters in right and left maxillary sinus in males and females

Parameters (f)	Mean difference (MD)		t-Value		p-Value	
	Males	Females	Males	Females	Males	Females
AP right MS (2D) AP left MS (2D)	$-0.071 \pm 0.093$	$-0.036 \pm 0.073$	-5.345	-3.194	< 0.001	0.003
AP right MS (3D) AP left MS (3D)	$-0.079 \pm 0.163$	$-0.043 \pm 0.080$	-3.412	-3.480	0.001	0.001
ML right MS (2D) ML left MS (2D)	$-0.051 \pm 0.064$	$-0.051 \pm 0.084$	-5.499	-3.903	< 0.001	0.000
ML right MS (3D) ML left MS (3D)	$-0.091 \pm 0.176$	$-0.043 \pm 0.083$	-3.641	-3.354	0.001	0.002
SI right MS (2D) SI left MS (2D)	$-0.063 \pm 0.083$	$-0.048 \pm 0.095$	-5.310	-3.281	< 0.001	0.002
SI right MS (3D) SI left MS (3D)	$-0.063 \pm 0.069$	$-0.039 \pm 0.080$	-6.344	-3.114	< 0.001	0.003
Volume right MS (2D) Volume left MS (2D)	-	$-0.002 \pm 0.015$	-	-1.000	-	0.323

Abbreviations: 2D, two-dimensional; 3D, three-dimensional; AP, anteroposterior; ML, mediolateral; MS, maxillary sinus; SI, superioinferior.

in Iraq and Turkish population was nearly the same. The studies on the Indian population showed a mean from 35 to 36 mm in males and 32 to 35 mm in females.

The ML diameter in our study was found to be insignificant in males and females. This result was similar to the study of the Gwalior region. At the same time, the ML was significantly different in the Iraq population, with a mean of  $24.7 \pm 4$  and  $22.7 \pm 3.2$  of RMS in males and females, respectively. The LMS showed a mean of  $23 \pm 4$  in females and  $25.6 \pm 4.4$  in males. The significance in ML diameter of genders might be seen due to the equal distribution of males and females in that study. The Turkish population showed a ML value of  $27.18 \pm 5.4$  in males and  $26.82 \pm 5.5$  in females on the right side and  $24.44 \pm 3.6$  and  $24.27 \pm 3.9$  on the left side in males and females, respectively. The mean value of the Turkish population was almost similar to the present study.

The volume of MS was also significant in genders. The mean volume for both MS was  $21.87 \pm 4.71 \text{ cm}^3$  in males and  $18.37 \pm 3.94 \text{ cm}^3$  in females. In the study at the Gwalior region, the mean volume on both sides was  $16.147 \pm 5.99 \text{ cm}^3$  in males and  $13.92 \pm 4.299 \text{ cm}^3$  in females. In the study of Karakas and Kavakli on 91 Turkish population of 5 to 55 years of age, the mean volume was comparatively less than the present study. The MS volume in males was  $14.74 \pm 5.79 \text{ cm}^3$  in RMS and  $14.55 \pm 4.72 \text{ cm}^3$  in LMS. In comparison, females had a mean of  $14.29 \pm 3.42 \text{ cm}^3$  on the RMS and  $13.78 \pm 3.41 \text{ cm}^3$  on LMS.<sup>19</sup> The vast difference of volume in both studies might be due to differences in patients' age groups since they included patients from 5 years, which suggests that MS is in its growing period, which might lead to a decrease in the mean volume.

Comparison with other studies showed that MS could be used for gender determination, and it also varies according to geographical and ethnic factors. The AP, SI diameter, and volume of MS were found to be the standard discriminative parameter for gender determination. The mean values of all parameters were higher in males compared with females. This gender-related difference may be due to energetic intake, nutrition, body composition, and genetics.

Our study also performed age estimation using MS dimensions and volume. Patients were categorized into three different age groups. In a prospective study performed by Abed-Allah and Mahdi on 110 cadavers, data was categorized into four age groups from 20 to 29, 30 to 39, 40 to 49, and 50 to 59 years.<sup>20</sup> Group 1 (20–29 years) showed a smaller mean value than other age groups. Similarly, in the present study the lowest value was seen in the age group of 18 to 25 years, suggestive of MS in its growing stage during that period. Group 2 (30–39 years) showed growth in the width and length of MS, whereas the age group of 40 to 49 years showed a partial increase in length and width, indicating the maximum height of MS in the comparative study. The last age group in both studies showed a maximum mean value. There was no significant difference noted in both the studies concerning age. It only showed the growth of the MS in each decade of life. A slight variation was noted in both studies for mean values, and the mean was larger in the

present study. This difference might be due to the study sample, since the comparative study included a cadaver. There might be variation in MS dimensions as the skull ages or dries up due to the resorption of the maxilla following the loss of dentition.

In addition, a comparison between both the MS showed a significant side difference for AP, ML, and SI diameter of MS ( $p < 0.005$ ). No significant differences were seen in the MS volume in males and females. The LMS showed a higher value for all dimensions. A study of Najem et al on 82 CBCT images showed no bilateral significant difference for MS length, width, and height in males and females.<sup>11</sup> In a study by Uthman et al, there was no significant side difference for the length of MS.<sup>18</sup> The significant difference was seen in mean width and height of LMS and RMS only in males, and the side difference was insignificant in females.

The distance between RMS and LMS in the present study was insignificant in genders and age groups. A reliability test was also performed to check the consistency of the 2D and 3D measurements.

The intraclass coefficient (ICC) value of 0.5 to 0.7 was considered moderately reliable, values 0.75 to 0.9 indicated good reliability, and values greater than 0.9 were considered excellent consistency. The comparison between the AP and ML diameters in 2D and 3D showed moderate reliability with an ICC value of nearly 0.6 to 0.7. The maximum reliability in 2D and 3D measurements was seen with respect to volume and distance between the MS with an ICC value of 1.0. In contrast, SI 2D and 3D measurements showed good reliability between the two measurements.

Thus, the measurement of MS dimensions and volume using CT can be used in forensic anthropology and other methods for gender determination and to know the growth of MS in different age groups. It can also be helpful to study racial and geographical differences. The variation in the results of MS dimensions and volume in our study compared with other studies might be due to sample size. There was no equal distribution of males and females in our study. We did not include any patient below 18 years and above 55 years and a combination of other factors like patient's size, body stature, physic of individuals, genetic, and environmental factors.

## Conclusion

The MS dimensions and volume comparison showed a significant difference in both males and females. The mean values are higher in males than females. The age group 3 (41–55 years) was found to have the highest mean value compared with other age groups. There is a significant difference noted in both RMS and LMS dimensions in males and females, with LMS having a larger value. When comparing 2D and 3D measurements, there is a consistency maintained in both the measurements. Thus, the measurements of MS dimensions and volume using 2D or 3D CT images may be a helpful tool for gender determination and to know the growth of MS dimensions in different age groups.



**Conflict of Interest**

None declared.

**References**

- 1 Attia A, El-Badrawy A, Shebel H. Gender identification from maxillary sinus using multi-detector computed tomography. *Mansoura J Forensic Med Clin Toxicol* 2012;20(01):17–28
- 2 Tambawala SS, Karjodkar FR, Sansare K, Prakash N. Sexual dimorphism of maxillary sinus using cone beam computed tomography. *Egypt J Forensic Sci* 2016;6(02):120–125
- 3 Deshmukh A, Devershi D. Comparison of cranial sex determination by univariate and multivariate analysis. *J Anat Soc India* 2006;55(02):48–51
- 4 Mudgade D, Motghare P, Kunjir G, Darwade A, Raut A. Prevalence of anatomical variations in maxillary sinus using cone beam computed tomography. *J Indian Acad Oral Med Radiol* 2018;30(01):18
- 5 Whyte A, Chapeikin G. Opaque maxillary antrum: a pictorial review. *Australas Radiol* 2005;49(03):203–213
- 6 Bangi BB, Ginjupally U, Nadendla LK, Vadla B. 3D evaluation of maxillary sinus using computed tomography: a sexual dimorphic study. *Int J Dent* 2017;2017:9017078
- 7 Fernandes CL. Forensic ethnic identification of crania: the role of the maxillary sinus—a new approach. *Am J Forensic Med Pathol* 2004;25(04):302–313
- 8 Gupta C, Kumar S, Antony SD, Lakshmi NK. A study of morphometric evaluation of the maxillary sinuses in normal subjects using computer tomography images. *Arch Med Health Sci* 2014;2(01):12
- 9 Arijji Y, Kuroki T, Moriguchi S, Arijji E, Kanda S. Age changes in the volume of the human maxillary sinus: a study using computed tomography. *Dentomaxillofac Radiol* 1994;23(03):163–168
- 10 Sharma SK, Jehan M, Kumar A. Measurements of maxillary sinus volume and dimensions by computed tomography scan for gender determination. *J Anat Soc India* 2014;63(01):36–42
- 11 Najem S, Safwat W, Elaziz R, Gaweesh Y. Maxillary sinus assessment for gender and age determination using cone beam computed tomography in an Egyptian sample. *Alexandria Dent J* 2020;46(02):63–69
- 12 Leth PM (2011). CT-scanning in Forensic Medicine. In K. Subburaj (Ed.), *CT-scanning - Techniques and Applications* (pp. 311–328). InTech - Open Access Publisher.
- 13 Wanzeler AMV, Alves-Júnior SM, Ayres L, da Costa Prestes MC, Gomes JT, Tuji FM. Sex estimation using paranasal sinus discriminant analysis: a new approach via cone beam computerized tomography volume analysis. *Int J Legal Med* 2019;133(06):1977–1984
- 14 Dykewicz MS, Hamilos DL. Rhinitis and sinusitis. *J Allergy Clin Immunol* 2010;125(2, Suppl 2):S103–S115
- 15 Lerno P. Identification par le sinus maxillaire. *Chir Dent Fr* 1983;53(216):39–40
- 16 Urooge A, Patil BA. Sexual dimorphism of maxillary sinus: a morphometric analysis using cone beam computed tomography. *J Clin Diagn Res* 2017;11(03):ZC67–ZC70
- 17 Teke HY, Duran S, Canturk N, Canturk G. Determination of gender by measuring the size of the maxillary sinuses in computerized tomography scans. *Surg Radiol Anat* 2007;29(01):9–13
- 18 Uthman AT, Al-Rawi NH, Al-Naaimi AS, Al-Timimi JF. Evaluation of maxillary sinus dimensions in gender determination using helical CT scanning. *J Forensic Sci* 2011;56(02):403–408
- 19 Karakas S, Kavakli A. Morphometric examination of the paranasal sinuses and mastoid air cells using computed tomography. *Ann Saudi Med* 2005;25(01):41–45
- 20 Abed-Allah M, Mahdi A. Maxillary sinus measurements in different age groups of human cadavers. *Tikrit J Dent Sci* 2013;1:107–112