Article published online: 2022-05-23

Magnification in Periodontics: An Overview

Surabhi Durgapal[1] Mamatha Shetty[1]

[1] Department of Periodontics, A B Shetty Memorial Institute of Dental Sciences, Nitte (Deemed to be University), Mangalore, Karnataka, India

Address for correspondence Mamatha Shetty, Department of Periodontics, MDS, A B Shetty Memorial Institute of Dental Sciences, Nitte (Deemed to be University), Mangalore, Karnataka 575018, India (e-mail: drmamathasshetty@nitte.edu.in).

J Health Allied Sci[NU] 2023;13:1–10.

Abstract

A plethora of changes in the concept and the techniques in dental sciences and an increase in patient awareness have spawned demand in advanced dental treatment encompassing elimination of disease with more precision and less discomfort. The use of magnification systems like microscopes is widespread in the medical field, and now it has successfully spread its wings in dentistry. Visual enhancement by using loupes or surgical microscopes can render refinement in the basic surgical procedures. Magnification periodontics refers to the wide range of procedures performed by the use of magnification systems like loupes and microscopes that allow convergence of ideas and efforts, which can make a huge impact on patients. Periodontal procedures are being increasingly performed nowadays that have enabled enhanced outcomes, which were difficult to achieve with the macrosurgery procedures when wound healing and tissue trauma are in consideration. The surgical operating microscope works within the microsurgical triad that includes illumination increased precision and magnification. The incorporation of smaller instruments and sutures and better visualization of the operating site enhance the surgical skills of the clinician. In the past decade, various periodontal procedures from the removal of calculus to the placement of dental implants have been performed using the surgical microscope, which have invariably provided favorable results. It is a topic of interest in the future of periodontal therapy.

Keywords
- magnification
- loupes
- microscope
- microsurgery

Introduction

Magnification is broadly defined as the process of enlarging the apparent size of the image. With everyday evolving dentistry, surgical procedures have become more precise and less painful. An increase in patient awareness has resulted in a higher demand for advanced therapy that includes ailment elimination as well as aesthetic and functional restoration with minimal trauma and suffering. Conventional dental procedures are rendered with an unaided eye. Treatment that is performed under visual enhancement by making use of loupes or microscope is termed as microscopic.

History

The roots of microsurgery were laid back in the 1800s when the first magnifying device was introduced in the medical field. In the profundity of rich historical archives in this new era of surgery, use of magnification and application of microsurgical triad allows the convergence of ideas and efforts to make a desirable impact on the vast number of patients. In 1949, a Boston dentist, van Leeuwen, employed a Greenough microscope to study the periodontium.[1] In the 19th century, Carl Zeiss, Ernst Abbe, and Otto Schott devoted their time in developing a microscope currently knowns as

article published online
May 23, 2022

DOI https://doi.org/10.1055/s-0042-1747911.
ISSN 2582-4287.

Thieme Medical and Scientific Publishers Pvt. Ltd., A-12, 2nd Floor, Sector 2, Noida-201301 UP, India

Table 1 Timeline of inventions in microscope

S.no.	Date	Scientist	Invention
1	1949	Boston scientist, Van Leeuwen [1,4]	Greenhough microscope to study periodontium
2	1953	Carl Zeiss company of West Germany[4]	First commercially marketed binocular-operating microscope
3	1960s	Egger and Petran[67]	Produced the first mechanical scanning confocal laser microscope Concept of confocal microscope was given by Minsky in 1950s
4	1981	Apotheker and Jako [2,4]	Incorporated first commercially available dental operating microscope (Dentiscope, Chayes-Virginia Inc., Evansville, Indiana, United States)
5	1981	Gerd Binnig and Heinrich Rohrer [68,69]	Scanning tunneling microscope that gives three-dimensional images of objects down to the atomic level 1986 they won Nobel Prize in Physics
6	1985	IBM scientist[70]	Atomic force microscope

Zeiss.[2] The microscope was first introduced to periodontics in 1992, since then it has been extensively implemented in routine procedures. Apotheker and Jako were the first ones to introduce microscopes in dentistry. Since then, new inventions in magnification have made it an indispensable asset (►**Table 1**). Its elaborated use in various specialties like endodontics, prosthodontics, oral and maxillofacial surgery, and lenses has also changed the future of periodontal surgeries.

Microsurgical Triad

Three advantages offered by microsurgery to the operator are as follows (►**Fig. 1**):

a. Magnification System
b. Illumination
c. Increased Precision

a. Magnification System

The human eye is the most efficient visual detector when it comes to imaging speed and resolution. Together with the muscles and cornea, an optical image is projected onto the retina. A sharp image of focal length 20 cm is produced. Due to the little ability of the eye's lens to change shape, images of objects close to the eye cannot be brought into focus on the retina. The closest the object can be viewed by the naked eye is ~10 cm due to the fact that the viewing angle becomes extremely small; this is the reason the nearest object is blurred. Similarly, an object at a great distance cannot be viewed with fine details due to the viewing angle being too small to reach the retina.[3] The magnification system has the capability to magnify the image that is displayed on the retina by increasing the visual angle.

Total magnification = Objective magnification x eyepiece magnification

Dr. McQuillen, during his time as a student of dentistry, identified the value of magnifying glasses while observing late Prof. Elisha Townsend employing magnifying glass to observe the margin of restorations. From that time up to the present, his enduring work character was largely ascribed by other dentists.[4] Choice of magnification system depends upon the task that needs to be achieved and the level of the experience that the operator holds.[5]

a.1 Loupes

The most common form of magnification system currently being used, with two side-by-side monocular lenses angled to focus on the operating field. It can be adjusted according to

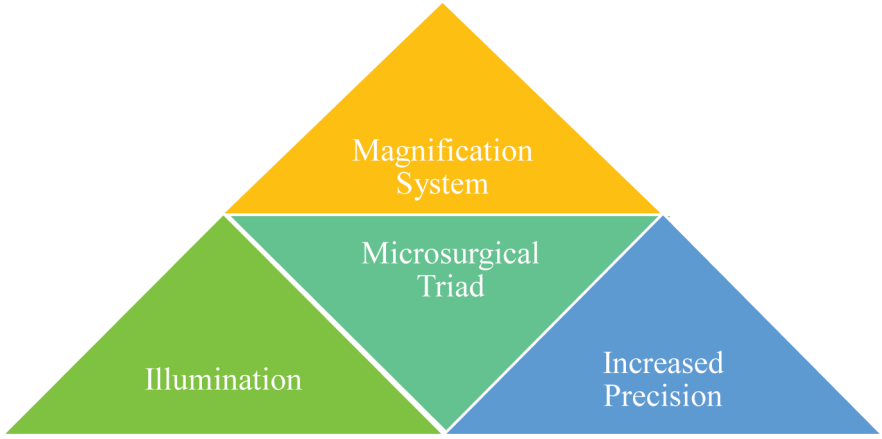

Fig. 1 Microsurgical triad.

Fig. 2 Loupes.

the need and is available as a headband or the front frame-mounted system (►**Fig. 2**).[6]

Types of loupes available[7,8]:

i. Simple Loupes
ii. Compound Loupes
iii. Prism Loupes.
iv. Galilean Loupe

i. Simple Loupes:

These loupes comprise of a pair of single lenses those are attached to two refracting surface side by side.

Advantage:

- It is cost-effective.

Disadvantage:

- Primitive
- This can lead to spherical and chromatic aberration, leading to a distorted image.
- Heavyweight with a magnification range of 1.5x is not particularly applicable in dentistry.

ii. Compound Loupes[9]:

This type of loupes consists of multiple lenses providing auxiliary refracting power. Compound loupes are made comprised of two pieces of glass that are held together with resin.

Advantages:

- Improved magnification
- Larger range and depth of field
- Increased working distance

Disadvantages:

- Antireflective protecting covering required.
- Lack of variable magnification

iii. Prism Loupes:

These are optically advanced loupes currently in use, consisting of a rooftop prism that lengthens the path of light by virtually folding the light. The range of magnification provided by these loupes is 1.5x-6x.[10]

iv. Galilean Loupes[9]:

Advantages:

- Cheap
- Simple to operate
- Lightweight

Disadvantages:

- Limited magnification (2.5x-3.5x)
- Blurry peripheral border

Adjusting Magnifying Loupes

Along with various advantages, it also consists of impediments to adjust to the eye. Therefore, to avoid double vision, the operator has to adjust loupes respective to the eyes. Unadapted position of loupes will converge and dilate to focus and will attempt to accommodate the error. This may cause fatigue to the ciliary and extraocular muscles resulting in eyestrain.

a.2 Microscope (►Fig. 3)

The term microscope was coined by Giovani Faber for the compound microscope. Operating microscopes are superior when compared with loupes. It has been widely used in the medical field but in dentistry, its use was limited to endodontics until microscope in performing plastic periodontal surgery became prevalent. The microscope provides stereoscopic vision with 4x-40x magnification and better illumination of the working area. A surgical microscope consists of a few important components: optical component, supporting structure, a lightning unit, binocular tube, and eyepiece.[11]

Currently, two types of microscopes are widely used: Greenough and Galilean type. Greenough type consists of two side-by-side arranged monocular microscopes at a specific angle so that the two objectives can focus on the same object. Prolonged use of this type of microscope results in eye strain and fatigue. Hence, came the Galilean type microscope that consists of a binocular viewing system in combination with magnifying loupes. Dental microscopes are designed on the Galilean principle that incorporates achromatic lenses and fully coated optics.

Parts of Operating Microscope

a) Supporting Structure

The supporting structures of a microscope are available as the wall or ceiling mounted or even can be safely placed on the floor. A microscope placed on the floor is much preferable as it can be easily moved from one place to other. The operating microscope consists of arms that can be adjusted and angulated with the help of a built-in spring for precise visualization.[12]

b) Eyepiece

The body of the microscope consists of an eyepiece with a magnification of 10x, 12.5, 16x, and 20x. It also consists of a

Fig. 3 Surgical operating microscope.

diopter that can be set from –5 to +5 to focus the lens. Diopter setting and interpupillary adjustment should be made prior to the use by the operator and should remain unchanged.[13]

c) Light Source

Light source is on salient features of an operating microscope, the presence of which helps provides coaxial illumination. Some microscopes can provide illumination to a smaller area, ~6 cm in diameter.[12]

d) Binocular Tube

The microscope provides two different types of binocular tubes: the straight tube that gives a parallel view of direction and inclined tubes that are in 45-degree inclination from the axis of the microscope.

Loupes versus Surgical Operating Microscope (►Fig. 4)

Loupes and microscope despite having many common features also come along with limitations. Loupes provide magnification from 1.5x to 3.5x but magnification where 4x and more is required in particular, loupes are considered to be inefficient and a microscope comes into play with a magnification range from 4x to 40x. Loupes can cause loss of 4% of the transmitted light due to surface reflection and without coating may lead to a 50% reduction in brightness. This problem of light reflection can be minimized by the use of a microscope. In spite of the loupe's usefulness, this high-power instrument also causes discomfort to the clinician due to its heavy weight. This can also influence the posture. The microscope on the other hand is mounted to the different platform does not cause fatigue to the clinician and also ensures good posture throughout the procedure.[14]

Microscope with its higher magnification provides increased precision in surgical skills and extreme accuracy but it also comes with a limitation of restricted vision. It is difficult to carry a microscope from one place to another; therefore, loupes serve better option. Also, a microscope is very expansive in comparison to loupes.[15]

b. Illumination

Illumination plays a major part in the operating field. Selection of an appropriate accessory light source also involves consideration of its quality brightness, focusing ability, and ease of transport between the surgeries.[16] Light focusing quality in the surgical area was improved with the introduction of fiber optic technology. A surgical microscope uses coaxial fiber optic illumination. This fiber optic is capable of producing, uniformly illuminated, bright, free of shadow, a circular spot of light that can be adjusted according to requirement. This technology can be installed in the instrument or the loupes and is now considered a standard feature of a surgical microscope. Halogen lamps have recently been bought in practice.[17]

c. Increased Precision

Microsurgery provides advanced surgical skills, tissue handling ability, proper wound approximation and to attain this level of experience, consistent application of techniques used in basic microsurgery is very important.

a. Hand Control

Physiological tremor is one unintended movement of hands that can occur due to anxiety, lack of practice, or some medical condition. To avoid this microsurgeon must be seated in a comfortable posture, stabilize the hand, and hold

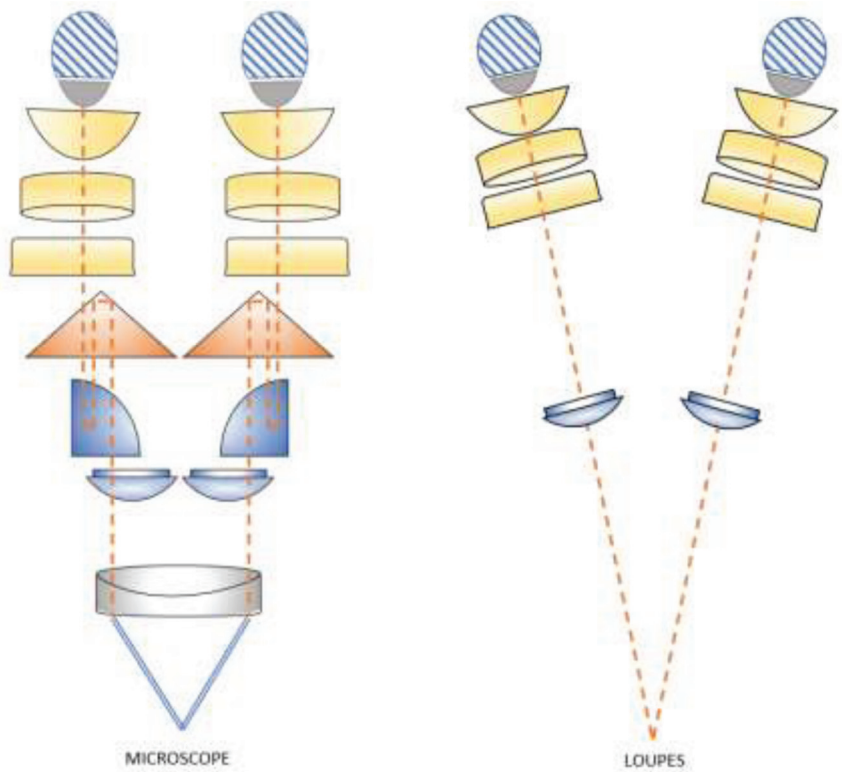

Fig. 4 Microscope versus loupes.

the instrument in a stable position. With the head in a straight upright position, movements of the hand are made purposefully and deliberately.[18] The instrument is held in the form of a pen grip.[19,20] Thumb, index, and middle fingers form a tripod providing a precisional hand grip. The middle finger firmly rests over the ring finger and helps hold the instrument to stabilize any unwanted movement. The intrinsic muscles rotate the hand, while flexor and extensor muscles of the hand are relaxed, which results in accurate movement of the instrument.[21,22] Instrument held in internal precision grip helps in opening and closing of instruments smoothly. Regardless of the correct posture of the clinician, if the handgrip is not correct it can lead to stiffness of the body. Therefore, exact hand movement and the correct hand grip are crucial to achieving precision in microsurgery.

b. Ergonomics in Microsurgery

A proper ergonomics approach will be useful in providing better visual feedback, accuracy in hand movements, handgrip for precision in work, and microsurgical instrument care. The term ergonomics was introduced by K. F. H Murrell in 1965.[23] In 1949, ergonomics research society in England was formed due to the rising interest in equipment design, workplace layout, and environmental conditions.[24]

c. Visual Feedback

Visual information is an important part of ergonomics. Where touch is masked by the presence of gloves and also diluted by instruments, the use of a microscope magnifies the vision 5 to 40 times

A study on most comfortable positioning for dental operating microscope done in 2004 indicated that shorter operators had to adopt a strained position for mandibular observation but become comfortable if using a short objective lens. Between the target structure and the optical lenses, a minimum distance of 18 cm exists.

d. Limb Support

This is one of the important parts of proper ergonomics. The limb support should be closer to the work providing greater control and accuracy in the movement and smaller amplitude of tremor. The limb support along with the forearm decreases the loading weight and aggravation in tremor.[25]

e. Body Posture

Unbalanced and incorrect posture can result in fatigue after a prolonged period of work hours. The microscope should be adjusted in a way so that it can allow vertical alignment of the head and neck without flexion. The level of the forearm should allow adduction of the shoulder and support the trunk.[25]

Armamentarium in Microsurgery

The instrument used in microsurgery is smaller in size compared with the instrument used in conventional surgery. A set of instruments that are being constantly used in periodontal microsurgery are ophthalmic knives, microscissors, microsurgical forceps, micro-needle holders, smaller size needles, fine sutures, microscalpel holders, and elevators.

1. Needles

There is a wide range of needles available for surgery with specific lengths and curvatures. In periodontal microsurgery, the most preferred needles that are bought underuse are reverse cutting or spatula needles with microtips.[26] Needles are now available in different shapes, ranging from straight to curved. To ensure perpendicular penetration in areas with narrow margins like the marginal gingiva and interdental papilla, a curved needle serves as the best option. ⅜ curvature of the needle provides optimum result in most periodontal microsurgery.[27]

2. Knives

Commonly used knives in periodontics are lamellar, crescent, blade breaker, sclera, and spoon knife. Ophthalmic knives being smaller in size, chemically etched, and extremely sharp can provide a precise wound edge in comparison to the no. 15 blade used in conventional surgeries.[28] The crescent knife consists of a unilateral bevel measuring from 2.4 to 3.7mm that is used for intrasulcular incision and root coverage procedures to obtain connective tissue graft from a donor site. The spoon knife is also beveled on one side and is used for effectively undermining the lateral sulcular region in preparation for the placement of connective tissue grafts. Its unbeveled design helps track through the tissue adjacent to the bone. Ophthalmic knives efficiently make sharp incisions leaving sharp wound edges; this results in less trauma and faster wound healing.[29]

3. Suture and Suture Material

Suture material that is made up of natural or artificial fiber is used to keep wound together by approximating the wound margin until they hold them sufficiently well. Silverstein L.H in 1999 said that any strand of material utilized to ligate blood vessels or approximate tissues is called a suture. The goal is to provide adequate tension to the wound closure to avoid dead spaces but not cause ischemia. This allows healing by primary intention and reduces postoperative pain. The ideal suture material is the one with a uniform tensile strength that can hold the wound margin securely with minimal tissue reaction and no cut, tear, or shrinking of the tissue. Penetration of needles causes trauma to the tissue and the presence of foreign material can increase the susceptibility to infection; therefore, the choice of the right suture material is very important.[30]

A suture can be classified as absorbable or nonabsorbable, natural or synthetic; it can also be monofilamentous or multifilamentous. A multifilament thread consists of a high capillarity characteristic; hence, monofilament materials are the most preferable suture material to be used.[31]

Ideally, a small diameter suture should be selected in surgical practice that can hold the mending tissues.[32] In conventional periodontal surgeries, 3–0 to 5–0 sutures are frequently used but for the periodontal microsurgery suture, 6–0 to 9–0 sutures are an ideal choice.[33] Suture materials that are indicated for periodontal surgery are polyglactin 910, poliglecaprone 25, surgical gut, and polydioxanone. According to some studies, poliglecaprone 25 and polyglactin 910 are considered superior to surgical gut sutures,[34,35] where nonabsorbable suture needs removal after a period of time by the surgeon; the absorbable suture has the ability to resorb on its own.

4. Microneedle Holder

A microneedle holder is used to grasp the needle, push and pull it through the tissues, and also helps in tying a knot. It should be held from the distal tips between its middle and lower thirds fingers. To provide high precision, microsurgical instruments are designed to be light-weighted not more than 15 to 20 g to avoid the fatigue of arms and hands, circular in cross-section, and smaller in size with ~18 cm in length.[36] Due to its improved visual acuity, smaller instruments provide more precision than the instrument used in conventional surgeries.[37] The needle holder also consists of a lock with a locking force of 0.5N or 50 g.[36] All microinstruments are color coated to avoid unwanted reflection of light directed from the microscope.[38]

5. Microscissor

Microscissors are 14 to 18 cm in length. This instrument helps in the dissection of tissue tags, blood vessels, and even nerves. A 9 cm long microscissor is preferred for the removal of delicate tissue parts. Microscissor can be either straight or curved depending upon the area or the type of tissue that needs to be managed.

6. Microforceps.

For the handling of the tissue at the time of dissection or during holding of a fine suture and tying a knot, microforceps are considered to be an effective instrument.

Basic Microsurgical Suturing

1. Suture Geometry

Suturing technique used in periodontal microsurgery slightly differs from the one used in conventional surgeries. Needle penetration is perpendicular to the tissue and exits at an equal distance from the margin. To achieve proper wound approximation, the size of the bite is kept 1.5 times the thickness of the tissue.[39] With the help of magnification, the discrepancy that occurs during suturing in microsurgery can be scrutinized. With the help of the above geometric standards of the suturing, a proper coaptation of the wound can be achieved.

2. Knot Tying

After placing suture, with the microsurgical needle holder in the dominant hand and microforceps in the other hand, a knot is tied under the microscope.[37] A preferred knot is a surgeon's knot then comes the square knot. To achieve the integrity of the knot, square knots are used. Well-tied knots will resist the functional loads during mastication and will remain stable resisting loosening of the knot. Excess tying

will not increase the strength of the knot but will only result in excess bulk.[40]

The most commonly used suturing technique in periodontics is interrupted suture, vertical, and horizontal internal/external mattress suture, single-sling and double-sling suture, and continuous locking suture.[41]

Periodontal Implications of Microsurgery

All mucogingival surgical techniques are operator sensitive and have different results to different procedures. The microsurgical principle has its application in many periodontal surgical procedures, resective or regenerative procedures. Magnification when used along with the minimally invasive techniques provides good results.[36]

Application in Scaling and Root Planning

Microscope with its property of higher magnification and illumination helps in accomplishing basic periodontal treatment like scaling and root planning in the critical areas like furcation and with ease.[42] The success of any periodontal therapy depends upon the thoroughness of the debridement of the root surface.[43,44] To achieve a calculus-free surface, sometimes surgical access was required.[45] Fourteen to twenty-four percent of cases treated with surgical access showed less calculus when observed under a stereomicroscope.[46,47] Therefore, all the research done provides enough evidence suggesting that root debridement can be better performed under magnification. Comparative evaluation of scaling and root planning with the use of scanning electron microscopy resulted in more efficiency in removing the calculus than the unaided group.[48] Another study where the evaluation of the effectiveness of scaling and root planning when done using atomic force microscopy and scanning electron microscopy suggested its efficacy. Microanalysis of the root surface identified alteration within cementum when observed under atomic force microscope. Therefore, proving that use of an operating microscope is the best aid in removing debris from the tooth surface.[49]

Application in Root Coverage Procedure

Gingival recession is the apical displacement of the gingival margin, which results in the exposure of the root surface.[50] Root coverage procedure is an integral aspect when there is the need to restore the gingival esthetics. Microsurgery offers a view that can identify minute discrepancies and help treat periodontal problems. Root coverage procedure where class III and class IV marginal surgeries were treated using conventional technique gave better results when performed under magnification. Therefore, the use of microsurgery has made the root coverage procedure that either involves procuring a graft or placement of regenerative material extremely reliable.[51] Reconstruction of gingival tissue is more predictable by the use of gold standard treatment subepithelial connective tissue graft. A systematic review on the effect of magnification on root coverage procedure pointed out that magnification can increase the percentage of root coverage in the root coverage procedure.[52] Use of surgical microscope to enhance the root coverage procedure with subepithelial connective tissue graft demonstrated 98% of root coverage under a microscope, compared with the cases performed by the unaided eye, which was found to be 88.3%. Therefore, both the approaches were good; however, one performed under a surgical microscope provides additional clinical benefits.[53]

Application in Restoring Edentulous Ridge

Restoration of the edentulous ridge is very important when one is planning to place a dental implant in the future. To achieve an adequate vertical height of the edentulous ridge, sufficient soft tissue thickness creation is mandatory. Application of magnification in regenerative therapy permits proper excess and minimal trauma with increased accuracy.[54] A microsurgical approach using guided tissue regeneration on intrabony defects demonstrated closure of interdental spaces in 92.3% along with gain in clinical attachment level, reduction in probing depth, and increase in gingival recession. Therefore, the microsurgical approach in periodontal regeneration provides with high ability of wound closure along with the barrier membrane and gives optimum results.[55]

Minimally Invasive Surgery along with Magnification

Minimally invasive surgery was first introduced by Harrel in 1999.[56] As the name suggests minimally invasive surgery involves a much smaller incision to gain access to the surgical area and debridement of the defect, preserving blood supply in the interdental area when compared with the traditional approach. This is very useful when single or multiple isolated defects have to be treated. In medically compromised patients like a patient suffering from diabetes mellitus, minimally invasive surgery is a boon when it comes to the healing wound.[57] Minimally invasive surgery when combined with the use of magnification has shown better results compared with that done without the use of loupes or a surgical operating microscope. Minimally invasive surgery of prediagnosed type 2 diabetes mellitus under 3x magnification successfully achieved periodontal tissue regeneration approximately at the level in a patient without diabetes mellitus.[58]

Application of Magnification in Implant Surgery

Placement of implant in dentistry is a unique art to restore normal function, contour, esthetics, speech, and health regardless of atrophy, disease, or injury of stomatognathic.[59] Despite its advancement, implant surgery complications are frequently resulting in several poor treatment outcomes. The overall frequency of complication is 13.9% that can occur due to wrong angulation, improper implant location, or can also be due to nerve injury or sinus membrane complication.[60] Therefore, the use of the microscope in all phases of an implant can help recognize the problem and plan a predictable surgery. It can also help in the seating of implant in an anatomically correct position and reduce the surrounding tissue trauma.[61] The success rate of the sinus lift procedure is 97% when performed under a microscope,[62,63] providing indirect visualization of sinus membrane and reducing the

risk of perforation. The altered sensation caused by injury to the nerve can be reduced by the incorporation of a microscope during implant placement.[64]

Macro- or Microsurgery?

One question that arises is whether the difference between macro and microsurgery can be practically useful. In contrast to classic microsurgical procedures, the microsurgical techniques that are used in periodontal treatment meet the requirement of being delicate to provide atraumatic therapy with a precise adaptation of fragile oral mucosa. Since the introduction of the microsurgical approach in reconstructive periodontal therapy in the 1990s, many scientific shreds of evidence have emerged to propose the superiority of the microsurgical approach (►**Table 2**).

Advantages of Use of Microscope in Periodontal Treatment

1. Minimizes the surgical time, reduces patient discomfort
2. Improves incision and approximation of wound by use of suture (6–0 to 9–0) and promotes wound healing
3. Helps in osseous surgery
4. Accurate procuring of graft from the donor site to the suturing of it in the recipient site
5. Availability of high-resolution video and photography for patient education, keeping documentation, and training purposes.[65]

Future of Microsurgery

Recent advancements in the use of microscopes from three-dimensional microsurgery systems to the development of instrumentation, the ease of working, and accuracy in work

Table 2 Studies comparing micro- and microsurgical approach

Year	Researcher	Observation		
			Micro	Macro
2005	Burkhardt and Lang[71]	Fluorescence angiograms were performed to evaluate the degree of vascularization along with other clinical parameters in the subepithelial connective tissue graft procedure for root coverage	After 3 days and 7 days, the vascularization was 53.3 ± 10.5% and 84.8 ± 13.5%, respectively. Percentage of root coverage 99.4 ± 1.7%	Vascularization evaluated was 7.95 ± 1.8%/44.5 5.7% and 64.0 ± 12.3%, respectively Percentage of mean root coverage 90.8 ± 12.1%
2010	Andrade et al[72]	Clinical parameters like percentage of root coverage, the width of keratinized tissue (WKT), and thickness of keratinized tissue (TKT) were evaluated after 6 months of root coverage procedure using coronally repositioned flap and enamel matrix derivative	Percentage of root coverage 92% Statistically significant difference from baseline to 6 months in Mean WKT and TKT 2.23 ± 0.69 and 0.80 ± 0.39 at the baseline and 2.92 ± 0.92 and 1.11 ± 0.32 after 6 months	Percentage of root coverage 83% No statistically significant difference
2011	Bittencourt et al[53]	Comparison of esthetic, postoperative morbidity, and root coverage after subepithelial connective tissue graft (SECT) technique for gingival recession with or without the use of a surgical microscope	The average percentage of root coverage after 12 months 98% Esthetically at the end of the experimental period 24 patients (100%) patient was satisfied with the results of the surgery	Average root coverage 88.3% 19 out of 24 patients (79.1%) were satisfied with the results esthetically
2020	Liao et al[73]	Mechanical and biological properties by analyzing immunofluorescence assay and cell proliferation of root surface after instrumented with and without the use of a microscope	Increased clearance of bacterial deposit and calculi moderate cell morphological changes	Loss of normal surface structure, formation of groove defects was observed. Flattened and shrank cells on the root surface

Abbreviation: Sub-epithelial connective tissue graft (SECT)

have also increased, including the introduction of robotic microsurgery. In 1997, Jacques Himpens and Guy Cardiere performed robotic-assisted surgery that was the first robotic surgery of its time.[61] This bought a drastic change in the use of robotic surgery compatible with modern-day medicine. Robotic microsurgery serves to be a novel adjunctive tool that can provide enhanced magnification along with high-level precision.[66] The use of robotic microsurgery is yet to be introduced in periodontal treatment.

How Can I Learn Microsurgery?

To make use of a microscope in day-to-day procedures, proper training and hands-on programs are being incorporated. The primary focus of teaching should be on developing clinical skills, stabilizing hands to reduce physiologic tremors, subsumed with correct posture. Microsurgery can be taught in brief, well-organized laboratory workshops. It is very important to understand that to make proper use of a microscope in nonsurgical or surgical procedures, continuous practice is very important.

Conclusion

Microsurgery is a skill that can only be achieved by proficiency. The use of microsurgery can be technique sensitive and more demanding than a conventional surgical procedure, yet successfully results in a better outcome and proves to be beneficial. With its challenges in dexterity and perception, it can bring evolution in periodontics. Its advantages in various periodontal nonsurgical and surgical treatment, the improved visual acuity, minimal trauma, uneventful wound healing, and enhanced ergonomics have led to its acceptance by the clinician as well as the patient. Today periodontal microsurgery may be in its infancy stage, but tomorrow it is the future of dentistry.

Conflict of Interest
None declared.

References

1 Mukherjee S, Dasgupta S. Microscope in Dentistry: A Review Article. Microscope 2021;9(02):15–21
2 Rubinstein R. Magnification and illumination in apical surgery. Endod Topics 2005;11:56–77
3 Kriss TC, Kriss VM. History of the operating microscope: from magnifying glass to microneurosurgery. Neurosurgery 1998;42 (04):899–907, discussion 907–908
4 Gutmann JL, Endo C. Historical perspectives on the use of microscopes in dentistry. J Hist Dent 2017;65(01):20–27
5 Tamai S. History of microsurgery. Plast Reconstr Surg 2009;124(6, Suppl):e282–e294
6 Mathew MR, Nishith RK, AB SB, Vanasi M, Shashidhar K. Periodontal Microsurgery—A Review.
7 Christensen GJ. Magnification in dentistry: useful tool or another gimmick? J Am Dent Assoc 2003;134(12):1647–1650
8 Owen ER. Practical microsurgery. I. A choice of optical aids for fine work. Med J Aust 1971;1(05):224–226
9 Mallikarjun SA, Devi PR, Naik AR, Tiwari S. Magnification in dental practice: How useful is it? J Health Res Rev 2015;2(02): 39–44
10 Leonard S, Tibbetts LS, Shanelec DA. Principles and practice of periodontal surgery. Int J Microdent 2009;1:13–24
11 Burkhardt R, Hürzeler MB. Utilization of the surgical microscope for advanced plastic periodontal surgery. Pract Periodontics Aesthet Dent 2000;12(02):171–180, quiz 182
12 Khayat BG. The use of magnification in endodontic therapy: the operating microscope. Pract Periodontics Aesthet Dent 1998;10 (01):137–144
13 Rubinstein R. The anatomy of the surgical operating microscope and operating positions. Dent Clin North Am 1997;41(03): 391–413
14 Christensen GJ. Magnification in dentistry-useful tool or gimmick? J Am Dent Assoc 2003;134:1647–1650
15 Belcher JM. A perspective on periodontal microsurgery. Int J Periodontics Restorative Dent 2001;21(02):191–196
16 Jain R, Kudva P, Kumar R. Periodontal microsurgery-magnifying facts, maximizing results. J. Adv. Med. Dent. Sci. Res. 2014;2(03): 24–34
17 Burkhardt R, Lang NP. Periodontal plastic microsurgery. Jan Lindhe Niklaus P. Lang Thorkild Karring, eds. Periodontology and Implant Dentistry 2008;5:1029-1042.
18 Acland RD, Russell RC. Practice manual for microvascular surgery. Plast Reconstr Surg 1990;85(03):475
19 Barraquer JI. The history of the microscope in ocular surgery. J Microsurg 1980;1(04):288–299
20 Bunke H, Chater N, Szabo Z. The Manual of Microvascular Surgery. San Francisco: Ralph K Daves Medical Center; 1975
21 Klopper P, Muller JH, Van Hattum AH. Microsurgery and Wound Healing. Amsterdam: Experta Medica; 1979
22 Lee S. Manual of Microsurgery. Boca Raton, FL: CRC Press; 1985
23 J. R. DE JONG (1966) A review of: "Ergonomics: Man in his Working Environment". By K. F. H. MURRELL. (London: Chapman & Hall, 1965.) [Pp. xix+496.] 63s., Ergonomics, 9:3, 275.
24 Singleton WT. Introduction to Ergonomics. Geneva: World Health Organization; 1972
25 Patkin M. Ergonomics Applied to the Practice Microsurgery. J Occupat Environ Med 1978;20(05):366.30
26 Thacker JG, Rodeheaver GT, Towler MA, Edlich RF. Surgical needle sharpness. Am J Surg 1989;157(03):334–339
27 Abidin MR, Towler MA, Thacker JG, Nochimson GD, McGregor W, Edlich RF. New atraumatic rounded-edge surgical needle holder jaws. Am J Surg 1989;157(02):241–242
28 Company Brochure. Reading, PA: Surgical Specialties; 1998
29 Wound Closure Manual. Somerville, NJ: Ethicon; 1994:8
30 Österberg B, Blomstedt B. Effect of suture materials on bacterial survival in infected wounds. An experimental study. Acta Chir Scand 1979;145(07):431–434
31 Mouzas GL, Yeadon A. Does the choice of suture material affect the incidence of wound infection? A comparison of dexon (polyglycolic acid) sutures with other commonly used sutures in an accident and emergency department. Br J Surg 1975;62(12): 952–955
32 Wound Closure Manual. Somerville, NJ: Ethicon; 1994:15
33 Gutmann JL, Harrison JW. Surgical Endodontics. Boston: Blackwell Scientific; 1991:278–299
34 LaBagnara J Jr. A review of absorbable suture materials in head & neck surgery and introduction of Monocryl: a new absorbable suture. Ear Nose Throat J 1995;74(06):409–415
35 Anatol TI, Roopchand R, Holder Y, Shing-Hon G. A comparison of the use of plain catgut, skin tapes and polyglactin sutures for skin closure: a prospective clinical trial. J R Coll Surg Edinb 1997;42 (02):124–127
36 Burkhardt R, Lang NP. Periodontal plastic microsurgery. In: Lindhe J, Lang NP, Karring T, eds. Clinical Periodontology and Implant Dentistry. 5th edition. Oxford, USA: Blackwell Munksgaard; 2008:1029–1044
37 Tibbetts LS, Shanelec D. Principles and practice of periodontal microsurgery. Int J Microdent. 2009;1:13–24

38 Yadav VS, Salaria SK, Bhatia A, Yadav R. Periodontal microsurgery: reaching new heights of precision. J Indian Soc Periodontol 2018; 22(01):5–11
39 PRICE PB Ann Surg. Stress, Strain and Sutures. 1948 Sep; 128(03): 408–21
40 Belcher JM. Periodontal microsurgery. In: Dibart S, Karima M, eds. Practical Periodontal Plastic Surgery. Oxford, USA: Blackwell Munksgaard; 2006:15–22
41 Hassan HK. Dental suturing materials and techniques. Global J Oto 2017;12(02):555–833
42 Sitbon Y, Attathom T. Minimal intervention dentistry II: part 6. Microscope and microsurgical techniques in periodontics. Br Dent J 2014;216(09):503–509
43 Lindhe J, Nyman S. Long-term maintenance of patients treated for advanced periodontal disease. J Clin Periodontol 1984;11(08): 504–514
44 Lindhe J, Westfelt E, Nyman S, Socransky SS, Haffajee AD. Long-term effect of surgical/non-surgical treatment of periodontal disease. J Clin Periodontol 1984;11(07):448–458
45 American Academy of Periodontology. 1996 World workshop in periodontics. Review: non-surgical pocket therapy: mechanical. Ann Periodontol 1996;1:469
46 Rabbani GM, Ash MM Jr, Caffesse RG. The effectiveness of subgingival scaling and root planning in calculus removal. J Periodontol 1981;52(03):119–123
47 Fleischer HC, Mellonig JT, Brayer WK, Gray JL, Barnett JD. Scaling and root planning efficacy in multirooted teeth. J Periodontol 1989;60(07):402–409
48 Dadwal A, Kaur R, Jindal V, Jain A, Mahajan A, Goel A. Comparative evaluation of manual scaling and root planning with or without magnification loupes using scanning electron microscope: a pilot study. J Indian Soc Periodontol 2018;22(04):317–321
49 Mohan R, Agrawal S, Gundappa M. Atomic force microscopy and scanning electron microscopy evaluation of efficacy of scaling and root planning using magnification: a randomized controlled clinical study. Contemp Clin Dent 2013;4(03):286–294
50 Kassab MM, Cohen RE. The etiology and prevalence of gingival recession. J Am Dent Assoc 2003;134(02):220–225
51 Tibbetts LS, Shanelec DA. An overview of periodontal microsurgery. Curr Opin Periodontol 1994;•••:187–193
52 Moro MG, Souto ML, Rovai ES, Neto JB, Holzhausen M, Pannuti CM. Effect of magnification on root coverage surgery: a systematic review. Braz J Oral Sci 2020;19:e201669
53 Bittencourt S, Del Peloso Ribeiro E, Sallum EA, Nociti FH Jr, Casati MZ. Surgical microscope may enhance root coverage with subepithelial connective tissue graft: a randomized-controlled clinical trial. J Periodontol 2012;83(06):721–730
54 Cortellini P, Tonetti MS. A minimally invasive surgical technique with an enamel matrix derivative in the regenerative treatment of intra-bony defects: A novel approach to limit morbidity. Journal of clinical periodontology 2007;34(1):87-93.
55 Cortellini P, Tonetti MS. Microsurgical approach to periodontal regeneration. Initial evaluation in a case cohort. J Periodontol 2001;72(04):559–569
56 Harrel SK. A minimally invasive surgical approach for periodontal regeneration: surgical technique and observations. J Periodontol 1999;70(12):1547–1557
57 Gupta P, Jan SM, Behal R, Mir RA, Shafi M, Teli ZA. Periodontal microsurgery: a review. IOSR J Dent Med Sci 2014;13:12–17
58 Mizutani K, Shioyama H, Matsuura T, et al. Periodontal regenerative therapy in patients with type 2 diabetes using minimally invasive surgical technique with enamel matrix derivative under 3-year observation: a prospective cohort study. J Periodontol 2021;92(09):1262–1273
59 Misch CE. Dental Implant Prosthetics. E-book. Amsterdam, Netherlands: Elsevier Health Sciences; 2004 Sep 20
60 Misch K, Wang HL. Implant surgery complications: etiology and treatment. Implant Dent 2008;17(02):159–168
61 Andhare MG, Pratibha SG, Shriniwas VK. Periodontal Microsurgery: A Much-Needed Treatment Aspect in Periodontics. Jounal of research and advancement in dentistry 2020;10:2s:225-232
62 Steiner GG, Steiner DM, Herbias MP, Steiner R. Minimally invasive sinus augmentation. J Oral Implantol 2010;36(04):295–304
63 Engelke W, Schwarzwäller W, Behnsen A, Jacobs HG. Subantroscopic laterobasal sinus floor augmentation (SALSA): an up-to-5-year clinical study. Int J Oral Maxillofac Implants 2003;18(01):135–143
64 Gennaro P, Chisci G, Gabriele G, Iannetti G. Conservative surgical and microsurgical techniques for the management of dental implants that impinge on the inferior alveolar nerve. Br J Oral Maxillofac Surg 2014;52(06):566–568
65 Michaelides PL. Connective-tissue root coverage using microsurgery. Dent Today 1996;15(10):74–79, 76, 78–79
66 Brahmbhatt JV, Gudeloglu A, Liverneaux P, Parekattil SJ. Robotic microsurgery optimization. Arch Plast Surg 2014;41(03):225–230
67 Paddock SW. Confocal laser scanning microscopy. Biotechniques 1999;27(05):992–996, 998–1002, 1004
68 Binnig G, Rohrer H. Scanning tunneling microscopy. Surf Sci 1983; 126:236–244
69 Binnig G, Rohrer H. Scanning tunneling microscopy. Helv Phys Acta 1982;55:726–735
70 Binnig G, Quate CF, Gerber C. Atomic force microscope. Phys Rev Lett 1986;56(09):930–933
71 Burkhardt R, Lang NP. Coverage of localized gingival recessions: comparison of micro- and macrosurgical techniques. J Clin Periodontol 2005;32(03):287–293
72 Andrade PF, Grisi MF, Marcaccini AM, et al. Comparison between micro- and macrosurgical techniques for the treatment of localized gingival recessions using coronally positioned flaps and enamel matrix derivative. J Periodontol 2010;81(11):1572–1579
73 Liao H, Zhang H, Xiang J, Chen G, Cao Z. The effect of the surgical microscope on the outcome of root scaling. Am J Transl Res 2020; 12(11):7199–7210

