



An Intraindividual Comparison of Open versus Paine Retinaculotome Release for Bilateral Carpal Tunnel Syndrome*

Comparação intraindividual dos resultados da liberação aberta ou com retinaculótomo de Paine na síndrome do túnel do carpo bilateral

Carlos Henrique Fernandes¹ Lia Miyamoto Meirelles¹ João Baptista Gomes dos Santos¹
 Marcela Fernandes¹ Luis Renato Nakachima¹ Flavio Faloppa¹

¹ Hand Surgery Unit, Department of Orthopedics and Traumatology, Escola Paulista de Medicina, Federal University of São Paulo, São Paulo, Brazil

Address for correspondence Carlos Henrique Fernandes, MD, PhD, Leoncio de Magalhães Avenue, 1021, São Paulo, Brazil (e-mail: carloshandsurgery@gmail.com).

Rev Bras Ortop 2023;58(2):295–302.

Abstract

The main purpose of this research was to do an intraindividual comparison of outcomes between the open ulnar incision (OUI) and the Paine retinaculotome with palmar incision (PRWPI) techniques in patients with bilateral carpal tunnel syndrome (CTS). The patients underwent OUI surgery on one hand and PRWPI surgery on the contralateral hand. The patients were evaluated with the Boston carpal tunnel questionnaire, visual analogue scale for pain, palmar grip strength, and fingertip, key, and tripod pinch strengths. Both hands were examined in the preoperative and postoperative periods after 2 weeks, 1 month, and 3 and 6 months. Eighteen patients (36 hands) were evaluated. The symptoms severity scale (SSS) scores were higher, in the preoperative period, in the hands that underwent surgery with PRWPI (p -value = 0,023), but lower in the 3rd month postoperative (p -value = 0.030). The functional status scale (FSS) scores were lower in the periods of 2 weeks, 3 months, and 6 months (p -value = 0,016) on the hands that underwent surgery with PRWPI. In a different two-group module study, the PRWPI group presents the SSS scores average on the 2nd week and 1st month, and the FSS scores average on the 2nd week, less 0.8 and 1.2 points respectively compared to open group. The hands that underwent surgery with PRWPI presented significantly lower SSS scores at 3 months postoperative, and lower FSS scores at 2 weeks, and 3 and 6 months postoperative, compared to open surgery group.

Keywords

- ▶ carpal tunnel syndrome/surgery
- ▶ surveys and questionnaires
- ▶ median nerve

* This study was performed at the São Paulo Hospital, Federal University of São Paulo, São Paulo, SP, Brazil.

received
August 3, 2021

accepted
January 31, 2022

article published online
May 16, 2022

DOI <https://doi.org/10.1055/s-0042-1744497>.
ISSN 0102-3616.

© 2022. Sociedade Brasileira de Ortopedia e Traumatologia. All rights reserved.

This is an open access article published by Thieme under the terms of the Creative Commons Attribution-NonDerivative-NonCommercial-License, permitting copying and reproduction so long as the original work is given appropriate credit. Contents may not be used for commercial purposes, or adapted, remixed, transformed or built upon. (<https://creativecommons.org/licenses/by-nc-nd/4.0/>)

Thieme Revinter Publicações Ltda., Rua do Matoso 170, Rio de Janeiro, RJ, CEP 20270-135, Brazil

Resumo

O principal objetivo desta pesquisa foi fazer uma comparação intraindividual dos resultados entre as técnicas de incisão ulnar aberta e retinaculótomo de Paine com incisão palmar em pacientes com síndrome do túnel do carpo (STC) bilateral. Os pacientes foram submetidos à cirurgia aberta em uma mão e cirurgia com retinaculótomo de Paine na mão contralateral. Os pacientes foram avaliados com o *Boston carpal tunnel questionnaire*, escala visual analógica para dor e força de preensão palmar, pinça lateral, pinça polpa-polpa e tripode. As duas mãos foram examinadas antes da cirurgia e 2 semanas, 1 mês, 3 e 6 meses após a cirurgia. Dezoito pacientes (36 mãos) foram avaliados. As pontuações da escala de gravidade dos sintomas (EGS) foram maiores no pré-operatório nas mãos submetidas à cirurgia com retinaculótomo de Paine ($p = 0,023$), mas menores no 3º mês após o procedimento ($p = 0,030$). As pontuações da escala de estado funcional (EEF) foram menores às 2 semanas, 3 meses e 6 meses ($p = 0,016$) nas mãos submetidas à cirurgia com retinaculótomo de Paine. Em um estudo de módulo de diferença de dois grupos, o grupo submetido à cirurgia com retinaculótomo de Paine apresentou pontuações médias de EGS na 2ª semana e 1º mês e de EEF na segunda semana inferiores a 0,8 e 1,2 pontos, respectivamente, em comparação ao grupo submetido ao procedimento aberto. As mãos submetidas à cirurgia com retinaculótomo de Paine apresentaram escores significativamente menores de EGS em 3 meses e de EEF em 2 semanas, e aos 3 e 6 meses após a cirurgia em comparação a técnica aberta.

Palavras-chave

- ▶ síndrome do túnel do carpo/cirurgia
- ▶ inquéritos e questionários
- ▶ nervo mediano

Introduction

A large number of prospective and randomized studies have been performed in recent years comparing the results of open and endoscopic surgical treatments.¹ The major disadvantage of endoscopic treatment for carpal tunnel syndrome (CTS) is the high cost of the equipment and blades.² The Paine retinaculotome through a palmar approach is an effective and low-cost alternative.³ Median nerve decompression using the Paine retinaculotome has been shown to effectively cause remission of symptoms in the long-term, with a low rate of postoperative pain.³ Few studies have been performed comparing the results of the release of open surgery and retinaculotome instrument-assisted surgery of carpal tunnel.⁴ The palmar ulnar incision for decompression of the carpal tunnel was described by Tubiana. Its advantages include avoiding injury to the palmar cutaneous branch, avoiding a scar over the topography of the median nerve, and consequently avoiding adhesion on the median nerve.⁵

The evaluation of patients who have undergone bilateral surgical treatment with different techniques for each hand has the advantage of the patient being their own internal control.⁶⁻⁸

The main purpose of this research was to do an intraindividual comparison of outcomes between open ulnar incision and Paine retinaculotome with palmar incision in patients with bilateral CTS.

Material and Methods

The present study had approval of the institution's ethics and research committee. It is a cross-cut longitudinal study. The

data collection period was from December 2017 to December 2018.

The diagnosis of bilateral idiopathic CTS was made when the patient presented, on both hands, at least three of the six diagnostic criteria recommended by the American Academy of Orthopedic Surgeons.⁹ The patients were submitted to an electric study for confirmation of CTS diagnostic. If symptoms did not improve with non-surgical treatment, the patients were submitted to a carpal tunnel release. Electrophysiological studies were not done in the postoperative period, the outcomes were evaluated regarding the clinical improvement.

In the intraindividual evaluation, patients were submitted to and evaluated the two surgical techniques—the one tested (Paine retinaculotome) on one hand, and the standard (open) on another. For this reason, the number of hands operated by the two different surgical techniques were the same. Patients were informed about participation in the study. After completing the preoperative evaluations, patients were asked which hand they would like to have operated first. The most symptomatic hand was the first hand to be submitted to surgery; consequently, the other surgical technique would be used on the contralateral hand. The two surgical techniques, remission rates of symptoms, and complications were explained to the patients, and, therefore, they would undergo surgical procedures by different techniques in each hand. Based on the information, the patients had the choice of the surgical technique to be used in the first surgery. The surgical procedures for each hand occurred in different periods of time, so there were no simultaneous bilateral surgeries. The exclusion criteria included previous carpal tunnel release,

inflammatory diseases, and patients who did not desire to participate in the research.

With this experimental design, it was not possible to blind either the patients or assessors to the type of surgery performed in each hand. In an attempt to avoid the bias of the preference by the surgeons for one of the surgical techniques, all evaluations were performed by a hand therapist (L. M. M.).

The patients were evaluated by one of the authors (L. M. M.) in the preoperative period and on 2 weeks, 1, 3, and 6 months after surgery for each hand. The assessment included measurements with the visual analogue scale (VAS) for pain; palmar and pinch strengths; symptom severity scores (SSS); and the functional status scores (FSS) of the Boston carpal tunnel questionnaire (BCTQ). Regarding bilateral symptoms, as done in previous research, the patients filled out two questionnaires, one for each hand, and were instructed to answer the questions always in relation to the symptoms and disabilities of each side.¹⁰

The surgical procedures were performed by orthopedic residents or hand fellows under direct supervision of a senior hand surgeon.

Paine Retinaculotome with Palmar Incision

A 1.5-cm longitudinal straight incision was performed, 0.5 cm proximally from the medial palmar crease, along the radial border of the ring finger (→Fig. 1). The Paine retinaculotome (→Fig. 2) was placed, with its base protecting the median nerve and the blade in contact with the trans-

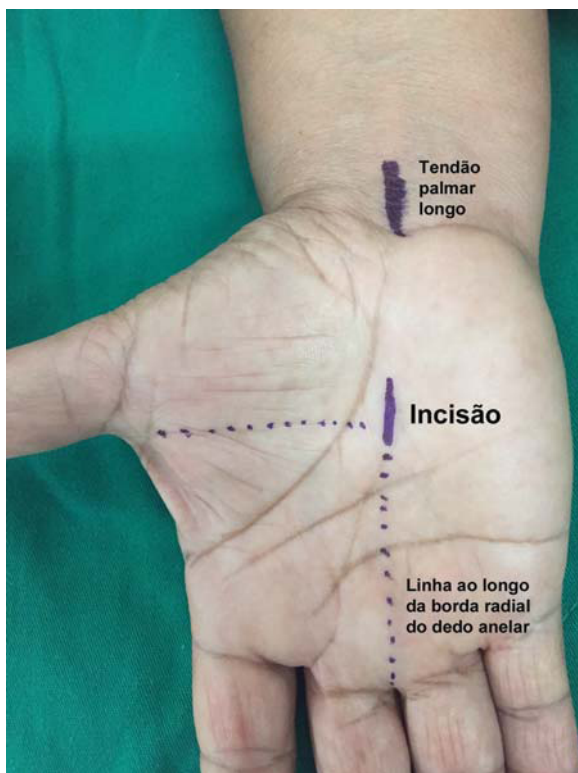


Fig. 1 A 1.5 cm longitudinal straight incision was performed, 0.5 cm proximally from the medial palmar crease, along the radial border of the ring finger.

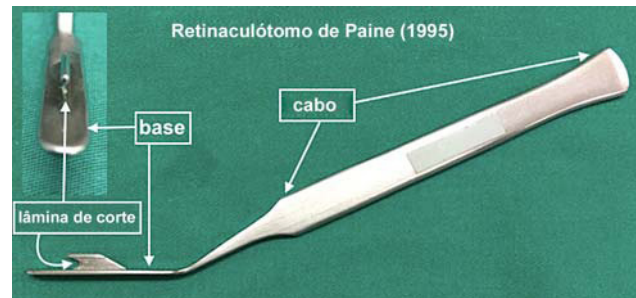


Fig. 2 Paine retinaculotome.

verse carpal ligament (TCL) to divide the ligament. If there was an incomplete release, a second passage was done.

Open Surgery with Palmar Ulnar Incision

A longitudinal incision of ~ 4 cm starting at the palmar crease of the wrist and accompanying the outer border of the hypothenar eminence was made (→Fig. 3). The carpal tunnel ligament (CTL) was divided at the level of its insertion on the pisiform. The distal antebrachial ventral fascia was sectioned longitudinally with blunt scissors under direct vision to avoid an incomplete decompression.

Statistical Methods

The samples' power (power and sample size) was calculated based on the scores of the techniques in the preoperative moment (→Table S1–Supplementary material, available online only). Possible differences between surgical techniques were evaluated by analysis of variance for repeated measurements. The timing of evaluations was considered to be a factor between groups, since the variables were measured at 5 different time periods (preoperative, 2 weeks, 1 month, 3 months, and 6 months postoperative). The objective of this work is to compare the two techniques in all five collection periods, for both the SSS and the FSS. As the data are paired, that is, the same individual is researching and controlling oneself, we used the Wilcoxon test.

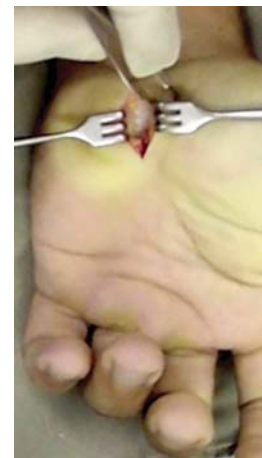

Fig. 3 A palmar ulnar incision of approximately 4 cm to perform the open release.

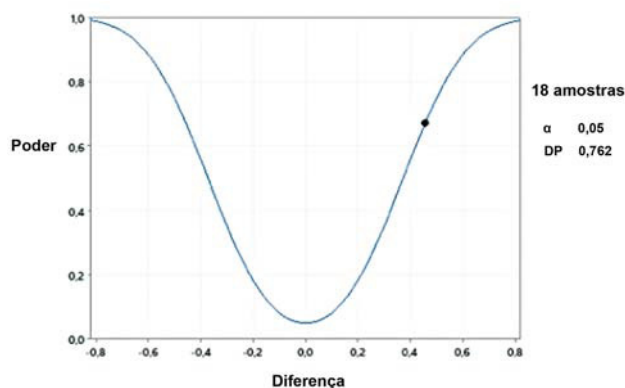
Table 1 Patients gender, age, and their choices regarding the side and technique for the first surgery

Patients	Gender	Age	Side	Surgical technique
1	Female	60	Rigth	Open
2	Female	50	Left	Retinaculotome
3	Female	68	Left	Open
4	Male	82	Left	Retinaculotome
5	Female	43	Rigth	Open
6	Male	47	Left	Open
7	Female	43	Left	Retinaculotome
8	Female	63	Rigth	Open
9	Female	56	Left	Open
10	Female	60	Rigth	Retinaculotome
11	Female	36	Rigth	Retinaculotome
12	Female	62	Rigth	Retinaculotome
13	Female	52	Left	Retinaculotome
14	Female	58	Left	Open
15	Female	40	Left	Retinaculotome
16	Female	55	Left	Retinaculotome
17	Male	56	Left	Open
18	Female	35	Rigth	Open

Results

Eighteen patients were diagnosed with bilateral CTS, and 36 hands were submitted to surgery in total. As for the first surgery, 11 subjects chose the left hand, while 7 subjects chose the right hand, and as for their first surgery, 9 subjects underwent open surgery with palmar ulnar incision, while 9 subjects underwent the Paine retinaculotome with palmar incision (► **Table 1**). The mean time interval between the 1st procedure and the contralateral procedure were 10 to 11 months.

The sample has a power of 0.671 (67.1%) with a 95% statistical confidence. This is a good result in view of the

**Graph 1** Sample power curve.

sample size of 18 cases. The power curve was included as **Graph 1**.

There were no statistically significant differences between the two surgical techniques, at any of the times evaluated, regarding scores of palmar grip, fingertip, key, and tripod strengths (► **Table 2**).

Comparing the pain scores evaluated by the VAS, there were no statistically significant differences between the two surgical techniques at any of the times evaluated (► **Table 3**).

Regarding the SSS scores, there were statistically significant differences between the two surgical techniques in the preoperative time; the group of hands submitted to the Paine retinaculotome with palmar incision technique showed a statistically significant higher average score (p -value = 0.023). The scores also showed differences in postoperative time; the hands submitted Paine retinaculotome with palmar incision presented significantly less scores at 3 months postoperative (► **Table 4**). Regarding the FSS, there were no statistically significant differences between the two surgical techniques in the preoperative time. However, the Paine retinaculotome with palmar incision produced significantly lower average functionality scores than the Paine retinaculotome technique at 2 weeks, and 3 and 6 postoperative (► **Table 5**).

For calculation of the minimal clinically important difference (MCID), the difference in module, between the techniques, and at each moment was calculated, and, thus, we performed a descriptive analysis with a 95% confidence interval for (► **Table 6**).

Discussion

Numbness and tingling may appear sporadically in the population, without necessarily indicating a diagnosis of CTS.¹¹ Some authors reported that when there are clear clinical evidences of CTS, a hand surgeon can diagnose CTS accurately without electrodiagnostic studies,^{12,13} and others describe an exaggerated value of the findings of complementary tests more than the clinical symptoms reported by patients.^{14,15} Sometimes, in clinical practice, patients report more intense symptoms in the hand that presents less intense compression in electrical studies. The findings of the Hangeman et al.¹⁶ study suggest that surgeons prefer to offer peripheral nerve decompression to patients with abnormal electrophysiology. In our study, all patients had electric studies for STC diagnosis confirmation.

Padua et al.,¹⁷ in the follow-up of patients with unilateral CTS, showed that contralateral symptoms developed in most cases, and they found a significant positive correlation of bilateral CTS with the duration of symptoms, whereas there was no correlation with the severity of symptoms. We believe that the reason of patients' appointment was the severity of the symptoms. Although it can be considered a bias of randomization, in our study, it was the patient's choice that the more symptomatic hand was operated first. We did not perform surgery on both hands at the same time. In general, the patient needs one free hand able to carry out daily living activities, especially personal hygiene. For mild

Table 2 Measures of palmar grip strength, fingertip, key, and tripod (in Kg) in relation to the surgical technique and moment of evaluation. Mean values and standard deviation in brackets

Moment	Palmar grip		Fingertip		Key		Tripod	
	Open	Retinaculotome	Open	Retinaculotome	Open	Retinaculotome	Open	Retinaculotome
Preoperative	19.42 (SD 7.93)	21.00 (SD 9.25)	4.47 (SD 1.93)	3.89 (SD 1.62)	6.53 (SD 2.35)	6.42 (SD 2.55)	5.61 (SD 2.40)	5.17 (SD 2.39)
2nd week	8.67 (SD 6.02) ^a	10.13 (SD 6.61) ^a	3.11 (SD 1.53) ^a	3.27 (SD 1.41) ^a	3.73 (SD 1.74) ^a	4.20 (SD 1.99) ^a	3.40 (SD 1.59) ^a	3.87 (SD 1.55) ^a
1st month	14.29 (SD 6.88) ^b	18.82 (SD 5.48) ^b	3.65 (SD 1.68) ^a	3.53 (SD 1.41) ^a	5.29 (SD 2.40) ^a	4.71 (SD 2.08) ^a	4.18 (SD 1.81) ^a	3.59 (SD 1.11) ^a
3rd month	16.62 (SD 6.93) ^b	18.38 (SD 5.57) ^b	4.14 (SD 1.83) ^{b,c}	4.38 (SD 1.72) ^{b,c}	5.74 (SD 2.44) ^{b,c}	6.06 (SD 1.77) ^{b,c}	4.68 (SD 2.16) ^{b,c}	4.79 (SD 1.60) ^{b,c}
6th month	20.11 (SD 5.80) ^b	19.66 (SD 5.55) ^b	5.50 (SD 3.14) ^{a,b,c,d}	4.88 (SD 2.16) ^{a,b,c,d}	7.19 (SD 3.49) ^{a,b,c,d}	6.63 (SD 1.85) ^{a,b,c,d}	6.11 (SD 2.97) ^{b,c}	5.34 (SD 2.61) ^{b,c}

Abbreviation: SD, standard deviation.
^aStatistical difference from preop ($p < 0.05$).
^bStatistical difference from the 2nd week ($p < 0.05$).
^cStatistical difference from 1st month ($p < 0.05$).
^dStatistical difference from 3rd month ($p < 0.05$).

Table 3 Measures of visual analog pain scale in relation to surgical technique and moment of evaluation. Mean values and standard deviation in brackets

Moment	Open	Retinaculotome
Preoperative	6.39 (SD 2.89)	7.72 (SD 2.78)
2nd week	4.29 (SD 3.02) ^a	3.43 (SD 3.01) ^a
1st month	3.69 (SD 3.30) ^a	2.63 (SD 3.20) ^a
3rd month	2.29 (SD 3.02) ^{a,b}	1.76 (SD 2.61) ^{a,b}
6th month	1.94 (SD 2.86) ^{a,b}	1.44 (SD 2.71) ^{a,b}

Abbreviation: SD, standard deviation.
^aRepresents statistical difference from preop ($p < 0.05$);
^bstatistical difference from the 2nd week and 1st month ($p < 0.05$).

conditions, temporarily contralateral symptom improvement is common after unilateral surgery. We just indicate surgery for the contralateral hand when the clinical symptoms return.

The sample size of our study is smaller than most randomized clinical trials evaluating unilateral surgery, but it is similar in size to those who conduct bilateral surgery with different techniques.¹⁸ The main reason for this small sample size was due to the difficulty in convincing patients to undergo different surgical techniques for each hand.

Patients with CTS have more decisional conflict than hand surgeons. One of the factors associated with greater decision conflict in CTS patients was less confidence that they would achieve their goals. It is possible to help empowering patients by providing information about their options and by helping them understand their values and preferences.¹⁶ In our research, after detailed information, the patients took the decision and chose the first surgical technique.

Pain is defined as an unpleasant sensory and emotional experience associated with, or similar to that associated with, actual or potential tissue damage that is genuinely personal and subjective; different persons may respond differently to the same stimulus.¹⁹ This subjectivity can also be extended to the perceived intensity of symptoms. To reduce this subjectivity, we have used the intraindividual comparison. In our study, each patient underwent bilateral surgical treatment for CTS using a different surgical technique for each hand and were evaluated pre and postoperatively. Obviously, such a comparison is limited in clinical research and difficult to apply. Doing an intraindividual comparison between open and endoscopic techniques, Fernandes et al. evaluated 15 patients (30 hands) and did not observe differences between open and endoscopic surgery when assessed by the SSS, FSS, VAS, and palmar and digital grip strength results.⁸

Surgical carpal tunnel treatment results are commonly evaluated by pain intensity, sensitivity assessment, grip strength, SSS and FSS scores, complication rates, and the time it takes to return to work.^{20,21}

An evaluation of the BCTQ items independently shows that the highest scores regarding the severity of the symptoms are related to residual symptoms, and that the highest

Table 4 Measurements of the Boston carpal tunnel questionnaire score for severity of symptoms in relation to a surgical technique and time of evaluation. Mean values and standard deviation in brackets

Moment	Open	Retinaculotome	P-values
Preoperative	37.11 (SD 8.38)	41.33 (SD 8.15)*	*statistically different from open ($p < 0.05$)
2nd week	22.57 (SD 9.61)	18.36 (SD 8.12)*	*statistically different from open ($p < 0.05$)
1st month	21.81 (SD 11.57)	16.38 (SD 4.99)	
3rd month	18.47 (SD 8.49)	15.12(SD 7.51)*	*statistically different from open ($p < 0.05$)
6th month	18.13 (SD 10.93)	14.87 (SD 7.82)	

Abbreviation: SD, standard deviation.

Table 5 Measurements of the Boston carpal tunnel questionnaire score for functional status of the hand in relation to a surgical technique and time of evaluation. Mean values and standard deviation in brackets and 95%

Moment	Open	Retinaculotome	P-value
Preoperative	24.67 (SD 9.15)	26.00 (SD 7.21)	
2nd week	24.21 (SD 10.89)	18.71 (SD 7.94)*	*statistically different from open ($p < 0.05$)
1st month	19.31 (SD 7.98)	15.31 (SD 5.19)	
3rd month	16.29 (SD 9.06)	13.24 (SD 7.67)*	*statistically different from open ($p < 0.05$)
6th month	13.87 (SD 7.46)	10.80 (SD 5.31)*	*statistically different from open ($p < 0.05$)

Abbreviation: SD, standard deviation.

Table 6 The difference in module of symptom severity scores and functional status scores, between the surgical techniques, at each moment

	SSS			FSS		
	Mean	Standard deviation	CI	Mean	Standard deviation	CI
Preoperative	0.565	0.434	0.200	0.542	0.452	0.209
2nd week	0.842	0.851	0.431	1.108	1.252	0.633
1st month	0.885	0.888	0.449	0.882	0.907	0.431
3rd month	0.422	0.415	0.197	0.559	0.500	0.238
6th month	0.455	0.537	0.272	0.467	0.512	0.259

Abbreviations: CI, confidence interval; FSS, functional status score; SSS, symptom severity score.

scores regarding functional status are related to disabilities; thus, the higher the score, the greater the symptom severity and degree of disability.¹⁰

Minimal clinically important difference (MCID) is the smallest difference in the score of an outcome instrument that patients perceive as important. Kim et al. found that, after 3 months of surgery, a 1.14-point change in the SSS scale and a 0.74-point change in the FSS scale indicated a clinically relevant threshold of satisfaction.²² Ozyüreköglu et al.²³ calculated that the MCID in the score of the SSS after carpal tunnel steroid injection was found to be 1.04. Ozer et al.,²⁴ in non-diabetic's patients, found an MCID of 0.8 and 1.6 points at 3 and 6 months, respectively, were identified for SSS; and an MCID of 1.25 points at 3 months and 1.45 points at 6 months were identified for FSS. De Kleermaeker et al.²⁵ believe there is no consensus about the minimal clinically important difference for the Boston carpal tunnel questionnaire and that the MCID should be individually calculated from baseline SSS and FSS scores, as

patients experiencing more symptoms require more improvement to notice a clinically important difference. Schrier et al.²⁶ studied the MCID in patients undergoing unilateral carpal tunnel release and found the optimal relative MCID for injection patients was indeed lower than that of the surgical group, at 0.30, which was associated with a sensitivity of 85%, and a specificity of 77%. In our study, we calculated the difference in module; the average SSS scores of the Retinaculotome patients' group were lower than 0.8 points in the 2nd week and 1st month after the surgery, and the average FSS scores of the Retinaculotome patients' group were lower than 1.2 points in the 2nd week.

Many times, in surgical trials, the intervention performed by a surgeon is not necessarily identical to that performed by another surgeon. That is, no matter how reproducible the technique is, it is not identical. Surgical techniques depend on a learning curve, a curve that can vary for each technique and for each surgeon. It is one of reasons that outcomes of a

same surgical technique cannot be the same when performed by different surgeons. This does not imply methodological failures or a chance effect, but it happens because the interventions are not the same.²⁷ In our research, the surgical procedures were performed by residents and fellows under supervision of one of the seniors' authors.

Most patients have a good result with open carpal tunnel decompression, but there is a small incidence of unsatisfactory outcomes, usually relating to tenderness of the scar or pillar pain.²⁸ The mechanism of pillar pain is not clear, but it may result from small neuromas as a result of incision in the interthenar space. Despite the advantage of the ulnar incision, it is performed in the interthenar space.

We believe there is a lack of randomized clinical studies comparing open surgery with Paine retinaculotome. The Paine retinaculotome was described to be used through a wrist incision to cut the CTL as the instrument passes into the palm. Paine and Polyzoids²⁹ described 90% of patients achieved very satisfactory results. The most common reason for failure was incomplete division of the distal portion of CTL. Pignataro et al.³⁰ studied the use of Paine retinaculotome by palmar incision in cadavers and obtained tunnel decompression on all hands with no vascular or nerve injury.

Previous studies with Paine retinaculotome have demonstrated excellent clinical outcomes^{3,20} that were kept under evaluation at least 86 months after surgery.³

Conclusion

Considering the subjectivity of the Boston carpal tunnel questionnaire scores, the hands which were submitted to surgery with Paine retinaculotome with palmar incision presented significantly lower SSS scores at 3 months of postoperative, and lower FSS scores at 2 weeks, and 3 and 6 months postoperative. In a difference module study, the Paine retinaculotome group presented SSS scores average on the 2nd week and 1st month, and the FSS scores average on the 2nd week, lower than 0.8 and 1.2 points, respectively, compared to the group submitted to open surgery.

Financial Support

The present research received no specific grant from any funding agency in the public, commercial, or not-for-profit sectors.

Conflito de Interesse

Os autores declararam não haver potenciais conflitos de interesse em relação à pesquisa, autoria e/ou publicação deste artigo.

Referências

- Sayegh ET, Strauch RJ. Open versus endoscopic carpal tunnel release: a meta-analysis of randomized controlled trials. *Clin Orthop Relat Res* 2015;473(03):1120–1132
- Saw NL, Jones S, Shepstone L, Meyer M, Chapman PG, Logan AM. Early outcome and cost-effectiveness of endoscopic versus open carpal tunnel release: a randomized prospective trial. *J Hand Surg Br* 2003;28(05):444–449
- Fernandes CH, Nakachima LR, Hirakawa CK, Gomes Dos Santos JB, Faloppa F. Carpal tunnel release using the Paine retinaculotome inserted through a palmar incision. *Hand (N Y)* 2014;9(01):48–51
- Yücetaş SC, Yildirim A. Comparative results of standard open and mini open, KnifeLight instrument-assisted carpal tunnel release. *J Neurol Surg A Cent Eur Neurosurg* 2013;74(06):393–399
- Galbiatti J, Komatsu S, Faloppa F, Albertoni WM, Silva SEA. Via de acesso ulnar na síndrome do túnel do carpo. *Rev Bras Ortop* 1981;26(11/12):389–394
- Rab M, Grünbeck M, Beck H, et al. Intra-individual comparison between open and 2-portal endoscopic release in clinically matched bilateral carpal syndrome. *J Plast Reconstr Aesthet Surg* 2006;59(07):730–736
- Michelotti B, Romanowsky D, Hauck RM. Prospective, randomized evaluation of endoscopic versus open carpal tunnel release in bilateral carpal tunnel syndrome: an interim analysis. *Ann Plast Surg* 2014;73(Suppl 2):S157–S160
- Fernandes CH, Meirelles LM, Fernandes M, Nakachima LR, Santos JBGD, Faloppa F. Intra-individual evaluation of results between open and endoscopic release in bilateral carpal tunnel syndrome. *Rev Bras Ortop* 2018;53(06):696–702
- Keith MW, Masear V, Chung KC, et al. American Academy of Orthopaedic Surgeons Clinical Practice Guideline on diagnosis of carpal tunnel syndrome. *J Bone Joint Surg Am* 2009;91(10):2478–2479
- Okamura A, Meirelles LM, Fernandes CH, Raduan Neto J, Dos Santos JB, Faloppa F. Evaluation of patients with carpal tunnel syndrome treated by endoscopic technique. *Acta Ortop Bras* 2014;22(01):29–33
- Atroshi I, Gummesson C, Johnsson R, Ornstein E, Ranstam J, Rosén I. Prevalence of carpal tunnel syndrome in a general population. *JAMA* 1999;282(02):153–158
- D'Auria JL, Montanez A, Toirac A, Goitz RJ, Fowler JR. Accuracy of Surgeon Diagnosis in Predicting Carpal Tunnel Syndrome. *Hand (N Y)* 2021;16(02):179–182
- Fernandes CH, Moreira SR, Miyamoto Meirelles L, Gomes Dos Santos JB, Faloppa F, Albertoni WM. Linburg-Comstock anomaly: A comparison of the prevalence in women with and without clinical carpal tunnel syndrome. *Hand Surg Rehabil* 2021;40(01):64–68
- Meirelles LM, Fernandes CH, Ejnisman B, Cohen M, Gomes Dos Santos JB, Albertoni WM. The prevalence of carpal tunnel syndrome in adapted Sports athletes based on clinical diagnostic. *Orthop Traumatol Surg Res* 2020;106(04):751–756
- Meirelles LM, Fernandes CH, Ejnisman B, Cohen M, Dos Santos JBG, Faloppa F. Changing Concepts for the Diagnosis of Carpal Tunnel Syndrome in Powerlifting Athletes with Disabilities. *Rev Bras Ortop (Sao Paulo)* 2020;55(06):755–758
- Hageman MG, Bossen JK, Neuhaus V, Mudgal CS, Ring DScience of Variation Group. Assessment of Decisional Conflict about the Treatment of carpal tunnel syndrome, Comparing Patients and Physicians. *Arch Bone Jt Surg* 2016;4(02):150–155
- Padua L, Padua R, Nazzaro M, Tonali P. Incidence of bilateral symptoms in carpal tunnel syndrome. *J Hand Surg [Br]* 1998;23(05):603–606
- Hu K, Zhang T, Xu W. Intraindividual comparison between open and endoscopic release in bilateral carpal tunnel syndrome: a meta-analysis of randomized controlled trials. *Brain Behav* 2016;6(03):e00439
- Tursky B, Jamner LD, Friedman R. The pain perception profile: A psychophysical approach to the assessment of pain report. *Behav Ther* 1982;13:376–394
- Meirelles LM, dos Santos JBG, dos Santos LL, et al. Evaluation of Boston Questionnaire applied at late postoperative period of carpal tunnel syndrome operated with the Paine retinaculotome through palmar port. *Acta Ortop Bras* 2006;14:126–132
- Fernandes CH, Lopes EJ, Meirelles LM, dos Santos JBG, Faloppa F, Albertoni WM. Carpal tunnel release surgery in patients with and

- without Limburg-Comstock anomaly. *Hand Surg Rehab* 2021;40(06):777-781
- 22 Kim JK, Jeon SH. Minimal clinically important differences in the Carpal Tunnel Questionnaire after carpal tunnel release. *J Hand Surg Eur Vol* 2013;38(01):75-79
 - 23 Ozyüreköglü T, McCabe SJ, Goldsmith LJ, LaJoie AS. The minimal clinically important difference of the Carpal Tunnel Syndrome Symptom Severity Scale. *J Hand Surg Am* 2006;31(05):733-738, discussion 739-740
 - 24 Ozer K, Malay S, Toker S, Chung KC. Minimal clinically important difference of carpal tunnel release in diabetic and nondiabetic patients. *Plast Reconstr Surg* 2013;131(06):1279-1285
 - 25 De Kleermaeker FGCM, Boogaarts HD, Meulstee J, Verhagen WIM. Minimal clinically important difference for the Boston Carpal Tunnel Questionnaire: new insights and review of literature. *J Hand Surg Eur Vol* 2019;44(03):283-289
 - 26 Schrier VJ, Gelfman R, Amadio PC. Minimal clinically important difference is lower for carpal tunnel syndrome patients undergoing injection versus surgery. *J Hand Surg Eur Vol* 2020;45(01):90-92
 - 27 Demange MK, Fregni F. Limits to clinical trials in surgical areas. *Clinics (São Paulo)* 2011;66(01):159-161
 - 28 Nancollas MP, Peimer CA, Wheeler DR, Sherwin FS. Long-term results of carpal tunnel release. *J Hand Surg Br* 1995;20(04):470-474
 - 29 Paine KW, Polyzoidis KS. Carpal tunnel syndrome. Decompression using the Paine retinaculotome. *J Neurosurg* 1983;59(06):1031-1036
 - 30 Pignataro MB, Ruschel PH, Folberg CR, Carneiro RS. Técnica de liberação do túnel do carpo com minincisão palmar e uso do retinaculótomo: estudo em cadáveres. *Rev Bras Ortop* 1998;33(03):190-194