Article published online: 2022-05-29

Transmitral Septal Myectomy and Mitral Valve Surgery via Right Mini-Thoracotomy

Ali El-Sayed Ahmad[1] Saad Salamate[1] Sabrina Giammarino[1] Veceslav Ciobanu[2] Farhad Bakhtiary[1]

[1] Division of Thoracic and Cardiovascular Surgery, HELIOS Klinikum Siegburg, Siegburg, Germany
[2] Division of Thoracic and Cardiovascular Surgery, HELIOS Universitätsklinikum Wuppertal, Siegburg, Germany

Address for correspondence Ali El-Sayed Ahmad, MD, PhD, Division of Thoracic and Cardiovascular Surgery, HELIOS Klinikum Siegburg, Ringstr. 49, Siegburg 53721, Germany (e-mail: ali.assayed@gmail.com).

Thorac Cardiovasc Surg 2023;71:171–177.

Abstract

Background Transmitral myectomy for symptomatic hypertrophic obstructive cardiomyopathy is possible with existence of substantial mitral valve disease. We present herein our experience of minimally invasive transmitral septal myectomy combined with mitral valve surgery through right anterior mini-thoracotomy in the past 4 years at our institution.

Methods Between March 2017 and October 2020, 14 patients with hypertrophic obstructive cardiomyopathy and mitral valve disease required minimally invasive transmitral septal myectomy combined with mitral valve reconstruction or replacement at our institution. Mean age of patients was 54.2 ± 11.4 and 42.9% ($n = 6$) were female. Twelve patients (85.1%) were in New York Heart Association class III to IV and 6 patients (42.9%) presented with persistent atrial fibrillation. Clinical data were prospectively entered into our institutional database.

Results Cardiopulmonary bypass time accounted for 140.2 ± 32.6 minutes and the myocardial ischemic time was 78.5 ± 12.4 minutes. Thirty-day mortality and overall mortality were zero. Peak ventricular outflow gradient decreased from 75.2 ± 12.7 to 9.4 ± 2.3 mm Hg ($p < 0.0001$). Simultaneously, mitral valve reconstruction and replacement were performed in 11 (78.6%) and 3 (21.4%) patients, respectively. No systolic anterior motion was seen in patients with mitral valve repair. No conversion to full sternotomy and/or rethoracotomy was noted. During a mean follow-up period of 24 ± 13 months, no patient required reoperation, no recurrence mitral regurgitation, and left ventricular outflow tract obstruction.

Conclusion Transmitral septal myectomy combined with mitral valve surgery through right anterior mini-thoracotomy can be performed safely with excellent surgical outcomes.

Keywords
- minimally invasive surgery (includes port access
- mini-thoracotomy)
- mitral valve surgery
- cardiomyopathy

Introduction

Hypertrophic obstructive cardiomyopathy (HOCM) is a genetic disease of the myocardium characterized by a hypertrophic left ventricle (LV) leading in most cases to left ventricular outflow tract obstruction (LVOTO). Untreated patients die of sudden cardiac death due to ventricular arrhythmias.[1] Septal myectomy is the procedure of choice for surgical treatment and has been shown to have the best long-lasting results for severe symptomatic patients with a left ventricular outflow tract (LVOT) pressure gradient > 50 mm Hg and refractory to medical therapy.[2] Moreover, concomitant mitral valve (MV) surgery is required in 11 to 20% of patients undergoing myectomy.[3] Various accesses to reach and resect the hypertrophied myocardium to dilate the LVOT are described in the literature.[4,5] Transmitral access seems to be very suitable for septal myectomy particularly when mitral surgery is

received
September 21, 2021
accepted after revision
January 27, 2022
article published online
May 29, 2022

© 2022. Thieme. All rights reserved.
Georg Thieme Verlag KG,
Rüdigerstraße 14,
70469 Stuttgart, Germany

DOI https://doi.org/10.1055/s-0042-1744261.
ISSN 0171-6425.

This document was downloaded for personal use only. Unauthorized distribution is strictly prohibited.

necessary. However, minimally invasive transmitral septal myectomy combined with MV surgery through right anterior mini-thoracotomy (RAMT) is rarely presented in the literature. The objective of this study is to present our minimally invasive surgical technique and the clinical results of our institutional experience with this technique over the past 4 years.

Material and Methods

Between March 2017 and October 2020, 14 patients with HOCM and MV disease required in our department minimally invasive transmitral septal myectomy combined with MV surgery. The study was approved by the responsible ethics committee (Ifd. Nr.: 82/2021) and individual patient consent for the study was waived. As part of the dyspnea examination, MV regurgitation and HOCM were simultaneously diagnosed by echocardiography in all patients and both pathological findings required surgery. During the same period, 59 patients with HOCM associated with aortic valve disease were treated in our department through the classical transaortic approach.

The mean age of patients was 54.2 ± 11.4 and 42.9% ($n = 6$) were female. Twelve patients (85.7%) were in New York Heart Association (NYHA) class III to IV and 6 patients (42.8%) presented with persistent atrial fibrillation (AF). MV degeneration was diagnosed in all patients. The pathological finding of the MV included severe posterior leaflet prolapse in 9 patients (64.3%), ruptured chordae tendineae in 3 patients (21.4%), systolic anterior motion (SAM) in 3 patients (21.4%), Barlow's MV disease in 2 patients (14.3%), elongated anterior mitral leaflet (AML) in 2 patients (14.3%), and rheumatic MV with annular calcification in 2 patients (14.3%). Regarding the extent of the HOCM disease, 13 patients (92.8%) were diagnosed with isolated subaortic HOCM and one patient (7.1%) with extensive HOCM causing some midventricular and apical obstruction. Therefore, MV reconstruction and replacement were performed in 11 (78.6%) and 3 (21.4%) patients, respectively. Transmitral septal myectomy was successfully performed in all patients. Clinical data were prospectively entered into our institutional database. Relevant clinical characteristics of our patients are listed in ►**Table 1**.

Operative Technique

The patient was placed in a supine position with slight elevation of the right chest. After induction of general anesthesia and intubation with single lumen endotracheal tube, cannulation for cardiopulmonary bypass (CPB) was performed through the common femoral vessels guided by transesophageal echocardiogram (TEE) in all patients after heparin administration. Surgical and percutaneous access in the right groin was performed in 5 (35.7%) and 9 (64.2%) patients, respectively. All operations were performed following the technique and the operative setting described by Seeburger et al.[6] RAMT was performed through a 3- to 5-cm skin incision at the fourth right intercostal space in 12 (85.7%) patients. In 2 (14.3%) patients, periareolar skin incision as nipple-cut approach was performed. After insertion of a soft tissue retractor (Valve Gate Soft Tissue Protector, Geister, Germany) and placement of pericardial stay sutures, the

Table 1 Patient characteristics

Characteristic	*N* (%)
Number of patients	14 (100)
Age (years ± SD)	54.2 ± 11.4
Female	6 (42.9)
Arterial hypertension	8 (57)
ICD	2 (14.3)
Permanent pacemaker	1 (7.1)
Prior myocardial infarction	2 (14.3)
Diabetes mellitus	4 (29.0)
COPD	3 (21.0)
Renal failure	2 (14.3)
Smoking history	6 (42.8)
Atrial fibrillation	6 (42.8)
Coronary artery disease	5 (35.7)
Previous cardiac operations	0 (0.0)
Peripheral arterial disease stage II	1 (7.1)
NYHA functional class	
I/II	2 (14.3)
III/IV	12 (85.7)

Abbreviations: COPD, chronic obstructive lung disease; ICD, implantable cardioverter defibrillator; NYHA, New York Health Association; SD, standard deviation.

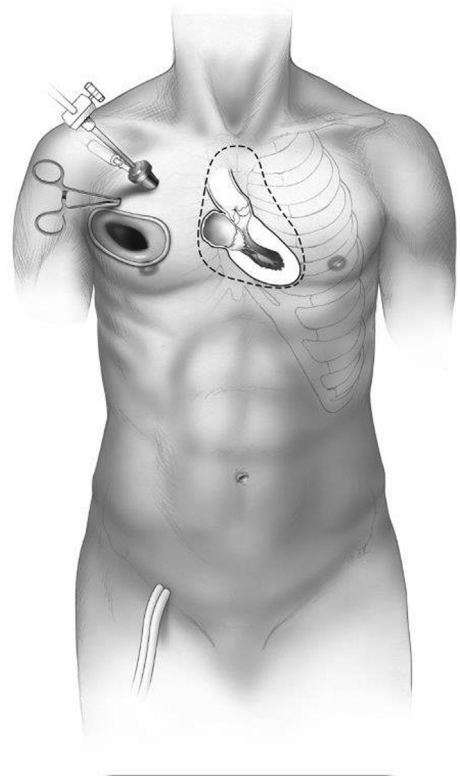

Fig. 1 Setup of video-assisted minimally invasive transmitral septal myectomy and mitral valve surgery through right anterior mini-thoracotomy and percutaneous femoral cannulation for cardiopulmonary bypass.

 © 2022. Thieme. All rights reserved.

This document was downloaded for personal use only. Unauthorized distribution is strictly prohibited.

three-dimensional (3D) camera (Aesculap Einstein Vision, Tuttlingen, Germany) port and the Chitwood clamp (Scanlan International, Inc, St. Paul, Minnesota, United States) were placed through the intercostal space above the main incision (►**Fig. 1**). Crystalloid cardioplegia (Custodiol; Koehler Chemi, Alsbach-Haenlien, Germany) was administered in an antegrade fashion through a long cardioplegia catheter (Medtronic DLP 9F, Ref 10012) into the ascending aorta.

After exposure of the MV, assessment, and determining the operative strategy of the MV (valve repair in 11 [78.6%] and valve replacement in 3 [21.4%] patients), interventricular septum was reached in cases of MV repair after classical detachment of the AML from the annulus with leaving a 1-mm margin (►**Fig. 2A**). An extensive myectomy was then performed using knife and scissors after placing a stay suture on the muscle bulge (►**Fig. 2B, C**). If necessary, resection of hypertrophied LV muscle, including apical muscle and abnormal muscle bundles around papillary muscles (PMs) can be easily performed through the mitral orifice. The depth and localization of the myectomy were adjusted based on the measured thickness on TEE. The goal was to achieve a thickness of 10 to 15 mm. The continuity of the AML was then performed with augmentation using an 18-mm autologous pericardial patch in all patients (►**Fig. 2D, E**). MV repair was performed to obtain a sufficient leaflet coaptation and a competent valve (►**Fig. 2F**; ►**Table 2**). In case of MV replacement, the AML was totally removed leading to better exposure and resect of hypertrophied LV structures including chordae and PM. A mechanical or biological mitral prosthesis was then implanted. An automatic fastener (Cor-Knot, LSI Solutions, Rochester, New York, United States) was used to secure the valve or ring sutures. Concomitant procedures including cryomaze procedure, tricuspid annuloplasty, or occlusion of left atrial appendage were performed as needed depending on the patient's comorbidities.

After testing the competence of the valve with a water probe, the left atrium was closed in two layers with 4–0 Prolene (►**Video 1**). Intraoperative TEE was performed to assess the enlarged LVOT, confirm a satisfactory MV function, and left and right ventricular function as well as an absence of SAM phenomena.

Video 1

The most important steps of the technique are presented in a male patient with severe hypertrophic obstructive cardiomyopathy (HOCM) and mitral valve regurgitation. Online content including video sequences viewable at: https://www.thieme-connect.com/products/ejournals/html/10.1055/s-0042-1744261.

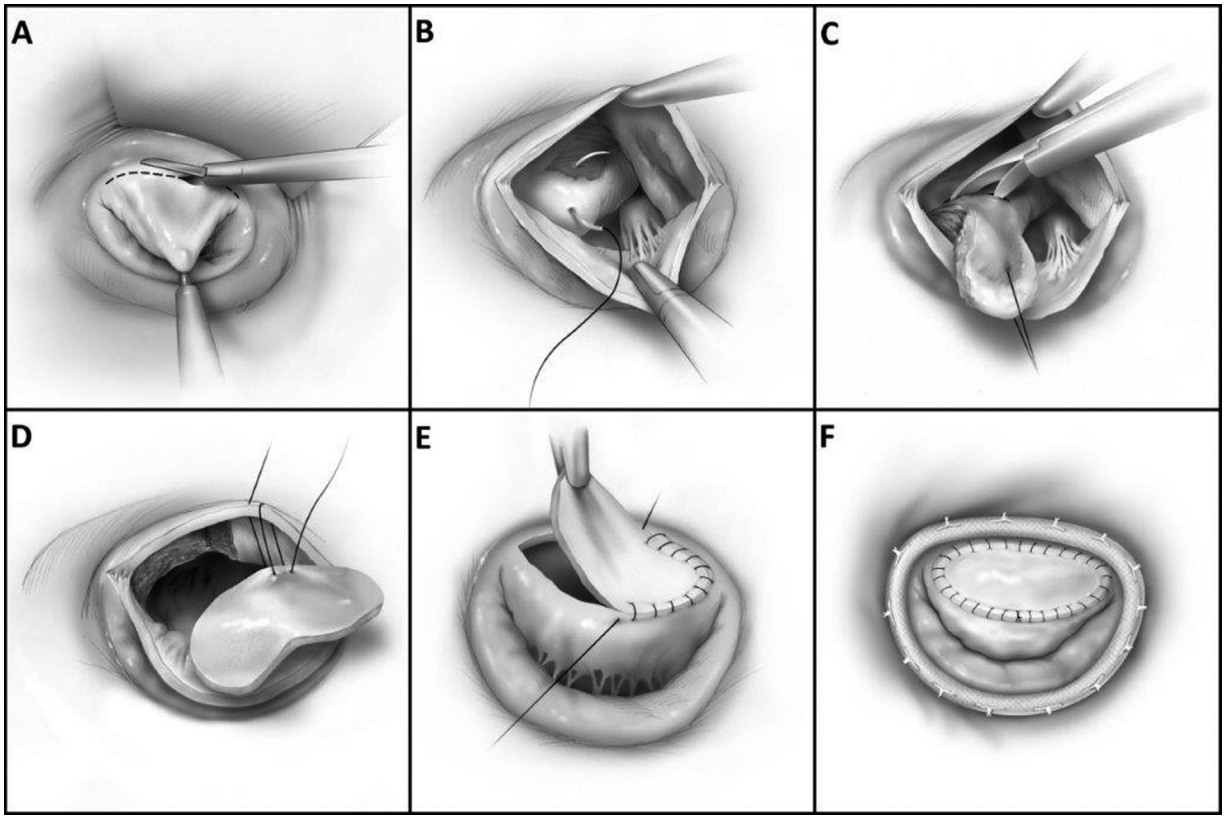

Fig. 2 Illustration showing the different steps of transmitral septal myectomy and mitral valve reconstruction. (**A**) Detachment of the AML from the annulus with leaving a 1-mm margin. (**B**) Placement of a stay suture on the muscle bulge. (**C**) Resection of the muscle bulge using a scissor. (**D**) Augmentation of the AML using an autologous pericardial patch. (**E**) Running suture of the pericardial patch on the AML carried from the right fibrous trigone toward the left fibrous trigone. (**F**) Annuloplasty of mitral valve with complete ring after augmentation of the AML with autologous pericardial patch. AML, anterior mitral leaflet.

 © 2022. Thieme. All rights reserved.

This document was downloaded for personal use only. Unauthorized distribution is strictly prohibited.

Table 2 Perioperative results and surgical procedures

Variable	*N* (%)
Elective surgery	14 (100)
CPB time (minutes ± SD)	140.2 ± 32.6
Myocardial ischemic time (minutes ± SD)	78.5 ± 12.4
Septal myectomy	14 (100)
Mitral valve operation	
Repair	11 (78.6)
Replacement	3 (21.4)
Biological	1 (7.1)
Mechanical	2 (14.3)
Use of "loop technique"	9 (64.3)
Resuspension of PML	6 (42.8)
Resuspension of AML	2 (14.3)
Resuspension of both leaflets	1 (7.1)
AML patch augmentation	11 (78.6)
Concomitant procedures	
Tricuspid annuloplasty	1 (7.1)
Cryomaze	4 (29.0)
LAA closure	4 (29.0)
Ventilation time (h)	4.2 ± 2.1
Intensive care unit stay (d)	2.3 ± 1.1
Hospital stay (d)	7.4 ± 3.1
Intraoperative mortality	0 (0.0)
Thirty-day mortality	0 (0.0)
Overall mortality	0 (0.0)
Delirium	1 (7.1)
Postoperative cerebrovascular event	0 (0.0)
New pacemaker implantation	1 (7.1)
Conversion to full sternotomy	0 (0.0)
Thoracic wound infection	0 (0.0)
Pericardial effusion with need to puncture	0 (0.0)
Rethoracotomy	0 (0.0)
New postoperative transient dialysis	0 (0.0)
New onset of atrial fibrillation	3 (21.4)
Postoperative NYHA class I/II	14 (100)
Patients referred to the rehabilitation clinic	9 (64.3)
Patients discharged home	5 (35.7)

Abbreviations: AML, anterior mitral leaflet; CPB, cardiopulmonary bypass; LAA, left atrial appendage; NYHA, New York Health Association; PML, posterior mitral leaflet; SD, standard deviation.

After arterial and venous decannulation from the groin, the soft tissue and skin were closed with a resorbable intracutaneous suture in case of surgical access. In case of percutaneous access, a vessel closure device MANTA (Essential Medical Inc., Malvern, Pennsylvania, United States) was used to close the artery. After hemostasis was confirmed, the ribs were secured with two FiberWire (Arthrex, Naples, Florida, United States) and the wound was then closed in layers.

Statistical Analysis

All perioperative data were collected prospectively. Data are presented as mean ± standard deviation. Categorical variables are expressed as percentages. Preoperative and postoperative echocardiographic values were compared using a paired Student's *t*-test. For this analysis, a *p*-value less than 0.05 was considered statistically significant. All statistical analyses were performed with StatView (version 5.0) for Windows software (SAS Institute, Inc, Cary, North Carolina, United States).

Follow-Up

Clinical data from the initial hospitalization were prospectively entered into our institutional database. Follow-up for discharged patients was performed by mail or telephone interview during a 2-month closing interval ending in January 2021 and was 100% complete.

Results

Transmitral myectomy and MV surgery was performed electively in all patients. CPB time accounted for 140.2 ± 32.6 minutes and the myocardial ischemic time 78.5 ± 12.4 minutes. Thirty-day mortality and overall mortality were zero. Mean ventilation time, intensive care unit stay, and hospital stay were 4.2 ± 2.1 hours, 2.3 ± 1.1 days, and 7.4 ± 3.1 days, respectively.

No conversion to full sternotomy and/or rethoracotomy was noted. No permanent postoperative cerebrovascular event was observed. One patient (7.1%) developed a transient delirium and was discharged home without any symptoms.

Simultaneously, MV repair and replacement were performed in 11 (78.6%) and 3 (21.4%) patients, respectively. In all patients with MV repair, the AML was patched and augmented with an 18-mm autologous pericardium, an annuloplasty was performed with complete ring Physio II (Edwards Lifesciences, Irving, California, United States). In 9 patients (64.3%) with MV repair, the posterior mitral leaflet (PML) was resuspended using the "loop technique" in 6 patients (42.8%) to address the PML prolapse and the AML in 2 patients with Barlow's MV disease (14.3%). In one patient (7.1%), the valve repair was unsuccessful due to severe prolapse of both leaflets and the patient received a bioprosthesis (St. Jude Medical Epic, St. Paul, Minnesota, United States). In addition, two patients (14.3%) with MV replacement received mechanical valve (ATS Medical, Inc, Minneapolis, Minnesota, United States) because of severe calcification of both leaflets with restriction of PML.

Tricuspid annuloplasty and cryomaze with occlusion of left atrial appendage procedure were performed as concomitant procedures in one (7.1%) and four (29.0%) patients, respectively (►**Table 2**).

Clinical symptoms were markedly improved from NYHA class III/IV to NYHA class I/II in all patients. Before discharge

 © 2022. Thieme. All rights reserved.

This document was downloaded for personal use only. Unauthorized distribution is strictly prohibited.

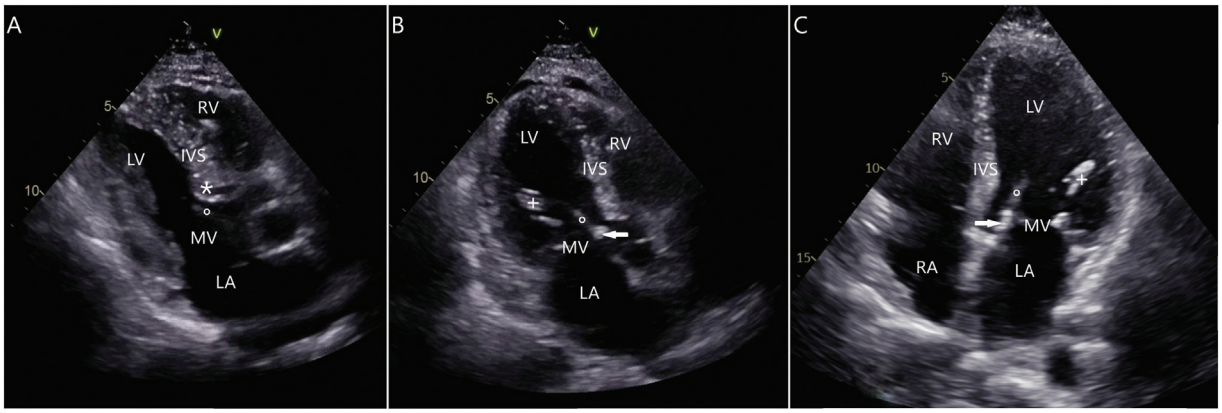

Fig. 3 (**A**) Preoperative transthoracic echocardiogram showing a severe subvalvular aortic outflow tract muscular obstruction. Note the markedly hypertrophied septal "knob" (white asterisk) and its close contact with the AML (white bullet). (**B**) Postoperative transthoracic echocardiogram demonstrates a reduction of the thickness of the interventricular septum with reconstruction of the mitral valve by patch augmentation of the AML (white arrow) and loop insertion (white plus). (**C**) Transesophageal echocardiogram at 1-year follow-up showing a competent reconstructed mitral valve with normal thickness of the IVS. AML, anterior mitral leaflet; IVS, interventricular septum; LA, left atrium; LV, left ventricle; MV, mitral valve; RA, right atrium; RV, right ventricle.

of the patients, postoperative peak ventricular outflow gradient regressed significantly from 75.2 ± 12.7 to 9.4 ± 2.3 mm Hg ($p < 0.0001$) and the left ventricular end-diastolic diameter increased from 40.6 ± 2.8 to 43.2 ± 2.2 mm ($p = .0371$). Interventricular wall thickness decreased significantly from 21.2 ± 2.3 to 13.1 ± 2.1 mm ($p < 0.0001$) (►**Fig. 3**). No SAM was seen in patients with MV repair. Two patients (14.3%) have postoperatively a trace mitral regurgitation (MR) (►**Table 3**). No iatrogenic ventricular septal defect was noted. A permanent pacemaker was necessary for one patient (7.1%) due to postoperative complete atrioventricular block grade 3. Nine patients (64.3%) were transferred to rehabilitation clinics and remaining 5 patients (35.7%) were discharged home (►**Fig. 4**).

During a mean follow-up period of 24 ± 13 months, no patient died or required reoperation, no patient had worse than mild MR, and no LVOTO was noted. None of the patients

Table 3 Echocardiographic data

Variable	Preoperative	Postoperative	*p*-Value
Peak LVOT gradient (mm Hg ± SD)	75.2 ± 12.7	9.4 ± 2.3	< 0.0001
LVEDD (mm ± SD)	40.6 ± 2.8	43.2 ± 2.2	0.0371
Interventricular septal wall thickness (mm ± SD)	21.2 ± 2.3	13.1 ± 2.1	< 0.0001
Left ventricular ejection fraction (% ± SD)	58.0 ± 9.6	56.1 ± 8.6	0.6341
Preoperative findings of mitral valve morphology			
Rheumatic, *N* (%)	2 (14.3)		
Mitral annular calcification, *N* (%)	2 (14.3)		
Degenerative, *N* (%)	12 (85.7)		
Barlow, *N* (%)	2 (14.3)		
Severe posterior leaflet prolapse, *N* (%)	9 (64.3)		
Ruptured chordae tendineae, *N* (%)	3 (21.4)		
SAM, *N* (%)	3 (21.4)		
Elongated anterior leaflet, *N* (%)	2 (14.3)		
Postoperative findings of mitral valve morphology			
Severe MR, *N* (%)	0 (0.0)		
Trace MR, *N* (%)	2 (14.3)		
SAM, *N* (%)	0 (0.0)		
Paravalvular leak, *N* (%)	0 (0.0)		

Abbreviations: LVEDD, left ventricular end-diastolic diameter; LVOT, left ventricular outflow tract; MR, mitral regurgitation; SAM, systolic anterior motion; SD, standard deviation.

 © 2022. Thieme. All rights reserved.

This document was downloaded for personal use only. Unauthorized distribution is strictly prohibited.

Fig. 4 Patient at last follow-up.

Table 4 Last follow-up

Variable	*N* (%)
Postoperative NYHA class	
I/II	12 (85.7)
III/IV	2 (14.3)
Reoperation	0 (0.0)
Moderate to severe mitral regurgitation	0 (0.0)
LVOTO	0 (0.0)
Peak LVOT gradient (mm Hg ± SD)	10.2 ± 1.7
LVEDD (mm ± SD)	44.6 ± 3.1
Interventricular septal wall thickness (mm ± SD)	12.2 ± 2.7
Left ventricular ejection fraction (% ± SD)	56.0 ± 11.1

Abbreviations: LVEDD, left ventricular end-diastolic diameter; LVOT, left ventricular outflow tract; LVOTO, left ventricular outflow tract obstruction; NYHA, New York Health Association; SD, standard deviation.

developed cerebrovascular events during this period. One patient (7.1%) was rehospitalized at month 4 after discharge due to heart failure related to AF. At last follow-up, the peak LVOT gradient averaged 10.2 ± 1.7 mm Hg and clinical symptoms were markedly improved in 12 patients (85.7%) and have NYHA class I/II. Two patients (14.3%) have a NYHA class III/IV, one (7.1%) due to severe chronic obstructive pulmonary disease and the other due to a rapid progression of the aortic valve stenosis scheduled for the operation (►**Table 4**). To optimize the EuroScore during the index operation in this high-risk patient, only the MV and HOCM were treated, since the mild to moderate aortic valve stenosis could be resolved with transcatheter aortic valve implantation procedure in the future.

Discussion

Over the past two decades, minimally invasive MV surgery has gained increasing popularity worldwide due to its beneficial effects demonstrated in several studies.[7,8] Concomitant procedures with MV surgery via the same minimally invasive access are very common with low mortality and morbidity.[9] However, transmitral myectomy for HOCM as concomitant procedure through RAMT is not routine and is reported in few cases in the literature.[11,12] To the best of our knowledge, this is the large published series of patients who underwent a minimally invasive MV surgery with transmitral septal myectomy with midterm outcomes.

Conventionally, transaortic access is the standard for surgical treatment of HOCM. Over the past 15 years, transaortic access showed a considerable reduction in operative mortality, to less than 2% in several studies.[12–15] However, the transaortic approach is associated with the risk of aortic valve damage, and difficulties in approaching the middle or distal portion of the LV, especially in cases where the aortic valve is not intended to be replaced. While the transaortic approach improved resolution of SAM and MR, the transmitral approach decreases the risk of aortotomy and aortic valve damage and allows for a better view of the entire LV for radical myectomy as well as more complex MV repair or replacement.[16,17]

In the past 4 years, 14 patients with HOCM and MV disease underwent a minimally invasive MV surgery with transmitral septal myectomy at our institution. The procedure was successfully performed in all patients. Particularly in patients with combined HOCM and MV disease, this surgical technique provides excellent exposure of the entire septum as well as the MV and the subvalvular apparatus, including the base of PMs, and allows a myectomy that easily extends to the LV apex.[18] Adequate myectomy of hypertrophied ventricle leads to a reduction of LVOTO and enlargement of LV cavity and is related to an improvement of the prognosis by reducing the symptoms and consequences of HOCM. All these were confirmed in our patients directly postoperatively and at the follow-up. The last follow-up (24 ± 13 months) shows no LVOTO, the peak LVOT gradient was 10.2 ± 1.7 mm Hg and the clinical symptoms were markedly improved in 12 patients (85.7%) with NYHA class I/II.

There is no doubt that transmitral myectomy and MV surgery is a complex and time-consuming procedure. The exposure of the entire LV and performing a radical transmitral myectomy present technical challenges. These can be facilitated by partial detachment of AML for the upper LV area and through the MV orifice for the lower LV area, and the use of a 3D camera to enable an optimal view of all LV structures. Moreover, good experience of the surgeon in the minimally invasive surgery and the use of an automated knot system in MV surgery accelerate the procedure.[19] All these factors play a role not only by simplifying the procedure but also in the reduction of the procedure's time. Due to the consideration of the abovementioned facts, CPB time and myocardial ischemic time were lower than those cited in previous reports.[10,11]

In our cohort, the AML was patched and augmented with autologous pericardium in patients with MV repair. This technique leads to a larger LVOT with a decrease of the LVOT gradient, an augmentation of the AML and the increase

 © 2022. Thieme. All rights reserved.

This document was downloaded for personal use only. Unauthorized distribution is strictly prohibited.

of the coaptation area of the MV leading to a competent valve, and the prevention of a SAM phenomenon with long-term durability of the pericardial patches used.[20,21] The midterm outcomes in our cohort confirm this finding.

Key findings of this experience include clear and evident superior visualization of the ventricular septum through the detached MV, effective immediate and midterm relief of LVOTO, and improvement in symptoms. MV repairs in this cohort were performed by AML patch augmentation and the classical resuspension of the AML in cases of AML prolapse or PML in cases of PML prolapse using "loop technique."

Study Limitations

The main limitation of our study is its retrospective and nonrandomized study with small cohort. Besides, it lacks a direct comparison with a group of patients receiving a standard surgical approach. However, the sample size is very small, so the study is not powered enough to detect the incidence of possible complications both perioperatively and in the follow-up. Finally, the generalizability of our findings is questionable, given its single-center design.

Conclusion

Video-assisted RAMT approach provides an excellent access to safely perform a septal myectomy with concomitant MV repair/replacement with good clinical and cosmetics outcomes despite technical challenges.

Conflict of Interest
None declared.

References

1 Fifer MA, Vlahakes GJ. Management of symptoms in hypertrophic cardiomyopathy. Circulation 2008;117:429–439
2 Nguyen A, Schaff HV. Transaortic septal myectomy for obstructive hypertrophic cardiomyopathy. Oper Tech Thorac Cardiovasc Surg 2018;106:670–675
3 Hong JH, Schaff HV, Nishimura RA, et al. Mitral regurgitation in patients with hypertrophic obstructive cardiomyopathy: implications for concomitant valve procedures. J Am Coll Cardiol 2016; 68:1497–1504
4 Nguyen A, Schaff HV. Surgical myectomy subaortic, midventricular, and apical. Cardiol Clin 2019;37:95–104
5 Wu JJ, Seco M, Medi C, et al. Surgery for hypertrophic cardiomyopathy. Biophys Rev 2015;7:117–125
6 Seeburger J, Borger MA, Falk V, et al. Minimal invasive mitral valve repair for mitral regurgitation: results of 1339 consecutive patients. Eur J Cardiothorac Surg 2008;34(04):760–765
7 Schmitto JD, Mokashi SA, Cohn LH. Minimally-invasive valve surgery. J Am Coll Cardiol 2010;56:455–462
8 Aybek T, Dogan S, Risteski PS, et al. Two hundred forty minimally invasive mitral operations through right minithoracotomy. Ann Thorac Surg 2006;81:1618–1624
9 Kilic A, Szeto WY, Atluri P, Acker MA, Clark Hargrove W. Operative outcomes of concomitant minimally invasive mitral and tricuspid valve surgery. Innovations (Phila) 2019;14(05):412–418
10 Gilmanov DSh, Bevilacqua S, Solinas M, et al. Minimally invasive septal myectomy for the treatment of hypertrophic obstructive cardiomyopathy and intrinsic mitral valve disease. Innovations (Phila) 2015;10(02):106–113
11 Sakaguchi T, Totsugawa T, Tamura K, Hiraoka A, Chikazawa G, Yoshitaka H. Minimally invasive trans-mitral septal myectomy for diffuse-type hypertrophic obstructive cardiomyopathy. Gen Thorac Cardiovasc Surg 2018;66(06):321–326
12 Ommen S, Maron BJ, Olivotto L, et al. Long-term effects of surgical septal myectomy on survival in patients with obstructive hypertrophic cardiomyopathy. J Am Coll Cardiol 2005;46:470–476
13 Woo A, Williams WG, Choi R, et al. Clinical and echocardiographic determinants of long- term survival after surgical myectomy in obstructive hypertrophic cardiomyopathy. Circulation 2005; 111:2033–2041
14 Desai M, Bhonsale A, Smedira N, et al. Predictors of long-term outcomes in symptomatic hyper- trophic obstructive cardiomyopathy patients undergoing surgical relief of left ventricular outflow tract obstruction. Circulation 2013;128:209–216
15 Sedehi D, Finocchiaro G, Tibayan Y, et al. Long-term outcomes of septal reduction for obstructive hypertrophic cardiomyopathy. J Cardiol 2015;66(01):57–62
16 Gutermann H, Pettinari M, Van Kerrebroeck C, et al. Myectomy and mitral repair through the left atrium in hyper- trophic obstructive cardiomyopathy: the preferred approach for contemporary surgical candidates? J Thorac Cardiovasc Surg 2014;147:1833–1836
17 Mohr FW, Seeburger J, Misfeld M. Keynote Lecture-transmitral hypertrophic obstructive cardiomyopathy (HOCM) repair. Ann Cardiothorac Surg 2013;2:729–732
18 Casselman F, Vanermen H. Idiopathic hypertrophic subaortic stenosis can be treated endoscopically. J Thorac Cardiovasc Surg 2002;124:1248–1249
19 Bakhtiary F, El-Sayed Ahmad A, Amer M, et al. Video-assisted minimally invasive aortic valve replacement through right anterior minithoracotomy for all comers with aortic valve disease. Innovations (Phila) 2021;16(02):169–174
20 Vriesendorp PA, Schinkel AFL, Soliman OI, et al. Long-term benefit of myectomy and anterior mitral leaflet extension in obstructive hyper- trophic cardiomyopathy. Am J Cardiol 2015;115:670–675
21 Shomura Y, Okada Y, Nasu M, et al. Late results of mitral valve repair with glutaraldehyde-treated autologous pericardium. Ann Thorac Surg 2013;95:2000–2006

This document was downloaded for personal use only. Unauthorized distribution is strictly prohibited.

 © 2022. Thieme. All rights reserved.