Article published online: 2022-09-05

Oncocytic Meningioma: Case Report of a Rare Meningioma Variant

Meningioma oncocítico: Relato de caso de variante rara de meningioma

Yuri Reis Casal[1] Lívia Porto Teixeira[2] Gabriela Alencar Bandeira[2] Matheus Moreli Porceban[3] Wellingson Silva Paiva[3] Luis Filipe de Souza Godoy[2] Vitor Nagai Yamaki[3] Leandro Tavares Lucato[2] Venâncio Avancini Ferreira Alves[1] Fernando Pereira Frassetto[1]

[1] Division of Neuropathology, Department of Pathology, Universidade de São Paulo, São Paulo, SP, Brazil
[2] Division of Neuroradiology, Department of Radiology, Universidade de São Paulo, São Paulo, SP, Brazil
[3] Department of Neurosurgery, Universidade de São Paulo, São Paulo, SP, Brazil

Address for correspondence Yuri Reis Casal, MD, Rua Dr. Enéas de Carvalho Aguiar, 255 – Hospital das Clínicas da Universidade de São Paulo, São Paulo, Brazil (e-mail: yurireiscasal@hotmail.com).

Arq Bras Neurocir 2023;42(1):e79–e84.

Abstract

Oncocytic meningioma has been first identified in 1997 as a rare meningioma variant, composed predominantly of large meningothelial cells with abundant intracytoplasmic mitochondria. Here, we describe a 34-year-old male patient presenting with 2 weeks of progressive holocranial headache. Brain magnetic resonance imaging (MRI) revealed an extra axial solid-cystic expansive lesion in the left parieto-occipital parasagittal region, with intense vascularization. Histological and immunohistochemical analysis established the diagnosis. We also review briefly the pathological and radiological findings of this rare variant of meningioma as described in the literature.

Keywords
- meningioma
- mitochondria
- pathology

Resumo

O meningioma oncocítico foi identificado pela primeira vez em 1997 como uma variante rara do meningioma, composta predominantemente por grandes células meningoteliais com abundantes mitocôndrias intracitoplasmáticas. Aqui, descrevemos um paciente do sexo masculino de 34 anos apresentando cefaleia holocraniana progressiva de 2 semanas. A ressonância magnética (RM) do cérebro revelou lesão expansiva sólido-cística extra-axial em região parassagital parieto-occipital esquerda, com intensa vascularização. A análise histológica e imuno-histoquímica estabeleceu o diagnóstico. Também revisamos brevemente os achados patológicos e radiológicos desta variante rara de meningioma, conforme descrito na literatura.

Palavras-chave
- meningioma
- mitocôndrias
- patologia

received
July 17, 2021
accepted
October 13, 2021

DOI https://doi.org/10.1055/s-0042-1743556.
ISSN 0103-5355.

© 2022. Sociedade Brasileira de Neurocirurgia. All rights reserved.
This is an open access article published by Thieme under the terms of the Creative Commons Attribution-NonDerivative-NonCommercial-License, permitting copying and reproduction so long as the original work is given appropriate credit. Contents may not be used for commercial purposes, or adapted, remixed, transformed or built upon. (https://creativecommons.org/licenses/by-nc-nd/4.0/)
Thieme Revinter Publicações Ltda., Rua do Matoso 170, Rio de Janeiro, RJ, CEP 20270-135, Brazil

Introduction

Oncocytic meningioma is a rare histological meningioma variant, characterized histologically by large meningothelial cells, with a ground-glass oncocytic appearance due to abundant intracytoplasmic mitochondria.[1,2] Oncocytic changes are rare in tumors of the central nervous system and are generally limited to neoplasms of the choroid plexus and neurohypophysis.[3,4] This variant of meningioma has been included in the description of the World Health Organization (WHO) classification of tumors of the central nervous system (4th edition, 2016), but its clinical, radiological, and histopathological characteristics are still poorly understood, due to a very limited number of descriptions in the literature.

The first case was reported by Roncaroli et al. in 1997.[5] Sassagawa et al.[6] reported a case with intratumoral bleeding as the main clinical-radiological finding, an unusual feature in meningiomas.[7] The diagnosis of oncocytic differentiation of meningioma has been later associated by some authors with a worse clinical prognosis and greater risk of recurrence.[7] However, most cases do not present invasion of the adjacent brain parenchyma or other major criteria of atypia; therefore, oncocytic differentiation has not been defined as a high-grade neoplasm.[8]

Histological criteria for the diagnosis of oncocytic meningioma require at least 75% of the tumor cell population presenting the characteristic oncocytic pattern.[8] Immunohistochemical evaluation of the reported cases also demonstrate positivity for antimitochondrial antigens.[6] In its first description, oncocytic meningioma was described as having an aggressive behavior, indicating worse prognosis, despite its apparently benign histological presentation.[6]

Here, we describe a case of oncocytic meningioma from the Hospital das Clínicas of the Universidade de São Paulo, São Paulo, state of São Paulo, Brazil. To our knowledge, this is the first case of oncocytic meningioma reported in the American continent.

Clinical Summary

Clinical History

Male patient, 34 years old, engineer, previously healthy, complained of progressive headache for 14 days. Pain was reported as holocranial, intense, and unresponsive to analgesics, sometimes associated with nausea and vomiting. Family members reported that the patient presented with episodes of behavioral arrest for seconds, without loss of consciousness, motor alterations, or sphincter dysfunction. He denied any comorbidities, use of medications, alcohol, smoking, or use of illicit drugs. At the initial neurological evaluation, the patient was alert, lucid, and oriented in time and space, with muscle strength preserved on the four limbs. He presented tactile hypoesthesia on the right upper limb and lower quadrantopsia on the right side. Speech was fluent, able to name objects; however, with some writing difficulty.

Magnetic resonance imaging (MRI) showed a large, solid-cystic extra-axial parietal lesion in the left side, with lobulated contours, presenting accentuated vascularization and heterogeneous contrast enhancement, without restriction to diffusion of water molecules. In addition, the perfusion evaluation demonstrated a marked increase in the relative cerebral blood volume in relation to the contralateral normal white matter.

There was perilesional edema in addition to a large cystic content adjacent to the lesion, without contrast enhancement, which, together with the lesion, determined left lateral ventricle compression and subfalcine herniation (►**Fig. 1**).

A complementary study of the whole vertebral spine showed no changes. Laboratory tests on admission did not detect hematological, hepatic, or renal dysfunctions. Integrating all imaging findings, clinical history, age and gender of the patient led to hemangiopericytoma as the main diagnostic hypothesis, followed by primary meningeal neoplasia, dural metastases, lymphoma, and inflammatory diseases as differential diagnosis. Since the lesion showed intense vascularization, the patient was submitted to arteriography to attempt preoperative embolization 1 day before surgery. Despite the embolization, the tumor showed exuberant vascularization during the surgery as well as areas of internal bleeding. The lesion was completely removed surgically. The patient was discharged from the hospital 4 days after the surgery, being followed-up by the neurosurgery group.

Pathological Findings

We received multiple irregular fragments of brownish tissue with frequent reddish spots and fibroelastic consistency alternating with friable areas (►**Fig. 2**–A).

The entire specimen was fixed in 10% buffered formalin and embedded in paraffin. Then, 5-μ-thick sections were cut and stained with hematoxylin and eosin (H&E). Immunohistochemical staining was performed on an automated immunostaining system Ventana BenchMark Ultra (Ventana, Oro Valley, AZ, USA) with negative and positive controls. The antigens searched were: epithelial membrane antigen (EMA, clone E29; Ventana, Oro Valley, AZ, USA), SSTR2 (Clone UMB1; Abcam, Cambridge, UK), STAT6 (Clone 426R-16; Cell Marque, Rocklin, CA, USA), S100 protein (polyclonal; Ventana, Oro Valley, AZ, USA), progesterone receptor (1E2; Ventana, Oro Valley, AZ, USA), glial fibrillary acidic protein (GFAP, EP672Y, Cell Marque, Rocklin, CA, USA), CD34 (clone QBEnd/10, Ventana; Oro Valley, AZ, USA), anti-mitochondrial antibody (clone 113–1; BioGenex, Fremont, CA, USA) and K_i-67 (clone 30–9; Ventana, Oro Valley, AZ, USA).

Microscopic examination revealed a predominant solid pattern, with high cellular areas intermingled with prominent large intratumoral vascular spaces. The prevailing cell pattern was well-defined epithelioid cells with marked pleomorphic, irregular, and vesicular nuclei, with frequent nuclear pseudoinclusions, and broad eosinophilic granular cytoplasm (►**Fig. 3**). We observed the presence of neutrophilic infiltrate predominantly in areas of ischemic pattern necrosis and frequent areas of intratumoral hemorrhage. The mitotic count was 2 mitoses in 10 high power fields (400x

 © 2022. Sociedade Brasileira de Neurocirurgia. All rights reserved.

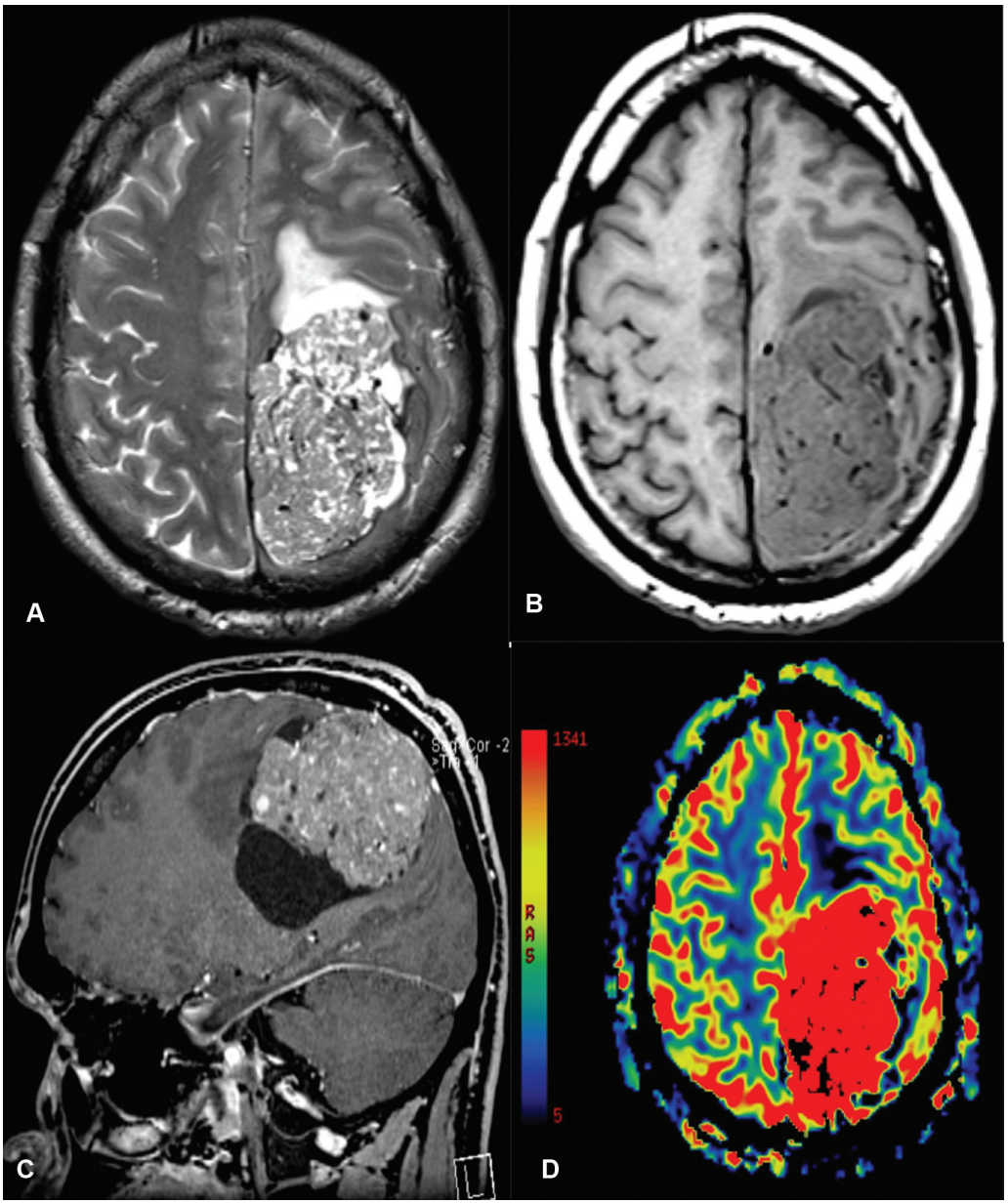

Fig. 1 Axial T2-weighted (**A**), axial T1-weighted precontrast (**B**) and sagittal T1- weighted postcontrast (**C**) Magnetic resonance imaging (MRI) shows a large, solid-cystic extra-axial lesion in the left parieto-occipital region, presenting accentuated vascularization and heterogeneous contrast enhancement. Perfusion MRI (**D**) exhibits marked increase in the relative cerebral blood volume in relation to the contralateral normal white matter.

magnification/0,196 mm^2). The proliferation index, measured by Ki67 immunoreactivity, ranged from 4 to 10% in "hot-spots" (median of 8%).

The immunohistochemical positivity for EMA, progesterone receptor, and SSTR2a antibodies demonstrated the meningothelial origin of the neoplasia (►**Fig. 4–A, B** and **C**). The negativity for STAT6 (►**Fig. 4 - G**) and the presence of immune-positivity for the vascular endothelial markers (CD34) limited to the vessel walls (►**Fig. 4**–F) ruled out the hypotheses hemangiopericytoma and of tumors of vascular origin. The diffuse cytoplasmic immunopositivity for anti-mitochondrial antibody determined the diagnosis of oncocytic meningioma (►**Fig. 4 - D**).

Discussion

A very limited number of cases of oncocytic meningiomas have been reported in the literature and little is known about the imaging and histological features of this variant. Previous studies have reported tumors with a broad dural base, homogeneous contrast enhancement, and with a tendency to hemorrhage.[6,9]

 © 2022. Sociedade Brasileira de Neurocirurgia. All rights reserved.

Fig. 2 (A) Macroscopic appearance of the tumor after fixation on 10% buffered formalin.

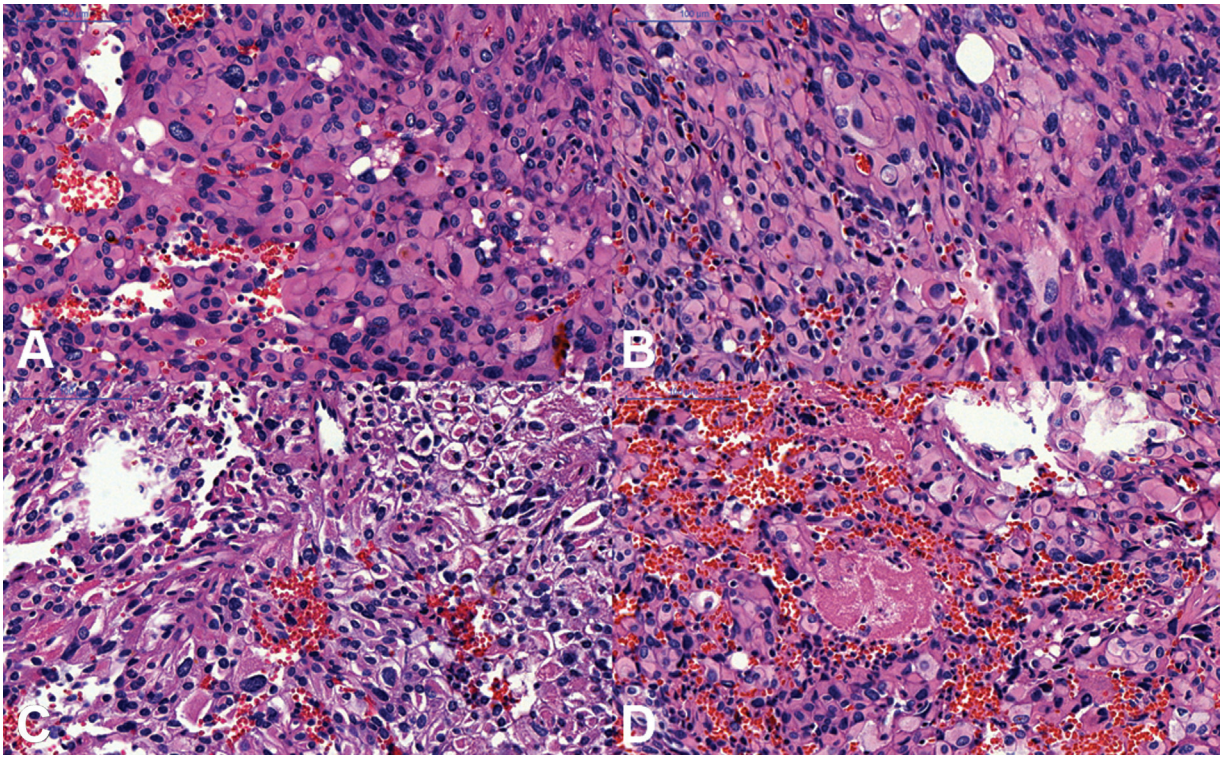

Fig. 3 (A) Hematoxylin & eosin stained slide highlighting intensely pleomorphic tumor cells with well-defined borders. (B) The tumor cells show frequent nuclear pseudoinclusions, eosinophilic and granular cytoplasm, and areas of hypercellularity. (C) Most tumor cells present pale and clearly granular cytoplasm. (D) Areas hemorrhage and focus of necrosis (center of the field) are frequent in this tumor.

In our case, although there was no doubt regarding the extra-axial origin of the tumor, some image characteristics such as the absence of a dural tail and exuberant vascularization with large caliber vessels intermingling the entire tumor were considered atypical characteristics[3] for meningothelial neoplasm.[10] In angiography, there was no pattern of vascularization commonly found in meningioma, characterized by large central vessels with multiple peripheral branches of fine caliber. All these findings led to the preoperative hypothesis of non-meningothelial mesenchymal neoplasms, mainly hemangiopericytoma.

 © 2022. Sociedade Brasileira de Neurocirurgia. All rights reserved.

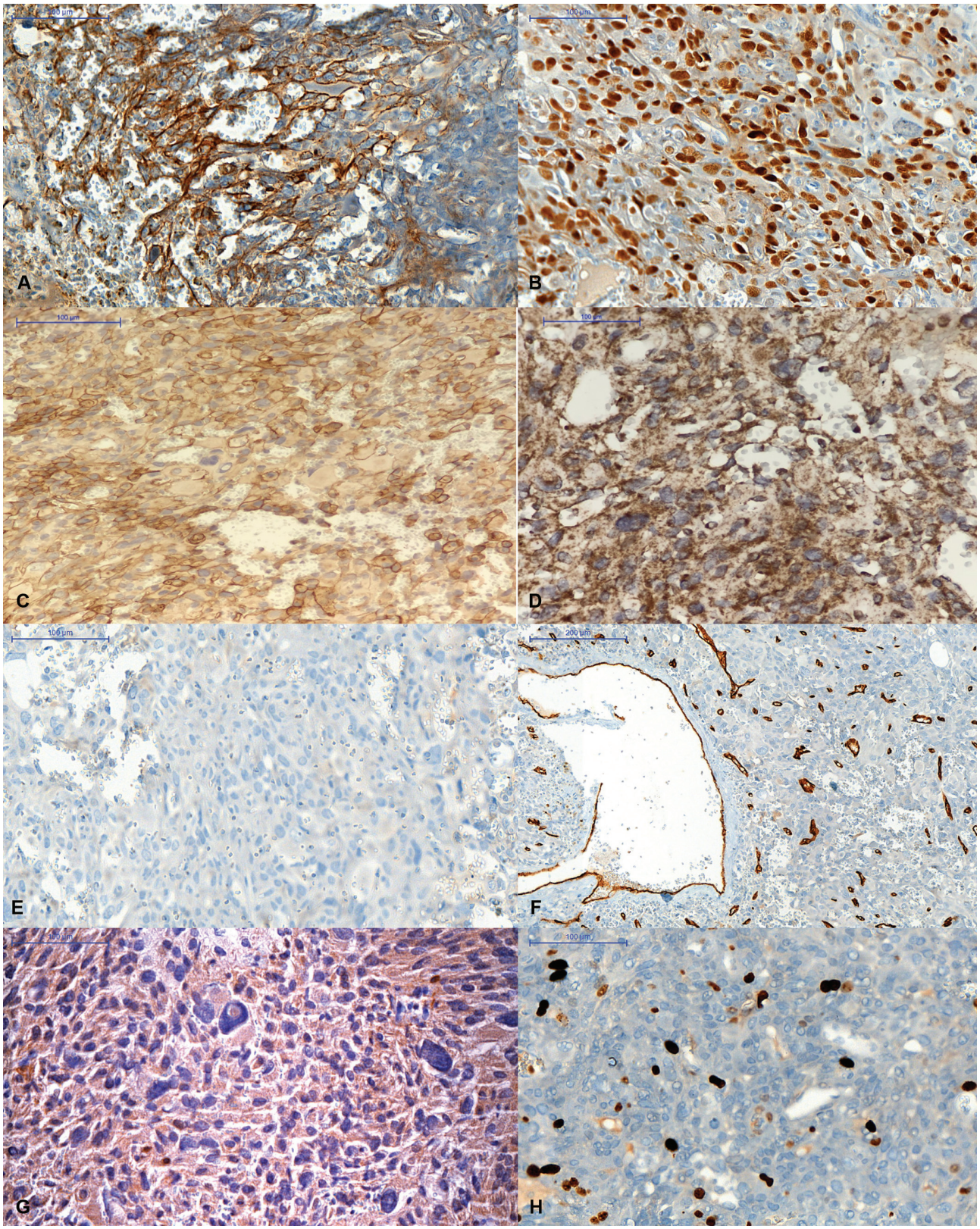

Fig. 4 (**A**) Focal membrane immunoreactivity to EMA in tumor cells. (**B**) Nuclear immunoreactivity to progesterone receptor. (**C**) Diffuse membrane immunoreactivity to anti-SSTR2A. (**D**) Strong granular cytoplasmatic immunoreactivity to antimitochondrial antibody in tumor cells. (**E**) Negative immunoreaction to GFAP. (**F**) Vascular endothelial immunoreactivity to CD34 highlighting intense vascularization of the tumor. (**G**) Negative immunoreaction to STAT6, ruling out the possibility of solitary fibrous tumor epithelioid variant. (**H**) Low to moderate immunoreactivity to Ki67 (8% in the neoplastic cells).

 © 2022. Sociedade Brasileira de Neurocirurgia. All rights reserved.

Upon evaluation by imaging exams, this neoplasm can be confused with other tumors.[11] The usual treatment for both hemangiopericytoma and meningiomas is surgical resection, with gross total resection when feasible. Following surgery, the histopathological examination, associated with immunohistochemical testing, is essential for the diagnosis. In oncocytic meningiomas, the morphological evidence of large cell tumor of granular cytoplasm and meningothelial lineage together with the confirmation of numerous mitochondria in the cytoplasm differentiate this entity from other neoplasms with granular appearance.[3]

In general, in tumors that have an oncocytic morphology, such as oncocytic thyroid tumors and oncocytic adrenal gland tumors, the increased number of intracytoplasmic mitochondria has been related to impairment of mitochondrial DNA encoding for mitochondrial proteins, which results in mitochondrial proliferation via stimulation of transcription factors encoded by the nucleus.[12] In oncocytic neoplasms, the histological appearance is thought to be caused by a disequilibrium between mitochondrial proliferation and mitochondrial destruction and/or cell division, resulting in an accumulation of mitochondria.[13] Furthermore, oncocytic thyroid tumors are also reported to have a higher prevalence of large deletions of mitochondrial DNA (mtDNA) and mutations of mtDNA genes that code for oxidative phosphorylation proteins, which could be related to energy production defects.[14] The mitochondrial abnormalities may contribute to this predisposition to necrosis instead of apoptosis[14] and is a possible explanation for the uncommon pattern of vascularization of this oncocytic meningioma and the reported tendency for bleeding and infarction, as has also been seen in this case.

The need for adjuvant treatment is evaluated according to complete or incomplete removal of the tumor and atypical findings, like brain invasion, increased mitotic activity, increased cellularity, small cell with high nuclear to cytoplasmic ratio, sheeting, and foci of spontaneous necrosis.[2,15]

The knowledge of this entity is important because, despite some worrying microscopic and imaging aspects, it generally behaves indolently, with surgical resection being the therapy of choice and no need for adjuvant treatment.

Conflict of interests

The authors have no conflict of interests to declare.

Acknowlegdements

The authors wish to extend their special thanks to Maria Claudia Nogueira Zerbine for her kindness on providing essential tools to the present publication.

References

1 Marucci G, Betts CM, Frank G, Foschini MP. Oncocytic meningioma: report of a case with progression after radiosurgery. Int J Surg Pathol 2007;15(01):77–81
2 Louis D, Ohgaki H, Wiestler O, et al. WHO Classification of Tumours of the Central Nervous System (Revised 4th edition). IARCLyon2016
3 Caldarella A, Buccoliero AM, Marini M, Taddei A, Mennonna P, Taddei GL. Oncocytic meningioma: a case report. Pathol Res Pract 2002;198(02):109–113
4 Giangaspero F, Cenacchi G. Oncocytic and granular cell neoplasms of the central nervous system and pituitary gland. Semin Diagn Pathol 1999;16(02):91–97
5 Zunarelli E, Tallarico E, Valentini A, Maiorana A. Oncocytic meningioma: study of eight new cases and analysis of 13 reported cases. Pathology 2010;42(06):587–589
6 Sasagawa Y, Tachibana O, Iida T, Iizuka H. Oncocytic meningioma presenting with intratumoral hemorrhage. J Clin Neurosci 2013; 20(11):1622–1624
7 Roncaroli F, Riccioni L, Cerati M, et al. Oncocytic meningioma. Am J Surg Pathol 1997;21(04):375–382
8 Niiro M, Ishimaru K, Hirano H, Yunoue S, Kuratsu J. Clinicopathological study of meningiomas with haemorrhagic onset. Acta Neurochir (Wien) 2003;145(09):767–772
9 Zheng J, Geng M, Shi Y, Jiang B, Tai Y, Jing H. Oncocytic meningioma: a case report and review of the literature. Surg Oncol 2013;22 (04):256–260
10 Nagai Yamaki V, de Souza Godoy LF, Alencar Bandeira G, et al. Dural-based lesions: is it a meningioma? Neuroradiology 2021; 63(08):1215–1225
11 Lyndon D, Lansley JA, Evanson J, Krishnan AS. Dural masses: meningiomas and their mimics. Insights Imaging 2019;10(01):11
12 Cannon J. The significance of hurthle cells in thyroid disease. Oncologist 2011;16(10):1380–1387
13 Máximo V, Sobrinho-Simões M. Mitochondrial DNA 'common' deletion in Hürthle cell lesions of the thyroid. J Pathol 2000;192 (04):561–562
14 Máximo V, Lima J, Prazeres H, Soares P, Sobrinho-Simões M. The biology and the genetics of Hurthle cell tumors of the thyroid. Endocr Relat Cancer 2012;19(04):R131–R147
15 Rogers L, Barani I, Chamberlain M, et al. Meningiomas: knowledge base, treatment outcomes, and uncertainties. A RANO review. J Neurosurg 2015;122(01):4–23

 © 2022. Sociedade Brasileira de Neurocirurgia. All rights reserved.