



Prevention of Serious Complications during Endoscopic Ultrasound-Guided Biliary Drainage: A Case-Based Technical Review

Surinder Singh Rana¹ Jimil Shah¹ Harish Bhujade² Ujjwal Gors² Mandeep Kang² Rajesh Gupta³

¹Department of Gastroenterology, Postgraduate Institute of Medical Education and Research (PGIMER), Chandigarh, India

²Department of Radiodiagnosis, Postgraduate Institute of Medical Education and Research (PGIMER), Chandigarh, India

³Department of Surgical Gastroenterology, Postgraduate Institute of Medical Education and Research (PGIMER), Chandigarh, India

Address for correspondence Surinder S. Rana, MD, DM, FASGE, AGAF, Department of Gastroenterology, Postgraduate Institute of Medical Education and Research (PGIMER), Chandigarh 160012, India (e-mail: drsurinderrana@gmail.com).

J Digest Endosc 2022;13:82–88.

Abstract

Keywords

- ▶ endoscopic ultrasound
- ▶ stent
- ▶ biliary drainage
- ▶ endoscopic retrograde cholangiopancreatography

Endoscopic ultrasound-guided biliary drainage (EUS-BD) has a potential risk of clinically significant adverse events including fatal complications. Learning from complications improves the results from interventional procedures especially the high-risk procedure like EUS-BD. The various complications that have been reported following EUS-BD include bile leak, bleeding, cholangitis, peritonitis, stent migration both internal and external as well as in the peritoneal cavity and fatal perforations. In this technical review, we discuss technical strategies to prevent serious adverse events during EUS-BD using a case based approach.

Introduction

Endoscopic ultrasound-guided biliary drainage (EUS-BD) is a relatively recently developed EUS-guided intervention for BD in patients with biliary obstruction. Improvements in accessories and stents have led to gradual improvement in its success rates and thus have led its emergence as a preferred rescue technique for gaining access to the biliary tree when endoscopic retrograde cholangiopancreatography (ERCP) fails either due to inability to selectively cannulate the bile duct, altered gastroduodenal anatomy, periampullary diverticulum, gastric outlet obstruction, or presence of duodenal stents obscuring the papilla.^{1,2} EUS-BD has several advantages including being minimally invasive procedure that can be performed in the same session after failed ERCP, drainage

of both intra as well as extra hepatic bile ducts being feasible and ability to achieve internal BD, thereby obviating the need of an external drainage catheter. These potential advantages as well as improvement in the endoscopic accessories and technique have led to EUS-BD being considered as a first-line BD modality in malignant biliary obstruction.³ Avoidance of post-ERCP pancreatitis is an attractive incentive of EUS-BD being the first-line management option for BD in malignant biliary obstruction.

Despite these advantages especially avoidance of post-ERCP pancreatitis, EUS-BD has a potential risk of clinically significant adverse events including fatal complications. Complications have been variably reported ranging from 3.4 to 38.6% of procedures with one meta-analysis reporting an adverse event rate of 17%.⁴ The various complications that

DOI <https://doi.org/10.1055/s-0042-1743519>.
ISSN 0976-5042.

© 2022. Society of Gastrointestinal Endoscopy of India. All rights reserved.

This is an open access article published by Thieme under the terms of the Creative Commons Attribution-NonDerivative-NonCommercial-License, permitting copying and reproduction so long as the original work is given appropriate credit. Contents may not be used for commercial purposes, or adapted, remixed, transformed or built upon. (<https://creativecommons.org/licenses/by-nc-nd/4.0/>)

Thieme Medical and Scientific Publishers Pvt. Ltd., A-12, 2nd Floor, Sector 2, Noida-201301 UP, India

have been reported include bile leak, bleeding, cholangitis, peritonitis, stent migration both internal and external as well as in the peritoneal cavity and fatal perforations.^{1,2,4} Development of procedure-specific accessories, use of metal stents especially lumen-apposing stents (LAMS) as well as coaxial cautery, and increasing procedural experience have led to decrease in postprocedure adverse events.^{5,6}

Despite all the advancements, EUS-BD has a prospect of many potential procedural life-threatening complications and on a time scale they can be viewed as inevitable. Despite being stressful and traumatizing for both the patient and endoscopist, procedural complications often provide a valuable learning experience. It is important to understand that perfection does not exist, and complications are an inherent part of intervention procedures, especially the newer interventions. Carefully studying the complications and the likely reasons for the same can help us in making necessary changes in the steps of the procedure as well as accessories and thus prevent recurrence of these complications. Learning from complications improves the results from interventional procedures especially the high-risk procedure like EUS-BD. In this technical review, we discuss technical strategies to prevent serious adverse events during EUS-BD using a case-based approach.

Bleeding

Case Report

A 62-year-old female presented with progressively increasing cholestatic jaundice of 6 weeks followed by fever of 5 days

duration. On evaluation, patient had obstructive jaundice with serum bilirubin of 30 mg/dL (direct bilirubin of 24 mg/dL). Contrast-enhanced computed tomography (CT) revealed a 40 × 35 mm hypodense mass lesion in the head of pancreas with encasement of both superior mesenteric artery and vein with loss of fat planes with duodenum. EUS revealed luminal obstruction in the first part of duodenum due to tumor infiltration and echoendoscope could not be negotiated across the narrowing. EUS-guided fine-needle biopsy from the mass lesion revealed features suggestive of adenocarcinoma. The duodenoscope could not be negotiated across the narrowing and therefore EUS-guided hepaticogastrostomy (EUS-HGS) was planned for providing palliative BD.

After obtaining an informed consent, the dilated biliary radicle in segment 3 was punctured using a 19G needle under EUS guidance. Immediately after puncturing the bile duct, extravasation of echogenic contents was noted in the biliary system and the aspirated bile was found to be hemorrhagic (→ Fig. 1). However, the active extravasation of blood on EUS stopped after few minutes, the needle aspirate became clear, and no major vessel in the needle track could be identified on EUS Doppler. Thereafter, 0.025-inch guide wire was negotiated into the biliary radicles. However, deep cannulation of the wire could not be achieved and wire was getting struck at the needle bevel. Therefore, with guide wire in place the needle was exchanged with a 6 Fr cystotome. Using electrocautery, the needle track was dilated and cystotome negotiated into the dilated biliary radicles. Thereafter, repeated attempts made to negotiate the guide

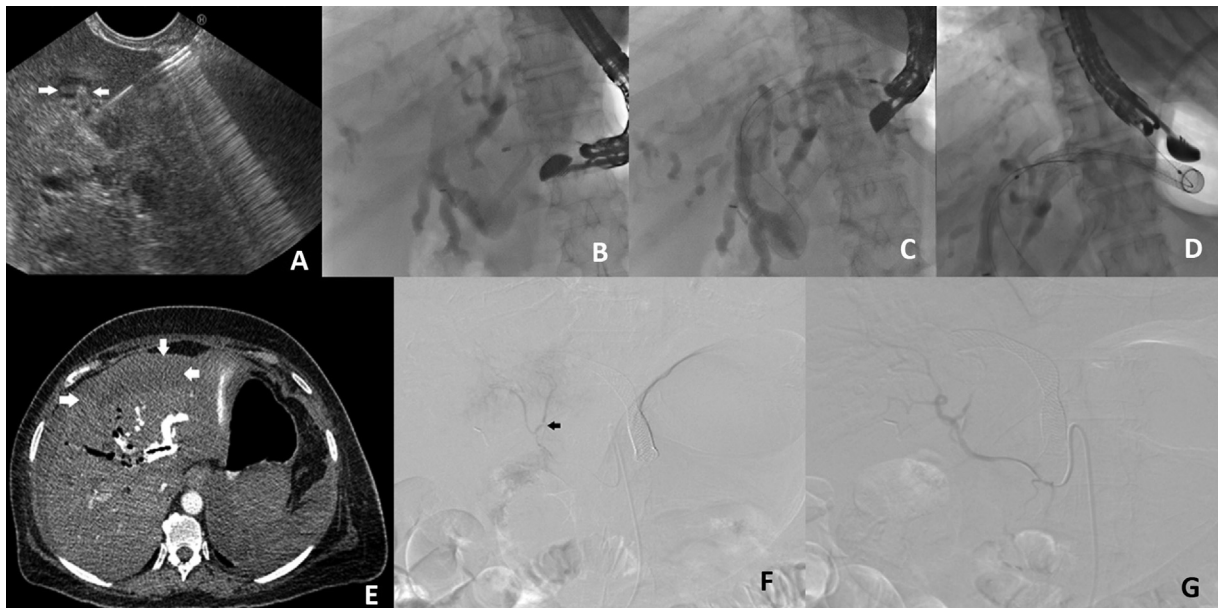


Fig. 1 Fatal bleeding after endoscopic ultrasound-guided hepaticogastrostomy (EUS HGS). (A) EUS: Immediately after puncturing the bile duct, extravasation of echogenic contents (arrow) noted in the dilated biliary system. The aspirated bile was found to be hemorrhagic. (B) The needle track was dilated and cystotome negotiated into dilated biliary radicles. However, guide wire could not be negotiated deep into the biliary system. (C) Second attempt for EUS HGS. The segment 2 liver punctured through the stomach. The guide wire negotiated deep into common bile duct and the tract dilated with 6Fr cystotome. (D) Fully covered metallic self-expanding metallic stents (80 × 10mm) inserted into the left ductal system. (E) Computed tomography abdomen: Large subcapsular hematoma (arrows) with pneumobilia. (F) Digital subtraction angiography: Selective cannulation of left hepatic artery (arrow) and prophylactic Gelfoam and polyvinyl alcohol embolization. (G) Digital subtraction angiography: Post-left hepatic artery embolization.

wire deep into the biliary system failed and the guide wire slipped out.

Following this, a second puncture of dilated biliary radicles from the segment 2 of liver from the stomach was done. After negotiating guide wire deep in the common bile duct (CBD), the track was dilated with a 6Fr cystotome and fully covered metallic self-expanding metallic stents (SEMS; 80 × 10mm, Wallflex, Boston Scientific, Natick, MA, USA) was inserted successfully. Immediate post-procedure, free flow of clear yellow colored bile was noted from the stent. Post-procedure ultrasound of the abdomen showed presence of pneumobilia and no subcapsular collection/hematoma was observed. However, 3 hours postprocedure, patient developed tachycardia with hemodynamic instability with significant drop in blood hemoglobin. Patient was resuscitated with crystalloids solution and blood transfusion. Urgent CT angiography showed large subcapsular hematoma without any active contrast extraversion (►Fig. 1). Patient continues to deteriorate rapidly despite all supportive management, requiring inotropic and ventilatory support. Patient underwent emergent digital subtraction angiography and no active contrast extravasation was seen. After selective cannulation of left hepatic artery, a prophylactic Gelfoam and polyvinyl alcohol embolization was performed. Despite these measures, patient continued to deteriorate and hence, was planned for surgical exploration. However, before surgery could be done patient succumbed to the illness.

Discussion

Bleeding is a dreaded complication of EUS-BD especially the procedures that involve the transhepatic biliary drainage (THBD) like EUS-HGS and EUS-guided antegrade stent placement.^{7,8} This increased risk of bleeding is due to the anatomy of the portal triad where the portal vein and hepatic artery lie in close proximity to the bile duct.⁹ This close proximity of the branches of the portal vein as well as hepatic artery to the needle track results in majority of bleedings during EUS-THBD occurring from either of these vessels. The portal vein radicles run alongside the bile duct radicles and can be occasionally missed even after using color Doppler guidance. The hepatic vein or its branches are rarely injured during EUS-THBD and bleeding from it occurs only in setting of significant hepatic injury and is usually accompanied with hepatic artery or portal vein injury.¹⁰

There is paucity of data that has evaluated the risk factors for post-EUS-THBD bleeding. However, as the procedure is technically similar to the percutaneous transhepatic biliary drainage (PTBD), its complications can be extrapolated to other similar THBD techniques like EUS-BD. Presence of coagulopathy or thrombocytopenia increases the risk of postprocedure bleeding and Society of Interventional Radiology has recommended that THBD procedures should be performed only when the international normalized ratio is <1.5 and the platelet count >50,000/mm³.¹¹ Puncture of nondilated biliary system also increases the risk of postprocedure bleeding because of increased tendency to puncture the central ducts that are accompanied with larger blood

vessels.¹² Other risk factors for increased bleeding after PTBD are advanced age, cirrhosis, renal failure, repeated needle passes, and use of larger gauge needle.^{13,14} EUS-BD usually involves use of 19G needles for puncture. However, in mildly dilated biliary systems a 22 G needle with a 0.018- or 0.021-inch guide wire should be considered.¹⁵ Use of electric cautery is also presumed to increase the risk of bleeding especially by causing “burn effect” to the surrounding vessels.¹⁶ This risk may be more pronounced in situations where the cystotome is used without achieving deep access of the guide wire into the biliary system, as was in the index case. This is because the deep access of the cystotome in the biliary tract is not confirmed. Use of covered SEMS for EUS-BD also decreases the risk of postprocedure bleeding by having a tamponade effect on the transmural tract. Multiple attempts at needle punctures increase the risk of bleeding by leaving the initial puncture tracts uncovered with metal stent as was in the index case. During the procedure if a blood vessel is accidentally punctured, the needle should be retracted back into the liver parenchyma and the stylet should be reinserted to push back the retained clot from inside the needle into the puncture tract and this may help in decreasing the risk of bleeding.¹⁵

In summary, the risk of bleeding following EUS-HGS can be reduced by following these tips:

1. Careful preprocedural evaluation for risk factors for increased bleeding.
2. Avoidance of puncture of blood vessels by a careful prepuncture EUS Doppler evaluation.
3. Use of cautery devices for tract dilatation only after securing a deep biliary access by the guide wire.
4. Avoidance of multiple punctures.
5. Avoidance of puncture of central biliary radicles as well as nondilated biliary system.

Acute Cholecystitis

Case Report

A 85-year-old male presented with progressively increasing cholestatic jaundice of 4 weeks duration. On evaluation, patient had obstructive jaundice with serum bilirubin of 24 mg/dL (direct bilirubin of 17 mg/dL). Contrast-enhanced CT revealed a 38 × 35 mm hypodense mass lesion in the head of pancreas. EUS-guided fine-needle biopsy from the mass lesion revealed features suggestive of adenocarcinoma. The patient's family was not willing for surgical resection and preferred palliative BD for relief of intractable pruritus. Selective biliary cannulation could not be achieved on ERCP and therefore EUS-guided choledochoduodenostomy (CDS) was planned for providing palliative BD.

After obtaining an informed consent, the dilated CBD was punctured from the duodenum using a 19G needle under EUS guidance (►Fig. 2). After confirming the location of needle tip by aspiration of bile, needle cholangiogram was obtained. Thereafter, a guide wire was negotiated deep into the biliary tree followed by dilatation of the transmural tract using a 6F cystotome (Endo-flex; Voerde, Germany). Following dilatation of the tract, a 6-cm fully covered SEMS

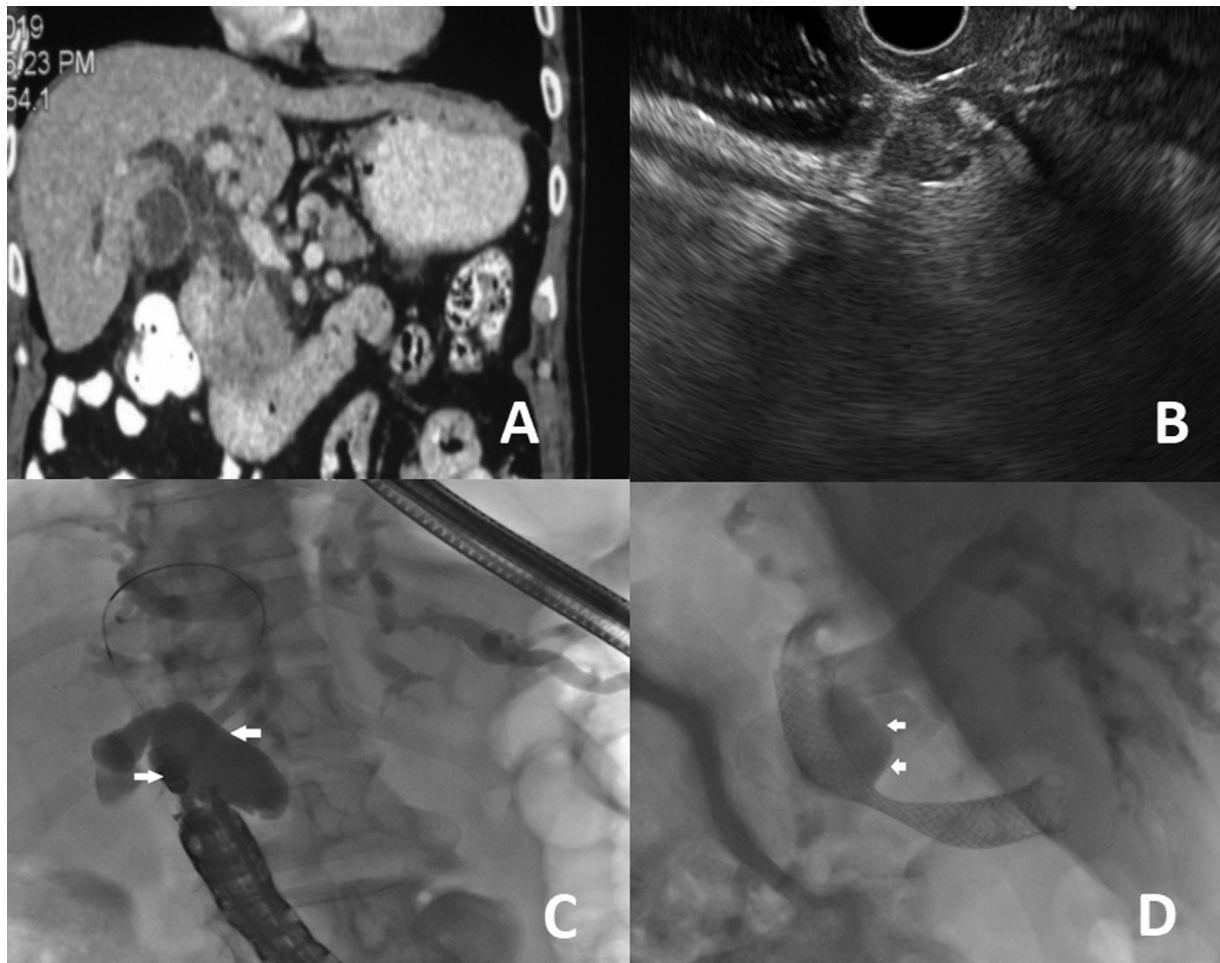


Fig. 2 Fatal acute cholecystitis post-endoscopic ultrasound-guided choledochoduodenostomy (EUS CDS). (A) Contrast-enhanced computed tomography abdomen: Mass in the head of pancreas causing lower common bile duct obstruction. (B) EUS CDS being performed. Guide wire negotiated deep into bile duct. (C) EUS CDS: Guide wire negotiated deep into left ductal system. Gallbladder filled with contrast noted (arrows). (D) Delayed emptying of contrast from the gallbladder (arrows).

(Wallflex; Boston Scientific) was deployed over the guide wire under fluoroscopic and endoscopic guidance. There were no immediate postprocedure complications and patient was discharged on oral antibiotics.

Patient presented 3 days later with hypotension accompanied with fever, chills, oliguria, and leucocytosis. Ultrasound of the abdomen revealed presence of pneumobilia and hugely distended gallbladder with echogenic contents. The patient was started on intravenous antibiotics and an emergent percutaneous cholecystostomy was performed. Despite these emergent measures, the patient clinical condition continued to deteriorate. Patient developed shock that was refractory to vasopressors and subsequently succumbed to the illness.

Discussion

Insertion of biliary stent can be associated with acute cholecystitis because of impairment of gallbladder ejection due to partial or complete obstruction of the cystic duct by the tumor progression or the covered metal stent.¹⁷ Kanno et al

reported acute cholecystitis in 4% of 99 patients who underwent EUS-BD.¹⁸ Acute cholecystitis, especially early cholecystitis seen within days of stent insertion, occurs due to occlusion of the cystic duct orifice by the covered stents used during EUS-CDS. Isayama et al studied the occurrence of acute cholecystitis after placement of transpapillary biliary stent in malignant biliary obstruction and reported that involvement of the cystic duct orifice by the tumor was an important risk factor for the development of postprocedure cholecystitis.¹⁹ They hypothesized that uninvolved cystic duct orifice is elastic and even if occluded by a covered stent, because of its elasticity, may allow space for drainage of bile from the gallbladder. Retention of the contrast agent in the gallbladder after the procedure is also considered as a predictive factor for the development of postprocedure cholecystitis.²⁰ It appears that bacterial translocation in to the biliary tree consequent to bilioduodenal stenting and retained contaminated contrast due to impaired gallbladder drainage due to partial or complete obstruction by stent or tumor or both leads to postprocedure acute cholecystitis.²¹ Presence of gallbladder stones has also been shown to be a

risk factor for the development of post-ERCP cholecystitis.^{17,21} Nakai et al have reported similar frequency of acute cholecystitis between patients who underwent endoscopic transpapillary BD using covered SEMS versus patients undergoing EUS-CDS using covered SEMS.²² This suggests that blockade of cystic duct orifice by the covered stent is an important mechanism for the development of acute cholecystitis following endoscopic BD.

Nakai et al reported that a SEMS with a high axial force is an important risk factor for the development of acute cholecystitis.²³ Ogura et al suggested that since the CBD that is stented in EUS-CDS is shorter in length as compared with bile duct that is stented in ERCP, the axial force generated by stent will be higher resulting in increased risk of cholecystitis due to blockade of cystic duct orifice by the covered stent.²⁴ Recently, LAMS have also been used in EUS-CDS. LAMS are shorter in length and therefore, there would be less chances of stent kinking and consequent cystic duct blockade. However, a recent meta-analysis comparing the efficacy and

safety of LAMS and SEMS for EUS-CDS has reported similar pooled rates of adverse events.²⁵

Acute cholecystitis is an unpredictable complication occurring after placement of a covered SEMS during EUS-CDS and placement of stent away from the cystic duct orifice seems to be the best intervention that will avoid this complication.²⁶ However, this may not be always possible because of lower cystic duct insertion or involvement of its orifice with malignant growth. Endoscopic transpapillary gallbladder stenting has been reported as an effective strategy to reduce the risk of acute cholecystitis following placement of transpapillary biliary covered SEMS placement.²⁷ However, in situation where EUS-CDS has been done, it may not be possible to do transpapillary gallbladder stenting as EUS-CDS is done in situations where transpapillary access to bile duct is not feasible. An alternative strategy to mitigate the risk of acute cholecystitis following endoscopic BD is to use partially covered metal stent with a proximal uncovered flared end or half covered metal stent.²⁸ Following

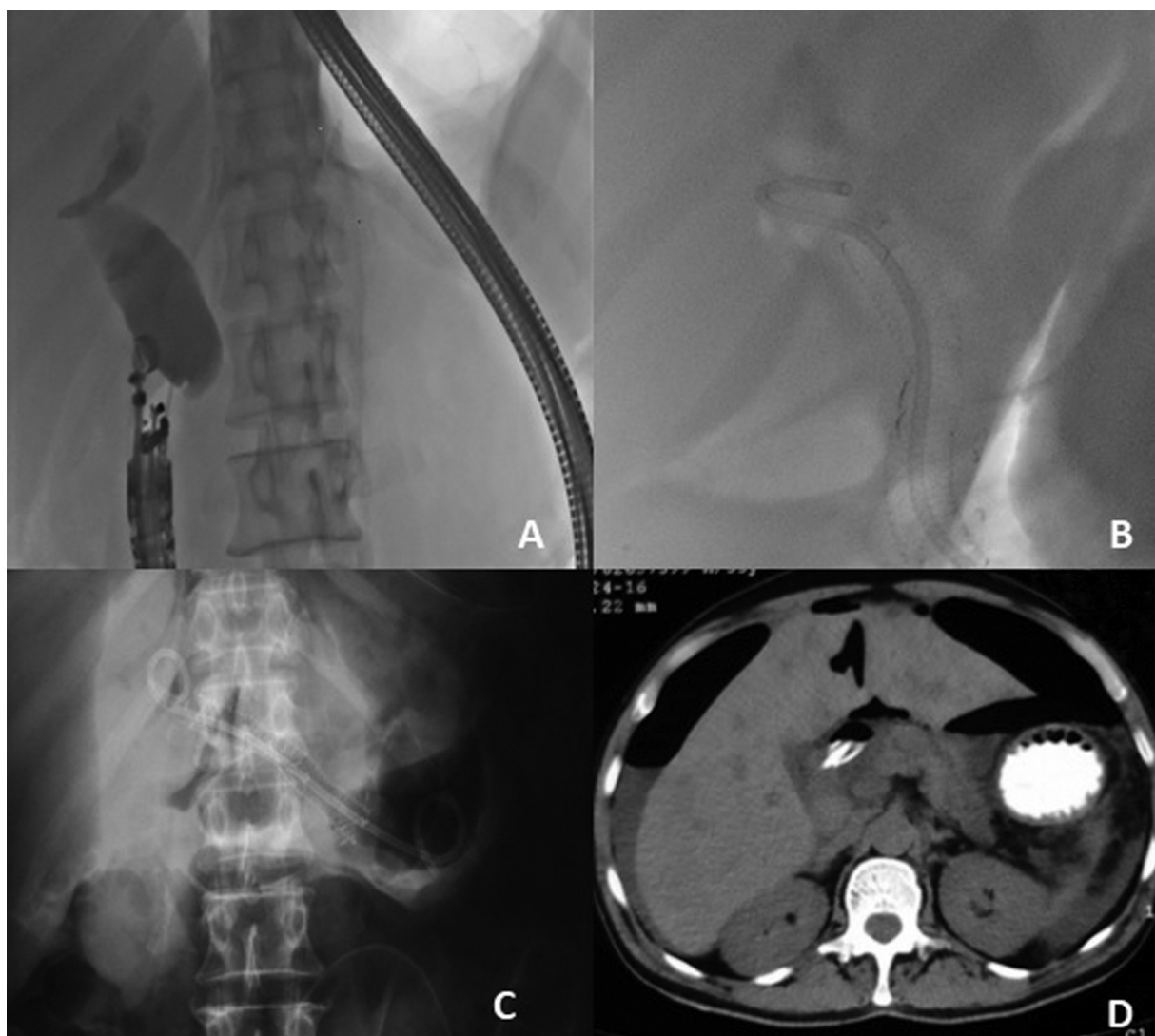


Fig. 3 Distal migration of partially covered self-expanding metallic stents (SEMS) causing bile and duodenal leak. (A) Endoscopic ultrasound (EUS)-guided needle puncture of the bile duct. The contrast-filled common bile duct is dilated. (B) EUS-guided partially covered SEMS placed in the bile duct. A double pigtail plastic stent through the SEMS to prevent migration. (C) Distal migration of the SEMS. (D) Contrast-enhanced computed tomography abdomen: Distally migrated stent leading on to pneumoperitoneum.

transpapillary BD, the uncovered end of the partially covered stent theoretically with their open interstices would allow for adequate drainage for the gallbladder to avoid cholecystitis.²⁹ Moreover, the partially covered stents have lower risk of migration as compared with fully covered metal stents.³⁰ However, the use of partially covered SEMs in EUS-CDS requires precise deployment of the uncovered part in the bile duct and its distal migration into the duodenum would lead on to uncovered part of the stent covering the choledochoduodenal fistula leading on to leakage of both the bile and duodenal contents. Therefore, partially covered stents have been infrequently used during EUS-CDS.³¹ Rai et al used partially covered SEMs for EUS-CDS in 30 patients and none of these patients developed acute cholecystitis.³² Also, none of these 30 patients had stent migration with bile leak being observed in only one patient. However, in our experience, there is considerable risk of maldeployment or migration of the uncovered part into the transmural tract leading on to bile leak (►Fig. 3) and therefore, we prefer, using fully covered SEMs for EUS-CDS.

In summary, there is no safe and effective strategy to prevent development of acute cholecystitis following EUS-CDS. Careful preprocedure evaluation of cross-sectional imaging should be done to ascertain the location of insertion of cystic duct into the CBD as well as exclude involvement of cystic duct orifice by the malignancy. Patients with low insertion of cystic duct as well as involvement of cystic duct orifice by malignancy are at high risk of development of postprocedure acute cholecystitis. Retention of contrast in the gallbladder following EUS-CDS is also considered as a predictive factor for the development of acute cholecystitis. Patients with above-mentioned risk factors should be kept under close observation for the development of acute cholecystitis following EUS-CDS and should promptly undergo gallbladder drainage if acute cholecystitis develops.

Other Complications of EUS-Guided Biliary Drainage

Gastrointestinal tract perforation is a rare complication that can occur during EUS-BD due to various reasons including failure of stent deployment after dilatation of the transmural tract, double mucosal puncture during EUS-CDS, and stent migration.³³ Double mucosal puncture is a rare complication that can occur during EUS-CDS and therefore puncture should be avoided when a double mucosal line is visualized on EUS. If there is a doubt about double mucosal puncture, endoscopic view of the guide wire should be looked at before dilating the transmural tract.³³ Stent placement through a double mucosal puncture can lead on to duodenal perforation. Cholangitis can also occur after EUS-BD and it is usually a late complication and occurs due to the stent blockade. Early cholangitis can be seen after EUS-HGS due to blockade of the bile duct radicles by the covered part of stent, and therefore partially covered metal stents are being used for EUS-HGS with uncovered part being inserted in the biliary system.^{31,33}

As discussed above, stent migration is also an important concern with EUS-BD as there is a no stricture to hold the stent in position. Various modifications like use of flaps or anchoring system on covered stents or placing pigtail stents through the covered SEMs have been used to decrease the risk of migration.³³ Various new stents for EUS-BD are being designed and reported with encouraging results but the search for an ideal stent still continues.³⁴

Conclusions

EUS-BD is a challenging endoscopic intervention that is associated with risk of significant adverse effects and therefore should be performed by experts at centers with an expert surgical as well as radiological back up. Bleeding, bile leak, perforation, stent migration, and development of postprocedure acute cholecystitis are important and potentially fatal complications that can develop post-EUS-BD. Adequate training in interventional EUS, comprehensive knowledge about the technical aspects of procedure as well as risk factors that predict complications and prompt recognition as well as treatment of complications are key components of successful EUS-BD.

Authors' Contributions

Surinder Singh Rana was involved in drafting of manuscript and collection and analysis of data. Jimil Shah contributed in collection of data and drafting of manuscript. Harish Bhujade, Ujjwal Gors, Mandeep Kang, and Rajesh Gupta were involved in collection of data.

Finding

No funding.

Conflict of Interest

None declared.

References

- 1 Hatamaru K, Kitano M. EUS-guided biliary drainage for difficult cannulation. *Endosc Ultrasound* 2019;8(Suppl 1):S67–S71
- 2 Baars JE, Kaffes AJ, Saxena P. EUS-guided biliary drainage: a comprehensive review of the literature. *Endosc Ultrasound* 2018;7(01):4–9
- 3 Kakked G, Salameh H, Cheesman AR, Kumta NA, Nagula S, DiMaio CJ. Primary EUS-guided biliary drainage versus ERCP drainage for the management of malignant biliary obstruction: a systematic review and meta-analysis. *Endosc Ultrasound* 2020;9(05): 298–307
- 4 Khan MA, Akbar A, Baron TH, et al. Endoscopic ultrasound-guided biliary drainage: a systematic review and meta-analysis. *Dig Dis Sci* 2016;61(03):684–703
- 5 Poincloux L, Rouquette O, Buc E, et al. Endoscopic ultrasound-guided biliary drainage after failed ERCP: cumulative experience of 101 procedures at a single center. *Endoscopy* 2015;47(09): 794–801
- 6 Lyu Y, Li T, Cheng Y, Wang B, Cao Y, Wang Y. Endoscopic ultrasound-guided vs ERCP-guided biliary drainage for malignant biliary obstruction: a up-to-date meta-analysis and systematic review. *Dig Liver Dis* 2021;53(10):1247–1253

- 7 Ogura T, Higuchi K. Endoscopic ultrasound-guided hepaticogastrostomy: technical review and tips to prevent adverse events. *Gut Liver* 2021;15(02):196–205
- 8 Ogura T, Higuchi K. Technical review of developments in endoscopic ultrasound-guided hepaticogastrostomy. *Clin Endosc* 2021;54(05):651–659
- 9 Quencer KB, Tadros AS, Marashi KB, et al. Bleeding after percutaneous transhepatic biliary drainage: incidence, causes and treatments. *J Clin Med* 2018;7(05):7
- 10 Saad WE, Davies MG, Darcy MD. Management of bleeding after percutaneous transhepatic cholangiography or transhepatic biliary drain placement. *Tech Vasc Interv Radiol* 2008;11(01):60–71
- 11 Patel IJ, Davidson JC, Nikolic B, et al; Standards of Practice Committee, with Cardiovascular and Interventional Radiological Society of Europe (CIRSE) Endorsement. Consensus guidelines for periprocedural management of coagulation status and hemostasis risk in percutaneous image-guided interventions. *J Vasc Interv Radiol* 2012;23(06):727–736
- 12 Weber A, Gaa J, Rosca B, et al. Complications of percutaneous transhepatic biliary drainage in patients with dilated and non-dilated intrahepatic bile ducts. *Eur J Radiol* 2009;72(03):412–417
- 13 Liu YS, Lin CY, Chuang MT, Tsai YS, Wang CK, Ou MC. Success and complications of percutaneous transhepatic biliary drainage are influenced by liver entry segment and level of catheter placement. *Abdom Radiol (NY)* 2018;43(03):713–722
- 14 Fidelman N, Bloom AI, Kerlan RK Jr, et al. Hepatic arterial injuries after percutaneous biliary interventions in the era of laparoscopic surgery and liver transplantation: experience with 930 patients. *Radiology* 2008;247(03):880–886
- 15 Chantarojanasiri T, Ratanachu-Ek T, Pausawasdi N. What you need to know before performing endoscopic ultrasound-guided hepaticogastrostomy. *Clin Endosc* 2021;54(03):301–308
- 16 Honjo M, Itoi T, Tsuchiya T, et al. Safety and efficacy of ultratapered mechanical dilator for EUS-guided hepaticogastrostomy and pancreatic duct drainage compared with electrocautery dilator (with video). *Endosc Ultrasound* 2018;7(06):376–382
- 17 Suk KT, Kim HS, Kim JW, et al. Risk factors for cholecystitis after metal stent placement in malignant biliary obstruction. *Gastrointest Endosc* 2006;64(04):522–529
- 18 Kanno Y, Koshita S, Ogawa T, et al. EUS-guided biliary drainage for unresectable malignant biliary obstruction: 10-year experience of 99 cases at a single center. *J Gastrointest Cancer* 2019;50(03):469–477
- 19 Isayama H, Kawabe T, Nakai Y, et al. Cholecystitis after metallic stent placement in patients with malignant distal biliary obstruction. *Clin Gastroenterol Hepatol* 2006;4(09):1148–1153
- 20 Kim GH, Ryoo SK, Park JK, et al. Risk factors for pancreatitis and cholecystitis after endoscopic biliary stenting in patients with malignant extrahepatic bile duct obstruction. *Clin Endosc* 2019;52(06):598–605
- 21 Ting P-H, Luo J-C, Lee K-C, et al. Post endoscopic retrograde cholangiopancreatography cholecystitis: the incidence and risk factors analysis. *J Chin Med Assoc* 2020;83(08):733–736
- 22 Nakai Y, Isayama H, Kawakami H, et al. Prospective multicenter study of primary EUS-guided choledochoduodenostomy using a covered metal stent. *Endosc Ultrasound* 2019;8(02):111–117
- 23 Nakai Y, Isayama H, Kawakubo K, et al. Metallic stent with high axial force as a risk factor for cholecystitis in distal malignant biliary obstruction. *J Gastroenterol Hepatol* 2014;29(07):1557–1562
- 24 Ogura T, Nishioka N, Yamada M, Yamada T, Higuchi K. Comparison study between double bare covered and fully covered metal stent during endoscopic ultrasound-guided choledochoduodenostomy (with video). *Dig Dis* 2021;39(02):165–170
- 25 Amato A, Sinagra E, Celsa C, et al. Efficacy of lumen-apposing metal stents or self-expandable metal stents for endoscopic ultrasound-guided choledochoduodenostomy: a systematic review and meta-analysis. *Endoscopy* 2020
- 26 Kahaleh M, Tokar J, Conaway MR, et al. Efficacy and complications of covered Wallstents in malignant distal biliary obstruction. *Gastrointest Endosc* 2005;61(04):528–533
- 27 Gosain S, Bonatti H, Smith L, et al. Gallbladder stent placement for prevention of cholecystitis in patients receiving covered metal stent for malignant obstructive jaundice: a feasibility study. *Dig Dis Sci* 2010;55(08):2406–2411
- 28 Takaoka M, Shimatani M, Ikeura T, et al. Usefulness of half-covered metallic stent placement in preventing acute cholecystitis complication in pancreatic cancer-induced distal biliary stricture. *JGH Open* 2020;4(06):1140–1145
- 29 Saxena P, Singh VK, Lennon AM, Okolo PI, Kallou AN, Khashab MA. Endoscopic management of acute cholecystitis after metal stent placement in patients with malignant biliary obstruction: a case series. *Gastrointest Endosc* 2013;78(01):175–178
- 30 Yokota Y, Fukasawa M, Takano S, et al. Partially covered metal stents have longer patency than uncovered and fully covered metal stents in the management of distal malignant biliary obstruction: a retrospective study. *BMC Gastroenterol* 2017;17(01):105
- 31 Itoi T, Isayama H, Sofuni A, et al. Stent selection and tips on placement technique of EUS-guided biliary drainage: transduodenal and transgastric stenting. *J Hepatobiliary Pancreat Sci* 2011;18(05):664–672
- 32 Rai P, Lokesh CR, Goel A, Aggarwal R. Endoscopic ultrasound-guided choledochoduodenostomy using partially-covered self-expandable metal stent in patients with malignant distal biliary obstruction and unsuccessful ERCP. *Endosc Int Open* 2018;6(01):E67–E72
- 33 Isayama H, Nakai Y, Yamamoto N, et al. Endoscopic ultrasound-guided biliary drainage: Complications and their management. *Int J Gastrointest Interv* 2017;6:114–117
- 34 Ogura T, Ueno S, Okuda A, et al. Technical feasibility and safety of one-step deployment of EUS-guided hepaticogastrostomy using an 8-mm diameter metal stent with a fine-gauge stent delivery system (with video). *Endosc Ultrasound* 2021;10(05):355–360