



Arthroscopic Hemitrapezectomy and Suspension with Mini TightRope for the Treatment of Rhizarthrosis: Outcome in patients in stages Eaton-Littler 2 to 3

Hemitrapezectomía artroscópica y suspensión con Mini TightRope para el tratamiento de la rizartrrosis: Resultados en pacientes en estadios 2 a 3 de Eaton-Littler

René Jorquera^{1,2,3} Pablo Orellana³ Francisco Melibosky³ Eduardo Paz⁴ Rodrigo Liendo⁵
Camila Azócar^{3,6}

¹ IWAS Faculty, IWC, Chile

² Department of Traumatology and Orthopedics, Facultad de Medicina, Universidad Andrés Bello, Santiago de Chile, Chile

³ Hand – Microsurgery and Arthroscopy Team, Department of Traumatology and Orthopedics, Clínica Indisa, Santiago de Chile, Chile

⁴ Clínica Indisa, IWAS, IWC INDISA, Chile

⁵ Department of Traumatology and Orthopedics, Escuela de Medicina, Pontificia Universidad Católica de Chile, Santiago de Chile, Chile

⁶ Department of Traumatology, Facultad de Medicina, Universidad de Chile, Chile

Address for correspondence Camila Azócar, MD, Avenida Santa María 1.810, Providencia, Santiago de Chile, Chile
(e-mail: camiazocars@gmail.com).

Rev Iberam Cir Mano 2022;50(1):e12–e18.

Abstract

Keywords

- ▶ rhizarthrosis
- ▶ arthroscopy
- ▶ basilar thumb arthritis
- ▶ Level of evidence: IV

Introduction Rhizarthrosis is a common cause of pain and impaired function of the hand. Most patients present an excellent response to the conservative treatment, although a small percentage requires a surgical procedure due to the persistence of symptoms. Different surgical procedures have been described; however, there is still no consensus in the literature regarding the superiority of one technique over the others. **Objective** To evaluate the clinical and radiological results of patients with a diagnosis of rhizarthrosis in stages 2 to 3 of the Eaton-Littler classification, submitted to arthroscopic hemitrapezectomy and suspension with Mini TightRope (Arthrex, Naples, FL, US).

Materials and methods We conducted a retrospective evaluation of the clinical and radiological results of patients operated on through the technique proposed in Clínica INDISA, in Santiago, Chile, between 2017 and 2019. The pre- and postsurgical assessments were performed using the visual analog scale (VAS) for pain, the

Nivel de evidencia: IV

received
May 17, 2021
accepted after revision
November 18, 2021

DOI <https://doi.org/10.1055/s-0042-1743512>.
ISSN 1698-8396.

© 2022. SECMA Foundation. All rights reserved.
This is an open access article published by Thieme under the terms of the Creative Commons Attribution-NonDerivative-NonCommercial-License, permitting copying and reproduction so long as the original work is given appropriate credit. Contents may not be used for commercial purposes, or adapted, remixed, transformed or built upon. (<https://creativecommons.org/licenses/by-nc-nd/4.0/>)
Thieme Revinter Publicações Ltda., Rua do Matoso 170, Rio de Janeiro, RJ, CEP 20270-135, Brazil

Disabilities of the Arm, Shoulder, and Hand (DASH) questionnaire, and the Kapandji score. The state of the articular cartilage was also evaluated intraoperatively according to the Badia classification.

Results A total of 12 patients (3 men and 9 women) met the inclusion criteria. Their mean age was 56 years, the mean duration of the follow-up was of 21 months. There were 7 patients in stage 2 and 5 in stage 3 according to the Eaton-Littler classification. Intraoperatively, there were 6 patients in stage II and 6 in stage III of the Badia classification. The mean preoperative score on the Kapandji index was of 3.6, and the mean postoperative score was of 9. The mean preoperative score on the VAS was of 8.8, and the mean postoperative score was of 1.2. The mean preoperative score on the DASH was of 33.3, and the mean postoperative score was of 4.7.

Conclusion Arthroscopic and suspension hemitrapeziectomy with Mini TightRope for the treatment of stage 2-3 rhizarthrosis is a minimally-invasive, reproducible technique, effective in reducing pain and improving function, with sustained effects on the short and middle terms (6 to 36 months).

Resumen

Introducción La rizartrrosis es una causa común de dolor y compromiso de la función de la mano. La mayoría de los pacientes responden de manera excelente al tratamiento conservador, aunque un pequeño porcentaje requieren algún tipo de procedimiento quirúrgico ante la persistencia de síntomas. Se han descrito diferentes procedimientos quirúrgicos; sin embargo, en la literatura aún no existe consenso respecto a la superioridad de una técnica sobre las demás.

Objetivo Evaluar los resultados clínicos y radiológicos de pacientes con diagnóstico de rizartrrosis, en estadios 2 a 3 de la clasificación de Eaton-Littler, operados con técnica de hemitrapeziectomía artroscópica y suspensión con Mini TightRope (Arthrex, Naples, FL, EEUU).

Materiales y métodos Se evaluaron retrospectivamente los resultados de pacientes operados con la técnica propuesta en la Clínica INDISA, en Santiago, Chile, entre 2017 y 2019. Las valoraciones pre y postquirúrgica se realizaron mediante la escala visual análoga (EVA) del dolor, el cuestionario de Discapacidades del Brazo, Hombro y Mano (Disabilities of the Arm, Shoulder, and Hand, DASH, en inglés) y el índice de Kapandji. También se evaluó el estado del cartílago articular en el intraoperatorio según la clasificación de Badia.

Resultados Un total de 12 pacientes (3 hombres y 9 mujeres) cumplieron con los criterios de inclusión. La edad promedio fue de 56 años, y el seguimiento medio, de 21 meses, y había 7 pacientes en el estadio 2 y 5 en el estadio 3 de Eaton-Littler. En el intraoperatorio, se clasificaron 6 pacientes como estadio II, y 6, como estadio III en la clasificación de Badia. Según el índice de Kapandji, la media prequirúrgica fue de 3,6 y la media postquirúrgica, de 9. La media prequirúrgica en la EVA fue de 8,8, y la postquirúrgica, de 1,2. La media del puntaje preoperatorio en el DASH fue de 33,3, y en el postoperatorio, de 4,7.

Conclusión La hemitrapeziectomía artroscópica y suspensión con Mini TightRope para el tratamiento de la rizartrrosis en estadios 2 a 3 es una técnica mínimamente invasiva, reproducible, y efectiva en disminuir el dolor y mejorar la función, con efectos mantenidos a corto y mediano plazos (6 a 36 meses).

Palabras clave

- rizartrrosis
- artroscopia
- artrosis basilar del pulgar

Introduction

Rhizarthrosis, or osteoarthritis of the trapeziometacarpal (TMC) joint, is a common condition. It mainly affects post-

menopausal women, with a prevalence higher than 33% in this subgroup.¹⁻⁶

Although the radiological presence of signs of osteoarthritis at the TMC joint increases with age, reaching 90% in

patients older than 80 years of age,⁵ more than 70% of the cases are asymptomatic and require no treatment.^{4,7} Patients generally present pain at the base of the thumb, limited mobility, grip weakness, and deformity.⁸ These symptoms can progress, generating significant hand dysfunction and altering daily life activities.⁹

Medical management is the first line of therapy, and it is usually sufficient for adequate symptom control. Surgical treatment is indicated in patients with disabling pain and minimal response to the medical treatment.^{5-7,10,11}

Although multiple surgical techniques have been described, currently there is no consensus on the superiority of a method to treat patients with Eaton-Littler stage-II and -III rhizarthrosis.^{6,12,13} Arthroscopic assistance has emerged in recent years as a tool to treat this pathology.¹⁴⁻¹⁸

The present study aims to evaluate the clinical and radiological outcomes of patients with Eaton-Littler stage-II and III rhizarthrosis submitted to arthroscopic hemitrapeziectomy and suspension with Mini TightRope (Arthrex, Naples, FL, US).

Materials and Methods

The present is a retrospective observational study of clinical and imaging records. The inclusion criteria were adult patients with Eaton-Littler stage-II and -III rhizarthrosis submitted to arthroscopic hemitrapeziectomy with Mini TightRope suspension from January 2017 to December 2019 performed by staff surgeons from Clínica Indisa, in Santiago, Chile. The patients should have had the condition for at least 6 months with no response to the conservative treatment. Patients with less than 6 months of postoperative follow-up were excluded, along with those with a history of ipsilateral surgery and evidence of scaphoid-trapezium-trapezoid (STT) joint involvement in preoperative or intraoperative images at the time of the mediocarpal arthroscopy.

Demographic data (gender and age) were evaluated. The preoperative study consisted of bilateral radiographs of the hand and thumb, pain assessment using the visual analog scale (VAS), and functional evaluation with the Disabilities of the Arm, Shoulder, and Hand (DASH) questionnaire and the Kapandji score.¹⁹ This evaluation was repeated six months after surgery, and the time until return to work was assessed. The articular cartilage was analyzed intraoperatively according to the Badia classification.²⁰

The statistical analysis consisted of the Shapiro-Wilk test to evaluate data normality, with negative results for the variables of age, VAS, DASH, Kapandji, and return to work. The Wilcoxon and Mann-Whitney tests were used for non-parametric values. The analysis was performed using the STATA (StataCorp LLC, College Station, TX, US) software, version 15. Significance was set at $p < 0.05$.

Surgical technique

1. Patient positioning: the patient was placed in the supine position on the surgical table with limb support on an auxiliary table. The procedure was performed under regional anesthesia, using an ischemia cuff at 250 mmHg adjusted per the patient's blood pressure. Vertical

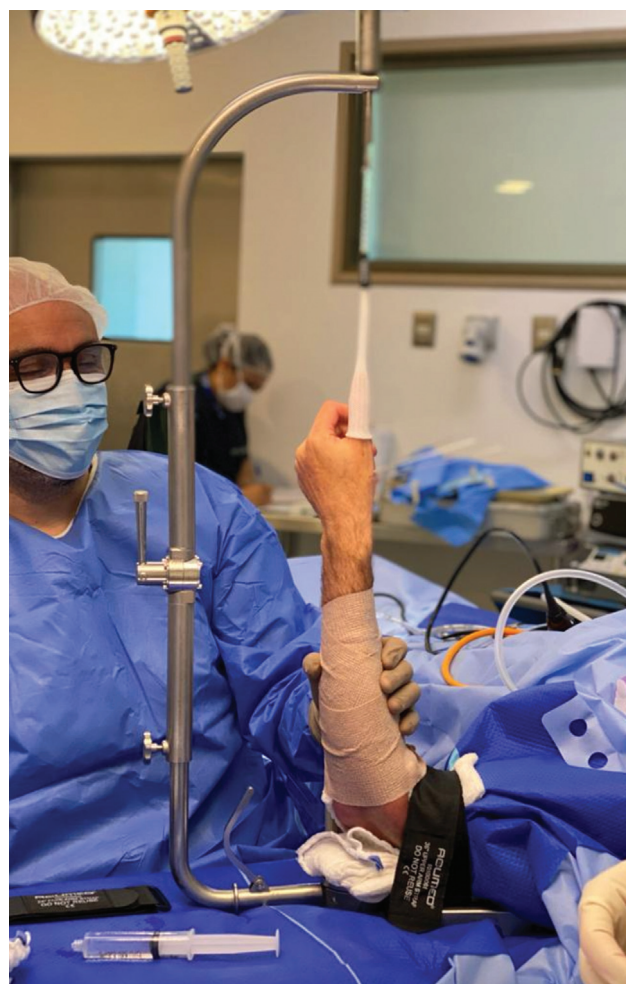

Fig. 1 Patient positioning.

traction of 4 Kg was applied to the thumb using Chinese finger traps (**► Fig. 1**).

2. Arthroscopic portals and diagnostic arthroscopy: the TMC joint was located through superficial palpation. The radial portal (1R) was opened, followed by joint distension with 5 mL of saline solution. The portal to introduce the 2.7-mm optic in a 30° angle was opened, and the ulnar portal (1U) was prepared under arthroscopic visualization (1U) (**► Fig. 2**). Arthroscopy of the TMC joint confirmed the diagnosis.
3. Assessment of the STT joint: under full wrist traction, a radial midcarpal portal (RCM) was established, allowing STT joint visualization and the determination of its integrity (**► Fig. 3**). If degenerative changes are observed in the STT, the surgical indication should be changed to total trapeziectomy. That is why we consider this a critical stage of the surgery.
4. Hemitrapeziectomy: partial trapezius resection was performed with a 2.9-mm drill in alternating portals. A hybrid (dry and wet) arthroscopy was required for adequate resection without risk of thermal damage from drilling, including to the instruments. Medial osteophyte resection must be adequate, since it is highly variable among patients. Resection of 50% of the height of the

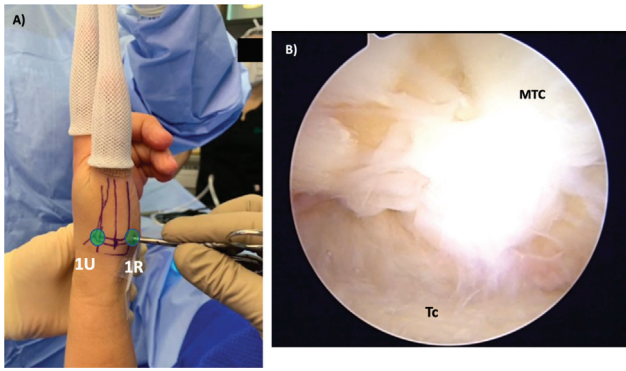


Fig. 2 Arthroscopic portals (A) and diagnostic arthroscopy of the trapeziometacarpal joint (B). Abbreviations: MTC, metacarpal; Tc, trapezium.

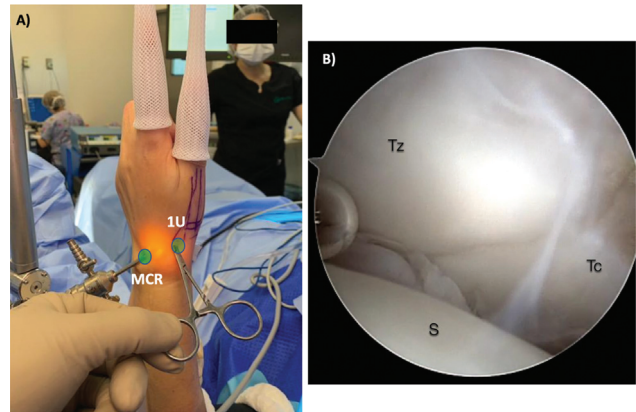


Fig. 3 Diagnostic arthroscopy of the scaphoid-trapezium-trapezoid (STT) joint using a radial midcarpal (RCM) portal. (A) Arthroscopic portals. (B) Arthroscopic view of the STT. Abbreviations: S, scaphoid; Tz, trapezoid; Tc, trapezium.

trapezium is performed because, with it, the main author has observed the best subjective clinical outcomes in his patients; in addition, along with osteophyte resection, this procedure decreases the rates of impingement (►Fig. 4).

5. Mini TightRope implantation: traction was removed and, under fluoroscopy, the Mini TightRope guide passed obliquely from the base of the first metacarpal bone through the 1R portal towards the proximal metaphyseal-diaphyseal junction of the second metacarpal bone (►Fig. 5). Finally, the Mini TightRope system buttons were installed, beginning with the button at the base of the first metacarpal bone, respecting the anatomical structures of the area, and then tying the system with the button at the level of the second metacarpal bone. We carried out this step under fluoroscopic assistance and interposing a curved mosquito clamp to avoid overloading the system, which would result in an impingement as a complication (►Fig. 6).
6. Closure and postoperative care: the portals were closed, and a bulky soft bandage was placed with no immobilization. Limb rest with a sling was indicated. On the

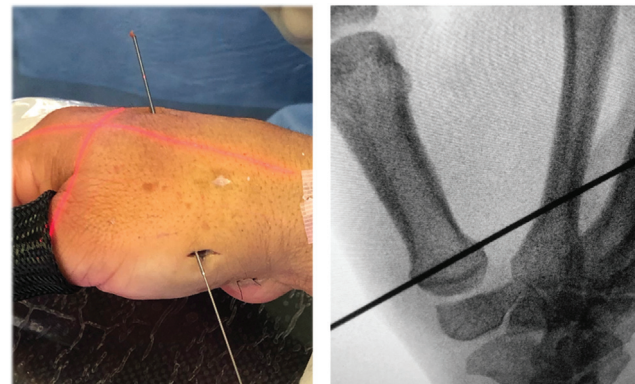


Fig. 5 Implantation of the Mini TightRope.

third postoperative day, active and passive exercises started with directed kinesiology. The sutures were removed at two weeks, followed by serial follow-up visits.

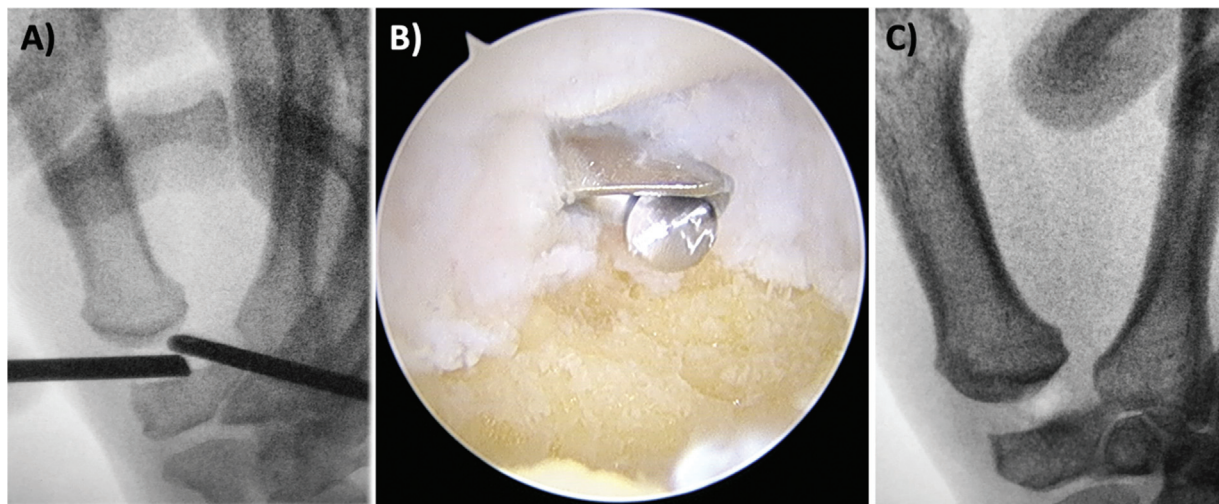


Fig. 4 Arthroscopic hemitrapeziectomy. (A) Intraoperative fluoroscopic view with optics at the radial (1R) portal and burr at the ulnar (1U) portal. (B) Arthroscopic view of the partial resection of the trapezium with a burr. (C) Intraoperative fluoroscopic view of the outcome of the hemitrapeziectomy.

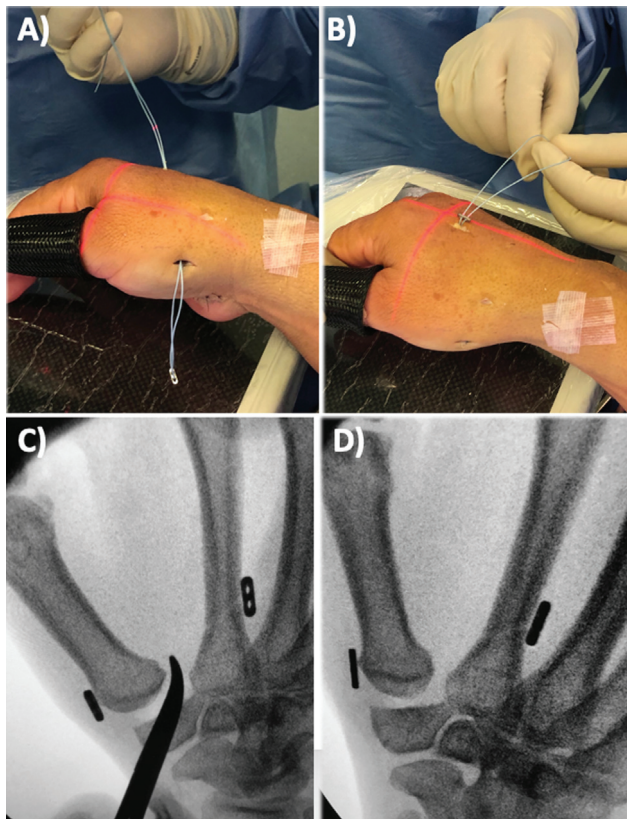


Fig. 6 Assembly of the Mini TightRope system. (A) Button implantation at the base of the first metacarpal bone. (B) Implantation of the second button at the level of the proximal third of the second metacarpal bone, and closure of the system with a knot at this level. (C) Interposition of a curved mosquito clamp to avoid overload. (D) Fluoroscopic result of the system.

Results

The mean follow-up period was of 21 months (range: 6 to 36 months). The patients were classified according to the Eaton-Littler¹⁶ classification based on preoperative radiographs; 7 patients were in stage 2, and 5 patients, in stage 3.

During surgery, the patients were classified according to the arthroscopic findings described by Badia;²⁰ six patients were in stage II, and six patients, in stage III.

The mean preoperative pain was of 8.8 (range: 7 to 10) on the VAS, and it decreased to 1.2 (range: 0 to 3) at 6 months postoperatively ($p = 0.000$). The mean preoperative DASH score was of 33.3 (range, 16 to 57), which decreased to 4.7 (range: 2 to 11) 6 months postoperatively ($p = 0.000$). The Kapandji score improved from an average of 3.6 (range: 1 to 6) to 8.8 (range: 7 to 10) in the postoperative period ($p = 0.001$). ► **Graphs 1, 2, and 3** show these results.

*valor de $p = 0,000 = *p\text{-value} = 0.00$

EVA = VAS

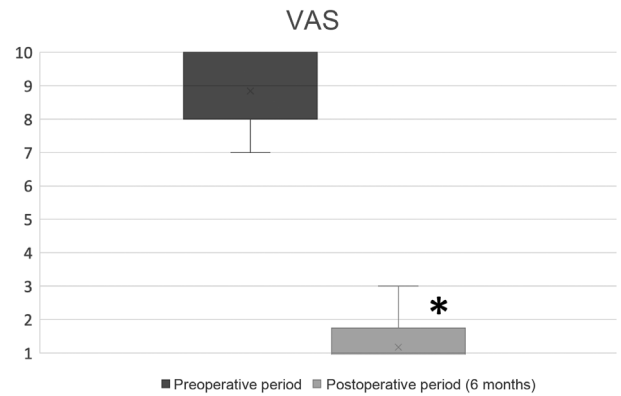
Preoperatorio = Preoperative period

Postoperatorio (6 meses) = Postoperative period (6 months)

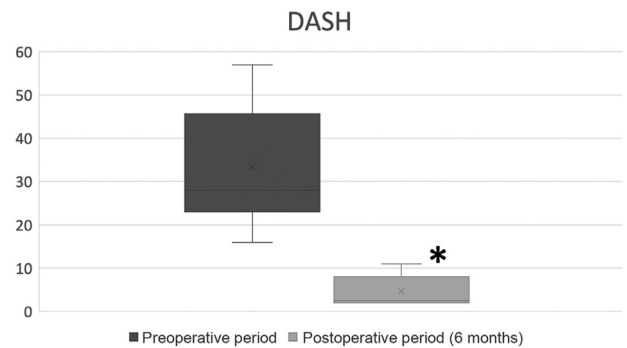
*valor de $p = 0,000 = *p\text{-value} = 0.00$

DASH = DASH

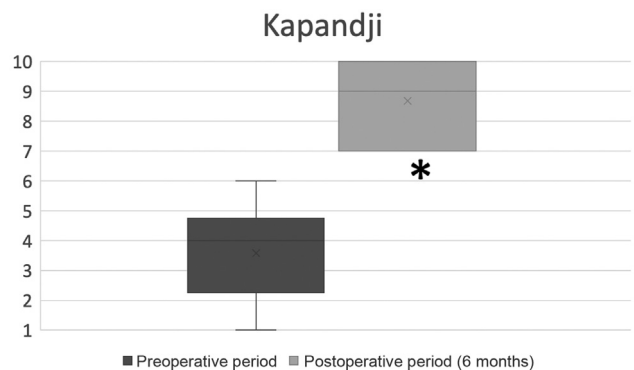
Preoperatorio = Preoperative period



Graph 1 Pain according to the visual analog scale (VAS) in the pre- and postoperative periods.



Graph 2 Pre- and postoperative scores on the Disabilities of the Arm, Shoulder, and Hand (DASH) questionnaire.



Graph 3 Kapandji score in the pre- and postoperative periods.

Postoperatorio (6 meses) = Postoperative period (6 months)

*valor de $p = 0,000 = *p\text{-value} = 0.00$

Kapandji = Kapandji

Preoperatorio = Preoperative period

Postoperatorio (6 meses) = Postoperative period (6 months)

The average time until return to work was of 9.2 weeks (range: 6 to 12 weeks); all patients resumed their previous work activities.

There was no complication in the immediate or late postoperative periods. No surgical reinterventions were required during the follow-up.

Discussion

In the present study, patients in stages 2 and 3 of the Eaton-Littler classification submitted to arthroscopic hemitrapeziectomy and suspension with Mini TightRope for rhizarthrosis presented a significant decrease in pain and improved function.

The advantages of arthroscopic techniques lie in the fact that they are minimally invasive, with lower damage to the soft tissues surrounding the joint, and higher ability to establish an accurate diagnosis⁸ of the actual stage of the patient. We believe that arthroscopy is critical for a correct joint evaluation, since preoperative, conventional imaging techniques may underestimate the presence of initial degenerative changes in both the TMC and STT joints.^{8,21,22}

In addition, arthroscopy enables an accurate evaluation of the STT joint, which is deemed essential. In patients with degenerative involvement of the STT joint, the technique proposed in the present study must be modified¹⁷ because STT osteoarthritis may result in persistent postoperative pain, compromising the clinical outcomes. The most indicated procedure for these patients is total trapeziectomy, either in an open or arthroscopic procedure. This fact encourages us to recommend the systematic evaluation of the STT as part of diagnostic arthroscopy, since this step is critical for correct staging. A potential modification to the intraoperative classification of Badia²⁰ would be the addition of a fourth stage to include patients with degenerative changes at the level of the STT joint.

The literature reports multiple surgical techniques for this type of patient; partial resection of the trapezius and suspension with buttons have been described in recent years with good medium- and long-term outcomes.^{17,18,23,24} The present series describes outcomes consistent with those found in the literature, and the technique used is deemed reproducible and effective for pain reduction and recovery of hand function.^{17,18,23,24} This technique reduces the probability of subsidence, a frequent long-term complication of total trapeziectomy, since it maintains the ligament support of the palmar and dorsal stabilizers; in addition, it enables the structural conservation of the anterior capsule and a thermal shortening with the shrinkage technique. The button system maintains the height of the first metacarpal.²⁵ Suspension with Mini TightRope enables the safe maintenance of the space and stable formation of scar fibrosis, reducing the complications associated with other similar techniques, such as those performed with Kirschner wires.

The potential complications of this technique include excessive tension on the button system, resulting in painful impingement, and/or the risk of narrowing the first intermetacarpal space, which would cause a significant decrease in postoperative function and poor clinical outcomes. This is

why we interpose the curved mosquito clamp, as detailed in the technique, to control the tension force when tying the system.

Another inherent complication of this technique is the risk of eccentric drilling, which can lead to an iatrogenic fracture. Thus, we suggest being extremely careful and checking the correct centralization of the guidewire over the metacarpal bones in multiple fluoroscopic planes.

We believe that hemitrapeziectomy and suspension with Mini TightRope is a good therapeutic alternative for patients in stages II and III of the Eaton-Littler classification, since it enables early rehabilitation with sustained symptom resolution and few complications.

The Mini TightRope device acts as an internal suspender and avoids subsidence, enabling early mobilization, early active rehabilitation, and a shorter time until the return to work, which is consistent with the literature. Even so, it is important to note that we did not evaluate the level of work activity, which would be interesting to describe in the future.

As a limitation of the present study, since this is a retrospective series with a small sample, we believe that it is imperative to carry out randomized prospective studies with larger samples and long-term follow-up to make a correct clinical recommendation. We believe that the present study shows relevant clinical outcomes because this is a reproducible technique, and it seems to be a good option for these patients.

Conclusion

Arthroscopic suspension hemitrapeziectomy with Mini TightRope is a reproducible technique and an effective therapeutic option to reduce pain and improve function in patients with rhizarthrosis in Eaton-Littler stages II and III. In addition, it enables an early return to work, with sustainable outcomes. Prospective studies with more patients are required for a clinical recommendation.

Informed Consent

The person in Figure 1 is one of the authors of this article. Informed consent was obtained.

Conflict of Interests

The authors have no conflict of interests to declare.

References

- 1 Dahaghin S, Bierma-Zeinstra SMA, Ginai AZ, Pols HAP, Hazes JMW, Koes BW. Prevalence and pattern of radiographic hand osteoarthritis and association with pain and disability (the Rotterdam study). *Ann Rheum Dis* 2005;64(05):682-687 [Internet]
- 2 Sonne-Holm S, Jacobsen S. Osteoarthritis of the first carpometacarpal joint: a study of radiology and clinical epidemiology. Results from the Copenhagen Osteoarthritis Study. *Osteoarthritis Cartilage* 2006;14(05):496-500
- 3 Giddins G. The Nonoperative Management of Hand Fractures in United Kingdom. *Hand Clin* 2017;33(03):473-487[Internet]

- 4 Armstrong AL, Hunter JB, Davis TRC. The prevalence of degenerative arthritis of the base of the thumb in post-menopausal women. *J Hand Surg [Br]* 1994;19(03):340–341[Internet]
- 5 Gottschalk MB, Patel NN, Boden AL, Kakar S. Treatment of Basilar Thumb Arthritis: A Critical Analysis Review. *JBJS Rev* 2018;6(07):e4
- 6 Pickrell BB, Eberlin KR. Thumb Basal Joint Arthritis. *Clin Plast Surg* 2019;46(03):407–413[Internet]
- 7 Baker RHJ, Al-Shukri J, Davis TRC. Evidence-Based Medicine: Thumb Basal Joint Arthritis. *Plast Reconstr Surg* 2017;139(01):256e–266e
- 8 Pegoli L, Parolo C, Ogawa T, Toh S, Pajardi G. Arthroscopic evaluation and treatment by tendon interpositional arthroplasty of first carpometacarpal joint arthritis. *Hand Surg* 2007;12(01):35–39
- 9 Spaans AJ, van Laarhoven CMC, Schuurman AH, van Minnen LP. Interobserver agreement of the Eaton-Littler classification system and treatment strategy of thumb carpometacarpal joint osteoarthritis. *J Hand Surg Am* 2011;36(09):1467–1470[Internet]
- 10 Gay AM, Cerlier A, Iniesta A, Legré R. Surgery for trapeziometacarpal osteoarthritis. *Hand Surg Rehabil* 2016;35(04):238–249 [Internet]
- 11 Hamasaki T, Laprise S, Harris PG, et al. Efficacy of Nonsurgical Interventions for Trapeziometacarpal (Thumb Base) Osteoarthritis: A Systematic Review. *Arthritis Care Res (Hoboken)* 2020;72(12):1719–1735
- 12 Thorkildsen RD, Røkkum M. Trapeziectomy with LRTI or joint replacement for CMC1 arthritis, a randomised controlled trial. *J Plast Surg Hand Surg* 2019;53(06):361–369[Internet]
- 13 Wajon A, Vinycomb T, Carr E, Edmunds I, Ada L. Surgery for thumb (trapeziometacarpal joint) osteoarthritis [Internet]. Vol. 2017Cochrane Database of Systematic Reviews, John Wiley and Sons Ltd; 2015 [cited 2021 May 1]
- 14 Wilkens SC, Bargon CA, Mohamadi A, Chen NC, Coert JH. A systematic review and meta-analysis of arthroscopic assisted techniques for thumb carpometacarpal joint osteoarthritis. *J Hand Surg Eur Vol* 2018;43(10):1098–1105
- 15 Wong CW, Ho PC. Arthroscopic Management of Thumb Carpometacarpal Joint Arthritis. *Hand Clin* 2017;33(04):795–812[Internet]
- 16 Eaton RG, Littler JW. Ligament reconstruction for the painful thumb carpometacarpal joint. *J Bone Joint Surg Am* 1973;55(08):1655–1666
- 17 Corella F, Ocampos M, Laredo R, Tabuenca J, Carnicer M, Larrainzar-Garijo R. Arthroscopic Trapeziectomy and Suture Button Suspensionplasty: A Review of the Literature and Description of the “Three-Step Arthroscopic Trapeziectomy Technique”. *J Wrist Surg* 2020;9(05):366–381
- 18 Yao J. Suture-button suspensionplasty for the treatment of thumb carpometacarpal joint arthritis. *Hand Clin* 2012;28(04):579–585
- 19 Kapandji A. Cotation clinique de l'opposition et de la contre-opposition du pouce. *Ann Chir Main* 1986;5(01):67–73[Internet]
- 20 Badia A. Trapeziometacarpal arthroscopy: a classification and treatment algorithm. *Hand Clin* 2006;22(02):153–163
- 21 Culp RW, Rekan MS. The role of arthroscopy in evaluating and treating trapeziometacarpal disease. Vol. 17, *Hand Clinics*. Elsevier; 2001:315–319
- 22 Culp RW, Rekan MS. The role of arthroscopy in evaluating and treating trapeziometacarpal disease. *Hand Clin* 2001;17(02):315–319, x–xi
- 23 Yao J, Cheah AEJ. Mean 5-Year Follow-up for Suture Button Suspensionplasty in the Treatment of Thumb Carpometacarpal Joint Osteoarthritis. *J Hand Surg Am* 2017;42(07):569.e1–569.e11[Internet]
- 24 Özçelik İB, Uğurlar M, Sarı A. Arthroscopic Hemitrapeziectomy and Suture Button Suspensionplasty in the Treatment of First Carpometacarpal Joint Eaton-Littler Stage 2-3 Arthrosis. *J Wrist Surg* 2019;8(02):132–138[Internet]
- 25 DeGeorge BR Jr, Chawla SS, Elhassan BT, Kakar S. Basilar Thumb Arthritis: The Utility of Suture-Button Suspensionplasty. *Hand (N Y)* 2019;14(01):66–72[Internet]