



Acute Promyelocytic Leukemia Masquerading as Sero-negative Polyarthrititis: Case Report

Priyanka Chauhan¹ Anshul Gupta¹ Chandni Bhandary Panambur¹ Dinesh Chandra¹
Rajesh Kashyap¹

¹Department of Haematology, Sanjay Gandhi Post Graduate Institute of Medical Sciences, Lucknow, Uttar Pradesh, India

Address for correspondence Rajesh Kashyap, MD, Department of Haematology, Sanjay Gandhi Post Graduate Institute of Medical Sciences, Raebareli Road, Lucknow 226014, Uttar Pradesh, India (e-mail: rajkashyapmd@gmail.com).

Ind J Med Paediatr Oncol 2022;43:386–389.

Abstract

Musculoskeletal manifestations as the sole presentation in acute leukemia is rare in adults. Acute promyelocytic leukemia (APML) is a subtype of acute myeloid leukemia (AML) with reported incidence of 10 to 15% of total AML cases. APML presenting as polyarticular arthritis has never been reported in the literature. We present an interesting case of 20-year-old male patient who manifested with polyarticular arthritis mainly of small joints as the initial presentation, followed by pancytopenia and eventually was diagnosed as a case of APML on bone marrow morphology and molecular analysis for *PML-RAR α* transcript. He was successfully treated with all-trans-retinoic acid (ATRA) and arsenic trioxide (ATO). Arthritis also resolved with complete remission of APML. Arthritis in a case with pancytopenia should promptly be evaluated prior to treatment with steroids and anti-metabolites. Arthritis can be a presenting manifestation of APML and responds to prompt management of leukemia as in other cases of leukemic arthritis.

Keywords

- ▶ acute promyelocytic leukemia
- ▶ arthritis
- ▶ musculoskeletal

Introduction

The incidence of acute promyelocytic leukemia (APML) is reported to be 0.32 cases per 100,000 population as per the SEER database.¹ APML is classified as acute myeloid leukemia (AML) with recurrent genetic abnormalities, as per the WHO (2008) and is a result of a balanced translocation t(15;17), which leads to the formation of fusion oncoprotein *PML-RARA* that leads to the arrest of normal myeloid differentiation at a promyelocyte stage. With the discovery of all-trans retinoic acid (ATRA) and arsenic trioxide as differentiating agents, the prognosis of APML has improved drastically with complete remission rates of >90%.^{2–4} However, such high cure rates are achievable only with timely diagnosis and vigorous management. The main presentation of APML

includes fever, generalized weakness, bleeding, and thrombotic manifestations due to coagulopathy.⁵ Though available literature has reported various cases of AML developing after rheumatoid or psoriatic arthritis,^{6–8} arthritis as an initial presentation in APML has never been reported to the best of our knowledge.

Case Report

This study being a case report, a waiver off consent was applied to the institutional ethics committee (IEC) and the same was accepted by the IEC.

We report a case of 20-year-old male patient, laborer by occupation, who consulted various physicians with complaints of fatigue and multiple joint pain, swelling, and

DOI <https://doi.org/10.1055/s-0042-1743506>.
ISSN 0971-5851.

© 2022. Indian Society of Medical and Paediatric Oncology. All rights reserved.

This is an open access article published by Thieme under the terms of the Creative Commons Attribution-NonDerivative-NonCommercial-License, permitting copying and reproduction so long as the original work is given appropriate credit. Contents may not be used for commercial purposes, or adapted, remixed, transformed or built upon. (<https://creativecommons.org/licenses/by-nc-nd/4.0/>)

Thieme Medical and Scientific Publishers Pvt. Ltd., A-12, 2nd Floor, Sector 2, Noida-201301 UP, India

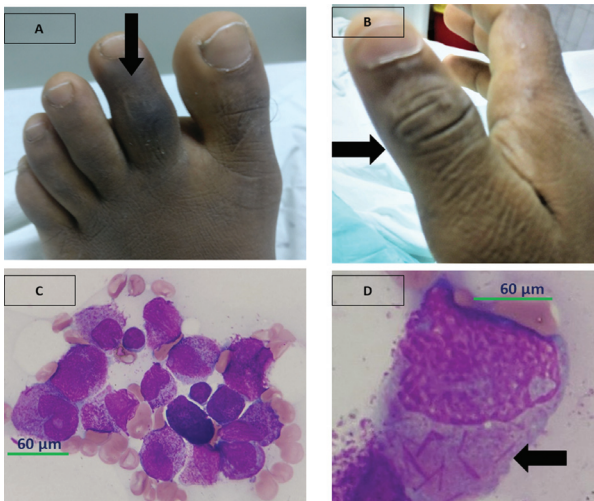


Fig. 1 (A and B) Arrow highlighting right thumb interphalangeal joint arthritis and dactylitis of the left second toe. (C and D) Normal hematopoietic elements are replaced by proliferation of more than 90% abnormal promyelocytes having high N:C ratio, irregular nucleus, open chromatin, with 1–2 prominent nucleoli, moderate amount of pale basophilic cytoplasm, with many of them showing multiple Auer rods (“Faggot cells” arrow). Cytochemistry: These abnormal promyelocytes are strongly positive for MPO.

stiffness of joints for 1 month. He was evaluated and treated with prescribed non-steroid anti-inflammatory drugs (NSAIDs) by the general physician; however, due to the persistence of his symptoms he was referred to immunology department of our hospital. General physical examination revealed pallor, no petechiae, ecchymosis, or lymphadenopathy. Musculoskeletal examination revealed right temporomandibular joint pain with jaw and mouth opening of one finger, right acromial tip enthesitis, dactylitis of left second toe (►Fig. 1A), left extensor tenosynovitis (►Fig. 1B), cervical spine local tenderness (C5–C8) present with restriction of movement in flexion (50°), extension (30°) and lateral rotation bilateral (30°). Systemic examination was within normal limits.

The laboratory investigations at first visit to the physician showed Hb-12.5 g/dL, total leucocyte count-4500/mm³, differential leucocyte count-neutrophil-62%, lymphocytes-38%, platelet count-120,000/μL, and peripheral blood smear-no abnormal cells. Baseline investigations at our center are documented in ►Table 1. Immunological work up showed elevated erythrocyte sedimentation rate (ESR) and C-reactive protein (CRP), anti-nuclear antibody profile, rheumatoid factor, anti-citrullinated peptide antibody (ACPA), HLA-B27 were all negative. The X-ray of involved joints did not show

Table 1 Laboratory profile of the patient

| Parameters | Investigations at our center at presentation | Investigations post consolidation chemotherapy |
|-------------------------------|---|--|
| Hb (g/dL) | 9.1 | 11.3 |
| TLC (/mm ³) | 800 | 7200 |
| DLC | N5L20 | N56L38E2M4 |
| Platelet count (/μL) | 76,000 | 2,26,000 |
| S. uric acid (mg/dL) | 4.2 | NA |
| S. calcium (mg/dL) | 9.1 | NA |
| S. phosphate (mg/dL) | 2.5 | NA |
| PT/INR | 15.4/1.34 | NA |
| APTT (seconds) | 26.7(Control-28.4) | NA |
| Fibrinogen (mg/dL) | 648 | NA |
| ESR (mm/hr) Westergren method | 140 | 18 |
| Malarial parasite | Negative | NA |
| Dengue serology | Negative | NA |
| CRP (mg/dL) | 13.3 | 0.5 |
| ANA | Negative | Negative |
| ACPA | Negative | Negative |
| RF | Negative | Negative |
| HLA-B27 | Negative | Negative |
| Bone marrow examination | Hypercellular marrow with 90% abnormal promyelocytes (MPO +), Faggot cells+ | No abnormal promyelocytes noted |
| RT-PCR PML-RARα | Positive for Bcr1 transcript | Negative |

Abbreviations: ACPA, anti-citrullinated peptide antibody; ANA, anti-nuclear antibody; APTT, activated partial thromboplastin time; CRP, C-reactive protein; DLC, differential leucocyte count; ESR, erythrocyte sedimentation rate; Hb, hemoglobin; INR, international normalized ratio; L, lymphocyte; M, monocyte; N, neutrophil; NA, not available; PT, prothrombin time; RF, rheumatoid factor; TLC, total leucocyte count.

any abnormality (**Supplementary figs. S1–3**, available online only). Ultrasound of meta-tarso-phalangeal joint of the second left toe showed minimal effusion, which was not amenable for aspiration. Bone marrow and flow cytometry done at our center in view of pancytopenia were diagnostic of APML-macro-granular variant (**Fig. 1B, 1D**). RT-PCR for *PML-RAR α* was positive for *Bcr1* transcript (**Supplement file 1**, available online only). Differentials of APML with leukemic arthritis versus reactive arthritis versus hemorrhagic arthritis were thought of after the reports were available. Hemorrhagic arthritis was ruled out due to normal coagulation parameters, no evidence of bleeding elsewhere and small joint involvement in this case contrary to typical large weight-bearing joint arthritis in hemorrhagic arthritis. The patient was labeled as APML, low risk (SANZ criteria),³ and was started on ATRA at 45 mg/m² per oral daily and ATO at 0.15 mg/kg/day IV infusion with close monitoring of coagulation parameters, electrocardiography (ECG), and serum electrolytes. In view of the limitation of activity due to arthritis and no relief with tramadol, the patient was started on low-dose prednisolone 10 mg daily but the symptoms and signs persisted, dose of steroids was increased to 15 mg and then 20 mg daily with some relief in symptoms. The patient tolerated ATRA and ATO protocol well with no adverse events and no differentiation syndrome. Day 28 marrow showed morphological remission. Musculoskeletal symptoms also gradually subsided and steroid was tapered and was discontinued by day 35 with complete resolution of musculoskeletal symptoms and signs. The patient continued consolidation with ATRA and ATO as per the APL0406 protocol.⁴ Bone marrow morphology and RT-PCR for *PML-RAR α* from marrow aspirate sample, post consolidation was negative. At 16 months of follow-up, the patient continues to be in remission without any recurrence of joint symptoms.

Discussion

Musculoskeletal presentation has been reported in many malignancies.⁹ The most common presentations are myalgia, arthralgia, arthritis, osteolytic bony lesions, and spontaneous fractures.⁹ Leukemic arthritis is defined as joint pain and swelling in a diagnosed case of leukemia when other causes of arthritis have been excluded.¹⁰ It is reported to occur in around 12 to 65% cases of acute leukemia in children, whereas in adults the reported prevalence is between 4 and 13%.^{11,12} In children, it is reported most in acute lymphoblastic leukemia, while in adults apart from acute leukemia, leukemic arthritis is also reported in chronic myeloid leukemia, adult T cell leukemia, and hairy cell leukemia.^{10,13} Pathogenic mechanisms for this type of arthritis described in the literature include direct infiltration of leukemic cells into synovial tissue, synovial reaction to tissue infiltration, immune complex mediated synovitis, and hemorrhage into the joint space due to thrombocytopenia. However, direct infiltration of the synovial tissue is the most common mechanism reported. It mostly presents as asymmetric pauciarticular large joint arthritis presenting as the initial manifestation in acute leukemia, while more sym-

metric and late presentation in chronic leukemia.^{14,15} Involved joints show typical signs of inflammation; erythema, swelling, tenderness mimicking other rheumatic diseases and often cause difficulty in diagnosis at initial presentation. Very few case reports have described the presentation of tenosynovitis or finger joint involvement as in our case.^{16,17} A few case reports have reported the development of acute promyelocytic leukemia in patients on therapy for rheumatoid arthritis but even after extensive literature search, arthritis as the presenting symptom of APML has not been reported. In their report, Naithani et al¹⁸ described arsenic trioxide-induced acute flare up of pre-existing rheumatoid arthritis. Akoz et al¹⁹ described atypical presentation of retinoic acid syndrome mimicking septic arthritis. Buyukkurt et al⁶ in their case reported the development of acute promyelocytic leukemia in a patient with gouty arthritis who was on long-term colchicine therapy. In our case, we kept the possibility of simultaneous presentation of both rheumatoid arthritis and APML but negative autoimmune work-up and temporal correlation of disappearance of symptoms and signs of arthritis coinciding with remission status of APML and no recurrence thereafter at 16 months of follow-up made the diagnosis of leukemic arthritis evident. In some cases, complete blood count and peripheral smear examination show non-specific findings such as anemia, leukocytosis, or leukopenia, mandating the need of bone marrow examination. Management involves managing the primary disease, joint symptoms, and signs resolve with the remission of disease.

The limitation of this case report is the inability to confirm leukemic arthritis by histopathological diagnosis of the synovial fluid as joint effusion was minimal and hence inability to perform aspiration.

Patient's Perspective

I had visited six to seven physicians prior to consulting this hospital for pain in multiple joints and difficulty chewing food, but there was no relief with various medications given. After I consulted this hospital, my blood tests showed decreased white blood counts for which I was investigated further and then my medications were started; after 15 days, my joint pain and swelling reduced by 50% and after 1 month of therapy, I felt completely normal. I continued therapy for another 6 months and now I am doing my work like before.

Conclusion

Arthritis as a presenting feature of acute leukemia has been well described; however, it has been seldom reported in APML. A high index of suspicion and thorough investigations are required prior to labeling it as rheumatic disorder and initiating treatment with steroids and/or antimetabolites, which may lead to the masking of the underlying etiology. It is imperative to monitor complete blood count and peripheral smear repeatedly in case of doubt and negative serological tests for immune disorders.

Consent

Informed consent was taken from the patient.

Funding

None.

Conflict of Interest

None declared.

Acknowledgments

We acknowledge the contribution of all the laboratory staff, residents, and nursing staff involved in managing this patient.

References

- Guru Murthy GS, Szabo A, Michaelis L, et al. Improving outcomes of acute promyelocytic leukemia in the current era: analysis of the SEER database. *J Natl Compr Canc Netw* 2020;18(02):169–175
- Lo-Coco F, Avvisati G, Vignetti M, et al; Gruppo Italiano Malattie Ematologiche dell'Adulto German-Austrian Acute Myeloid Leukemia Study Group Study Alliance Leukemia. Retinoic acid and arsenic trioxide for acute promyelocytic leukemia. *N Engl J Med* 2013;369(02):111–121
- Sanz MA, Martín G, González M, et al; Programa de Estudio y Tratamiento de las Hemopatías Malignas. Risk-adapted treatment of acute promyelocytic leukemia with all-trans-retinoic acid and anthracycline monochemotherapy: a multicenter study by the PETHEMA group. *Blood* 2004;103(04):1237–1243
- Platzbecker U, Avvisati G, Cicconi L, et al. Improved outcomes with retinoic acid and arsenic trioxide compared with retinoic acid and chemotherapy in non-high-risk acute promyelocytic leukemia: final results of the randomized Italian-German APL0406 trial. *J Clin Oncol* 2017;35(06):605–612
- Daver N, Kantarjian H, Marcucci G, et al. Clinical characteristics and outcomes in patients with acute promyelocytic leukaemia and hyperleucocytosis. *Br J Haematol* 2015;168(05):646–653
- Buyukkurt N, Korur A, Boga C. Development of acute promyelocytic leukemia in a patient with gouty arthritis on long-term colchicine. *Indian J Hematol Blood Transfus* 2016;32(Suppl 1):80–81. Doi: 10.1007/s12288-015-0523-4
- Ki MH, Ho LJ, Min LH, et al. A case of acute myeloid leukemia after adalimumab treatment in psoriatic arthritis. *J Rheum Dis* 2012;19(02):91–94
- Tanaka K, Oshikawa G, Akiyama H, et al. Acute myeloid leukemia with t(3;21)(q26.2;q22) developing following low-dose methotrexate therapy for rheumatoid arthritis and expressing two AML1/MDS1/EVI1 fusion proteins: a case report. *Oncol Lett* 2017;14(01):97–102
- Morais SA, du Preez HE, Akhtar MR, Cross S, Isenberg DA. Musculoskeletal complications of haematological disease. *Rheumatology (Oxford)* 2016;55(06):968–981
- Evans TI, Nercessian BM, Sanders KM. Leukemic arthritis. *Semin Arthritis Rheum* 1994;24(01):48–56
- Weinberger A, Schumacher HR, Schimmer BM, Myers AR, Brogadir SP. Arthritis in acute leukemia. Clinical and histopathological observations. *Arch Intern Med* 1981;141(09):1183–1187
- Spilberg I, Meyer GJ. The arthritis of leukemia. *Arthritis Rheum* 1972;15(06):630–635
- Needleman M. Childhood leukemia mimicking arthritis. *J Am Board Fam Pract* 1996;9(01):56–60
- Silverstein MN, Kelly PJ. Leukemia with osteoarticular symptoms and signs. *Ann Intern Med* 1963;59:637–645
- Brix N, Rosthøj S, Herlin T, et al. Arthritis as presenting manifestation of acute lymphoblastic leukaemia in children. *Arch Dis Child* 2015;100(09):821–825
- Thomas LB, Forkner CE Jr, Frei E III, Besse BE Jr, Stabenau JR. The skeletal lesions of acute leukemia. *Cancer* 1961;14:608–621
- Taillan B, Leyge JF, Fuzibet JG, Nectoux F, Ziegler G, Dujardin P. Knee arthritis revealing acute leukemia in a patient with rheumatoid arthritis. *Clin Rheumatol* 1991;10(01):76–77
- Naithani R, Mahapatra M, Kumar R, Kumar A, Agrawal N. Arsenic trioxide induced acute flare-up of rheumatoid arthritis in a patient with APL. *Ann Hematol* 2007;86(02):151–152
- Ayla Gokmen Akoz, Huseyin Engin & Nefise Oztoprak. Atypical presentation of retinoic acid syndrome that mimics septic arthritis in a patient with acute promyelocytic leukemia. *Acta Oncol (Madr)* 2007;46(08):1193–1194