Article published online: 2022-03-10

A Case of Minimal Change Disease after SARS-CoV-2 Vaccination under the Age of 18

Mohamad Nour Alhosaini[1]

[1] Department of Nephrology, American Hospital, Dubai, United Arab Emirates

Address for correspondence Mohamad Nour Alhosaini, MD, Department of Nephrology, American Hospital, Dubai, United Arab Emirates (e-mail: malhosaini@ahdubai.com).

Avicenna J Med 2022;12:31–33.

Abstract

This is a care report of a 16-year-old-male who developed de novo minimal change disease following the second dose of the Pfizer vaccine. The patient developed sudden onset edema and 10 kg weight gain. He had nephrotic range proteinuria with normal renal function. Kidney biopsy with adequate sample confirmed minimal change disease. The patient improved after 1 week of starting prednisone. This is the first case of minimal change disease after the Pfizer vaccine in the teenager population since expanding the age groups to allow younger subjects to receive the vaccine. Reporting cases at different age groups will help in trying to clarify whether the increasing reports of nephrotic syndrome following the vaccination are accidental or cause–effect relationship.

Keywords

- minimal change disease
- Pfizer
- SARS-COV-2

Introduction

The introduction of the severe acute respiratory syndrome coronavirus 2 (SARS-CoV-2) vaccination has altered the course of the pandemic and led to a significant drop in hospitalization and mortality. The lack of major side effects helped in expanding the use of the Pfizer BNT162b2 vaccine to include more age groups. However, there has been an increased number of case reports describing a glomerular disease associated with the vaccination in adults. Here we report the first case of minimal change disease (MCD) in a teenager patient after the second dose of the Pfizer vaccine.

Case Report

The patient is a 16-year-old white male who presented with legs edema. He received the second dose of the Pfizer vaccination 7 days before the symptom's onset. He also complained of abdominal discomfort with nausea. Subsequently, he noticed progressive ankles swelling and 10 kg weight gain. He denied any history of infections or malignancies. He was not on any medication or supplement.

His blood pressure was 115/74 mm Hg and the pulse was 99 bpm. Physical examination was significant for bilateral pitting edema up to the thighs and decreased breathing sounds on both lung bases with dullness to percussion. His abdomen was slightly distended.

Initial workup showed serum creatinine of 0.85 mg/dL, serum albumin was 1.5 g/dL, urinalysis showed +4 protein and moderate blood, and the protein to creatinine ratio was 5.6 g/gram (see ►Table 1). Testing for antinuclear antibody, antineutrophil cytoplasmic antibody, C3, C4, hepatitis C and B panels was all negative. Renal ultrasound revealed 11 cm kidneys bilaterally with slight increased echogenicity. Ascites and pleural effusion were noticed on the ultrasound.

He underwent a kidney biopsy. The sample contained a total of 56 glomeruli. Light microscopy showed normal glomeruli (►Fig. 1). Immunofluorescence studies were all negative. Electron microscopy showed diffuse foot process effacements (►Fig. 2). None of the glomeruli had any

published online
March 10, 2022

DOI https://doi.org/10.1055/s-0042-1743209.
ISSN 2231-0770.

© 2022. Syrian American Medical Society. All rights reserved.
This is an open access article published by Thieme under the terms of the Creative Commons Attribution-NonDerivative-NonCommercial-License, permitting copying and reproduction so long as the original work is given appropriate credit. Contents may not be used for commercial purposes, or adapted, remixed, transformed or built upon. (https://creativecommons.org/licenses/by-nc-nd/4.0/)
Thieme Medical and Scientific Publishers Pvt. Ltd., A-12, 2nd Floor, Sector 2, Noida-201301 UP, India

Table 1 Laboratory workup trend

Laboratory	Day 1	Day 5	Day 22
Creatinine	0.85	0.85	0.76
Albumin	1.7	2.7	3.7
Urinary protein to creatinine ratio (G/G)	10.3	2.92	0.06

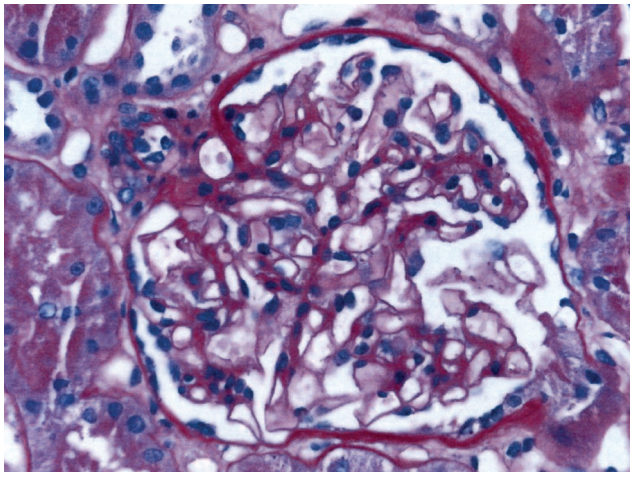

Fig. 1 Normal glomeruli (from the patient). PAS, periodic acid-Schiff; stain, high power.

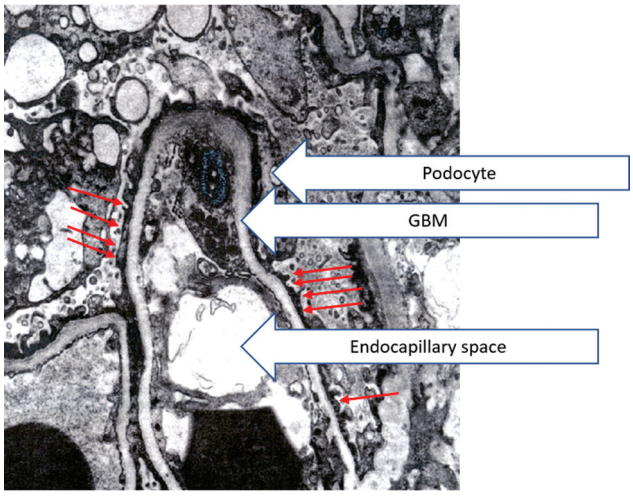

Fig. 2 EM, high power. Diffuse effacement of the foot processes (arrows). EM, electron microscopy; GBM, glomerular basement membrane.

segmental sclerosis and the number of the glomeruli was adequate that made the possibility of focal segmental glomerulosclerosis very low.

The patient was started on 60 mg of oral prednisone along with furosemide and olmesartan. After 1 week, edema resolved and his proteinuria and serum albumin started to improve.

Discussion

The association between nephrotic syndrome and vaccination was well known prior to the coronavirus disease 2019 (COVID-19) era, but it has been reported more frequently with the SARS-CoV-2 vaccines. However, none of the reported patients was under the age of 18. In mid-May of 2021, Pfizer was the first vaccine to be approved by the U.S. Food and Drug Administration for the age group of 12 to 17. Up to our knowledge, this is the first report of a nephrotic syndrome case in the teenager population in association with the COVID-19 vaccination.

The reported cases of nephrotic syndrome were largely due to MCD (10/11).[1–10] Of note, all of the reported cases with the vaccines that use the pioneer mechanism (Pfizer and Moderna) are due to MCD (8/8).[1–7,9] Whether this is a mere association or a true cause–effect relationship is to be determined. The largest randomized controlled trial of the Pfizer vaccine did not show any renal side effects. However, because T cell abnormality leading to podocytopathy was suggested as the main mechanism in the pathophysiology of MCD, it is plausible to postulate that the vaccine-induced T cell activation is a risk factor for developing nephrotic syndrome. The Pfizer vaccine is known to cause a favorable Th1 profile with the detection of interferon gamma and inerleukin-2 (IL-2) but not IL-4 or IL-5.[11] The messenger RNA of IL 2 was reported to be higher in the peripheral blood mononuclear cells during the acute phase of idiopathic nephrotic syndrome compared with the remission phase.[12] IL-2 was also significantly increased during relapse of steroid sensitive nephrotic syndrome compared with remission.[13]

If a cause–effect relationship is confirmed, this specific pattern of T cell activation can explain why MCD is the only reported nephrotic syndrome described with the pioneer mechanism (Pfizer and Moderna). In most of the reported cases, the nephrotic syndrome occurred after the first dose but our patient developed his symptoms after the second dose. This could be due to the variability in the intensity of the immune response between the first and second dose among different recipients.

Eighty to ninety-five percent of patients with MCD respond to steroids. Our patient started to enter remission after 1 week of steroids use. All the other reported cases showed a favorable initial response. Five out of the ten cases were a relapse and in one of them the relapse happened after the two doses. Whether a patient who has a history of MCD or developed de novo MCD after the first dose should abstain from the second dose to avoid reactivation of the nephrosis cannot be recommended. This is because the theoretical risk of relapse cannot be compared with the overwhelming benefits of the vaccine. In fact, steroids use probably reduces the response to the vaccine and a growing literature suggests the need for a third dose in immune-compromised patients.[14]

In summary, our case adds to the several cases of nephrotic syndrome after COVID-19 vaccination but this time at a much younger age. Increasing the awareness of this association is important with the needed expansion of vaccination and to help build up the knowledge to clarify whether this is an association or a cause–effect relation.

Conflict of Interest

None.

 © 2022. Syrian American Medical Society. All rights reserved.

References

1 Lebedev L, Sapojnikov M, Wechsler A, et al. Minimal change disease following the Pfizer–BioNTech COVID-19 vaccine. Am J Kidney Dis 2021 S0272–6386(21)00509–6; . Doi: 10.1053/j.ajkd.2021.03.010

2 D'Agati VD, Kudose S, Bomback AS, et al. Minimal change disease and acute kidney injury following the Pfizer–BioNTech COVID-19 vaccine. Kidney Int 2021 S0085–2538(21)00493–2; . Doi: 10.1016/j.kint.2021.04.035

3 Maas RJ, Gianotten S, van der Meijden WAG. An additional case of minimal change disease following the Pfizer–BioNTech COVID-19 vaccine. Am J Kidney Dis 2021;78(02):312

4 Weijers J, Alvarez C, Hermans MMH. Post-vaccinal minimal change disease. Kidney Int 2021;100(02):459–461 (online ahead of print)

5 Kervella D, Jacquemont L, Chapelet-Debout A, et al. Minimal change disease relapse following SARS-CoV-2 mRNA vaccine. Kidney Int. 2021 S0085–2538(21)00478–6; . Doi: 10.1016/j.kint.2021.04.033

6 Schwotzer N, Kissling S, Fakhouri F. Letter regarding "Minimal change disease relapse following SARS-CoV-2 mRNA vaccine". Kidney Int 2021 S0085–2538(21)00500–7; . Doi: 10.1016/j.kint.2021.05.006

7 Komaba H, Wada T, Fukagawa M. Relapse of minimal change disease following the Pfizer–BioNTech COVID-19 vaccine. Am J Kidney Dis 2021 S0272–6386(21)00627–2; . Doi: 10.1053/j.ajkd.2021.05.006

8 Morlidge C, El-Kateb S, Jeevaratnam P, Thompson B. Relapse of minimal change disease following the AstraZeneca COVID-19 vaccine. Kidney Int 2021;100(02):459. Doi: 10.1016/j.kint.2021.06.005

9 Holzworth A, Couchot P, Cruz-Knight W, et al. Minimal change disease following the Moderna mRNA-1273 SARS-CoV-2 vaccine. Kidney Int 2021 S0085–2538(21)00501–9; . Doi: 10.1016/j.kint.2021.05.007

10 Aydın MF, Yıldız A, Oruc A, et al. Relapse of primary membranous nephropathy after inactivated SARS-CoV-2 virus vaccination. Kidney Int 2021 S0085–2538(21)00494–4; . Doi: 10.1016/j.kint.2021.05.001

11 Sahin U, Muik A, Derhovanessian E, et al. COVID-19 vaccine BNT162b1 elicits human antibody and T_H1 T cell responses. Nature 2020;586(7830):594–599

12 Shimoyama H, Nakajima M, Naka H, et al. Up-regulation of interleukin-2 mRNA in children with idiopathic nephrotic syndrome. Pediatr Nephrol 2004;19(10):1115–1121

13 Neuhaus TJ, Wadhwa M, Callard R, Barratt TM. Increased IL-2, IL-4 and interferon-gamma (IFN-gamma) in steroid-sensitive nephrotic syndrome. Clin Exp Immunol 1995;100(03):475–479

14 Kamar N, Abravanel F, Marion O, Couat C, Izopet J, Del Bello A. Three doses of an MRNA COVID-19 vaccine in solid-organ transplant recipients. N Engl J Med 2021;385(07):661–662

 © 2022. Syrian American Medical Society. All rights reserved.