








# Evaluation of Recurrence and Hearing Outcome for Inactive Squamosal Disease after Cartilage Strengthening Tympanoplasty

Priyanshi Gupta<sup>1</sup>  Digvijay Singh Rawat<sup>2</sup>  Yogesh Aseri<sup>2</sup>  P. C. Verma<sup>2</sup>  B. K. Singh<sup>2</sup> 

<sup>1</sup>Department of Ear, Nose, and Throat, Mahatma Gandhi Medical College and Hospital, Jaipur, Rajasthan, India.

<sup>2</sup>Department of Ear, Nose, and Throat and Head and Neck Surgery, Jawaharlal Nehru Medical College, Ajmer, Rajasthan, India

Address for correspondence Priyanshi Gupta, MBBS, DLO, MS ENT, Department of ENT, Mahatma Gandhi Medical College and Hospital, Jaipur, Rajasthan 302022, India (e-mail: priyanshi728@gmail.com).

Int Arch Otorhinolaryngol 2022;26(4):e624–e629.

## Abstract

**Introduction** Inactive squamosal disease is unique for having a conflicting treatment protocol, with an age-old debate between early surgical intervention or keeping patients in a long-term follow-up. The shifting paradigm is early intervention to prevent further progress into active disease and improve hearing outcome in its nascent stage.

**Objective** To evaluate recurrence and hearing outcome in cases of inactive squamosal disease after cartilage strengthening tympanoplasty.

**Methods** The study was conducted on 50 patients with inactive squamosal disease. Detailed examination was done to grade the retraction. All patients underwent autologous conchal cartilage tympanomastoidectomy with temporalis fascia grafting. Recurrence and hearing evaluations were done by pure tone audiogram at regular intervals for one year.

**Results** Hearing loss was the most common presenting symptom. Isolated pars tensa retractions were more common (54%) than pars flaccida (12%), or those involving both (34%). Ossicular status was normal in only 14% of the cases, and the most common ossicular damage was to the lenticular process of the incus (52%). Three of the patients (6%) had residual perforation at the 3<sup>rd</sup> month of follow-up. Subjective improvement in hearing was reported by 42% patients. Hearing improvement greater than 10 dB was found in 24 patients (48%). Air–bone gap reduced from  $25.16 \pm 8.15$  dB preoperatively to  $12.90 \pm 6.20$  at 1 year of follow-up. Recurrence was seen in three patients (6%).

**Conclusion** Early intervention by cartilage strengthening of weakened tympanic membrane and ossicular reconstruction not only offers better hearing results, but also prevents progress to active disease.

## Keywords

- ▶ suppurative otitis media
- ▶ tympanoplasty
- ▶ ear ossicles

received  
September 3, 2021  
accepted  
December 1, 2021  
published online  
February 22, 2022

DOI <https://doi.org/10.1055/s-0042-1742762>.  
ISSN 1809-9777.

© 2022, Fundação Otorrinolaringologia. All rights reserved.  
This is an open access article published by Thieme under the terms of the Creative Commons Attribution-NonDerivative-NonCommercial-License, permitting copying and reproduction so long as the original work is given appropriate credit. Contents may not be used for commercial purposes, or adapted, remixed, transformed or built upon. (<https://creativecommons.org/licenses/by-nc-nd/4.0/>)  
Thieme Revinter Publicações Ltda., Rua do Matoso 170, Rio de Janeiro, RJ, CEP 20270-135, Brazil

## Introduction and Objectives

Tympanic membrane retraction occurs due to invagination of a part or whole of the tympanic membrane into the middle ear cavity. Chronic otitis media (COM) inactive squamous type is characterized by the tympanic membrane retraction involving pars flaccida, pars tensa, or both without granulations, keratin debris, and cholesteatoma. Long-term retraction pockets eventually lead to ossicular erosion, hearing loss and may further progress to cholesteatoma formation.<sup>1,2</sup>

To prevent the complications related to retraction, early intervention is often necessary. The options available to the clinician are many, ranging from wait and watch, medical treatment, and surgical intervention. There is a myriad of effective surgical techniques which can be done based on severity of retraction and status of the ossicular chain, such as ventilation tube insertion, excision of retraction pocket with fascia grafting, augmentation of tympanic membrane by cartilage, cortical mastoidectomy, and mastoid venting.<sup>3</sup>

In contrast to the previously common practice of regular follow-ups, detailed understanding of disease pathophysiology has highlighted the need for early surgical intervention to strengthen the weakened lattice of the tympanic membrane, which can prevent underlying gradual ossicular erosion with unrecognized hearing loss, to conclusively manifest as obvious severe hearing loss and active squamous pathology.

The benefits of cartilage as a reconstructive material for ossicles have been tested, but utility of cartilage as an augmentation material for strengthening and support of the tympanic membrane has found new relevance.

## Methods

The study aims to ascertain the additive effect of cartilage use both in augmentation, to prevent recurrence of retraction pocket, and reconstruction of ossicles, to improve the long-term hearing outcomes. Data gathering happened in the Department of Otorhinolaryngology at a tertiary teaching hospital in North India from February 1<sup>st</sup>, 2019, to February 1<sup>st</sup>, 2020. Approval from the Institutional Ethics Committee was obtained, and the study was registered with the Clinical Trials Registry – India (CTRI), with the trial number CTRI/2019/02/017654.

The present study included cases of patients with COM inactive squamous disease between 15 and 60 years of age who were willing to undergo surgery. Cases with cholesteatoma, those undergoing revision ear surgeries, and those with sensorineural hearing loss were excluded.

A written and fully explained Consent Form stating the voluntary participation of subjects in the study was signed by all participants. A detailed analysis of the patients' medical history, otoscopy and oto-telescopic examinations, and examination under microscope were performed to access and grade the retraction pockets. A battery of investigations including routine blood investigation, electrocardiography (ECG), urine tests, x-ray from the mastoid bilateral lateral oblique view, x-ray from the chest, pure tone audiometry, and tympanometry were done.

Hearing was evaluated by 256Hz, 512Hz, and 1024Hz tuning forks through the Rinne test, Weber test, and the absolute bone conduction test. The type and severity of preoperative hearing loss, its air–bone gap, was calculated by pure tone audiometry. Tympanometry was done to assess the mobility of tympanic membrane and middle ear pressure.

Surgery was performed under local or general anesthesia with the post auricular approach. Temporalis fascia graft was harvested. The external acoustic canal was opened medial to the spine of Henle, and the tympanomeatal flap was elevated. Transcortical mastoidectomy was performed and an orderly, systematic exenteration of the mastoid air cell tract was accomplished by identifying anatomical landmarks. Dura and sinus were located and followed to identify the mastoid antrum, and patency was checked. The posterior canal wall was thinned to identify the lateral semicircular canal and the short process of incus. If necessary, transmeatal drilling was performed to expose the depth of the retraction pocket. Subsequently, with the help of a sharp curved needle, the annulus was raised along with the retracted part of the eardrum in continuity. Absolute care was taken to raise the thinned-out retraction, by using a counter traction with the help of a small caliber suction canula with the appropriate negative pressure. The middle ear mucosa was identified inferiorly, below the round window niche or, in cases of grade IV retraction, near the eustachian tube's orifice. The plane between the tympanic membrane and middle ear mucosa was identified and the retracted tympanic membrane was separated from the mucosa over the promontory and ossicles. The thin retracted part of the tympanic membrane was resected. Conchal cartilage graft was harvested for ossiculoplasty, reconstruction of the attic area depending on the ossicular status, and augmentation of tympanic membrane. A vertical strut of cartilage of appropriate length was fashioned to be placed over the foot plate or stapes remnant to create an adequate middle ear space. A 0.5 mm thick conchal cartilage was used for the reconstruction of the attic area, and a 0.3 mm thick cartilage was used for interposition between the incus remnant and stapes, and/or reinforcement of the temporalis fascia graft. Gelfoam (Pharmacia & Upjohn Co. Kalamazoo, MI, USA) and Meroceel (Medtronic Xomed, Inc. Jacksonville, FL, USA) packing was done, and the wound was closed in two layers. All patients received postoperative antibiotics, decongestants and pain medication. Sutures were removed on the 7<sup>th</sup> postoperative day.

Subsequent follow-up was done on the 14th day, 1 month, and every 3<sup>rd</sup> month postoperatively. Hearing evaluation was done by audiometry recording air conduction and bone conduction of all the patients for 0.5, 1, 2, and 4 kHz preoperatively, and every three months in the postoperative period. Hearing results were reported using the guidelines recommended by World Health Organization (WHO) and the Committee on Hearing and Equilibrium of the American Academy of Otolaryngology-Head and Neck Surgery (AAO-HNS) for the evaluation of treatment result of conductive hearing loss. This includes reporting of the mean, standard deviation (SD), and range of the postoperative air–bone gap.<sup>4,5</sup>

**Table 1** Demographic and socioeconomic characteristics of the study population

Age distribution (years)	Number of patients
< 20	11 (22%)
21–30	14 (28%)
31–40	10 (20%)
41–50	11 (22%)
51–60	4 (8%)
Mean age: 32 ± 12.61 years	
Gender distribution	
Male	22 (44%)
Female	28 (56%)
Kuppuswamy score (socioeconomic status distribution)	
1 (Upper)	0 (0)
2 (Upper-middle)	1 (2%)
3 (Lower-middle)	2 (4%)
4 (Upper-lower)	27 (54%)
5 (Lower)	20 (40%)

The following parameters were used to compare the results of the study: graft uptake, hearing improvement by air–bone gap closure, and recurrence of retraction pocket within one year of surgery. The successful outcome was defined as complete and intact healing of the graft, without recurrence of retraction pockets, and with hearing improvement.

Statistical analysis: data were tabulated in MS Excel (Microsoft Corp. Redmond, WA, USA). Qualitative data was expressed in proportion, and quantitative data as mean ± SD. Comparison of baseline versus postoperative hearing was done by *t*-test using the OpenEpi (Dean AG, Sullivan KM, Soe MM. Atlanta, GA, USA) software, and *p*-value < 0.05 was considered statistically significant.<sup>6</sup>

## Results

The demographic and socioeconomic data of the 50 cases included in this study are summarized in ► **Table 1**. The majority of the patients were less than 40 years of age (70%); there were more females (56%) than males (44%). Most of the patients were of lower and upper lower socioeconomic status, according to the Kuppuswamy score.<sup>7</sup> Isolated hearing loss was the most-common presenting symptom (70%). Isolated pars tensa retractions were more common (54%) than pars flaccida (12%), and than cases involving both (34%). Sclerosed mastoid was observed in most patients. Bilateral involvement was seen in 32% of the patients. (► **Table 2**)

Ossicular status was normal in 14% patients and eroded in 86%. The most common ossicular damage was to the lenticular process of the incus (52%). (► **Table 3**). Type III tympanoplasty was performed, and conchal cartilage was used for ossiculoplasty, reconstruction of attic area, and augmentation of tympanic membrane with temporalis fascia.

**Table 2** Clinical presentation and examination findings of the study population

Presenting symptoms	Number of patients
• Isolated hearing loss	35 (70%)
• Isolated ear discharge	7 (14%)
• Hearing loss with ear discharge	8 (16%)
• Other	None
Retraction pocket site	
• Pars tensa alone	27 (54%)
• Pars flaccida alone	6 (12%)
• Both	17 (34%)
Pars tensa retraction (Sade)	
• Grade I	0 (0%)
• Grade II	14 (28%)
• Grade III	13 (26%)
• Grade IV	17 (34%)
Pars flaccida retraction (Tos)	
• Grade I	2 (4%)
• Grade II	8 (16%)
• Grade III	6 (12%)
• Grade IV	7 (14%)
Mastoid x-ray findings	
• Sclerosed	44 (88%)
• Diploic	6 (12%)
• Pneumatized	None
Tympanometry	
• Type A	5 (10%)
• Type B	25 (50%)
• Type C	20 (40%)

**Table 3** Intra-operative ossicular findings

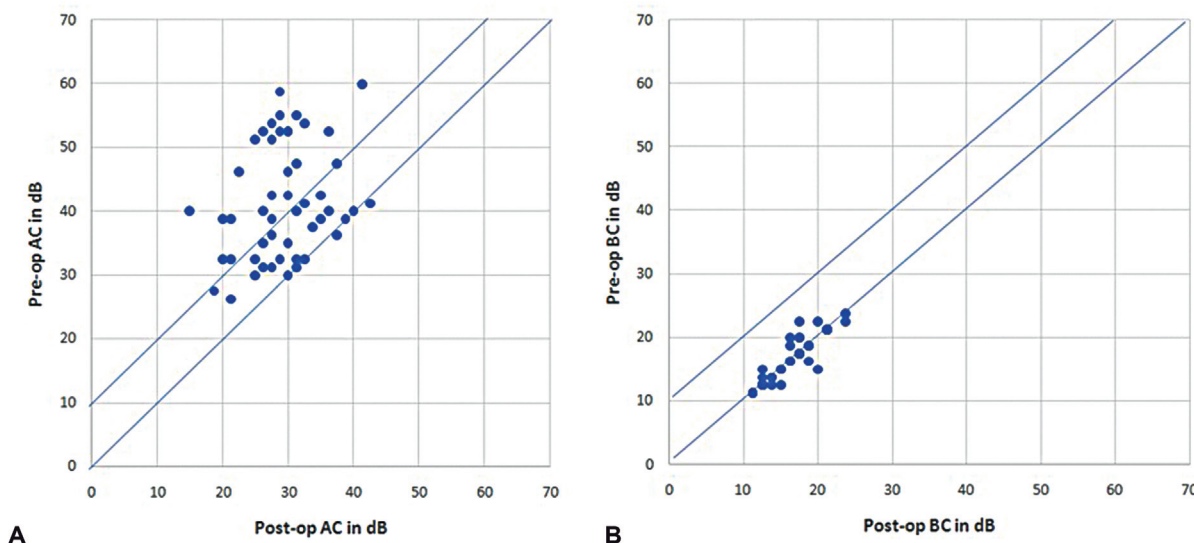
Ossicular status (Intra-op)	Number of patients
• Normal	7 (14%)
• M+, I-, SS+	26 (52%)
• M-, I-, SS+	2 (4%)
• M+, I-, SS-, FP+	5 (10%)
• M-, I-, SS-, FP+	10 (20%)

Abbreviations: M, malleus superstructure; I, incus superstructure; SS, stapes superstructure; FP, stapes foot plate. Notes: + indicates intact structure; – indicates eroded structure.

Three patients had a residual perforation at the 3<sup>rd</sup> month of follow-up. Subjective improvement in hearing was reported by 42% of the patients. There was a significant improvement in the mean air conduction postoperatively. The air–bone gap reduced from 25.16 ± 8.15 dB preoperatively to 13.40 ± 6.20 at 1-year of follow-up. (► **Table 4**). Three patients had recurrence within 1 year of surgery.

**Table 4** Comparison of average hearing thresholds (500Hz, 1000Hz, 2000Hz, and 4000Hz), as evaluated by audiometry preoperatively and 1 year after surgery

Hearing threshold	Preoperatively (In dB)	Postoperatively (In dB)	P-value
Mean air conduction	41.50 ± 8.94	29.35 ± 5.95	< 0.01
Mean bone conduction	16.13 ± 3.76	15.93 ± 3.55	0.6891
Air–bone gap	25.16 ± 8.15	13.40 ± 6.20	< 0.01



**Fig. 1** (A) Scatter diagram showing pre- and postoperative air conduction average hearing thresholds (500Hz, 1000Hz, 2000Hz, and 4000Hz) of each patient. (B) Scatter diagram showing pre- and postoperative bone conduction average hearing thresholds (500Hz, 1000Hz, 2000Hz, and 4000Hz) of each patient.

Scatter plots comparing average pre- and postoperative air conduction and bone conduction of individual patients were prepared. **Fig. 1A** shows that hearing, as depicted by air conduction, improved in the majority of patients. There are 8 patients on the diagonal line, showing no change in postoperative hearing thresholds. On the other hand, average hearing improved by more than 10 dB in 24 patients, as these are plotted in the graph on the left side of the 10 dB diagonal line. **Fig. 1B** showed that there was no significant change in bone conduction threshold postoperatively.

**Discussion**

The COM inactive squamous type is a disease of the middle ear with unpredictable progression. While most cases may exhibit a gradually progressive disease, a select few can have rapid progression into active disease, with a minority remaining static. This subset of COM usually presents with an underlying, undetectable, progressive hearing loss only to manifest with a severe degree of hearing loss after a few years due to ossicular erosion. The disease is characterized by retraction of the tympanic membrane, which is most commonly seen in the posterosuperior part of the pars tensa and in the pars flaccida.

Marchioni et al. suggested that the selective dysventilation of the attic occurs due to concomitant presence of a

series of complete or incomplete epitympanic diaphragms. This blockage develops a negative pressure, leading to the formation of a retraction pocket with normal eustachian tube functions.<sup>8</sup>

Shunyu et al. studied the histological findings in the pars tensa retraction pocket. They reported that subepithelial inflammation was seen in all grades of retraction, and that parakeratosis was more marked in grade II retraction. They noted that the papillary epithelial cones in the basal epithelial layer, loss of the middle collagen layer, and loss of the inner mucosal layer progressively increased from grade II to grade IV retraction. They did not find breaches of the epithelial basement membrane in any of the studied cases.<sup>9</sup>

Urik et al. performed an immunohistochemical analysis of pars tensa retraction pockets in 31 children. They concluded that there was a significantly higher concentration of Ki67, CD31, CD45, and D2–40 in stage III retraction, when compared with stage II. These markers indicate changes of hyperproliferation, angiogenesis, inflammation, and in the lymphatic endothelium. Inflammatory reactions leading to angiogenesis and hyperproliferation are the basis for development of cholesteatoma. These analyses suggest that stage III pars tensa retractions are precursors for cholesteatoma formation. All these studies suggested that the progression of grades of retraction is a continuous disease process.<sup>8,9</sup>

The pathological importance of retraction pocket lies in the loss of original histological and anatomical structures, which are associated with development of ossicular chain erosion, cholesteatoma formation, and potentially life-threatening complications of cholesteatoma.<sup>11</sup>

The reliable assessment of pars flaccida retraction was much more susceptible to intra- and interobserver variability than the assessment of the extent of pars tensa retraction. The subtle difference between a normal and slightly retracted pars flaccida, and the subjective nature of the assessment of the extent of scutum erosion are the main limitations of these type of studies.<sup>12</sup>

There are various classification systems used for retraction pockets but all of them suffer from poor reliability and correlate poorly with hearing status. In our study, we used the Sade and Tos classification systems for grading pars tensa and pars flaccida retractions, respectively.<sup>13</sup> We preferred to use the Sade and Tos systems, as they are time-tested methods which can be readily applied in the outpatient department.

The management of retraction pockets is challenging and there is no consensus for the management of different grades of retractions.<sup>14</sup> Retraction pockets have been managed based on its staging and symptomatology, ranging from watchful observation to grommet insertion, to surgical strategies.<sup>11,15,16</sup>

Cartilage tympanoplasty is commonly performed for the management of retraction pockets.<sup>17,18</sup> The surgery is performed with the intention of preventing cholesteatoma formation and improving hearing.<sup>19</sup> Comacchio et al. suggested that the surgical management of stage II and III retraction pockets with cartilage grafting can prevent cholesteatoma formation in the future.<sup>20</sup>

In our study, only 7 cases (14%) had normal ossicular status and the remainder had some degree of ossicular erosion. There were 10 cases (20%) with only the stapes footplate in the middle ear. We observed a higher degree (86%) of ossicular damage in our patients, when compared with other studies. This may be due to the longer duration of illness and delayed presentation, given that majority of the patients belonged to lower socio-economic class with limited access to specialized care, and possible negligence on their part, contrary to western literature where patients present early and are better informed.

The cartilage graft obtained from tragal as well as conchal cartilage were used for middle ear reconstruction. The advantage of using conchal cartilage is its accessibility through the same incision site, a bigger donor site, malleability, and its natural contour. The concave shape makes the placement in the attic area favorable. The disadvantage of conchal cartilage use is that it is thinner, and harvest can cause perichondritis.<sup>18,20</sup> These adverse effects were not observed in any of our patients.

Hearing assessment was performed using pure tone audiogram preoperatively, and every three months postoperatively. We observed a significant improvement in mean air conduction postoperatively at all frequencies (0.5, 1, 2, and 4 KHz) with significant closure of the air-bone gap. Previous, similar

studies have reported an improvement in hearing of 6 dB to as high as 18 dB in cases of COM with inactive squamosal disease.<sup>18,21,22</sup> Our finding of an improvement of 12.26 dB agrees with the other studies.

In our study, we observed that 3 cases (6%) had residual perforation. In the study by Kalra et al., they observed 10% cases with residual perforation.<sup>21</sup> Those 3 cases (6%) had decreased hearing, as observed by the increase in air conduction threshold and increased air-bone gap, which could be explained by the stiffness of cartilage reducing the tympanic membrane vibrations and transmission of sound waves into the inner ear. Thick cartilage is also believed to be the cause of dampening of sound vibrations. Kasbekar et al. reported worsening of hearing in 19% cases,<sup>22</sup> with 3 cases (6%) which showed development of retraction in the neotympanum 1 year after surgery. In 2 cases, the cartilage was placed in the posterosuperior region and retraction was observed in the anterior region, and 1 case with posterosuperior placement but pars flaccida retraction showed complete atelectasis. Kalra et al. observed recurrent formation of retraction pockets in 30% of their cases.<sup>21</sup>

Postoperative retraction of the neotympanum occurs in cases of poor tubal function. Reconstruction of the lateral attic wall reduces the incidence of attic retraction recurrence; however, it does not protect the recurrence of pars tensa retraction.<sup>23</sup>

A major limitation of our study was the short duration of the follow-up period. It has been observed that retraction recurrence can happen even after years of stability if the graft is not augmented, because the primary pathology, that is, the Eustachian tube dysfunction, has not been corrected. This brings to notice that more long-term follow-up studies on the development of recurrence, comparing presence and absence of cartilage augmentation are needed in the literature. We also recommend keeping the serial photographs and small video clips of otoendoscopic examinations in the patient's mobile phone itself for future reference.

## Conclusion

We observed good hearing outcomes with low rates of recurrence with cartilage tympanoplasty in inactive squamosal disease.

### Conflict of Interests

The authors have no conflict of interests to declare.

## References

- 1 Urík M, Hurník P, Žiak D, et al. Histological analysis of retraction pocket pars tensa of tympanic membrane in children. *Int J Pediatr Otorhinolaryngol* 2016;86:213–217
- 2 Rosito LPS, Sperling N, Teixeira AR, Selaimen FA, da Costa SS. The Role of Tympanic Membrane Retractions in Cholesteatoma Pathogenesis. *BioMed Res Int* 2018;2018:9817123
- 3 Mansour S, Magnan J, Haidar H, Nicolas K. Tympanic Membrane Retraction Pockets. In: Mansour S, Magnan J, Haidar H, Nicolas K, editors. *Tympanic Membrane Retraction Pocket: Overview and*

- Advances in Diagnosis and Management. Cham: Springer International Publishing; 2015:29–47
- 4 Monsell EM. New and revised reporting guidelines from the Committee on Hearing and Equilibrium. American Academy of Otolaryngology-Head and Neck Surgery Foundation, Inc. *Otolaryngol Head Neck Surg* 1995;113(03):176–178
  - 5 Olusanya BO, Davis AC, Hoffman HJ. Hearing loss grades and the *International classification of functioning, disability and health*. *Bull World Health Organ* 2019;97(10):725–728
  - 6 OpenEpi Menu [Internet]. [cited 2021 Sep 3]. Available from: [https://www.openepi.com/Menu/OE\\_Menu.htm](https://www.openepi.com/Menu/OE_Menu.htm)
  - 7 Sharma R. Revised Kuppaswamy's socioeconomic status scale: Explained and updated. *Indian Pediatr* 2017;54(10):867–870
  - 8 Marchioni D, Grammatica A, Alicandri-Ciuffelli M, Aggazzotti-Cavazza E, Genovese E, Presutti L. The contribution of selective dysventilation to attic middle ear pathology. *Med Hypotheses* 2011;77(01):116–120
  - 9 Shunyu NB, Gupta SD, Thakar A, Sharma SC. Histological and immunohistochemical study of pars tensa retraction pocket. *Otolaryngol Head Neck Surg* 2011;145(04):628–634
  - 10 Urík M, Hurník P, Žiak D, et al. Immunohistochemical analysis of retraction pocket pars tensa of tympanic membrane in children. *Int J Pediatr Otorhinolaryngol* 2019;122:111–116
  - 11 Alper C, Olszewska E. Assessment and management of retraction pockets. *Otolaryngol Pol* 2017;71(01):1–21
  - 12 James AL, Papsin BC, Trimble K, et al. Tympanic membrane retraction: An endoscopic evaluation of staging systems. *Laryngoscope* 2012;122(05):1115–1120
  - 13 Alzahrani M, Saliba I. Tympanic membrane retraction pocket staging: is it worthwhile? *Eur Arch Otorhinolaryngol* 2014;271(06):1361–1368
  - 14 Ramakrishnan Y, Kotecha A, Bowdler DA. A review of retraction pockets: past, present and future management. *J Laryngol Otol* 2007;121(06):521–525
  - 15 Cutajar J, Nowghani M, Tulsidas-Mahtani B, Hamilton J. The Natural History of Asymptomatic Deep Pars Tensa Retraction. *J Int Adv Otol* 2018;14(01):10–14
  - 16 Browning GG, Rovers MM, Williamson I, Lous J, Burton MJ. Grommets (ventilation tubes) for hearing loss associated with otitis media with effusion in children. *Cochrane Database Syst Rev* 2010;(10):CD001801
  - 17 Yung MW. Retraction of the pars tensa—long-term results of surgical treatment. *Clin Otolaryngol Allied Sci* 1997;22(04):323–326
  - 18 Dornhoffer J. Cartilage tympanoplasty: indications, techniques, and outcomes in a 1,000-patient series. *Laryngoscope* 2003;113(11):1844–1856
  - 19 Nankivell PC, Pothier DD. Surgery for tympanic membrane retraction pockets. *Cochrane Database Syst Rev* 2010;(07):CD007943
  - 20 Comacchio F, Mion M, Pedruzzi B. Retraction pocket excision with cartilage grafting as a preventive surgery for cholesteatoma. *J Otol* 2017;12(03):112–116
  - 21 Kalra VK, Yadav SPS, Verma M, Singh B, Goel A. Treatment of Tympanic Membrane Retraction Pockets by Excision and Cartilage Tympanoplasty: A Prospective Study. *Indian J Otolaryngol Head Neck Surg* 2018;70(03):392–394
  - 22 Kasbekar AV, Patel V, Rubasinghe M, Srinivasan V. The Surgical Management of Tympanic Membrane Retraction Pockets Using Cartilage Tympanoplasty. *Indian J Otolaryngol Head Neck Surg* 2014;66(04):449–454
  - 23 Jesic SD, Dimitrijevic MV, Nestic VS, Jotic AD, Slijepcevic NA. Temporalis fascia graft perforation and retraction after tympanoplasty for chronic tubotympanic otitis and attic retraction pockets: factors associated with recurrence. *Arch Otolaryngol Head Neck Surg* 2011;137(02):139–143