



How We Use Immunohistochemistry to Arrive at a Diagnosis in Breast Lesions

Ayushi Sahay¹ Asawari Patil¹ Sangeeta B. Desai¹

¹Department of Pathology, Tata Memorial Centre, Homi Bhabha National Institute, Mumbai, Maharashtra, India

Ind J Med Paediatr Oncol 2022;43:114–119.

Address for correspondence Ayushi Sahay, MD, Professor and Pathologist, Department of Pathology, 8th Floor, Annex Building, Tata Memorial Centre, Homi Bhabha National Institute, Mumbai, Maharashtra, India-400012 (e-mail: ayujain24@gmail.com).

Abstract

Keywords

- ▶ immuno-histochemistry
- ▶ breast cancer
- ▶ biomarker
- ▶ pathology

Immunohistochemistry (IHC) is an essential tool available to pathologists for facilitating diagnosis and as well as guiding the prognosis of breast lesions. Newer markers are increasingly being added to the pathologists' armamentarium. However, the selection and interpretation of the IHC markers should be judicious. In light of an appropriate morphological assessment, they should complement each other and produce accurate reports. We have briefly outlined here the immunohistochemical approach used in the diagnosis and management of breast cancers at our tertiary care cancer center.

Introduction

Breast cancer is one of the most common cancers affecting females worldwide and in India.^{1,2} Although morphological features of breast lesions are well described, immunohistochemical evaluation forms an indispensable component of not only accurate diagnosis but also a prognostic and predictive ancillary tool for breast cancer pathologists. At our high-volume tertiary care cancer center, breast lesions routinely undergo such diagnostic and prognostic evaluation and we briefly outline below our immunohistochemical approach for the different types of lesions encountered.

For diagnosis, appropriate immunohistochemistry (IHC) marker panel is ideally selected in view of the morphological features to address a specific diagnostic query. Prognostic IHC panels, on the other hand, are applied routinely in pathologically (morphologically and/or immunohistochemically) confirmed malignancies for guiding treatment decisions.

Diagnostic IHC

A) Benign versus Malignant?

This is the first and foremost question a pathologist has to answer when viewing a breast biopsy or specimen. Several benign lesions (such as complex sclerosing lesions and radial scar) and in situ tumors can mimic invasive tumors. In the breast, the hallmark of invasion is lack of myoepithelial cells (MECs).³ Both benign and in situ lesions show presence of an intact myoepithelial layer (albeit sometimes discontinuous) and basement membrane around the breast ducts and acini. However, MECs may not always be appreciable on morphology and there are a number of IHC markers available for their identification such as p63, p40, smooth muscle myosin heavy chain (SMMHC), calponin, smooth muscle antigen (SMA), S100, CD10, CK5/6. The absence of staining for MECs indicates invasive cancer. A notable exception is microglandular adenosis that is a benign lesion but lacks MECs; however, it is

DOI <https://doi.org/10.1055/s-0042-1742439>.
ISSN 0971-5851.

© 2022. Indian Society of Medical and Paediatric Oncology. All rights reserved.

This is an open access article published by Thieme under the terms of the Creative Commons Attribution-NonDerivative-NonCommercial-License, permitting copying and reproduction so long as the original work is given appropriate credit. Contents may not be used for commercial purposes, or adapted, remixed, transformed or built upon. (<https://creativecommons.org/licenses/by-nc-nd/4.0/>)

Thieme Medical and Scientific Publishers Pvt. Ltd., A-12, 2nd Floor, Sector 2, Noida-201301 UP, India

Table 1 Commonly used myoepithelial cell markers

Marker	Pattern	Utility	Pitfalls
P63	Nuclear	Best MEC marker with a clean background, no cross-reactivity with stromal myofibroblasts or vascular smooth muscle cells. Highly specific and ~90% sensitive	May show focal gaps/attenuation (discontinuous pattern) around noninvasive epithelial nests (especially CIS) and may also label ACC, papillary Ca, and squamous component of metaplastic Ca in a diffuse fashion
P40	Nuclear	Antibody against an isoform of p63, with similar reactivity and performance	Same as above. May be used interchangeably, but not proven superior to p63 for breast MEC
SMMHC	Cytoplasmic	Slightly higher sensitivity than p63	Cross-reactivity with stromal myofibroblasts and vascular smooth muscle
Calponin	Cytoplasmic	Continuous cytoplasmic linear staining pattern in normal or benign breast tissue, with a focal discontinuous pattern in a few DCIS	A high frequency of cross-reactivity with stromal myofibroblasts and vascular smooth muscle cells as well as occasionally tumor epithelial cells
CD10	Cytoplasmic	Relatively sensitive, no reactivity to vascular smooth muscle cells	Cross-reactivity to myofibroblasts and nonspecific reactivity to epithelial cells
CK 5/6	Cytoplasmic	Identifies MEC as well as useful in benign ductal hyperplasia and papillary breast lesions (usually mosaic) to differentiate from DCIS (usually negative)	Also positive in squamous epithelial cells, basal subtype DCIS and basal-like TNBC

Abbreviations: ACC, adenoid cystic carcinoma; Ca, carcinoma; DCIS, ductal carcinoma in situ; MEC, myoepithelial cells; SMMHC, smooth muscle myosin heavy chain; TNBC, triple-negative breast carcinoma.

identifiable by immunoreactivity for S100 protein and is typically triple negative. Conversely, adenoid cystic carcinoma and metaplastic carcinoma may be positive for MEC markers; however, the location of positivity will not be peripheral or linear.⁴ Various MEC markers and their utilities are shown in ► **Table 1**. In our practice, we use a combination of at least one nuclear (usually p63) and one cytoplasmic MEC marker (usually calponin or SMMHC). Other markers like SMA and S100 show a lot of cross-reactivity with surrounding myofibroblasts (especially in desmoplastic stroma) and blood vessels, limiting interpretation. Importantly, caution should be exercised when evaluating MEC markers in poorly fixed tissue and the presence of internal positive control (adjacent benign ducts) should always be cross-checked before interpreting MEC markers as absent to avoid a false-positive diagnosis of carcinoma.

B) Duct hyperplasia versus in situ cancer?

Increased use of mammographic screening has resulted in increasing biopsies that show a variety of intraductal proliferative lesions. In such biopsies, usual ductal hyperplasia (UDH) may sometimes be difficult to differentiate from atypical ductal hyperplasia (ADH) or in situ cancer (DCIS) of low-to-intermediate grade. Although morphological differences among these entities are well established, adjunctive IHC is a supportive tool in problematic cases. The usual panel includes high molecular weight keratins (HMWCK) like CK5/6, and estrogen receptor (ER): luminal epithelial cells of ADH/low-to-intermediate DCIS showing negativity for the former and diffuse strong expression for the latter, while UDH shows strong positivity for CK5/6 and heterogeneous/patchy ER expression. However, it should be noted that

apocrine metaplasia and columnar cell alteration may also show an absence of CK5/6 and should not be misinterpreted as DCIS.³⁻⁵

C) Ductal neoplasia versus lobular neoplasia?

Invasive lobular carcinomas (ILCs), in general, are more often multifocal, bilateral, and widely metastatic, with worse outcomes, recurrences, and higher mortality than ductal carcinoma. Although ILC is usually easily distinguishable from duct carcinoma due to its typical single file pattern and discohesion, there is marked morphological overlap. ILCs show loss of cell-cell adhesion due to the absence of E-cadherin and/or a dysfunctional cadherin-catenin complex. Diffuse membranous loss of E-cadherin is thus considered diagnostic of ILC, whereas normal ducts and duct carcinoma show diffuse membranous staining. However, it has to be kept in mind that E-cadherin may be retained in up to 15% lobular carcinomas,⁴ or conversely, show a loss in ~10 to 15% of ductal carcinomas, especially in higher grade tumors.⁶ Other members of the cadherin-catenin complex, such as p120 catenin and beta, catenin may serve as useful adjunctive markers in difficult cases. Similar to E-cadherin, p120 shows crisp linear membranous staining in normal breast ducts and duct carcinomas (both in situ and invasive). However, in contrast to E-cadherin, which is a negative marker (loss signifying ILC), p120 is a positive marker showing strong cytoplasmic staining in lobular neoplasia (both in situ and invasive).

Hence, cytoplasmic expression of p120 signifies lobular neoplasia, while membranous expression signifies duct carcinoma.⁴ Beta-catenin mirrors E-cadherin, showing loss of membranous staining in ILC.³ One should always compare

with internal control uninvolved breast ducts while interpreting these markers. Additionally, a diagnosis of ILC should be revisited if the tumor is ER-negative and/or HER2-positive. Hence, for differentiating lobular neoplasia from ductal neoplasia in difficult cases, morphology is useful in conjunction with a panel of these markers.

D) Type of papillary neoplasm?

Papillary neoplasms of the breast are a heterogeneous group. Their spectrum ranges from benign lesions (intraductal papilloma), atypical (ADH involving papilloma, in situ lesions (DCIS arising in papilloma or papillary DCIS), and invasive (solid papillary carcinoma). Encapsulated papillary carcinoma is a borderline lesion considered in situ by some and invasive by other. Diagnosis is usually challenging, especially in biopsies, and IHC is often helpful. The most useful IHC for differential among papillary neoplasms is MECs, which are evaluated at the periphery of the lesion and along the papillary cores.^{6,7}

In addition, the expression of HMWCK, ER, and neuroendocrine markers may also be used in difficult cases. ►Fig. 1 outlines the IHC approach used in our lab for papillary neoplasms. In fragmented biopsies, where encapsulation and periphery of the lesion cannot be reliably identified, an initial impression of a complex papillary neoplasm may be conveyed, deferring definitive diagnosis to a larger specimen.

E) Diagnosis of spindle cell neoplasms (SCN)?

SCN of the breast encompasses a wide spectrum ranging from benign to malignant and epithelial to myoepithelial to mesenchymal in origin. Biopsy interpretation of SCN of the breast is especially challenging due to limited tissue. It is helpful to categorize the lesion as low-grade or high-grade on

initial screening, consider the various differentials of each category, and accordingly choose IHC markers.^{8,9} In high-grade SCN, a differentiation between metaplastic or metastatic carcinoma from primary high-grade sarcoma or malignant phyllodes is particularly poignant due to differences in management, with nodal evaluation and chemotherapy more common for the former rather than latter.^{3,8} No specific IHC is useful to distinguish different grades of phyllodes tumor. ►Table 2 summarizes our diagnostic approach for high-grade and low-grade SCN. Morphological clues are often helpful, particularly the presence or absence of benign ducts or in situ carcinoma. Usually, a panel of markers is selected in light of morphology; however, if uncertainty persists even after morphological and immunohistochemical evaluation on a core biopsy, it is acceptable to exercise caution and issue a preliminary report of “low-grade SCN” or “high-grade SCN” and defer a definitive categorization for the subsequent surgical specimen.

F) Breast primary versus metastasis from other sites?

In almost every case, pathologists are required to identify the possible origin of carcinoma at a metastatic site, and rarely one may even encounter a breast biopsy where the metastasis forms a differential with primary breast carcinoma. IHC evaluation is invaluable in such cases. Aside from a cytokeratin to prove the epithelial nature of the tumor (when lymphoma or melanoma are the differentials), various markers of mammary origin are used to include or exclude the mammary origin of the tumor. Depending on location, other relevant markers used routinely include TTF1 and napsin A (lung origin), PAX8 and WT1 (ovarian origin), CDX2, and SATB2 (GI origin). Markers indicating mammary origin include gross cystic disease fluid protein (GCDFP-15)

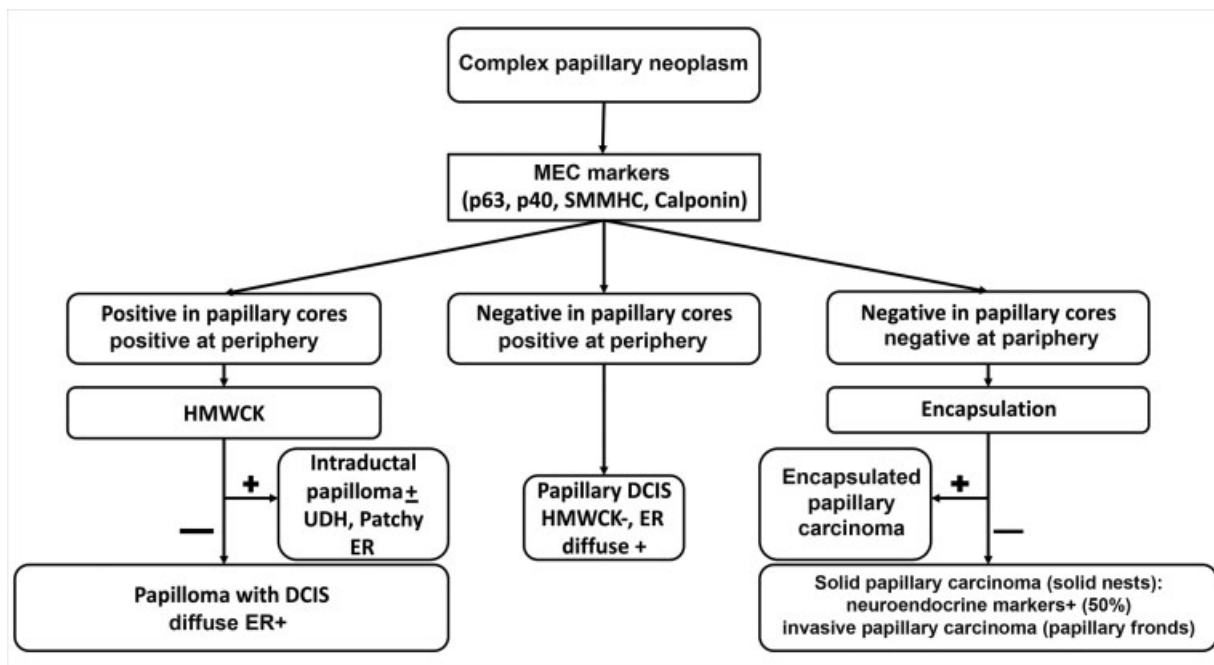


Fig. 1 Stepwise combined morphological and immunohistochemistry approach to the diagnosis of complex papillary neoplasms of breast. DCIS, ductal carcinoma in situ; ER, estrogen receptor; HMWCK, high molecular weight keratins; MEC, myoepithelial cells; SMMHC, smooth muscle myosin heavy chain; UDH, usual ductal hyperplasia.

Table 2 Immunohistochemical features of commonly encountered spindle cell lesions of the breast

Spindle cell neoplasm	Entity	Morphological clues	Immunohistochemistry	
			Positive	Negative
Low-grade	Myofibroblastoma	Bland spindle cells with thick collagen bundles, devoid of mammary ducts	CD34, desmin, variable: SMA, EMA, ER, PR, CD99, BCl2, CD10, S100	Epithelial markers (AE1/AE3, Pan-CK)
	Fibromatosis	Bland spindle cells, collagenous stroma; infiltrative border with chronic inflammation	Diffuse nuclear b-catenin, SMA, desmin ±	S100, CD34, epithelial markers
	Fibromatosis-like metaplastic carcinoma	Spindle cells with tapered nuclei, nuclear atypia and mitosis not prominent; DCIS rare (10–15%)	Epithelial markers (AE1/AE3, pan-CK, or HMWCK), p63, SMA	Desmin, CD34, BCl2, ER, PR, Her2
	Dermato-fibrosarcoma protuberans	Dermal; spindle cells in storiform and whirling pattern; infiltrative edges	CD34, SMA ±	S100, epithelial markers, factor XIIIa
	PASH	Sclerotic stroma; slit-like spaces lined by bland myofibroblastic cells, resembling endothelial cells	CD34, Bcl2, SMA, PR	CD31, ERG, desmin, ER
	Nodular fasciitis	Loose edematous stroma; mitosis usual; extravasated RBCs; inflammatory cells	SMA	Desmin, S100, CD34, epithelial markers
High grade	Metaplastic carcinoma	Malignant in situ/invasive epithelial component—helpful if present	Cytokeratin (AE1/AE3/Pan CK/EMA), SMA ±	CD34, S100, HMB45,
	Malignant phyllodes tumor	Any benign epithelial component—helpful if present	CD34 (30-50%), BCl2, C-kit, SMA ±, CK (rare), p63 (rare)	S100, HMB45
	Sarcoma	Any specific lineage differentiation (myoid, vascular, adipocytic, etc.) if present	As per lineage differentiation	CK, HMB45
	Melanoma	Intracytoplasmic pigment (if present), vesicular nuclei with prominent nucleoli	S100, HMB45, Melan A	CK, EMA, CD34

Abbreviations: CK, cytokeratin; DCIS, ductal carcinoma in situ; EMA, epithelial membrane antigen; ER, estrogen receptor; HMWCK, high molecular weight keratins; PASH, pseudoangiomatous stromal hyperplasia; PR, progesterone receptor; RBCs, red blood cells; SMA, smooth muscle antigen.

and mammaglobin; however, though both show high specificity (>95%), sensitivity is much lower (35–55%). Nonspecific focal staining may also be encountered, limiting diagnostic utility.^{3,10,11} A panel comprising GATA-3 along with various hormonal markers like ER, progesterone receptor (PR), HER2/neu, and androgen receptor (AR) is more commonly used.

GATA3, in contrast to GCDFF-15 and mammaglobin, is a nuclear IHC marker, and has shown a better sensitivity and relatively good specificity for breast cancer.⁴ However, it must always be interpreted with caution in a correct clinical context,

as it is also positive in a variety of other tumors, including urothelial carcinoma, squamous cell carcinoma, pheochromocytoma, parathyroid tumors, paraganglioma, mesothelioma, and choriocarcinoma among others.³ Also, GCDFF-15, mammaglobin as well as GATA3, may be negative in poorly differentiated and triple-negative breast carcinomas (TNBCs).⁴ Importantly, it has to be remembered that most of the above breast markers overlap with skin adnexal and salivary origin high-grade carcinomas. Identification of an associated in situ component or primary location of the tumor in the breast or dermis may be useful clues in this context.

Prognostic IHC

A) Biomarker-based subtyping

Currently, biomarker evaluation of breast cancer is an integral part of the routine histopathological evaluation by providing invaluable prognostic and predictive information. At our institute, the most recent American Society of Clinical Oncology/College of American Pathologists guidelines are followed for ER, PR, and HER2/neu evaluation.^{12,13} A semi-quantitative Allred score for ER and PR is also provided in the report, along with mention of the presence or absence of staining in internal control in ER/PR-negative cases. The classification of breast carcinoma into intrinsic subtypes, that is, luminal A, luminal B, HER2N enriched, and basal-like is a well-known requirement for clinical management, made possible by the addition of Ki-67 to the above IHC, with Ki-67 high classified as luminal B and Ki-67 low as luminal A.¹⁴

However, although initially a cutoff of 14% was proposed and later revised to 20% for Ki-67 high and low,¹⁴ there is sufficient evidence that Ki-67 IHC suffers from vagaries of preanalytical variables, testing methods, and interpretative errors. This leads to marked interobserver variability, limiting its role as a routine biomarker.¹⁵ As per the latest updates, only Ki-67 index <5% or over >30% can be reliably used in T1-2, N0-1 to estimate prognosis.¹⁶ In our practice, Ki-67 detection is performed in histological grade 2, stage I/II, ER+, HER2-IBC, where the distinction between luminal A and B carries relevance for the decision on administration of chemotherapy to the particular cancer patient.

B) Novel markers

With the advent of molecular and cytogenetic techniques, there has been a tremendous increase in our understanding of drivers of breast carcinoma. In certain instances, it has resulted in the availability of advanced treatment options, including targeted therapies. To that effect, the emerging programmed death-ligand 1 (PD-L1) assays are now being routinely performed as a predictive biomarker for the use of immune-checkpoint inhibitor therapy in breast carcinoma. The assays are all approved as “companion diagnostics” with specific drugs but are replete with problems in interpretation and implementation. There are a number of PD-L1 clones, performed on different automated platforms, and each has been approved as a companion predictive marker for a different anti-PD-1 or anti-PD-L1 drug. The tumor types for which a particular PD-L1 clone is predictive are also different, as are the interpretation guidelines. PD-L1 IHC may be interpreted in tumor cells, immune cells or both, depending on tumor type and clone used. Learning to interpret and correctly score PD-L1 also requires training and experience. In certain tumors, a combined positive score (CPS) is considered clinically relevant, while in others a tumor proportion score (TPS), and in yet others proportion of immune cell labeling (IC). The cutoff scores are also variable between different tumors. For example, for urothelial carcinoma, 22C3 pharm DX PD-L1 clone is considered positive when CPS is ≥ 10 , while for Ventana SP142 PD-L1 clone, the corresponding figure is $\geq 5\%$ of IC labeling.¹⁵ Hence, when

performing and evaluating these assays, it is necessary to know which companion drug and tumor it is being performed for, so that the correct PD-L1 clone can be applied and accordingly interpreted. Also, the pathologist's report should always carry the diagnosis of the tumor it is being used for, along with the specific PD-L1 IHC clone and cutoff used. As our knowledge of immunotherapy and predictive biomarkers rapidly evolves, these criteria and parameters are also likely to be updated. Currently, in the breast, positivity for PD-L1 IHC by the Ventana SP142 clone is U.S. Food and Drug Administration approved for the treatment of advanced TNBCs by atezolizumab in combination with nab-paclitaxel.¹⁷ A breast tumor is considered “PD-L1 positive” if it displays PD-L1 positive IC occupying $\geq 1\%$ of the tumor area.¹⁵ IC here includes tumor-infiltrating lymphocytes, as well as plasma cells, neutrophils, and macrophages.

IHC for AR, though not a novel IHC marker, its utility as a predictive marker for selection of TNBC patients likely to benefit from targeted AR inhibitor therapy has recently shown promise. A cutoff of $>1\%$ tumor nuclei expressing AR has shown a response to anti-AR therapy.⁴ At our institute, AR IHC is usually applied in clinically unresponsive/recurrent/metastatic TNBC settings and reported as percentage and intensity of nuclear staining observed.

IHC is a rapid, widely available, and cost-effective technique, which has a number of diagnostic, prognostic as well as predictive applications in breast pathology. One should not forget, however, especially in the Indian context, that most IHC, in general, and biomarkers in particular, are dependent on excellence in standardization. To obtain adequate standardization and quality results, the tissues should be properly fixed and processed, using 10% neutral buffered formalin, with adequate fixation times (6–72 hours). Use of standardized antibodies, detection systems, scoring criteria, and cutoff along with optimal internal validation, participation in internal and external quality assurance programs, and lab accreditation are needed to produce diagnostically accurate and reproducible reports for guiding patient management.^{18,19}

Authors' Contributions

AS was involved in conceptualization, designing, intellectual content, literature search, manuscript preparation, editing and review. SBD and AP contributed substantially in designing, intellectual content, manuscript editing and review.

Conflicts of Interest and Source of Funding

The authors declare there is no conflict of interest. This work has not received funding from any source. The manuscript has been read and approved by all the authors, and requirements for authorship have been met. All authors believe that this manuscript represents honest work.

References

- 1 Nair N, Shet T, Parmar V, et al. Breast cancer in a tertiary cancer center in India - an audit, with outcome analysis. *Indian J Cancer* 2018;55(01):16–22

- 2 Rangarajan B, Shet T, Wadasadawala T, et al. Breast cancer: an overview of published Indian data. *South Asian J Cancer* 2016;5(03):86–92
- 3 Liu H. Application of immunohistochemistry in breast pathology: a review and update. *Arch Pathol Lab Med* 2014;138(12):1629–1642
- 4 Peng Y, Butt YM, Chen B, Zhang X, Tang P. Update on immunohistochemical analysis in breast lesions. *Arch Pathol Lab Med* 2017;141(08):1033–1051
- 5 Zaha DC. Significance of immunohistochemistry in breast cancer. *World J Clin Oncol* 2014;5(03):382–392
- 6 Jorns JM. Papillary lesions of the breast: a practical approach to diagnosis. *Arch Pathol Lab Med* 2016;140(10):1052–1059
- 7 Varga Z, Mallon E. Histology and immunophenotype of invasive lobular breast cancer. daily practice and pitfalls. *Breast Dis* 2008–2009–2009;30:15–19
- 8 Tse GM, Ni YB, Tsang JY, et al. Immunohistochemistry in the diagnosis of papillary lesions of the breast. *Histopathology* 2014;65(06):839–853
- 9 Tay TKY, Tan PH. Spindle cell lesions of the breast - an approach to diagnosis. *Semin Diagn Pathol* 2017;34(05):400–409
- 10 Rakha EA, Aleskandarany MA, Lee AH, Ellis IO. An approach to the diagnosis of spindle cell lesions of the breast. *Histopathology* 2016;68(01):33–44
- 11 Allison KH, Hammond MEH, Dowsett M, et al. Estrogen and progesterone receptor testing in breast cancer: ASCO/CAP guideline update. *J Clin Oncol* 2020;38(12):1346–1366
- 12 Wolff AC, Hammond MEH, Allison KH, et al. Human epidermal growth factor receptor 2 testing in breast cancer: American Society of Clinical Oncology/College of American Pathologists Clinical Practice Guideline focused update. *J Clin Oncol* 2018;36(20):2105–2122
- 13 Nielsen TO, Leung SCY, Rimm DL, et al. Assessment of Ki67 in breast cancer: updated recommendations from the International Ki67 in Breast Cancer Working Group. *J Natl Cancer Inst* 2021;113(07):808–819
- 14 Goldhirsch A, Winer EP, Coates AS, et al; Panel members. Personalizing the treatment of women with early breast cancer: highlights of the St Gallen International Expert Consensus on the Primary Therapy of Early Breast Cancer 2013. *Ann Oncol* 2013;24(09):2206–2223
- 15 Cimino-Mathews A. Novel uses of immunohistochemistry in breast pathology: interpretation and pitfalls. *Mod Pathol* 2021;34(Suppl 1):62–77
- 16 Schmid P, Adams S, Rugo HS, et al; IMpassion130 Trial Investigators. Atezolizumab and nab-paclitaxel in advanced triple-negative breast cancer. *N Engl J Med* 2018;379(22):2108–2121
- 17 Desai SB. Breast cancer pathology reporting in the Indian context: need for introspection. *Indian J Pathol Microbiol* 2020;63(Supplement):S3–S4
- 18 Shet T. Ki-67 in breast cancer: simulacra and simulation. *Indian J Cancer* 2020;57(03):231–233
- 19 Shet T. Improving accuracy of breast cancer biomarker testing in India. *Indian J Med Res* 2017;146(04):449–458