

Endoscopic hemostasis for tumor bleeding using intraductal radiofrequency ablation

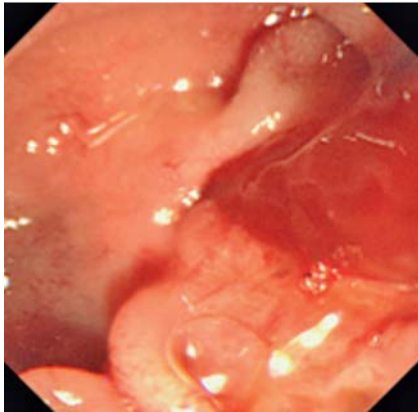


Fig. 1 Endoscopic view showing bleeding from the ampulla of Vater.

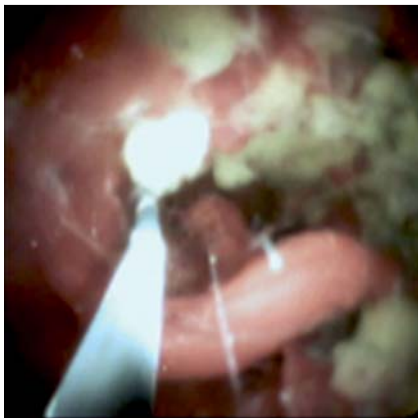
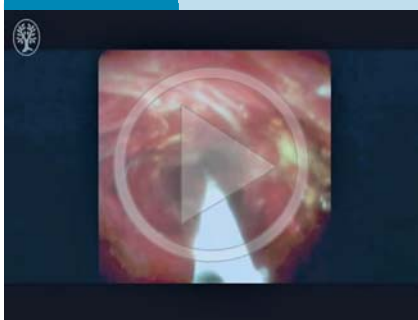


Fig. 2 Image during digital cholangioscopy showing tumor bleeding.

Video 1

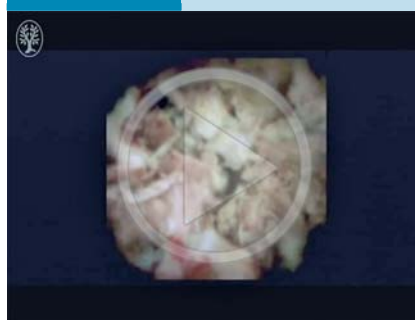


Digital cholangioscopy showing evidence of bleeding, although active bleeding was not seen.

Bleeding hepatobiliary tumors can sometimes be critical in patients with advanced malignancy. Several methods can be used to achieve hemostasis, such as the placement of a covered metal stent or vessel coiling under angiographic control. If tumor bleeding occurs near the mid or lower bile duct, a fully covered metal stent can be placed for hemostasis; however, this method may be challenging if there is bleeding at the hepatic hilum or when bleeding is inactive. Recently, intraductal radiofrequency ablation (RFA) has been reported to provide prolonged stent patency [1,2]. This technique may however also be clinically useful for achieving hemostasis. Herein, we present technical tips for achieving hemostasis of tumor bleeding using intraductal RFA.

An 80-year-old man with a history of uncovered metal stent insertion for advanced cholangiocarcinoma was admitted to our hospital with frequent cholangitis and anemia secondary to tumor bleeding. We needed to achieve hemostasis and insertion of an endoscopic retrograde cholangiopancreatography (ERCP) catheter into the common bile duct revealed bleeding from the ampulla of Vater (▶ **Fig. 1**). Next, using a guidewire, we inserted a digital cholangioscope (Spy-Glass Direct Visualization System) into

Video 2



Digital cholangioscopy showing necrotic tissue, with hemostasis having been successfully achieved by radiofrequency ablation.




Fig. 3 The 8-Fr bipolar probe that was used to perform intraductal radiofrequency ablation.

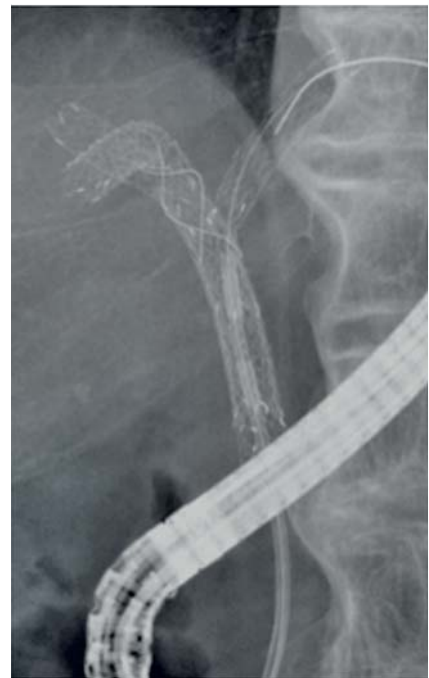

Fig. 4 Radiographic view showing the radiofrequency ablation probe positioned in the bile duct.

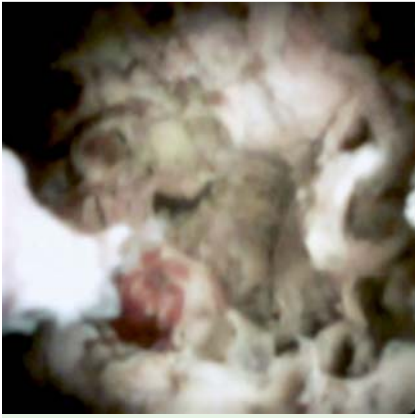

Fig. 5 Digital cholangioscopic view showing that hemostasis had been obtained by radiofrequency ablation.

the biliary tract and demonstrated tumor bleeding (▶ Fig. 2; ▶ Video 1). An 8-Fr bipolar probe (Habib EndoHPB catheter; EMcision Ltd., London, UK) (▶ Fig. 3) was inserted to the bleeding site (▶ Fig. 4) and through this energy was delivered by an RFA generator (VIO 200D), supplying

electrical energy at 350 kHz (effect 8) and 10 W for 90 seconds. Thereafter, a digital cholangioscope was inserted and showed that, with this procedure, hemostasis had been achieved without any adverse effects (▶ Fig. 5; ▶ Video 2).

Although this patient had previously experienced frequent cholangitis and anemia because of tumor bleeding, after this procedure, he had no further episodes of cholangitis or anemia until his death 2 months later. RFA has clinical utility not only for tumor ablation, but also for hemostasis of bleeding tumors.

Endoscopy_UCTN_Code_TTT_1AR_2AF

Competing interests: None

**Takeshi Ogura, Wataru Takagi,
Saori Ueno, Toshihisa Takeuchi,
Shinya Fukunishi, Kazuhide Higuchi**

Second Department of Internal Medicine,
Osaka Medical College, Osaka, Japan

References

- 1 Rustagi T, Jamidar PA. Intraductal radiofrequency ablation for management of malignant biliary obstruction. *Dig Dis Sci* 2014; 59: 2635–2641
- 2 Yoon WJ, Kim YT, Daghilar ES et al. Evaluation of bipolar radiofrequency ablation for occluded self-expandable metal stents in the bile duct: in vivo and in vitro study. *Endoscopy* 2015; 47: 1167–1170

Bibliography

DOI <http://dx.doi.org/10.1055/s-0042-117222>
Endoscopy 2016; 48: E328–E329
 © Georg Thieme Verlag KG
 Stuttgart · New York
 ISSN 0013-726X

Corresponding author

Takeshi Ogura, MD, PhD
 Second Department of Internal Medicine
 Osaka Medical College
 2-7 Daigaku-machi, Takatsuki-shi
 Osaka 569-8686
 Japan
 Fax: +81-72-6846532
 oguratakeshi0411@yahoo.co.jp