# First reports of esophageal adenocarcinoma with white globe appearance in Japanese and Caucasian patients

**Authors** Yusuke Tonai[1], Ryu Ishihara[1], Yasushi Yamasaki[1], Takashi Kanesaka[1], Sachiko Yamamoto[1], Tomofumi Akasaka[1], Noboru Hanaoka[1], Yoji Takeuchi[1], Koji Higashino[1], Noriya Uedo[1], Yasuhiko Tomita[2], Hiroyasu Iishi[1]

**Institutions** [1] Department of Gastrointestinal Oncology, Osaka Medical Center for Cancer and Cardiovascular Diseases, Osaka, Japan
[2] Department of Pathology and Cytology, Osaka Medical Center for Cancer and Cardiovascular Diseases, Osaka, Japan

**submitted** 9. May 2016
**accepted after revision** 29. July 2016

**Bibliography**
**DOI** http://dx.doi.org/10.1055/s-0042-114983
Published online: 14.9.2016
Endoscopy International Open 2016; 04: E1075–E1077
© Georg Thieme Verlag KG Stuttgart · New York
E-ISSN 2196-9736

**Corresponding author**
***Ryu Ishihara, MD***
Department of Gastrointestinal Oncology
Osaka Medical Center for Cancer and Cardiovascular Diseases
1-3-3 Nakamichi, Higashinari-ku
Osaka 537-8511
Japan
Fax: +81-6-6981-4067
isihara-ry@mc.pref.osaka.jp

**License terms**

**Background and study aims:** Better endoscopic diagnosis in case of Barrett's esophagus is still needed. White globe appearance (WGA) is a novel endoscopic marker for gastric adenocarcinoma, with high sensitivity for differentiating between gastric cancer/high-grade dysplasia and other lesions. We report 2 cases of esophageal adenocarcinoma with WGA. In Case 1, esophagogastroduodenoscopy (EGD) revealed a 10-mm esophageal adenocarcinoma in a 48-year-old Japanese woman with short-segment Barrett's esophagus. A small (<1 mm) white globular lesion, typical of WGA, was observed under the epithelium by magnifying narrow-band imaging. A dilated neoplastic gland with eosinophilic material and necrotic epithelial fragments was identified at the site of the WGA by histologic examination. In Case 2, EGD revealed a 5-mm esophageal adenocarcinoma in a 60-year-old Caucasian man with long-segment Barrett's esophagus. A typical WGA was observed by magnifying narrow-band imaging and similar histologic findings were identified at the site of the WGA. WGA could be a reliable endoscopic finding for target biopsy in esophageal adenocarcinoma, if its specificity is as high as in gastric cancer. The clinical implications of WGA in patients with Barrett's esophagus should be investigated further.

## Introduction

The incidence of esophageal adenocarcinoma is rapidly increasing, particularly in Europe and North America. This disease has a poor prognosis when detected at an advanced stage [1], and prevention of death from esophageal adenocarcinoma has therefore focused on its early detection. Gastroenterology society guidelines recommend endoscopic surveillance of Barrett's esophagus with targeted biopsies of visible lesions and random 4-quadrant biopsies every 2 cm. However, dysplasia and early cancer in patients with Barrett's esophagus may present with subtle changes not visible during endoscopic observation. In addition, random biopsies are subject to sampling errors because only a small fraction of the esophagus is biopsied. Techniques to improve the efficacy of endoscopic diagnosis are therefore highly desirable.

White globe appearance (WGA) was recently reported as a novel endoscopic marker for gastric adenocarcinoma [2]. WGA represents a small (<1 mm) white globular lesion located underneath the epithelium, which is visualized more clearly with narrow-band imaging (NBI) than with white-light imaging. WGA is frequently observed in gastric adenocarcinomas and has high specificity for differentiating between early gastric adenocarcinoma and non-cancerous mucosa [3]. However, there have been no reports of WGAs in other organs. We herein report the first two cases of Barrett's esophageal cancer with typical WGA.

## Case reports

### Patient 1

An asymptomatic 48-year-old Japanese woman with a history of prolactinoma was referred to our hospital for treatment of esophageal adenocarcinoma. Esophagogastroduodenoscopy (EGD) revealed a slightly red, depressed lesion, 10 mm in diameter, in short-segment Barrett's esophagus (**Fig. 1**). Magnifying narrow-band imaging (M-NBI) revealed no surface structure pattern and a mildly irregular vascular pattern with a clear demarcation line. A small (<1 mm) white globular lesion located under the cancerous Barrett's epithelium, typical of WGA, was observed close to the demarcation line in M-NBI (**Fig. 1**). Endoscopic submucosal dissection (ESD) was performed using a ball-tip Flush knife (BT) (1.5 mm,

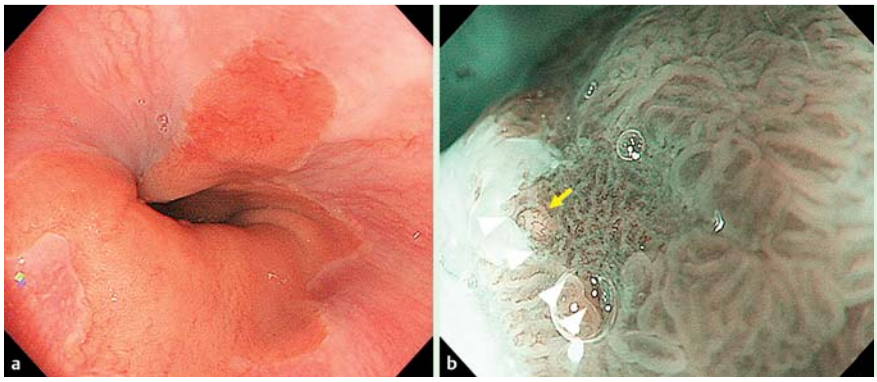

**Fig. 1** **a** In white light imaging, a slightly red, depressed lesion, 10 mm in diameter, was revealed in short-segment Barrett's esophagus. **b** Endoscopic image of white globe appearance (WGA) in magnifying narrow-band imaging (yellow arrow). WGA is observed closed to the demarcation line (white arrow head).

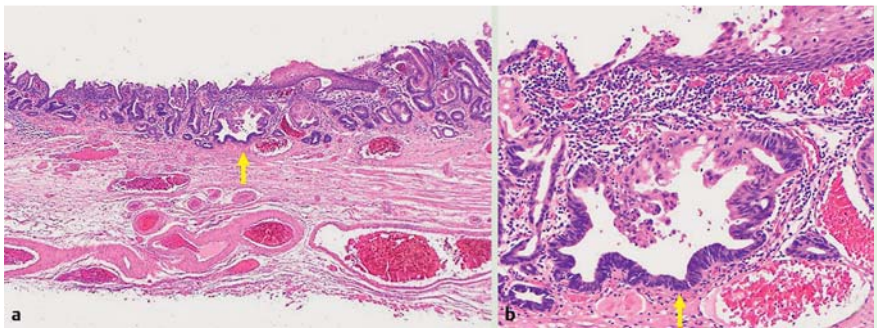

**Fig. 2** **a** Histologic image of intraglandular necrotic debris (yellow arrow). The lesion was identified at the site of the white globe appearance. **b** Magnified view of ▶ **Fig. 2 a**.

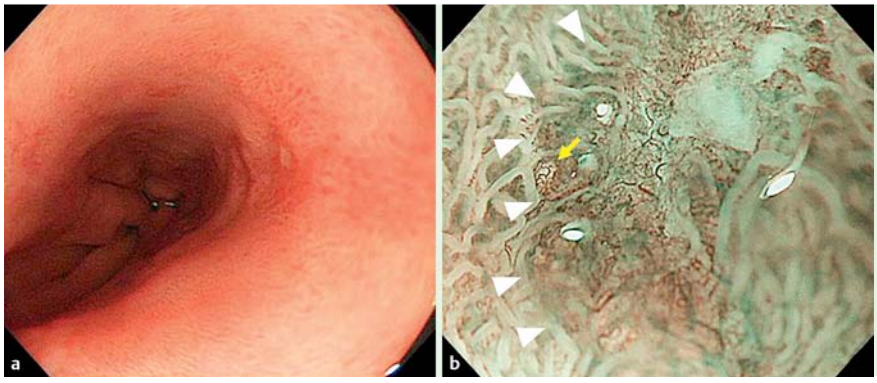

**Fig. 3** **a** In white light imaging, a slightly red, depressed lesion, 5 mm in diameter, was revealed in long-segment Barrett's esophagus. **b** Endoscopic image of white globe appearance in magnifying narrow-band imaging (yellow arrow). WGA is observed closed to the demarcation line (white arrow head).

Fujifilm Medical, Tokyo, Japan), and en bloc resection was achieved with no adverse events.

Histologic examination of the resected specimen revealed a well-differentiated adenocarcinoma, 10 mm in diameter, limited to the superficial muscularis mucosa, without lymphovascular involvement. A dilated neoplastic gland with eosinophilic material and necrotic epithelial fragments, typical of intraglandular necrotic debris (IND), was identified at the site of the WGA (▶ **Fig. 2**).

## Patient 2

An asymptomatic 60-year-old Caucasian man was referred to our hospital for treatment of esophageal adenocarcinoma. EGD revealed a slightly red, depressed lesion, 5 mm in diameter, in long-segment Barrett's esophagus (▶ **Fig. 3**). The lesion showed no surface structure pattern and a mildly irregular vascular pattern with a clear demarcation line in M-NBI, and a typical WGA close to the demarcation line (▶ **Fig. 3**). ESD was performed using a Flush knife BT, and en bloc resection was achieved with no adverse events.

Histologic examination of the resected specimen revealed a well-differentiated adenocarcinoma, 5 mm in diameter, limited to the superficial muscularis mucosa, without lymphovascular involvement. The typical finding of IND was identified at the site of the WGA (▶ **Fig. 4**).

## Discussion

We herein report the first Japanese and Caucasian cases of Barrett's esophageal cancer with WGA. Doyama et al. reported that WGA was a good marker for gastric neoplasia, and showed that WGA corresponded to IND, defined as eosinophilic material with necrotic epithelial fragments within the lumen of a dilated gland [2]. IND is a histologic marker for high-grade dysplasia or invasive carcinoma of the stomach; 25 of 58 high-grade dysplasias or invasive carcinomas had IND, and only 1 of 77 other types of lesions had IND [4]. The sensitivity and specificity of IND for high-grade dysplasia or invasive carcinoma were 43.1 % and 98.7 %, respectively [4]. IND has also been identified in adenocarcinomas in other organs, including the esophagus, but is rarely observed in normal mucosa [5–9], suggesting that it may also act as a marker for Barrett's esophageal cancer.

The clinical utility of WGA was evaluated by Yoshida et al. and Doyama et al. The sensitivity and specificity of WGA for differen-

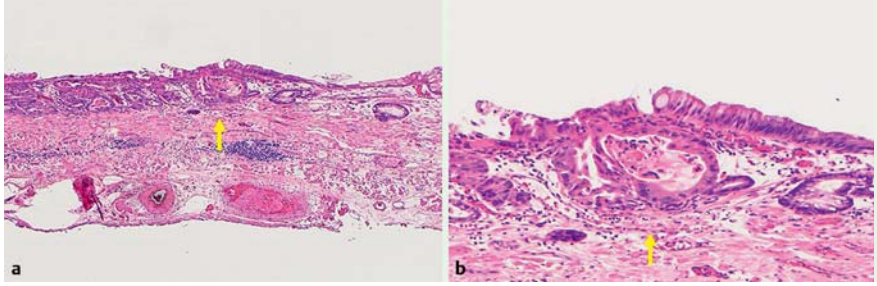

**Fig. 4** **a** Histologic image of intraglandular necrotic debris (yellow arrow). The lesion was identified at the site of the white globe appearance. **b** Magnified view of **Fig. 4a**.

tiating gastric cancer or high-grade dysplasia from other lesions were 21.4% and 97.5%, respectively [3], and for differentiating gastric cancer or high-grade dysplasia from low-grade adenoma were 21.5% and 100%, respectively [2]. The sensitivity of WGA was lower than that of IND, probably because IND is located just beneath the gastric epithelium and can therefore be observed by magnifying endoscopy and identified as WGA. However, despite its low sensitivity, its high specificity makes WGA a valuable endoscopic marker for gastric cancer.

Although the current cases provide the first reports of WGA in esophageal adenocarcinoma, this finding is probably not rare, and the failure to detect WGA may be because of a lack of familiarity with this finding. Given that we identified WGA in 2 consecutive cases of Barrett's esophageal cancer in our hospital, it is likely that more cases will be identified in the near future in line with increased awareness of WGA.

The development of endoscopic modalities such as NBI and magnifying imaging have facilitated the detection and diagnosis of gastrointestinal cancer. However the diagnosis of Barrett's esophageal cancer remains challenging, mainly because of concomitant inflammation. Gastroenterology society guidelines recommend endoscopic surveillance of Barrett's esophagus with targeted biopsies of visible lesions and random 4-quadrant biopsies every 2 cm. However, there are few reliable and accurate endoscopic findings for identifying targeted biopsies, and the results are therefore not satisfactory. Although WGA requires low- to high-magnification observation, it could offer a reliable endoscopic finding for targeting biopsies if its specificity is as high as in gastric cancer. Further studies are therefore needed to investigate the clinical implications of WGA.

## Conclusion

Previous reports of WGA have only included Japanese patients with gastric lesions. We herein report 2 cases of Barrett's esophageal cancer with WGA, 1 in a Japanese and the other in a Caucasian patient, thus confirming the potential presence of WGA in the esophagus as well as the stomach, and in Caucasian as well as Japanese individuals.

**Competing interests:** None

## References


1 *Rubenstein JH*, *Shaheen NJ*. Epidemiology, diagnosis, and management of esophageal adenocarcinoma. Gastroenterology 2015; 149: 302–317
2 *Doyama H*, *Yoshida N*, *Tsuyama S* et al. The "white globe appearance" (WGA): a novel marker for a correct diagnosis of early gastric cancer by magnifying endoscopy with narrow-band imaging (M-NBI). Endosc Int Open 2015; 03: E120–E124
3 *Yoshida N*, *Doyama H*, *Nakanishi H* et al. White globe appearance is a novel specific endoscopic marker for gastric cancer: A prospective study. Dig Endosc 2016; 28: 59–66
4 *Watanabe Y*, *Shimizu M*, *Itoh T* et al. Intraglandular necrotic debris in gastric biopsy and surgical specimens. Ann Diagn Pathol 2001; 5: 141–147
5 *Jass JR*. Classification of colorectal cancer based on correlation of clinical, morphological and molecular features. Histopathology 2007; 50: 113–130
6 *Caruso RA*, *Napoli P*, *Nania A* et al. Mitochondrion-rich differentiated adenocarcinomas of the stomach: clinicopathological, immunohistochemical and electron microscopy study of nine cases. Virchows Arch 2010; 456: 499–505
7 *Dutta S*, *Going JJ*, *Crumley AB* et al. The relationship between tumour necrosis, tumour proliferation, local and systemic inflammation, microvessel density and survival in patients undergoing potentially curative resection of oesophageal adenocarcinoma. Br J Cancer 2012; 106: 702–710
8 *Bronner MP*. Barrett's esophagus. The Korean J Helicobacter Up Gastrointest Res 2014; 14: 131–162
9 *Kannuna H*, *Rubio CA*, *Silverio PC* et al. DOME/GALT type adenocarcinoma of the colon: a case report, literature review and a unified phenotypic categorization. Diagn Pathol 2015; 10: 92–99