

Erratum

Radiation Retinopathy 15 Years after Orbital Irradiation for Thyroid Orbitopathy

K. Hurtikova, G. von Arx, N. Fichter, H. Gerding

Klin Monatsbl Augenheilkd 2016; 233: 508–510

In the article “Radiation Retinopathy 15 Years after Orbital Irradiation for Thyroid Orbitopathy” [1] we inadvertently submitted two angiographic images (● Fig. 1 c and 1 d) of another publication in the same issue [2]. The correct images are provided below. We regret any confusion caused by this error.

1 Hurtikova K, von Arx G, Fichter N, Gerding H. Radiation Retinopathy 15 Years after Orbital Irradiation for Thyroid Orbitopathy. Klin Monatsbl Augenheilkd 2016; 233: 508–510

2 Hurtikova K, Tschuppel S, Gerding H. Retinopathy after 30 Gray Whole Brain Radiation. Klin Monatsbl Augenheilkd 2016; 233: 511–513

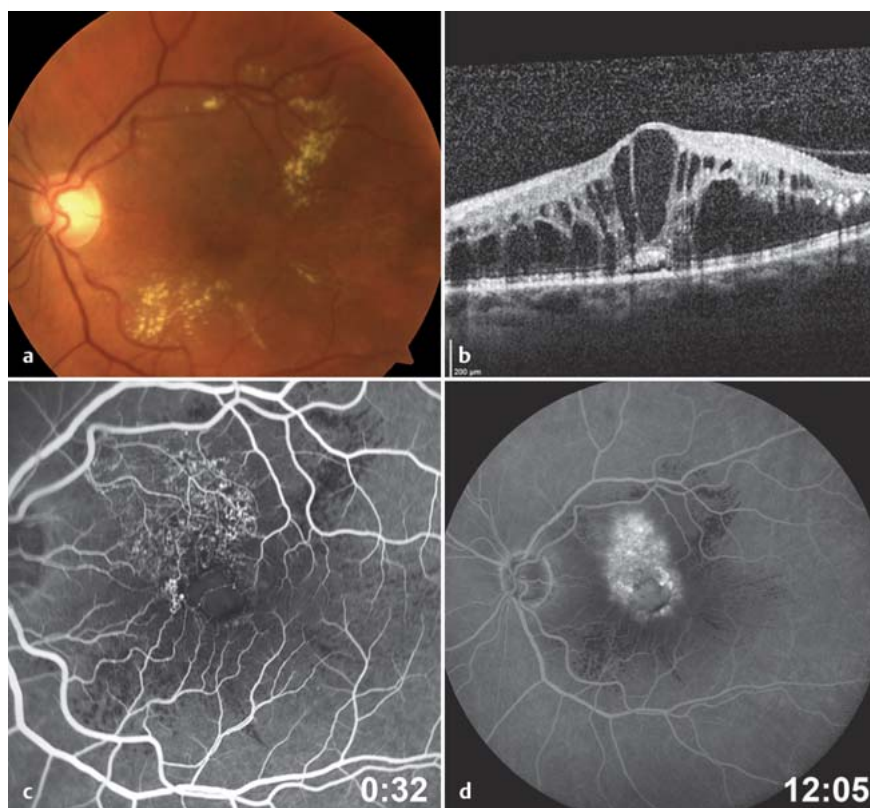


Fig. 1 Fundus color photograph (a), horizontal SD-OCT section (b), and fluorescence angiography (c and d) of the 55-year-old patient presenting radiation retinopathy 15 years after treatment of thyroid orbitopathy.