

A novel mechanical simulator for cannulation and sphincterotomy after Billroth II or Roux-en-Y reconstruction

Authors

Eckart Frimberger¹, Mohamed Abdelhafez^{1,2}, Roland M. Schmid¹, Stefan von Delius¹

Institutions

¹ II. Medizinische Klinik und Poliklinik, Klinikum rechts der Isar der Technischen Universität München, Munich, Germany
² Gastrointestinal Endoscopy Unit, Kasr Alainy Hospital, Cairo University, Cairo, Egypt

submitted

31. December 2015

accepted after revision

17. May 2016

Bibliography

DOI <http://dx.doi.org/10.1055/s-0042-111905>
 Published online: 8.8.2016
 Endoscopy International Open 2016; 04: E922–E926
 © Georg Thieme Verlag KG
 Stuttgart · New York
 E-ISSN 2196-9736

Corresponding author

Stefan von Delius, MD
 Klinikum rechts der Isar der
 Technischen Universität
 München
 II. Medizinische Klinik
 Ismaninger Str. 22
 81675 Munich
 Germany
 Fax: +49-89-41404905
 stefan.delius@mri.tum.de

Introduction: In patients with Billroth II (B II) or Roux-en-Y anatomy, endoscopic retrograde cholangiopancreatography (ERCP) is demanding. Here, we describe a novel simulator with simulated fluoroscopy for cannulation and sphincterotomy training in such situations.

Methods: A custom-made simulation system was built based upon a common chassis of a series of previously described ERCP simulators. The papilla is made out of organic material and can be cut by high frequency current. The advancement of guidewires and other instruments within transparent mock bile ducts can be viewed in the window of the simulator without the need for fluoro-

scopy. The ERCP B II/Roux-en-Y simulation system was first evaluated during an ERCP course.

Results: There were no technical problems related to the novel simulator during the course. After sphincterotomy, the organic papillae could easily be exchanged within a few seconds. Overall, the novel B II/Roux-en-Y simulator achieved favorable results by trainees and expert endoscopists in all categories assessed.

Conclusions: The new B II/Roux-en-Y mechanical simulator is simple and practicable. A first evaluation during an ERCP course showed promising results.

Introduction

In patients with Billroth II (B II) or Roux-en-Y reconstruction, cannulation of the papilla and successful sphincterotomy are challenging due to an altered anatomy [1–5]. Exposure to actual B II or Roux-en-Y cases in training is very limited and variable. This raises the demand for a competent and convenient training simulator that allows trainees to acquire the required skills and orientation before starting the application in real life practice. Although a variety of simulators have been developed for ERCP training purposes, none of them has addressed cannulation and sphincterotomy in the situation following B II or Roux-en-Y reconstruction [6–12].

Herein, we present the description, introduction, and first evaluation of a novel ERCP mechanical simulator (EMS) with simulated fluoroscopy, designed especially for ERCP training on cannulation and sphincterotomy of the papilla in the setting of B II or Roux-en-Y, using variable accessories and endoscopes. To the best of our knowledge, this is the first EMS described in the literature that is dedicated to B II or Roux-en-Y training.

Material and methods

Description of the simulation system

The new simulator is a further, newly developed component of a previously described ERCP training system [9]. The common features of the different types of simulators currently available are the chassis, the artificial biliopancreatic ducts that can be observed through a window of the simulator without the need for fluoroscopy, the duodenum mounted on a carriage, and the mounting elements for fixing the simulators onto the endoscopy trolley (► Fig. 1). In contrast to the ERCP simulators of the series resembling normal anatomy [9], papillae of the B II/Roux-en-Y simulator have a different orientation with the bile duct system adapted to this orientation. The simulator is custom-made, and was invented by one of the authors (EF).

When the endoscope is introduced into the simulator, after having passed the curved intubation tube, it reaches the duodenum with the papilla. Instruments introduced into and beyond the papilla become visible in the transparent bile duct in the window of the simulator. For fixing the papilla, a sliding carriage is pulled down with a lever at the bottom of the simulator (► Fig. 2). Two

License terms



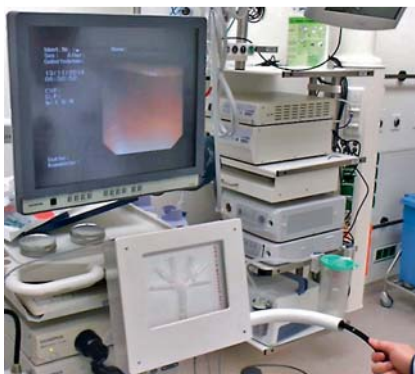

Fig. 1 B II/Roux-en-Y simulator fixed on an endoscopy trolley below the monitor. In the window of the simulator a guidewire inserted through the papilla is visible.



Fig. 2 B II/Roux-en-Y simulator. The sliding carriage, which is otherwise not visible, is pulled out for insertion of the papilla. The duodenum is mounted onto the carriage. In the window, the transparent bile duct is visible.

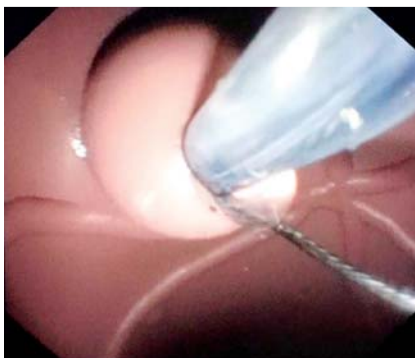


Fig. 3 Robust papilla made of rubber. It is meant for the initial training of B II beginners.



Fig. 4 Organic papillae ready for training. The metal coil at its end serves for fixing it to the simulator.



Fig. 5 The papilla is inserted into the opening of the duodenum and fixed to the mount by gently pressing its metal coil into the groove of the mount. The metal coil serves for grounding the papilla via the mount connected to a socket at the back. When the carriage is closed, the coil leads instruments inserted into the papilla into the bile duct. This can be viewed in the window of the simulator.

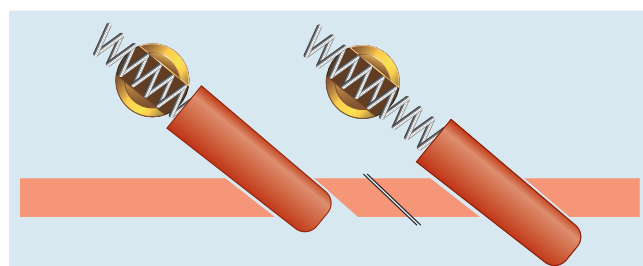


Fig. 6 The working length of the papilla, that is the portion protruding into the duodenum, is adjustable according to the purpose of the training given. The working length is adjusted by varying the fixation point of the metal spring to the mount. On the left, a short portion of the papilla is visible inside the duodenum. A far protruding papilla (right) allows the trainee to practice a longer cut than in reality. This gives them a better opportunity to learn the handling of the sphincterotomes or needle knives in combination with the application of HF current.

types of papillae are available. One is made out of rubber and is meant for initial intubation attempts, with catheters and guidewires, by B II/Roux-en-Y debutants (● Fig. 3). It cannot be cut by high frequency (HF) current.

The papillae for sphincterotomy consist of a metal spring embedded into the organic part of the papilla (● Fig. 4). Both the papilla and the metal spring have a canal through which inserted instruments can easily pass. The length of the channel inside the papilla

is 19 mm; this includes a 6-mm spiral (inner diameter 2.5 mm) inserted into the papilla. The diameter of the distal channel of the papilla without spiral is about 1 mm and can be easily cannulated due to the elasticity of the organic material. Placement of small caliber stents is also possible before needle-knife papillotomy. The papillae are fixed by pressing the spiral into the groove of the mount and can be easily removed again (● Fig. 5). The total length of the organic part of the papilla is 19 mm. The portion of the papilla protruding into the duodenum is adjustable according to the purpose of the training being given (● Fig. 6). A far protruding papilla, e.g. 14 mm, offers the trainee a large surface for practicing needle-knife cuts. The length is adjusted by varying the fixation point of the metal spring to the mount. The evolution of the papillae, influenced by course experiences, has resulted in them being easily intubated if done carefully. If approached inappropriately, not in line with its axis, the papilla is perforated, which corresponds to unsuccessful cannulation attempts in a patient. If the introduced guidewire does not appear in the window showing the bile duct, this indicates an inadequate technique.

► **Video 1** shows intubation of the afferent loop and reaching the papilla using both forward (CF-HQ 190I, Olympus Germany, Hamburg, Germany) and side viewing endoscopes (TJF-160VR, Olympus). Cannulation of the papilla is performed using an ERCP cannula (Contour ERCP cannula, Boston Scientific, Natick, MA, United States) and a guidewire (Jagwire, Boston Scientific). Successful cannulation of the biliary system is confirmed through the transparent window of the simulator. Exchange of the papilla is easy and fast, as is controlling its length.

► **Video 2** shows cannulation of the organic papilla using a B II sphincterotome (Billroth II Sphincterotome, COOK Ireland, Limerick, Ireland) and a guidewire (Jagwire, Boston Scientific), followed by cutting the papilla in the 5 o'clock direction using HF current (VIO 300, Erbe Elektromedizin, Tübingen, Germany) with the settings ENDO CUT I, effect 1, cutting duration 2, and cutting interval 3. Another sphincterotomy is performed after inserting a 5 Fr stent in the papilla, using a needle-knife (Huibregtse® Triple Lumen Needle Knife, COOK Ireland) also in the 5 o'clock direction with the above mentioned HF settings (► **Fig. 7**).

Evaluation

Evaluation of the B II/Roux-en-Y simulator was prospectively conducted on two levels (trainees and experts). The trainees' evaluation was performed in March 2015, during an annual ERCP training course at the II. Medizinische Klinik, Klinikum rechts der Isar, Technische Universität München, Germany.

A total of 10 trainees with previous ERCP experience practiced on the simulator for cannulation of the papilla and sphincterotomy. The experts' evaluation was collected from 11 ERCP experts with previous Billroth II and Roux-en-Y experience who supervised the training on this simulator during different training courses. The experts evaluated the realism of the simulator in comparison to real life ERCP in Billroth II and Roux-en-Y, as well as its utility as a teaching modality. The trainees and the experts were asked

to complete an evaluation questionnaire about their experience and assessment of the simulator. The questionnaires were adopted from previously published studies and the following criteria were scored using a seven-point Likert scale (1=poor, 7=excellent) [9, 13,14].

Trainees' questionnaire: (1) Practicing with this simulator improved my specific skills, (2) I would like to continue exercising with this simulator in my further training, (3) training with this simulator reduces the risks for patients in my opinion, and (4) I would recommend this simulator.

Experts' questionnaire: Realism: (1) tissue pliability, (2) papillary anatomy, (3) visual realism, (4) cannulation realism, (5) overall simulation realism. Advantages for training: (6) usefulness in teaching advanced ERCP, (7) ease of use, (8) utility as a training modality, (9) ease of integration in a training program, and (10) learning success of the trainees.

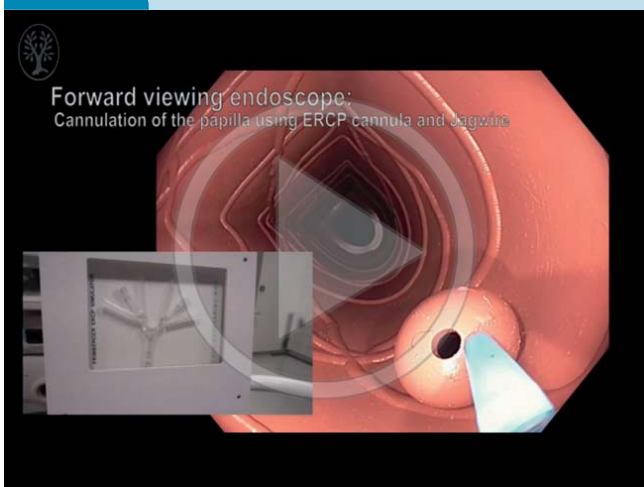
Primary outcomes were question 1 ("practicing with this simulator improved my specific skills") for the trainees' questionnaire and question 10 ("learning success of the trainees") for the experts' questionnaire. All other questions served as secondary outcomes.

Written responses were collected anonymously from both trainers and trainees following the simulator practice.

Results

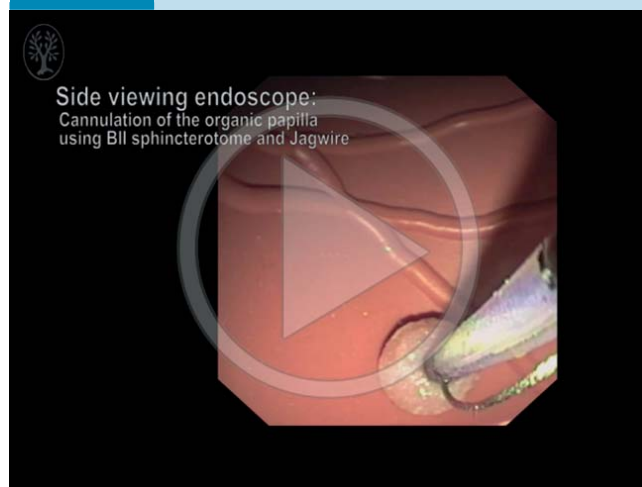
During the course, the B II/Roux-en-Y simulator was successfully used to perform the above mentioned procedures, without any technical problems. Successful cannulation of the papilla and insertion of instruments into the bile duct could be confirmed with direct visualization in the window of the simulator without the need for fluoroscopy. Each participant had the chance to achieve deep cannulation and to perform at least two Billroth II/Roux-en-Y sphincterotomies before filling out the questionnaire.

Video 1



Intubation of the afferent loop and reaching the papilla using both forward and side viewing endoscopes. Cannulation of the papilla is done using an ERCP cannula and a guidewire. Successful cannulation of the biliary system is confirmed through the transparent window of the simulator. Exchange of the papilla, as well as controlling its length, is easy and fast. Finally, a set of 66 organic papillae is shown suitable for high frequency sphincterotomy and prepared for a training course. Online content including video sequences viewable at: <http://dx.doi.org/10.1055/s-0042-111905>

Video 2



Cannulation of the organic papilla using a B II sphincterotome and a guidewire, followed by cutting the papilla in the 5 o'clock direction using high frequency current with the settings ENDO CUT I, effect 1, cutting duration 2, and cutting interval 3. Another sphincterotomy is performed after inserting a 5 Fr stent into the papilla, using a needle-knife also in the 5 o'clock direction with the above mentioned high frequency settings. Online content including video sequences viewable at: <http://dx.doi.org/10.1055/s-0042-111905>

Table 1 Trainees' evaluation (n = 10) of the B II simulator.

| Evaluation item | Score |
|-----------------------------|-------|
| Skills improvement | 5.8 |
| Continue to use in training | 5.7 |
| Risk reduction for patients | 6.2 |
| Recommendation | 6.4 |

Mean scores on a seven-point Likert scale (1, complete disagreement; 7 complete agreement).

Table 2 Experts' evaluation (n = 10) of the B II simulator.

| Item | Score |
|--------------------------------------|-------|
| Realism | |
| Tissue pliability | 4.9 |
| Anatomy | 5.0 |
| Visual realism | 5.3 |
| Cannulation realism | 4.8 |
| Overall realism | 5.6 |
| Advantages for training | |
| Usefulness in teaching advanced ERCP | 5.5 |
| Ease of use | 6.5 |
| Utility as a training modality | 6.8 |
| Ease of integration | 6.7 |
| Learning success of the trainee | 6.8 |

Mean scores on a seven-point Likert scale (1, complete disagreement; 7 complete agreement).

The trainees had a mean of 7 years of endoscopic experience (range 2–15 years). Seven trainees had the experience of less than 100 standard ERCPs, one had less than 200, one had less than 1000 and another one had more than 1000 standard ERCPs. The experts had a mean of 21 years of endoscopic experience (range 6–31 years) with a mean of 136 cases of ERCP in B II or Roux-en-Y reconstruction (range 30–800). The evaluation of the B II/Roux-en-Y simulator by both trainees and experts is summarized in **Table 1** and **Table 2**. In detail, primary outcomes reached mean scores of 5.8 (“skills improvement” as rated by the trainees) and 6.8 (“learning success of the trainee” as rated by the expert trainers) on a seven-point Likert scale. Overall, the B II/Roux-en-Y simulator gathered favorable evaluation with regard to all aspects of the questionnaire by both trainees and experts.

Discussion

ERCP after Billroth II or Roux-en-Y reconstruction is challenging [15]. Having reached the papillary region with the endoscope, one of the major difficulties is the ability to cannulate and cut the endoscopically inversely oriented papilla [4]. Herein, we present a novel ERCP mechanical simulator for cannulation and sphincterotomy after Billroth II or Roux-en-Y reconstruction. The simulator achieved favorable results in an initial evaluation by experts and trainees.

ERCP is a demanding and potentially dangerous procedure. Therefore, adequate training is mandatory before supervised procedures in patients. Regarding sphincterotomy, we were able to show that trainees particularly failed at atraumatic cannulation, which was in part related to poor alignment of the catheter with the axis of the bile duct for selective cannulation due to improper rotation of the endoscope shaft. Other common mistakes included scant use of lens flushing and insufficient view of the roof of the papilla. Furthermore, prolonged localized application of electrocautery without cutting, which can lead to thermally induced edema causing pancreatic outflow obstruction, or its opposite, an abrupt poorly controlled incision, were noted among novices [20]. The use of ERCP mechanical simulators has been shown to improve the skills of the trainees in the form of higher success rate and faster cannulation during the early training period as shown in a US multicenter randomized controlled trial [16]. Moreover, an improvement in the quality of sphincterotomy was observed with the use of training models [17]. Of importance, it is essential that practice at an EMS is supervised by an experienced endoscopist, since uncoached practices do not appear to provide further benefit [21]. Furthermore, EMS practice has been rated higher than practice with computer simulators in supplementing clinical ERCP training, since the former allows coordinated practice with real equipment and accessories [18]. Several ERCP mechanical simulators have been described. Nevertheless, most of them are limited to cannulation and sphincterotomy in the setting of normal anatomy. The capabilities of the specific simulators are described in **Table 3**.

Having reached the papilla with the endoscope, there are two main problems in the B II or Roux-en-Y situation. The first is cannulation of the papilla. In this simulator, this can be achieved with or without using a guidewire along with different accessories such as ERCP catheters or sphincterotomes. Both a side viewing duodenoscope or a forward viewing endoscope can be used. Thanks to the integrated window in the front of the simulator, correct deep cannulation can be verified by the appearance of

Table 3 Capabilities of different ERCP mechanical simulation models.

| Study first author, year, and reference | Visualization of accessories within the pancreatobiliary system by means of | Orientation of papillae | Sphincterotomy possible | Biliary system with side branches for selective cannulation | Stricture dilation possible | Stone extraction possible | Stent placement possible |
|---|---|-------------------------|-------------------------|---|-----------------------------|---------------------------|--------------------------|
| Leung 2007 [10] | Video camera | Regular | Yes | ND | Yes | ND | Yes |
| Frimberger 2008 [9] | Direct view of the ducts | Various | Yes | Yes | Yes | Yes | Yes |
| Grund 2012 [19] | Fluoroscopy and sensors within the ducts | Regular | Yes | Yes | Yes | Yes | Yes |
| Katanuma 2014 [7] | Direct view of the ducts | Regular | Yes | Yes | No | No | Yes |
| Schneider 2014 [6] | N/A, no pancreatobiliary system installed | Regular and inverse | No, metal papillae | N/A | N/A | N/A | N/A |
| Actual EMS | Direct view of the ducts | Inverse | Yes | Yes | Yes | Yes | Yes |

EMS, ERCP mechanical simulator. N/A, not applicable. ND, not described.

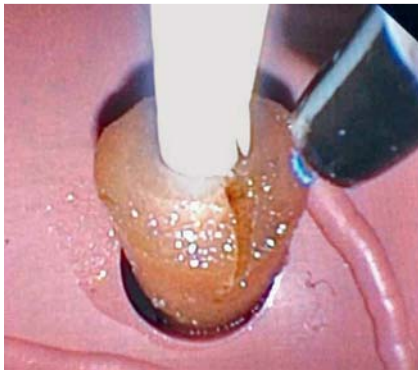


Fig. 7 Endoscopic appearance of a stented papilla inside the duodenum of the simulator. A needle-knife papillotomy was carried out along a stent.

the instruments in the bile duct without the need for fluoroscopy.

The second problem is sphincterotomy in the correct direction. Here, the trainee can practice various sphincterotomy techniques using all kinds of instruments such as standard sphincterotomes, B II sphincterotomes, S-shaped sphincterotomes or performing a needle-knife precut over an inserted stent. Cutting through the organic papilla simulates the feeling of cutting a natural papilla. In the initial evaluation, the Billroth II/Roux-en-Y simulator gathered favorable feedback from ERCP trainees and experts with regard to both the cannulation and sphincterotomy techniques. The new B II/Roux-en-Y simulator received favorable scores from the trainees in terms of risk reduction for patients and the majority judged it as recommendable. In this pilot study, the simulator received favorable scores from the experts for its ease of use, utility as a training modality, and for its successful learning results on the trainees justifying its further validation.

There are some limitations about the B II/Roux-en-Y model and its initial evaluation. First, this simulator does not recreate or provide training in negotiating the scope through the afferent limb to the papilla. As a consequence, endoscope control may also differ in the simulator in comparison to real life conditions. Further developments might contain variations of the afferent limb to simulate long passage through the afferent loop in Roux-en-Y reconstruction. On the other hand, all previously described EMS exhibit limitations with regard to simulation of the endoscope passage to the papilla to some extent. Second, the papillae exhibit only one orifice for cannulation of the artificial bile ducts. Papillae with two orifices for selective cannulation of the bile duct or pancreatic duct are currently under development. Third, trainee evaluation statements were worded in a positive fashion. This could have led to an acquiescence bias, particularly in a training environment. Moreover, the initial evaluation was done in a limited number of participants and construct validity still has to be shown by investigating whether the new training system could distinguish experienced endoscopists from beginners.

In conclusion, the new B II/Roux-en-Y mechanical simulator is simple and practicable. A pilot evaluation during an ERCP course showed promising results. Further studies are needed to show its construct validity as well as its utility during structured training programs.

Competing interests: E.F. is the inventor of the training model and has manufactured it. The previously used labeling for the new simulators, “X-Vision Training System or Model” has been replaced due to the abundant usage of the name “X-Vision.”

Now the simulators are called “Frimberger Simulator(s)”. The other authors have no further conflict of interest to declare.

Acknowledgments



The authors thank the organizers, tutors, and participants of GATE Munich for the opportunity to evaluate the training models during a course for ERCP training.

References

- 1 Moreels TG. ERCP in the patient with surgically altered anatomy. *Curr Gastroenterol Rep* 2013; 15: 343
- 2 Lee A, Shah JN. Endoscopic approach to the bile duct in the patient with surgically altered anatomy. *Gastrointest Endosc Clin N Am* 2013; 23: 483–504
- 3 Okabe Y, Ishida Y, Kuraoka K et al. Endoscopic bile duct and/or pancreatic duct cannulation technique for patients with surgically altered gastrointestinal anatomy. *Dig Endosc* 2014; 26: 122–126
- 4 Moreels TG. Endoscopic retrograde cholangiopancreatography in patients with altered anatomy: How to deal with the challenges? *World J Gastrointest Endosc* 2014; 6: 345–351
- 5 Maydeo A, Borkar D. Techniques of selective cannulation and sphincterotomy. *Endoscopy* 2003; 35: 19–23
- 6 Schneider AR, Schepp W. Do it yourself: building an ERCP training system within 30 minutes (with videos). *Gastrointest Endosc* 2014; 79: 828–832
- 7 Katanuma A, Itoi T, Umeda J et al. A novel dry model for practicable sphincterotomy and precut needle knife sphincterotomy. *Gastroenterol Res Pract* 2014; 2014: 908693
- 8 Bittner JG, Mellinger JD, Imam T et al. Face and construct validity of a computer-based virtual reality simulator for ERCP. *Gastrointest Endosc* 2010; 71: 357–364
- 9 Frimberger E, von Delius S, Rösch T et al. A novel and practicable ERCP training system with simulated fluoroscopy. *Endoscopy* 2008; 40: 517–520
- 10 Leung JW, Lee JG, Rojany M et al. Development of a novel ERCP mechanical simulator. *Gastrointest Endosc* 2007; 65: 1056–1062
- 11 Matthes K, Cohen J. The Neo-Papilla: a new modification of porcine ex vivo simulators for ERCP training (with videos). *Gastrointest Endosc* 2006; 64: 570–576
- 12 Neumann M, Mayer G, Ell C et al. The Erlangen Endo-Trainer: life-like simulation for diagnostic and interventional endoscopic retrograde cholangiography. *Endoscopy* 2000; 32: 906–910
- 13 Bar-Meir S. A new endoscopic simulator. *Endoscopy* 2000; 32: 898–900
- 14 Sedlack R, Petersen B, Binmoeller K et al. A direct comparison of ERCP teaching models. *Gastrointest Endosc* 2003; 57: 886–890
- 15 Adler DG, Lieb JG2nd, Cohen J et al. Quality indicators for ERCP. *Am J Gastroenterol* 2015; 110: 91–101
- 16 Lim BS, Leung JW, Lee J et al. Effect of ERCP mechanical simulator (EMS) practice on trainees' ERCP performance in the early learning period: US multicenter randomized controlled trial. *Am J Gastroenterol* 2011; 106: 300–306
- 17 Leung JW, Yen DC, Lim BS et al. Didactic teaching and simulator practice improve trainees' understanding and performance of biliary papillotomy. *J Interv Gastroenterol* 2013; 3: 64–68
- 18 Leung J, Lim B, Ngo C et al. Head-to-head comparison of practice with endoscopic retrograde cholangiopancreatography computer and mechanical simulators by experienced endoscopists and trainees. *Dig Endosc* 2012; 24: 175–181
- 19 Grund KE, Ingenpaß R, Durst F et al. [Neuartiges Hands-on-Phantom für das realistische Training der gesamten diagnostischen und therapeutischen ERCP]. *Endo heute* 2012; 25: 14–17
- 20 von Delius S, Thiess P, Meining A et al. Validation of the X-Vision ERCP Training System and technical challenges during early training of sphincterotomy. *Clin Gastroenterol Hepatol* 2009; 7: 389–396
- 21 Liao WC, Leung JW, Wang HP. Coached practice using ERCP mechanical simulator improves trainees' ERCP performance: a randomized controlled trial. *Endoscopy* 2013; 45: 799–805