

Laparoscopic Chromopertubation, Myomectomy with Opening of the Uterine Cavity and Hysteroscopy during the Early Implantation Phase of an Undetected Pregnancy: Delivery of a Child with a Complex Brain Malformation

Laparoskopische Chromopertubation, Myomenukleation mit Öffnung der Gebärmutterhöhle und Hysteroskopie im Frühstadium der Nidation bei einer unentdeckten Schwangerschaft: Geburt eines Kindes mit komplexer Hirnfehlbildung

Authors

C. Mann¹, K. Karl², B. Ertl-Wagner³, H. Weigand⁴, C. J. Thaler^{1,5}

Affiliations

The affiliations are listed at the end of the article.

Key words

- embryonic period
- malformation
- infertility
- pregnancy
- reproductive medicine
- sonography

Schlüsselwörter

- Embryonalstadium
- Fehlbildung
- Unfruchtbarkeit
- Schwangerschaft
- Reproduktionsmedizin
- Ultraschall

received 22.11.2015

revised 9.2.2016

accepted 5.4.2016

Bibliography

DOI <http://dx.doi.org/10.1055/s-0042-106086>
 Geburtsh Frauenheilk 2016; 76: 906–909 © Georg Thieme Verlag KG Stuttgart · New York · ISSN 0016-5751

Correspondence

Dr. Corinna Mann, MD
 Gynecological Endocrinology and Reproductive Medicine Department of Gynecology and Obstetrics
 Ludwig-Maximilians-University Hospital
 Maistraße 11
 80337 Munich
 Germany
corinna.mann@kinderwunschzentrum.at

Abstract

A previously infertile woman underwent laparoscopic myomectomy involving opening of the uterine cavity and chromopertubation that showed closed Fallopian tubes during the early implantation stage of an undetected pregnancy. The pregnancy was not terminated, and a child with a complex brain malformation was delivered at 37 weeks of gestation by Cesarean section.

Introduction

We report on a 38-year-old female with secondary infertility and multiple fibroids who underwent diagnostic hysteroscopy and laparoscopic myomectomy involving opening of the uterine cavity during the implantation stage of an undetected pregnancy. To our knowledge, only three other cases have been published on invasive procedures (hysteroscopy, laparoscopy and chromopertubation) involving the uterine cavity during the implantation stage. None of these other cases involved myomectomy or opening of the uterine cavity [1–3].

Our patient underwent a scheduled cesarean section in week 37 and delivered a child with congenital cerebellar vermis hypoplasia, a rare complex malformation of the brain with multiple causes, as described in the Discussion section below.

Case Presentation

A 38-year-old patient and her husband of African origin presented with secondary infertility. They had been trying to have children for six years. Three years ago, they achieved a spontaneous

Zusammenfassung

Bei einer Patientin mit sekundärer Infertilität wurde, im Frühstadium der Einnistungsphase einer unbekannt Schwangerschaft, eine laparoskopische Myomenukleation mit Eröffnung des Cavums und Chromopertubation durchgeführt. Die Untersuchung zeigte verschlossene Tuben beidseits. Die Schwangerschaft wurde nicht abgebrochen, in der 37. SSW wurde die Patientin per Sectio caesarea von einem Kind mit einer komplexen Hirnfehlbildung entbunden.

pregnancy, which ended at around 20 weeks of gestation at the couple's home in Africa. The patient could not provide any information or documentation that would have given a clue about the potential etiopathology of this miscarriage. The patient had multiple uterine fibroids. On presentation to our infertility clinic, she reported regular menstrual periods of 3–5 days every 27–28 days with severe dysmenorrhea. We found no indication of hyperandrogenism, and the patient did not report hypermenorrhea. In addition to her infertility, she complained of recurrent mild back pain and pelvic pain which did not require medication. She reported no significant diseases or prior operations and no use of drugs or medications. Endocrine work-up in the early follicular phase including androgens was not significant apart from an elevated FSH of 15.7 U/l and a low AMH of 0.3 ng/ml. Transvaginal and abdominal ultrasound showed four fibroids: the first was located intramurally at the fundus and measured 60 × 66 × 52 mm; the second was located close to the cervix subserosally and measured 47 × 47 × 45 mm; the third was located subserosally in the anterior wall and measured 47 × 38 × 40 mm; and the fourth was located intramurally in the anterior wall and measured 30 × 30 × 40 mm. The

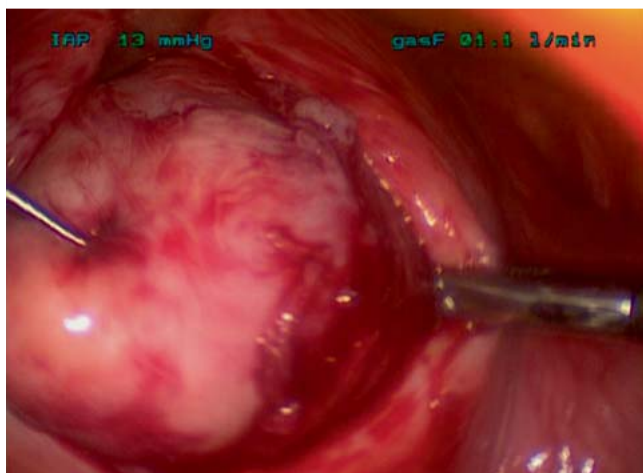


Fig. 1 Laparoscopic surgery: myomectomy of the large fibroid at the fundus.

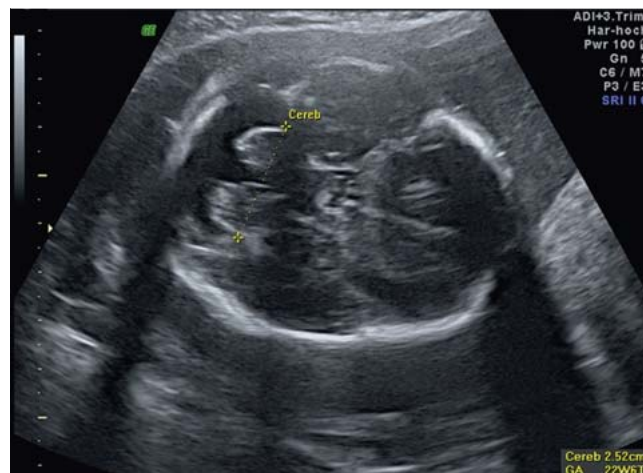

Fig. 2 Fetal ultrasound imaging at 25 weeks of gestation shows hypoplasia of the cerebellar vermis with an enlarged cisterna magna.

endometrial lining was irregular and intracavitary fibroids could not be excluded.

Semen analysis of the husband showed a volume of 0.9 ml and a total sperm count of 24 million. Sperm motility grade A and B was 35%, and normal sperm morphology was 20%. According to the WHO criteria (2010) this represents hypospermia. The 57-year-old male patient had fathered three children aged 31, 21 and 19 with a previous wife.

Because of her fibroids and her infertility combined with chronic back and pelvic pain, the patient was offered laparoscopic chromopertubation, hysteroscopy and myomectomy. Routine preoperative blood work-up carried out 5 days prior to surgery on cycle day 15 was normal, and serum hCG was undetectable (< 0.1 IU/l). Hysteroscopy showed an unremarkable cavity and no evidence of transmural or intracavitary fibroids. Both proximal tubal ostiums could be visualized and were unremarkable. Five fibroids were seen on laparoscopy (► **Fig. 1**): 1. intramural fibroid at the fundus (6 cm); 2. subserosal fibroid close to the entrance of the right fallopian tube (4 cm); 3. subserosal fibroid close to the cervix (4 cm); and two further small subserosal fibroids (each 2 cm). Both fallopian tubes and ovaries appeared normal. On chromopertubation, no dye could be passed through the tubes, even with increasing pressure. The large fibroid at the fundus and the fibroid close to the fallopian tube were removed. During myomectomy, the uterine cavity was opened with a transverse incision

measuring 3 cm and was subsequently closed with 4 deep simple interrupted stitches. The operation took a total of 120 minutes and there were no complications or significant blood loss. The patient recovered well and was discharged home on the third postoperative day. Because of the tubal findings, we recommended IVF at 6 months after the operation.

After 4 weeks the patient presented with nausea and pelvic pain. Ultrasound examination showed an intact intrauterine pregnancy with an embryonic heartbeat and a CRL of 18 mm, corresponding to the 8 + 1 week of gestation p.m. According to this biometry, the patient had conceived one day prior to her preoperative blood hCG test, and she was in the 2 + 6 week of gestation on the day of the operation. The couple was given detailed information about the situation and all potential maternal and fetal risks involved, including preterm labor, preterm delivery, uterine rupture and abnormal placental implantation. In addition, a thorough evaluation of the potentially teratogenic effects of the operation and related compounds was done (► **Table 1**). The Pharmacovigilance and Counseling Center for Embryonic Toxicology at the Charité in Berlin did not report any teratogenic or toxicological hazards. Findings at consecutive ultrasound examinations performed in weeks 10 and 13 were limited due to the remaining fibroids but showed normal biometry, fetal growth, and placental implantation. For religious reasons, the patient preferred not to undergo nuchal translucency screening. In week 18, sonography showed an enlarged cisterna magna and an echogenic intracardiac focus. At this point, amniocentesis and karyotyping of the fetus were recommended, but the couple decided against it, again for religious considerations. Ultrasound in week 20 confirmed the enlarged cisterna magna and mild ventriculomegaly as well as potential hypoplasia of the cerebellar vermis (► **Fig. 2**). An MRI, recommended for further evaluation, also confirmed these findings. The couple was informed in detail about this particular syndrome, its prognosis and the consequences for infant's later life and clearly stated their decision not to intervene with the pregnancy. Fetal growth and general development remained within normal limits, but in week 37 sonography indicated progressive thinning of the myomectomy scar. An elective cesarean section was scheduled to avoid the risk of uterine rupture. At 36 + 6 weeks of gestation, a female infant of normal weight and size (length 48 cm; 38th percentile), weighing 2810 g was deliv-

Table 1 Potential teratogenic effects of the operation and related compounds; Source: Pharmacovigilance and Counseling Center for Embryonic Toxicology at the Charité in Berlin, Germany.

Medication	Potential teratogenic effect
Midazolam	none
Sufentanil	none
Cefuroxime	none
Propofol	none
Mivacurium	none
Dexamethasone	none
Ranitidine	none
Dexketoprofen	none
Indigo carmine dye	none

ered with Apgar scores of 9/10/10. Her immediate postnatal adaptation was normal. Initially the little girl presented with hypoglycemia of 43 mg/dl and hyperbilirubinemia. From day 3, both values were normal. Findings of postnatal neurological examination and developmental neurological examinations were within normal ranges. The child drank normally and had a normal weight gain. An MRI on day 5 showed a complex brain malformation with congenital cerebellar vermis hypoplasia, moderate microcephaly, and multiple heterotopias (● Fig. 3). In addition, ultrasound examination showed left renal dysplasia. Both kidneys were small and the left kidney showed hyperechogenic parenchyma at the lower pole. Ophthalmologic examination was within normal ranges except for an abnormal configuration of the papillae. After 10 days the little girl was discharged with her mother with the recommendation that she should have an ultrasound examination of her kidney together with a check-up by the nephrology outpatient clinic after 3–4 months, she should be followed up by the department for developmental neurology and should receive regular physiotherapy.

Developmental neurological examination at three months showed normal somatic development, good communication behavior and eye contact. But the movement patterns of the girl were suspicious, with erratic, isolated movements of the arms and legs and a rigid posture of the left arm, as well as limited control of the head when lifting it up. In addition, the girl had a discrete intermittent nystagmus and propulsive movements of the tongue. This amounts to a central motor disorder which can be only classified further when the girl is older.

Discussion

We report on a case of a woman who had hysteroscopy, laparoscopy with myomectomy involving hysterotomy and chromoperturbation during the implantation stage of an unknown pregnancy. To the best of our knowledge this is the first case that describes a term pregnancy after myomectomy with opening of the uterine cavity during the early implantation stage.

Uterine fibroids are common in women of reproductive age and prevalence rates range from 20–50% [4]. Depending on their location fibroids are associated with impaired fertility, abnormal sites for placental implantation as well as an increased risk of spontaneous abortion or preterm labor and delivery [5]. Fertility outcomes are decreased in women with submucosal fibroids, and removal of such fibroids seems to confer benefit. The effect of intramural fibroids remains unclear. If they have an impact on fertility it appears to be small, depending on the size and if the endometrium is involved.

According to the patient's menstrual history and consecutive sonographies, the gestational age on the day of the operation was probably around 2 + 6 weeks of gestation p.m. This is consistent with a negative hCG serum concentration (< 2 IU/l) 5 days prior to this date. Neither the hysteroscopic examination, which used saline to distend the uterine cavity, nor the chromoperturbation or the myomectomy with opening of the uterine cavity disrupted the pregnancy. This could be explained by the stable adhesion between blastocyst and early decidua that has been reported for the adhesion phase, even prior to invasion phase of the implantation process. The implantation process involves three key phases: apposition, stable adhesion, and invasion of the blastocyst. The apposition phase is characterized by the start of interaction and attachment between the blastocyst and the apical surfaces of the

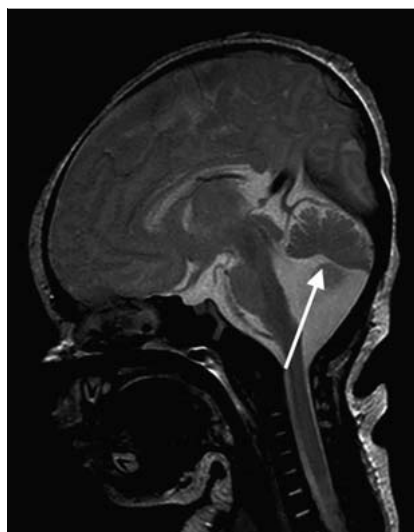

Fig. 3 Neonatal MRI: sagittal T2-weighted image shows hypoplasia of the vermis with malrotation.

endometrium. This process is strongly influenced by the adhesion molecule L-selectin [6,7]. More stable attachments are formed during the adhesion phase involving interaction of integrins. Finally, the blastocyst invades between luminal epithelial cells and embeds itself between the stromal cells of the endometrium on the 6th – 7th day after fertilization [8]. It is only at this stage when the embryo connects to the maternal circulation that hCG can be detected in maternal blood.

This timing of the gestation is consistent with the fact that no signs of an early pregnancy were detected on hysteroscopy. The early implantation site is thought to be significantly smaller than 1 mm² [9], and a site of this size could not be identified hysteroscopically. During the further course of this pregnancy, the placental implantation site was monitored closely by high resolution sonography but did not show any pathologies. All medications, anesthetics and dyes which were used were evaluated in cooperation with the Pharmacovigilance and Counseling Center for Embryonic Toxicology at the Charité in Berlin, which did not find any hint of toxic or teratogenic effects.

Fetal biometry and growth remained within normal limits during the entire course of the pregnancy. However, the uterine wall at the site of the myomectomy showed progressive thinning so that an elective cesarean section was performed at 36 + 6 weeks of gestation.

To date, only a few successful pregnancy outcomes have been reported after an inadvertent invasive procedure such as hysterosalpingography, laparoscopy, or chromoperturbation during early pregnancy [1–3]. It should be noted that none of the previously described cases reported a myomectomy with opening of the uterine cavity.

The female newborn was of normal size and weight and had a complex brain malformation with congenital cerebellar vermis hypoplasia, moderate microcephaly, and multiple heterotopias. In addition, ultrasound revealed dysplasia of the left kidney. The right kidney was normal and BUN (blood urea nitrogen) was within normal ranges. These anomalies may be due to a wide range of causes, such as ionizing radiation in the second half of the pregnancy [10], drugs such as phenytoin [11], viral causes such as cytomegalovirus infection during pregnancy [12,13], and chromosomal syndromes such as trisomy 18 [14] and trisomy 21 [15], all of which have been associated with congenital cerebellar vermis hypoplasia. These anomalies can also be part of

complex malformations such as Marsden-Walker syndrome [16]. It should be noted that neural development starts at week 5, which was more than 2 weeks after surgery was performed in our case. It is difficult to estimate the influence that the invasive surgical procedure performed during very early pregnancy may have had on the complex disorder documented in the female neonate born to our patient, as no other cases of comparable operations have been reported to date.

A large Swedish study covering 2 million deliveries in Sweden examined fetal outcomes after laparoscopy and laparotomy performed between the fourth and the twentieth week of gestation. A total of 2181 patients with laparoscopy and 1522 with laparotomy were evaluated but none of the cases involved opening of the uterine cavity. Pregnancies where the mother underwent surgery were compared with the total population for birth weight, duration of gestation, growth restriction, infant survival, and fetal malformations. The study revealed a significantly increased risk for infants in both the laparoscopy and the laparotomy groups of weighing <2500 gm and being delivered before 37 weeks of gestation, as well as a higher incidence of infants with growth restriction compared to the total population. There were no differences in the rate of fetal malformations or the cumulative infant survival rates up to 1 year compared to the total population [17].

Conclusion

Laparoscopies and hysteroscopies are usually scheduled in the follicular phase of the cycle. However, patients with an oligomenorrhea/amenorrhea or irregular cycles may be difficult to schedule. In addition, patients may alter the timing of the procedure for personal reasons. We always perform hCG tests prior to any surgery. However, this case documents the limitations of our approach in excluding very early pregnancy. A hysteroscopy or laparoscopy should preferably always be done in the follicular phase, but the risks of luteal phase surgery for an unrecognized pregnancy may be lower than expected.

Conflict of Interest

None.

Affiliations

- ¹ Gynecological Endocrinology and Reproductive Medicine, Department of Gynecology and Obstetrics, Ludwig-Maximilians-University Hospital, Maistr. 11, 80337 Munich, Germany
- ² Prenatal Diagnosis, Department of Obstetrics and Gynecology, Ludwig-Maximilians-University Hospital, Maistr. 11, 80337 Munich, Germany; now: Prenatal Diagnosis Munich, Tegernseer Landstr. 64, 81541 Munich, Germany
- ³ Institute for Clinical Radiology, Ludwig-Maximilians-University Hospital, Munich, Germany
- ⁴ Department of Pediatric Neurology Ludwig-Maximilians-University Hospital, Munich, Germany
- ⁵ Gynecological Endocrinology and Reproductive Medicine, Department of Gynecology and Obstetrics, Ludwig-Maximilians-University Hospital, Marchioninstr. 15, 81377 Munich, Germany

References

- 1 *AL-Mizzen E, Barnick CG, Grudzinskas JG.* Early pregnancy is elusive and robust. *Early Pregnancy* 2001; 5: 144–148
- 2 *Dwivedee K, Banfield PJ.* A case report of inadvertent hysteroscopy and laparoscopy in a patient of uterus didelphys with early pregnancy. *J Obstet Gynaecol* 2007; 27: 638–639
- 3 *Erenus M, Sezen D.* Ongoing pregnancy in a woman who inadvertently underwent office hysteroscopy during early pregnancy. *Fertil Steril* 2005; 83: 211–212
- 4 *Novak ER, Woodruff JD.* Myoma and other benign Tumors of the Uterus. *Gynecologic and Obstetrics Pathology*. 8th ed. Philadelphia, USA: Saunders; 1979: 260–278
- 5 *Hurst BS, Matthews ML, Marshburn PB.* Laparoscopic myomectomy for symptomatic uterine myomas. *Fertil Steril* 2005; 83: 1–23
- 6 *Genbacev OD, Prakobphol A, Foulk RA et al.* Trophoblast L-selectin-mediated adhesion at the maternal-fetal interface. *Science* 2003; 299: 405
- 7 *Steeber DA, Engel P, Miller AS et al.* Ligation of L-selectin through conserved regions within the lectin domain activates signal transduction pathways and integrin function in human, mouse, and rat leukocytes. *J Immunol* 1997; 159: 952–963
- 8 *James JL, Carter AM, Chamley LW.* Human placentation from nidation to 5 weeks of gestation. Part I: What do we know about formative placental development following implantation? *Placenta* 2012; 33: 327–334
- 9 *Knoth M, Larsen J.* Ultrastructure of a human implantation site. *Acta Obstet Gynecol Scand* 1972; 51: 385–393
- 10 *Johnston MV, Barks J, Greenamyre T et al.* Use of Toxins to disrupt Neurotransmitter Circuitry in the developing Brain. In: Boer GJ, Feenstra MGP, Mirmiran M, Swaab DF, van Haaren F, eds. *Biochemical Basis of functional Neuroteratology*. Amsterdam: Elsevier; 1988: 425–446
- 11 *Lindvall O, Nilsson B.* Cerebellar atrophy following phenytoin intoxication. *Ann Neurol* 1984; 16: 258–260
- 12 *Sugita K, Ando M, Makino M et al.* Magnetic resonance imaging of the brain in congenital rubella virus and cytomegalovirus infections. *Neuroradiology* 1991; 33: 239–242
- 13 *Perlman JM, Argyle C.* Lethal cytomegalovirus infection in preterm infants: clinical, radiological, and neuropathological findings. *Ann Neurol* 1992; 31: 64–68
- 14 *Nakamura Y, Hashimoto T, Sasaguri Y et al.* Brain anomalies found in 18 trisomy: CT scanning, morphologic and morphometric study. *Clin Neuropathol* 1986; 5: 47–52
- 15 *Crome L, Cowie V, Slater E.* A statistical note on cerebellar and brainstem weight in mongolism. *J Ment Defic Res* 1966; 10: 69–72
- 16 *Garcia-Alix A, Blanco D, Cabanas F et al.* Early neurological manifestations and brain anomalies in Marsden-Walker syndrome. *Am J Med Genet* 1992; 44: 41–45
- 17 *Reedy MB, Källén B, Kuehl TJ.* Laparoscopy during pregnancy: a study of five fetal outcome parameters with use of the Swedish Health Registry. *Am J Obstet Gynecol* 1997; 177: 673–679