Modern Radiological Imaging of Osteoarthritis of The Hip Joint With Consideration of Predisposing Conditions

Moderne radiologische Bildgebung der Arthrose des Hüftgelenks unter Berücksichtigung der Präarthrosen

Authors M.-A. Weber[1], C. Merle[2], C. Rehnitz[1], T. Gotterbarm[2]

Affiliations
[1] Diagnostic and Interventional Radiology, University Hospital Heidelberg, Germany
[2] Orthopedics and Trauma Surgery, University Hospital Heidelberg, Germany

Key words
- hip joint
- osteoarthritis
- magnetic resonance imaging
- projection radiography
- computed tomography
- femoroacetabular impingement

received 27.11.2015
accepted 11.2.2016

Bibliography
DOI http://dx.doi.org/10.1055/s-0042-104511
Published online: 18.5.2016
Fortschr Röntgenstr 2016; 188: 635–651 © Georg Thieme Verlag KG Stuttgart · New York · ISSN 1438-9029

Correspondence
Prof. Marc-André Weber
Universitätsklinik Heidelberg, Diagnostische und Interventionelle Radiologie
Im Neuenheimer Feld 110
D-69120 Heidelberg
Germany
Tel.: ++49/62 21/5 63 74 34
Fax: ++49/62 21/56 54 20
MarcAndre.Weber@med.uni-heidelberg.de

Abstract

Osteoarthritis is the most common disease of the hip joint in adults and has a high socioeconomic impact. This review article discusses the value of three imaging modalities in the diagnosis of osteoarthritis of the hip joint: projection radiography, computed tomography, and magnetic resonance imaging (MRI). Besides established imaging diagnostics of osteoarthritis, this review also outlines new MRI techniques that enable the biochemical analysis of hip joint cartilage and discusses predisposing deformities of the hip joint including femoroacetabular impingement (FAI) with labral pathologies, hip joint dysplasia, malrotation, and, finally, femoral head necrosis, for which early detection and an exact description of the extent and localization of the necrotic area are extremely important. Conventional X-rays remain indispensable for the diagnosis of osteoarthritis, while MRI is able to depict additional early symptoms and signs of activity of the disease. With the increasing number of joint-preserving interventions such as surgical hip luxation and hip joint arthroscopy for treating FAI, high-resolution imaging is gaining further importance for both pre- and postoperative diagnostics because it can accurately recognize early stages of joint damage. With high-resolution MR sequences and MR arthrography, the detailed depiction of the thin cartilaginous coating of the hip joint has become quite possible.

Key points:
- Projection radiography is the method of choice for the diagnostic work-up of osteoarthritis of the hip joint.
- Using computed tomography, the amount of acetabular bone stock prior to total hip arthroplasty is assessed in selected patients.
- Magnetic resonance imaging can substantiate the indication of surgery in case of discrepancy between clinical symptoms and radiological findings of the hip joint.
- If distinct and left untreated, predisposing conditions (such as femoroacetabular impingement) may lead to early development of osteoarthritis of the hip joint.
- Functional cartilage imaging can verify changes in the biochemical composition of the cartilage before they become morphologically evident.

Citation Format:
- Weber MA, Merle C, Rehnitz C et al. Modern Radiological Imaging of Osteoarthritis of The Hip Joint With Consideration of Predisposing Conditions. Fortschr Röntgenstr 2016; 188: 635–651

Zusammenfassung

Die Hüftgelenkarthrose ist bei Erwachsenen die häufigste Erkrankung des Hüftgelenks mit hohen sozioökonomischen Auswirkungen. In dieser Übersicht werden die Wertigkeiten der Modalitäten Projektionsradiografie, Computertomografie und Magnetresonanztomografie (MRT) in der Diagnostik der Hüftgelenkarthrose diskutiert. Dieser Übersichtsbeitrag stellt neben der etablierten bildgebenden Diagnostik der Coxarthrose neue MRT-Techniken zur biochemischen Analyse des Hüftgelenkknorpels vor und diskutiert Präarthrosen und präarthrotische Deformitäten am Hüftgelenk inklusive des femoroacetabulären Impingementsyndroms (FAI) mit Labrumpathologien, der Hüftgelenkdysplasie, Fehlrotationen sowie der Hüftkopfnekrose. Für letztgenannte Entität sind die Früherkennung und die genaue Beschrei-

bung von Ausmaß und Lokalisation der Nekrosezone von außerordentlicher Bedeutung. Die konventionelle Röntgendiagnostik ist für die Diagnostik der Coxarthrose unverändert unverzichtbar, während die MRT weitere Frühsymptome und Aktivitätszeichen der Hüftgelenkarthrose darzustellen vermag. Mit zunehmender Zahl gelenkerhaltender Eingriffe, z. B. der chirurgischen Hüftluxation und der Hüftgelenksarthroskopie in der Therapie des FAI, gewinnt die hochauflösende Diagnostik in der prä- und postoperativen Bildgebung an Bedeutung, um akkurat Frühstadien der Gelenkschädigung erkennen zu können. Mit hochauflösenden MR-Sequenzen und der MR-Arthrografie ist die detaillierte Darstellung des dünnen Knorpelüberzugs am Hüftgelenk gut möglich.

Introduction

There are two types of osteoarthritis of the hip joint: primary and secondary. Primary osteoarthritis, also known as idiopathic osteoarthritis, is a diagnosis of exclusion, meaning its cause is unknown. Primary osteoarthritis is therefore a very heterogenous group of diseases, the diagnosis of which are not based on individual radiological or clinical findings but rather on a combination of typical clinical symptoms and imaging. The cause of secondary osteoarthritis is known, however. Common causes are trauma after fractures, osteonecrosis, dysplasia, bone misalignment, joint infection, and femoroacetabular impingement (FAI). Besides being classified as either primary or secondary, osteoarthritis can also generally be categorized as localized, which usually indicates an acute occurrence such as stress or trauma, or symmetrical (or multifocal), whereby the latter usually indicates a genetic, systemic metabolic, or environmental cause. For example, the considerably reduced incidence of osteoarthritis among Asians and Black Africans also indicates a contributory cause that is either genetic or environmental [1]. Clinically, osteoarthritis is characterized by the following leading symptoms: pain, limping, limited walking ability, joint effusion, limited range of motion, startup stiffness, shortening of the legs, progressive deformity, and bone misalignment, as well as progressive muscle weakness or atrophy. Occasionally, a striking discrepancy between radiologic findings and clinical symptoms is observed, so that patients with pronounced radiologic changes only have mild symptoms whereas patients with minor X-ray findings complain about sharp pain. Therefore, a diagnosis of osteoarthritis and, above all, the therapy indication, should only be made after reviewing both radiologic and clinical findings.

Imaging Modalities

Conventional X-Rays

Conventional X-rays are the workhorse when it comes to osteoarthritis. As the imaging standard, projection radiography has the following tasks: 1. Confirmation of the diagnosis; 2. Analysis of the individual anatomy in order to design the endoprosthesis (calibration); 3. Depiction of the situation under stress (in other words, X-ray examination while patient is standing); 4. Basis for assigning a Kellgren-Lawrence grade (osteophytes, joint space width, sclerosis, deformity) [1, 2]. Reliable radiological indicators of osteoarthritis are joint space narrowing, subchondral sclerosis, subchondral cysts, and osteophyte formation [3]. Furthermore, loose bodies (< 10), joint deformities, subluxations, and joint effusion can be observed [1] (**Fig. 1**). In the advanced stages of osteoarthritis, the femoral head is deformed such that it is either cylindrical or mushroom-shaped. The classic radiologic sign of osteoarthritis is joint space narrowing, in particular on anteroposterior X-rays taken while the patient is standing. When joint space and cartilage narrowing occurs, the femoral head changes its position relative to the socket. The migration of the femoral head is primarily cranial (combined with anterolateral or anteromedial movement) but occasionally axial or medial (**Fig. 2**). This description of the migration is based on what can be seen in the anteroposterior X-ray image [4]. Cartilage damage that can be detected using MRI is also to be expected in these directions. Signs of medial-caudal migration on X-rays are joint space narrowing in the medial joint part with subchondral sclerosis and osteophyte formation in cases of enlarged laterocranial joint space. The orthopedic surgeon makes the indication for joint replacement independent of the direction of migration. However, because the various types of migration lead to a change in leverage ratios, the goals of geometric reconstruction of the hip joint using endoprosthetics include the normalization of the center of rotation (COR) (**Fig. 2**), anatomical offset reconstruction, and equalization of leg length. The goal of achieving a long service life for the implant components and maximum security against luxation is greatly influenced by the position and orientation of the implant components with consideration of the individual anatomy of each patient.

Computed Tomography

In-house, CT examinations with multi-planar and three-dimensional reconstructions have replaced most special X-ray projections and also work very well in patients with limited range of motion (**Fig. 3**). The depiction of subtle subchondral sclerosis, cyst formation, and proof of small osteophytes or loose bodies is also more sensitive than with projection radiography. Another common in-house indication is the preoperative diagnosis of anomalies in the hip socket or in the post-traumatic condition with metal present which is performed by assessing the amount of acetabular bone stock and checking for misalignment/deformity of the proximal femur. The orthopedic surgeon would like to know whether and in which localization the available bone stock allows for safe endoprosthetic anchoring of the implant components. For example, for dysplastic osteoarthritis with high luxation of the femoral head and neoarticulation, the question is how big the original acetabulum is and whether enough dimensioned bone stock is available to securely anchor the planned socket (**Fig. 4**). Furthermore, for these patients the evaluation of the mostly pathologically increased femoral anteversion is significant, because an implant with diaphyseric anchorage and free rotational adjustment must be chosen in order to correct it. Where there is axial misalignment and deformity of the proximal femur (such as after correctional osteotomy on the proximal femur), three-dimensional CT imaging is helpful in the planning of multiplanar corrective osteotomy, if necessary. The goal of this procedure is to anchor the shaft components in the femur in proper alignment and with sufficient anchoring surface area.

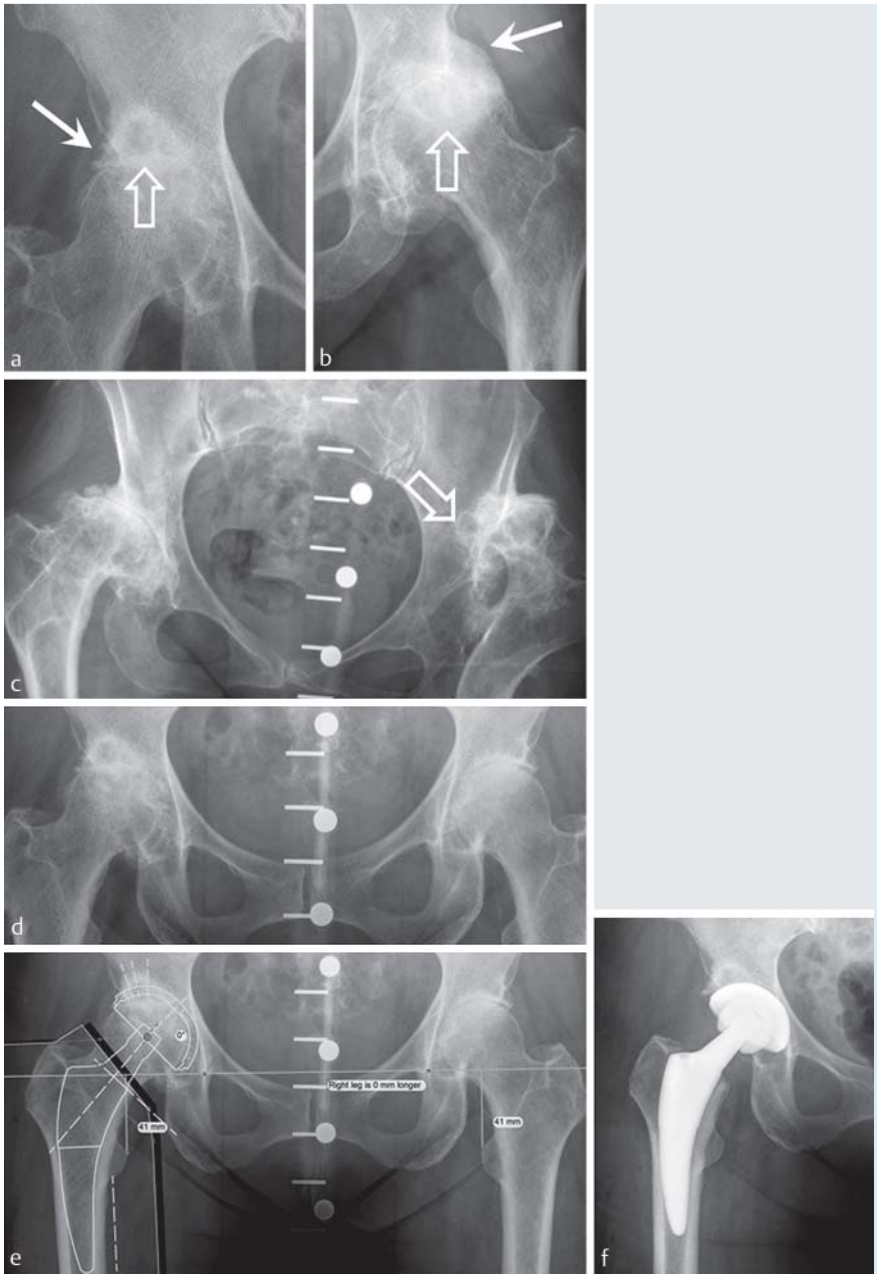

Fig. 1 **a – c** Illustration of radiological signs of osteoarthritis of the hip joint with latero-cranial joint space narrowing, extensive subchondral sclerosis, and subchondral cyst formation with sclerotic border in the acetabulum (open arrows). Acetabular rim osteophytes (arrows). **c** Dysplastic osteoarthritis. **d – f** Preoperative planning template and X-ray following cementless hip arthroplasty of the right hip.

Magnetic Resonance Imaging

For hip joint diagnosis focusing on osteoarthritis and predisposing conditions, whenever there is a big discrepancy between clinical symptoms and degree of severity of the osteoarthritis in the X-ray image (**Fig. 5**), unclear joint pain, and no improvement of clinical symptoms when using conservative therapy, MRI can be used to verify possible evidence of early-stage osteoarthritis. Further indications are evidence of active osteoarthritis (bone marrow edema, synovitis, effusion), as well as, especially in young patients with clinical suspicion, the evaluation of cartilage and labrum before hip arthroscopy (or the use of endoprosthetics). In-house, MRI is also used in selected patients for preoperative evaluation of actual cartilage damage before joint-preserving periacetabular osteotomy in young adults (e.g, triple osteotomy). The results after joint-preserving operations depend on the degree of preoperative cartilage damage [1, 2, 4]. In-house, the most common indication for an MRI is the substantiation of the indication for a surgical intervention where there is a big discrepancy between clinical symptoms and degree of severity of the osteoarthritis in the X-ray image. The orthopedic surgeon looks at the MRI for the existence of labrum damage, cartilage damage, effusion/synovitis, and subchondral and paralabral cysts. The following examples illustrate the condition of cartilage before a planned corrective procedure (**Fig. 6**), the condition of cartilage that substantiates the TEP (total endoprosthesis) indiction (**Fig. 7**), and the exclusion of other causes for hip joint pain (**Fig. 8**). In short, where there is hip joint osteoarthritis, the primary significance of MRI is to provide evidence of early signs of arthritis (joint cartilage, labrum) as well as active signs of osteoarthritis (**Fig. 9**). Moreover, MRI is also able to show any associated muscle atrophy. Osteoarthritis does not only affect joint cartilage and the neighboring subchondral bone, but also, especially through inflammatory processes, intra-articular structures (such as synovial membranes) and peri-

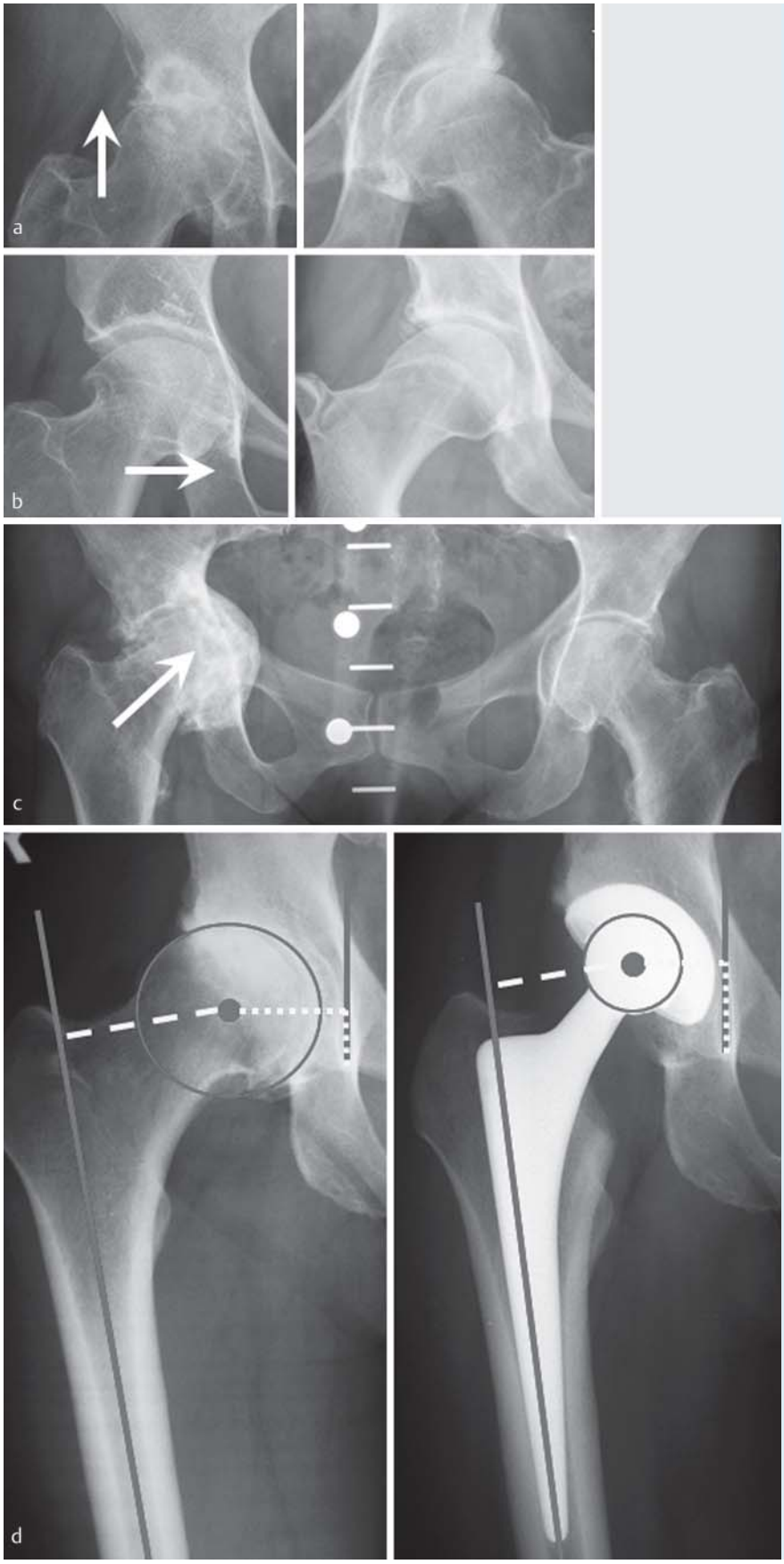

Fig. 2 Illustration of common migration patterns of the femoral head (arrows) in osteoarthritis of the hip joint **a – c**. The most common forms are cranial **a** combined with anterolateral or anteromedial movement and medial-caudal **b** with joint space narrowing in the medial joint, rather than latero-cranial migration and the seldom seen axial form in protrusio acetabuli **c**. **d** The goals of hip arthroplasty are normalization of the center of rotation (COR), offset reconstruction, and equalization of leg length. In the given example, the femoral and acetabular offset was decreased by the implantation and the center of rotation was cranialized.

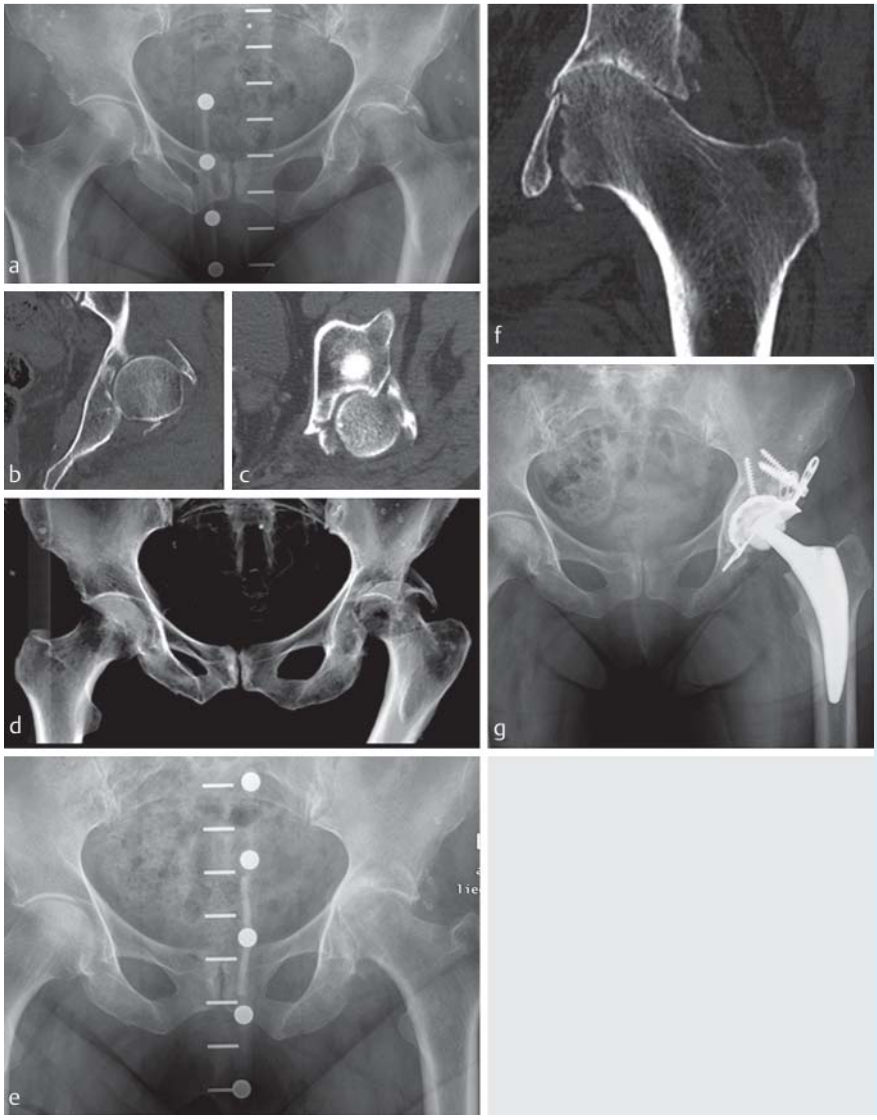

Fig. 3 Illustration of post-traumatic (secondary) osteoarthritis. 80-year-old female with left acetabular fracture and left hip dislocation after a fall at home **a**. Closed repositioning and conservative therapy with mobilization and planed X-ray follow-up after 6 weeks. Coronal **b** and axial **c** layers of the CT scans as well as 3 D reconstruction **d** clearly show dorsal subluxation of the femoral head and acetabular rim avulsion. **e** After six weeks of immobilizing left hip pain (severely limited joint mobility), evidence of progressive elevation of the femoral head, collapsed femoral head, and partial loss of joint space, as well as subchondral sclerosis; hence complete view of post-traumatic femoral head necrosis and secondary osteoarthritis. **f** Coronal layer of CT scan. This was followed by implantation of an acetabular reconstruction ring implant and a cementless metaphyseally anchored shaft, with good clinical results **g**.

articular structures (such as capsules, ligaments, tendons, and musculature). Thus, whenever there is marked osteoarthritis, damage to muscles, tendons, and ligaments is often observed due to chronic stress. Free bodies in the form of cartilage and bone desquamation are also a typical sign of osteoarthritis and are easier to detect with MRI than with X-rays. With osteoarthritis, even the smallest desquamation can show up on MRI as reactive synovitis (detritic synovitis) with effusion formation and synovial thickening, which can be considered a sign of activation. (In Anglo-American literature, the typical development of active arthritis, which, clinically, often comes in batches, has led to the term "osteoarthritis" [1, 4].) Acute pain and limited range of motion are most commonly found whenever the presence of subchondral bone marrow edema, synovitis, or effusion is seen on MRI (▶ **Fig. 9**).

The anatomy of cartilage and cartilage damage in the hip joint

When interpreting MRI results, it is important to be familiar with normal anatomy of cartilage in the hip joint, because that makes it clear that only thin-layered high-resolution sequences (magnetic resonance arthrography, in some cases with the traction technique) make possible the visualization of the thin cartilaginous coating and a reliable representation of its pathology, since cartilage thickness is a maximum of 2 mm in the acetabulum and 2.5 – 3 mm on the femoral head [5]. The hyaline cartilage is shaped like a crescent-moon at the acetabulum whereas the acetabular fossa, located at the center of the acetabulum, is free of cartilage. The caudal, open part of the crescent-moon- or horseshoe-shaped cartilage is spanned by the transverse ligament. The cartilage on the femur head is also not shaped like a semicircle but rather like a horse shoe. The fovea capitis lacks cartilage. The capitis femoris ligament (present in 90 % of all humans) comes out here, moves caudally, and joins the acetabular fossa above the transverse ligament at the caudal acetabular edge. The thickest part of the acetabular cartilage is the main load-carrying area in the middle of the acetabular roof and the thickest cartilage of the femoral head is just lateral of the fovea capitis [4]. The pictures (▶ **Fig. 10**) illustrate the thin cartilaginous coating by means of three-dimensional sequencing with an isotropic edge length of the voxel of less than 1 mm or by using magnetic resonance arthrography. Cartilage damage can come in the form of edematous cartilage, smaller defective cartilage for-

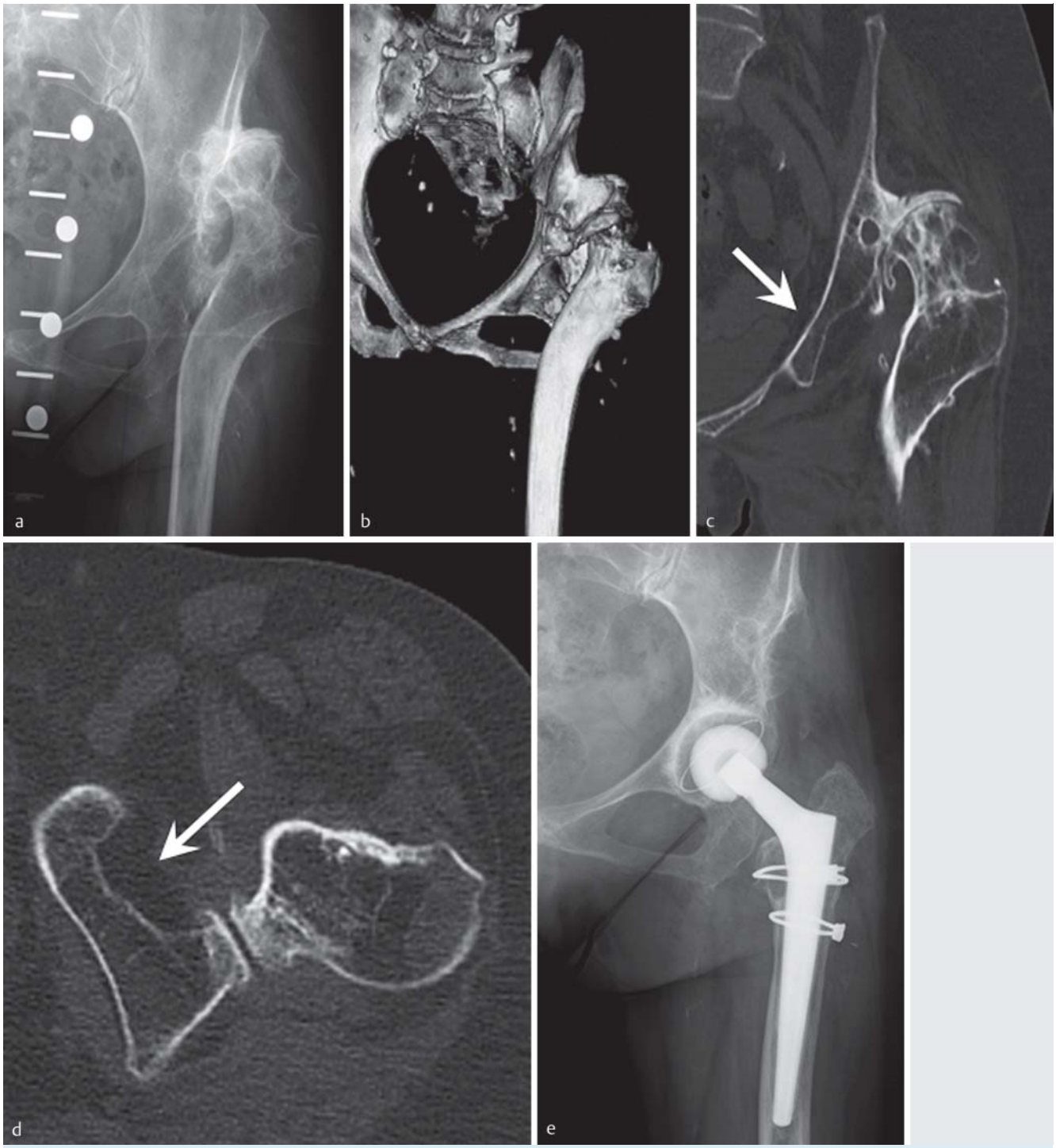

Fig. 4 With dysplastic osteoarthritis, it is important to have sufficient bone stock to anchor the total endoprosthesis. In this 68-year-old female with dysplastic osteoarthritis and high hip dislocation on both sides **a**, a CT scan **b – d** was performed to evaluate misalignment of the femur, bone stock, and the original size of the acetabulum (arrows). In this case, the bone stock and the size of the acetabulum were sufficient for endoprosthesis anchoring (cemented cup, cementless conical shaft) with restoration of the original center of rotation **e**.

Fig. 5 Illustration of the value of additional MRI to confirm the indication for a surgical intervention in selected cases. **a-d** 38-year-old female with clear constraints on her quality of life due to pain at night and stress-related pain (walking for more than 15 minutes was no longer possible). X-ray **a** shows cranial view of coxa profunda with remaining cartilage in the main load-bearing area and moderate acetabular and femoral osteophytes. The MRI (**b**: coronal fat-suppressed proton-density sequence) was performed to support the indication of TEP **c** and depicts, as did the operative findings **d** of the resected femoral head, the circular cartilage damage (arrows). **e – h** 56-year-old female with only mild changes to the hip on X-rays **e, f**. To substantiate the TEP indication, the MRI followed (**g** sagittal and **h**: coronal fat-suppressed proton-density sequence) and revealed labrum damage (open arrow), cartilage damage (arrow), joint effusion, and subchondral cysts.

mation, fibrillation, delamination, and even extensive loss of cartilage (▶ **Fig. 10**). The bone below becomes stronger due to the resulting local, mechanical, and unphysiological stress. It scleroses or increases its surface area due to bony outgrowth (osteophytes). Particles formed by abrasion and wear of the cartilage lead to cellular inflammation and then to an inflammatory reaction in the synovia. This results in synovitis with accompanying joint effusion. With the release of inflammation mediators, the synovitis also increases the speed of cartilage breakdown [4, 6, 7].

Functional cartilage imaging

In the meantime, there are also MRI techniques that make it possible to illustrate cartilage vitality or quality. In other words, you can see changes to the microarchitecture and the biochemical composition of the cartilaginous coating (proteoglycans, collagen fibers, water content) before morphologically visible defects actually occur. This means that you are able to see pre-osteoarthritis (very early forms of osteoarthritis). In this way, cartilage quality before surgery, cartilage regeneration after microfracture cartilage repair techniques, and the vitality and integrity of cartilage trans-

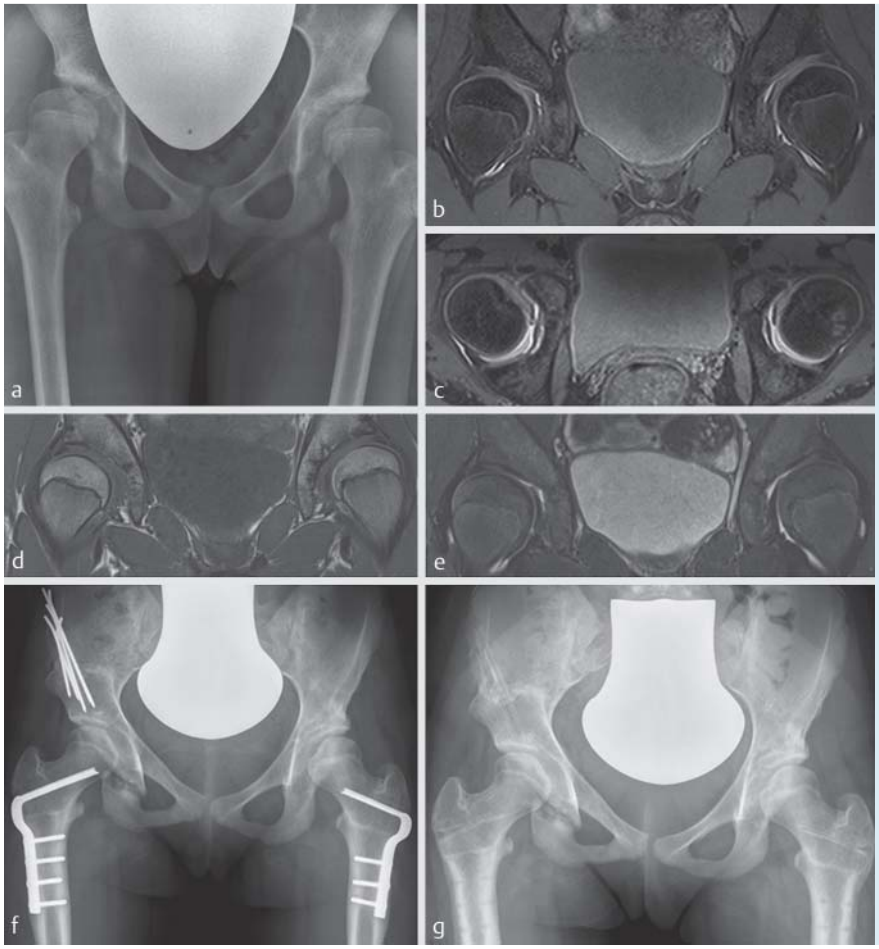

Fig. 6 Illustration of the indication for an MRI to assess the condition of the cartilage before planned realignment osteotomy: 13-year-old female with symptomatic hip dysplasia on both sides (center-edge angle of 14° on both sides; normal center-edge angle is 20 – 40°). The X-ray **a** shows bilateral signs of overload (subchondral sclerosis) at the acetabular rim. Insufficient cover of the femoral head in coxa valga causes increased lateral load and, over time, arthritic destruction of the joint. The MRI (**b**: coronal; and **c**: axial fat-suppressed proton-density sequence with 1 mm^3 voxel size; **d**: coronal T1-weighting; **e**: coronal STIR) was performed to assess the condition of the cartilage and the morphology of the hip joint. No chondral lesions or labrum degeneration appear. To improve hip joint coverage, the MRI was followed by varus derotation osteotomy (VDRO) with Dega acetabuloplasty (left) and VDRO and Tönnis triple pelvic osteotomy (right) **f, g** Situation after removal of metal.

plants can be evaluated [8]. However, these techniques are not in routine use at the moment and are mostly the subject of scientific studies. At the hip joint, the best evaluated technique is the so-called dGEMRIC (delayed gadolinium-enhanced MRI of cartilage) technique [9]. In principle, the fact that proteoglycans in cartilage have negatively charged side chains has to do with the glycosaminoglycans (GAGs) [10]. These negatively charged GAG molecules repel the contrast agent molecules (the negatively charged gadolinium (Gd^{2-})), which are also negatively charged, so that there is a negative correlation between the levels of the proteoglycans and the contrast enhancement in the cartilage. The practical procedure for conducting a dGEMRIC examination of the hip joint has several steps. First, unenhanced sequences are obtained. After that, the patient is given the Gd^2 MRI contrast agent intravenously (for example, a double dose of gadopentetate dimeglumine). Next, the patient needs to move his hip joint for 15 minutes, by going up and down stairs, for example. That is followed by a waiting time of 60 – 90 minutes before the next MRI examination so that the contrast agent has time to diffuse into the cartilage, whereby the rate of diffusion into the cartilage is negatively correlated to the concentration of proteoglycans in the cartilage. In the following MRI examination, the T1 times in the cartilage are measured, with three-dimensional T1-weighted sequences, for example. The ROI analysis of the T1 times in the acetabular and femoral cartilaginous coating shows an indirect but specific measurement for the concentration of proteoglycans in the cartilage. The T1 times are color coded and overlaid with an anatomic sequence such as a proton density weighted sequence (**Fig. 11**). Since the anionic MRI contrast agent (such as gadopentetate^{2-}) spreads itself around in the cartilage reciprocally proportional to the negatively charged GAG molecules and leads to a shortening of the T1 times in the cartilage, a loss of GAG in the cartilage as indicated by the lowering of the T1 time in the dGEMRIC technique is an early sign of cartilage degeneration (indirect GAG measurement using the T1 time as a reciprocal measure of the GAG content in the cartilage). Another method, that does not require the use of a contrast agent, is T2 mapping. Quantitive T2 mapping is a way to measure T2 relaxation times in the cartilaginous coating, most commonly using two-dimensional spin-echo sequences, and allows for conclusions to be drawn with regard to collagen and water content as well as the zonal ultrastructure, especially of the collagen organization, the collagen fiber integrity, and the cartilaginous coating. Besides a loss of proteoglycans, there are also changes in the extracellular matrix and damage within the collagen fiber network. An increase in the T2 times, which are represented by colored maps and overlaid with anatomical MRI images, is associated with early degeneration or destruction of the collagen fiber network and increased water content in the cartilage. Elevated T2 values were found in patients with hip dysplasia and early osteoarthritis (Kellgren-Lawrence 1 – 2) [11] and in patients with femoral osteonecrosis and preserved femoral head

Fig. 7 Illustration of the indication for an MRI to assess the condition of the cartilage in order to support the TEP indication: 24-year-old male with right-side hip and groin pain who suffered a medial femoral fracture at the age of 10 and underwent corrective osteotomy of the right proximal femur. The X-ray **a** shows continued evidence of joint space at the deformed femoral head. The MRI, which was performed to show evidence/exclusion of cartilage damage, shows the deformed femoral head and the hypertrophic labrum (open arrow) as well as cartilage damage (arrows) and free bodies (open arrow); **b** coronal view; **c** sagittal view; and **d** axial fat-suppressed proton-density sequence. Despite his young age, the patient, suffering from secondary osteoarthritis with pronounced pain and an impaired lifestyle, was successfully treated with cementless total hip arthroplasty **e**.

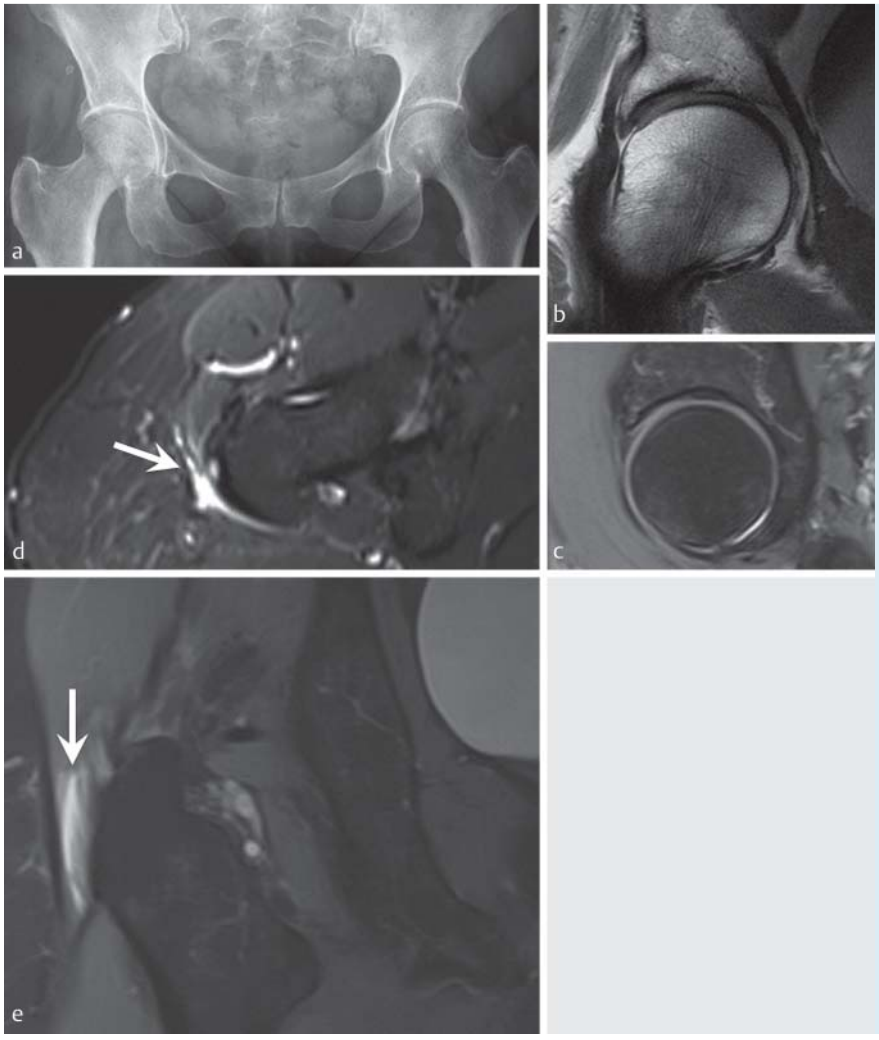

Fig. 8 Illustration of the indication for an MRI to exclude other causes of the hip joint pain: Unclear right-side coxalgia in a 68-year-old female with a normal hip X-ray **a** for someone of her age. The MRI, which was performed to clarify the causes of the condition, shows an intact cartilaginous covering but a trochanteric bursitis (arrows) as the cause of the coxalgia (**b** proton-density (PD) weighting in radial orientation; **c** sagittal fat-suppressed PD; **d** axial STIR; **e** coronal fat-suppressed PD). The patient underwent therapy using NSAIDs (non-steroidal anti-inflammatory drugs) whenever necessary and stretching and strengthening of the hip joint abductor muscles.

sphericity, when compared to healthy control groups [12]. However, many factors influenced the T2 signal, such as the hydration condition of the patient and the "magic angle effect" [13–15]. Another disadvantage of the technique is the lack of specificity for the concentration of GAG molecules in the cartilage, although the examination time has been reduced considerably. Newer studies point to an advantage of the combination of T2 mapping and dGEMRIC, which combines high sensitivity and specificity [16, 17].

Pre-Osteoarthritis of The Hip Joint

The diagnosis of pre-osteoarthritic conditions, which is gaining in importance, includes etiologically different misalignments, deformities, and labrum pathologies, all of which may lead to early development of osteoarthritis, if distinct and left untreated. Examples of pre-osteoarthritic deformities are dysplasia and malrotation, such as juvenile hip dysplasia, juvenile hip dislocation, and hereditary epiphyseal dysplasia, FAI, chronic stress such as after fractures, femoral head necrosis, Legg-Calvé-Perthes disease, and slipped epiphysis (**Fig. 12, 13**) [18]. FAI occurs in cases of incomplete congruence of femur and acetabulum. Normal hip joints are covered properly and have a spherical head, which permits physiological range of motion. There are two kinds of hip impingement: pincer impingement and cam-type impingement. However, it must be keep in mind that, with respect to radiological changes, a combined form of impingement is found in up to 86% of patients. In the case of pincer impingement, excessive covering, due to a protruding dorsal-cranial acetabular rim, for example, leads to early bone contact with the femoral neck and therefore to limited range of motion, which then leads to damage of the labrum and, through eccentric stress, to damage of the joint cartilage. In the case of cam impingement, the aspherical head with protruding subcapital femoral neck leads to early striking of the femoral neck at the ventral acetabulum and, therefore, painful restriction of mobility and, through eccentric stress on the cartilage, joint damage [19, 20]. This situation involves little to no offset between caput and collum femoris, which is also referred to as a bump deformity (**Fig. 14**). The term "bump" refers to appositional bone growth and is where the name "cam" is derived from. Labrum lesions in young patients are alarming because they represent an early the onset of irreversible joint damage. Labrum lesions usually result from a primary anomaly of the hip joint morphology with the FAI being a predisposing factor for premature osteoarthritis [21], since cam-type FAI typically first causes damage to the ventrolateral sublabral

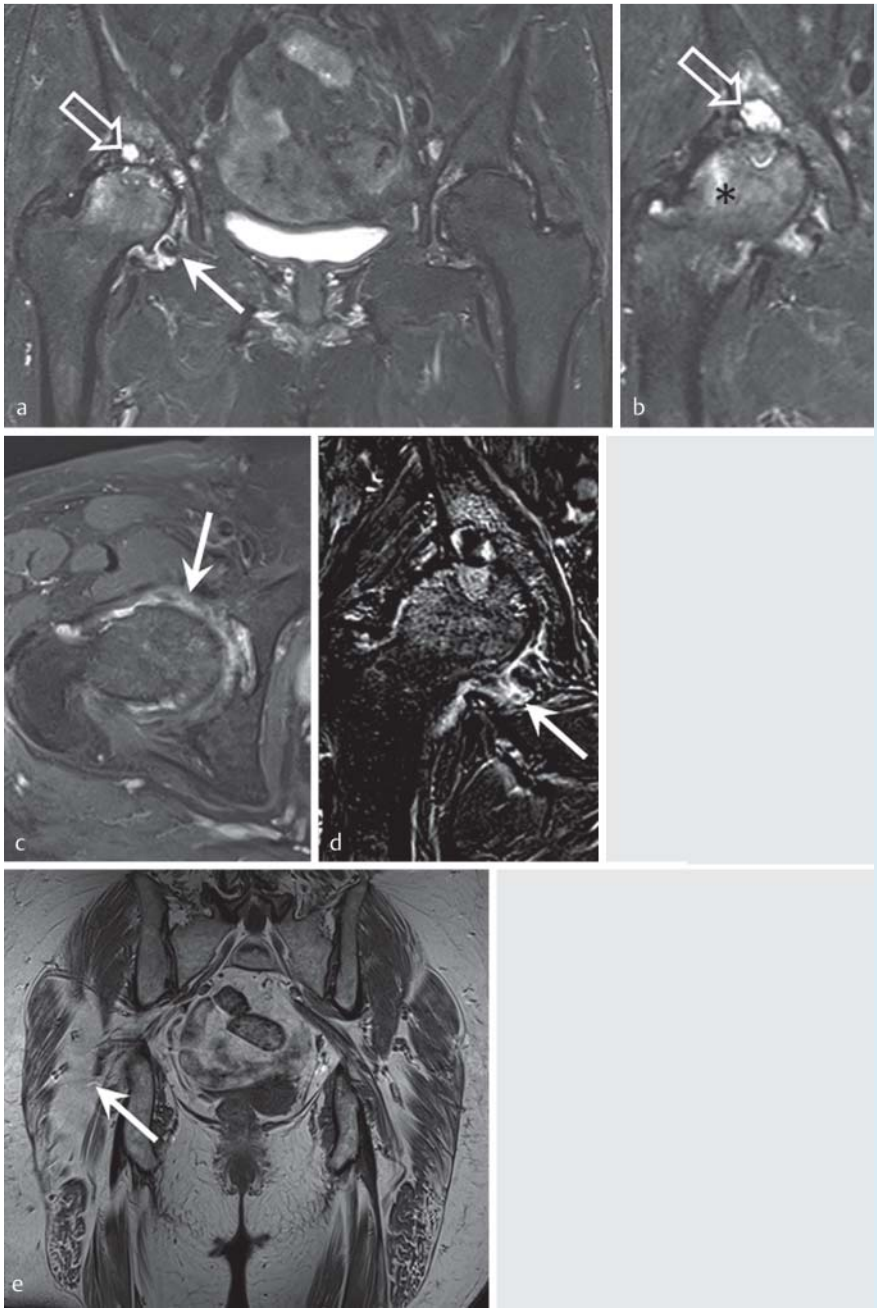

Fig. 9 Activated right-side osteoarthritis in a 69-year-old female with bone marrow edema (asterisk) in the femoral head and acetabulum, subchondral cyst formation (open arrows), free body (arrow in **a**), synovitis (arrows in **c – d**), and fatty muscle atrophy (arrow in **e**) of the right-side gluteal muscles (**a – b** coronal STIR; **c** axial contrast-enhanced fat-saturated T1-weighting; **d** coronal subtraction (CE T1w – T1w); **e** coronal T1-weighting).

socket cartilage and then causes labrum lesions. Labrum lesions are often commonly associated with manifest osteoarthritis. The prevalence of FAI in young people amounts to 10 – 15 % [22]. The diagnostic algorithm consists of anamnesis and clinical examination, whereby groin pressure pain and reproducible groin pain through a combination of hip flexion, adduction, and internal rotation are indicative of labrum lesions (positive anterior labrum impingement test). Projection radiography is also used here for the first images. That is followed by MRI or a MR arthrogram with greater sensitivity to evaluate possible damage to the cartilage and labrum [19, 23, 24]. Direct MR arthrography is the best imaging modality for preoperative evaluation of damage to the labrum or cartilage at the hip joint [25]. Since there is often no presence of effusion with labrum lesions and the labrum often shows a heterogeneous signal in healthy patients, too, distension of labral tears through direct MR arthrography leads to better diagnosis with a sensitivity/specificity of 90 – 95 %/91 % [26]. In-house, as an additional sequence, radial layering around the femoral neck is used, that depicts labrum and cartilage in an orthogonal way. The technique of direct MR arthrography that is used in-house is as follows: Joint puncture under fluoroscopy; test injection of 1 – 2 ml of iodine-containing contrast agent to verify the correct position; and injection of 10 – 20 ml of diluted gadolinium chelates such as gadoteric acid 0.0025 mmol/ml. If pain is provoked by distension of the joint, this is indicative of a labrum lesion, just as a brief reduction in pain through simultaneous intra-articular injection of a local anesthesia (such as bupivacaine 0.5 %) indicates the emergence of pain resulting from within the joint [27]. In projection radiography, an aspheric protrusion at

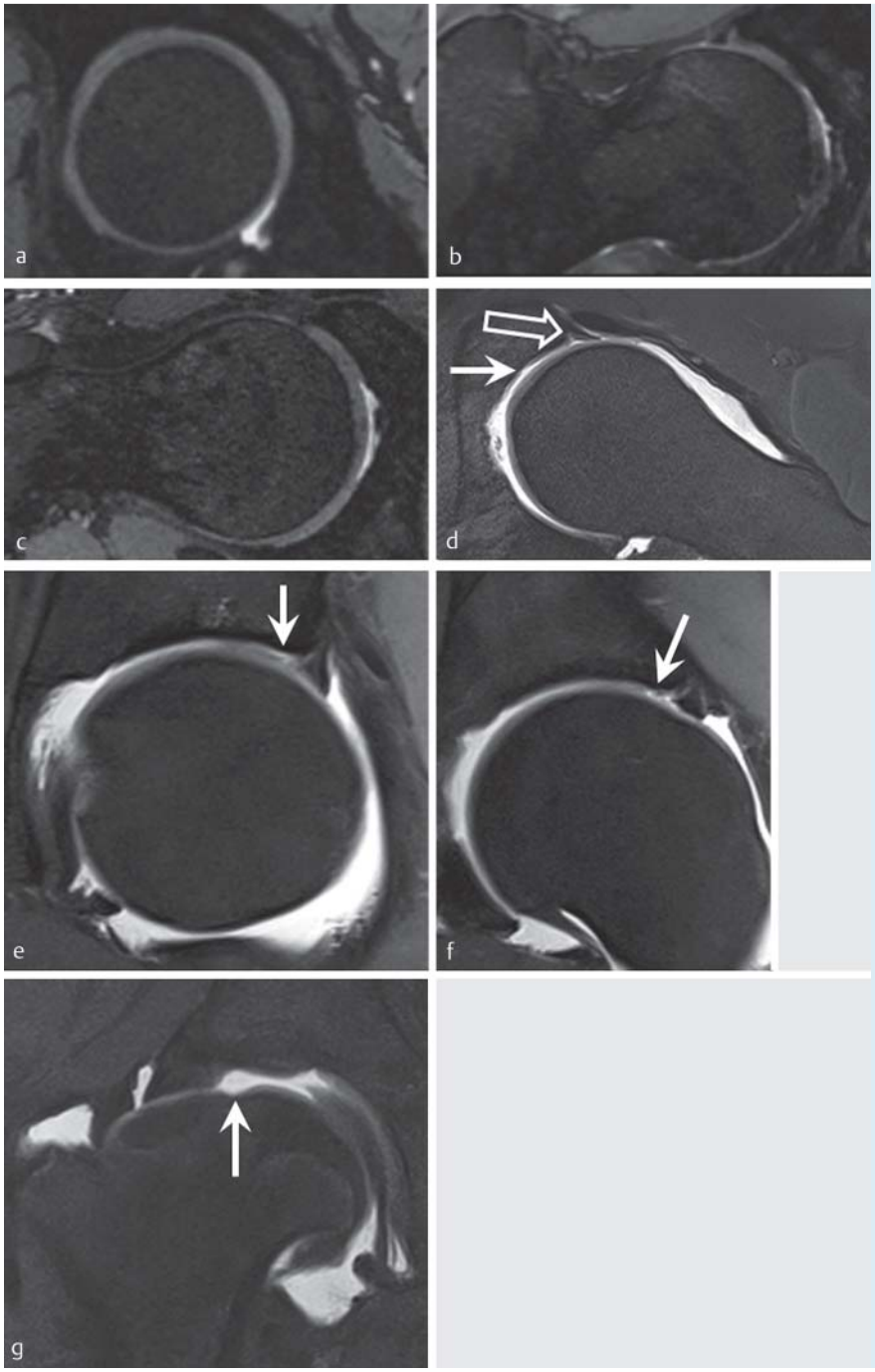

Fig. 10 **a – c** Illustration of normal hip cartilage using a three-dimensional TrueFisp sequence with an isotropic resolution of 0.63 mm^3 in a healthy 31-year-old female proband (**a** sagittal view; **b**: coronal view; **c**: transverse view). **d – f** 40-year-old male with cam-type femoroacetabular impingement. MR arthrogram with axial fat-suppressed T1-weighting **d** and coronal fat-suppressed proton-density weighting **e – f** shows the labral tear (open arrow) and cartilage damage (arrows) anterior-superior to the acetabulum with focal delamination. **g** 13-year-old male with Legg-Calvé-Perthes disease (first diagnosis and VDRO at the age of 7). (Coronal fat-suppressed T1-weighted) MR arthrogram shows focal cartilage damage at the femoral head (arrow).

the femoral head-neck junction with insufficient streamlining of the femoral head-neck junction (missing femoral neck offset) in the cam-type FAI can lead to pistol-grip deformity [28]. A criterion that has seen more and more use in the past few years that is especially suitable for MRI diagnostics is the alpha (α) angle [29, 30]. It is formed by the femoral neck axis, which runs through the middle of the femoral neck, and a second line that extends from the center of the femoral head through the point where the spherical contour of the femoral head ends (that is, where the head contour exits the femoral head circle) (▶ **Fig. 14**). Values greater than 50° are considered an indication of cam-type FAI [24], whereby the alpha angle should be measured on an MRI layer that runs axially and parallel to the femoral neck. The disadvantage is great variability of the measured values, depending on the reporting radiologist. For example, substantial overlap of the alpha angle appeared between healthy volunteers and patients with cam-type deformity with alpha angles of more than 55°, depending on who the analysis was performed by, of one to nearly 2/3 of all healthy volunteers, so that the authors have recommended a threshold value of 60° [31]. The alpha angle is most significant for the anterosuperior segment [31], which can also be approached well arthroscopically. An indirect sign of possible cam-type impingement can be the appearance of a herniation pit in the T2-weighted sequences. This transcortical synovial herniation is represented by high signal intensity erosion with an average diameter of 5 mm at the

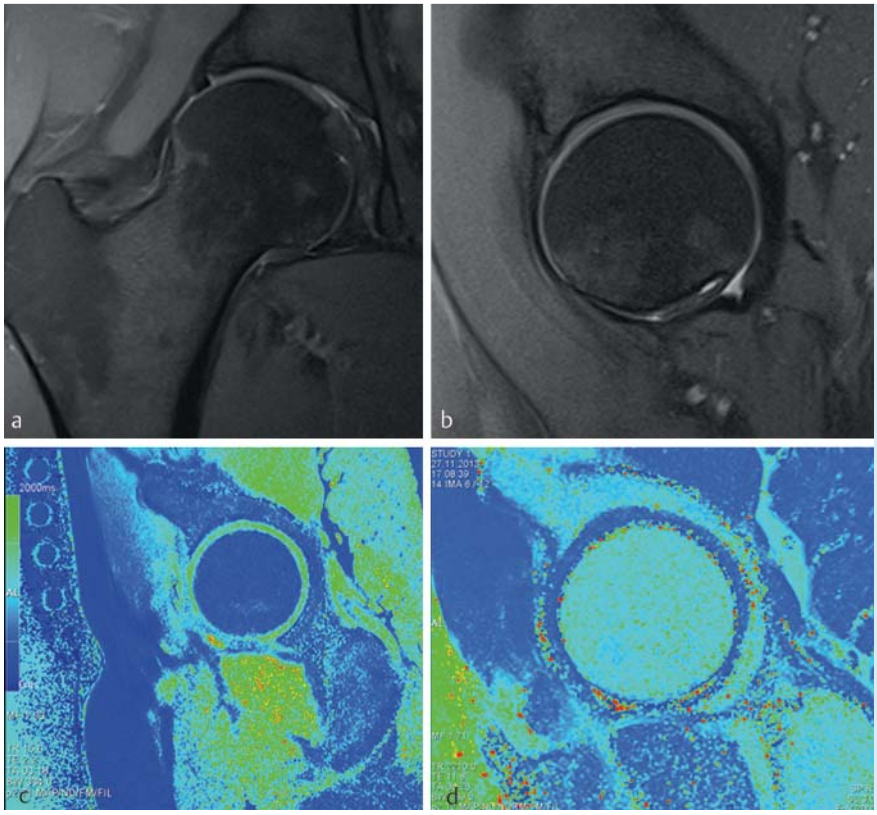

Fig. 11 Illustration of two functional MRI cartilage sequences of the hip in a healthy 31-year-old female proband. **a – b** Anatomic fat-suppressed proton-density weighting (**a** coronal view; **b** sagittal view); **c** dGEMRIC; and **d** T2 mapping parameter images. No presence of cartilage damage.

anterolateral femoral neck, in other words, exactly where the femoral neck strikes the acetabulum [32]. Attempts to establish measurements that are better suited than the alpha angle for differentiating between healthy people and those with cam-type FAI, such as femoral neck offset, have not yet achieved the desired effect [33]. Therefore, in our opinion, whenever any epimetaphyseal bump is present, the information that the radiologist puts in the findings report is more important than the measured value for the orthopedic surgeon, so that after examining the clinical indication the orthopedic surgeon can decide whether the bump can be approached using hip arthroscopy.

In general, careful consideration must be made when diagnosing FAI. A definitive diagnosis should only be based on a combination of typical clinical symptoms and imaging rather than, for example, a borderline alpha angle. To verify FAI, an intra-articular injection with local anesthetic can be administered as a diagnostic test. If conservative therapy over the course of roughly three months using physical therapy and pain medication does not lead to sufficient improvement of the symptoms, hip arthroscopy will be carried out in-house in accordance with imaging findings. The goal of the therapy in cases of FAI with labrum damage is to correct the individual pathoanatomy in order to achieve considerable improvement of impingement-free range of motion, which should prevent future mechanical damage to the labrum and cartilage. Pathomorphologies (such as bony growths on the femoral head in cases of cam-type impingement) are trimmed back with a ball cutter during hip arthroscopy. Since complete labral resection has worse clinical results than labral refixation, nowadays the goal is to restore the labrum as much as possible, whereby unstable parts of the labrum must be resected, in the same manner as meniscus tears, but labrum lesions with a stable rim and securely anchored base will be refixed with bone anchors [18, 22].

Various deformities such as coxa profunda, protrusio acetabuli, and acetabular retroversion, which can be detected using projection radiography, can cause pincer impingement. Normally, on a pelvic X-ray the ventral acetabular rim runs cranially and medial to the dorsal acetabular rim and both projection lines merge in the acetabular rim area. In the case of acetabular retroversion the two lines can cross sooner, which results in a “propeller” or “crossover” sign of the hip socket. Excessive femoral head coverage is commonly found in cases of acetabular retroversion or prominent posterior acetabular wall. Physiologically, the acetabulum is anteverted. With coxa profunda (deep acetabular socket) and protrusio acetabuli (lowering of the femoral head), the CE angle is typically enlarged. An angle of more than 39° is an indicator of coxa profunda or protrusio acetabuli in adults. Protrusio acetabuli occurs when the medial hip contour crosses over the ilioischial line medially [23, 28]. Pincer impingement arises from linear contact between the deep acetabular rim and the femoral head-neck junction. This can either occur locally, such as through malrotation of the socket, or circumferentially, as with coxa profunda. The femoral head-neck junction is normal in the case of pure pincer impingement (as opposed to cam-type impingement), but, over the course of time, persistent strikes cause changes to the head-neck junction that even include broad-based bone apposition. Therapeutically, this can be removed during hip arthroscopy and a circular ossified labrum can be removed using a ball cutter (**Fig. 14**). Here, too, the goal of the therapy is to correct the individual pathoanatomy in order to achieve considerable improvement

of impingement-free range of motion, which should prevent future mechanical damage to the labrum and cartilage [18, 22].

Conclusion

Conventional X-ray diagnostics was and still is the workhorse when diagnosing osteoarthritis. Projection radiography is the standard diagnostic method and serves to confirm the clinical diagnosis as well as to evaluate the degree of severity of osteoarthritis. CT is a good method for clearly illustrating bone stock, anatomic conditions, and deformation of the proximal femur. MRI is used to confirm early forms and to clarify possible cartilage damage and/or wear and tear, which cannot be seen on X-rays. Increasingly, subtle and often clinically long-term inapparent morphological anomalies of the proximal femur (such as cam impingement) and of the socket (such as pincer impingement) are also etiologically associated with osteoarthritis and FAI is seen today as a pre-osteoarthritic deformity. Evidence of labrum lesions in the MR arthrography often represents just the tip of the iceberg of pathological change of the acetabulum and/or femur, since that is often associated with obvious cartilage damage.

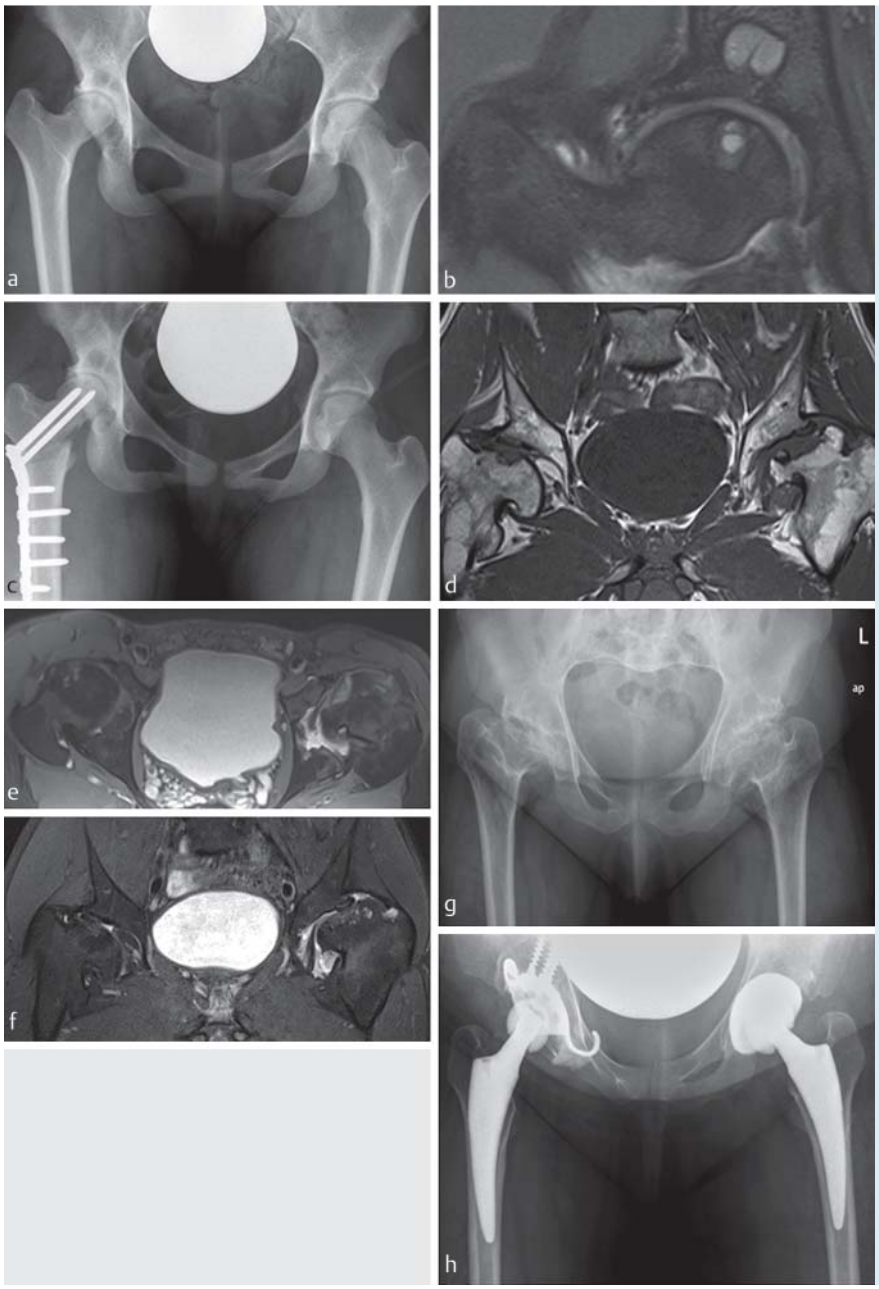

Fig. 12 Illustration of various pre-osteoarthritic conditions. **a – c** 15-year-old female with hypoplasia of the right femoral head in premature epiphyseal fusion following slipped capital femoral epiphysis and leg shortening of 2 cm at the right side. X-ray **a** shows both coxa vara and visible cysts in the right acetabulum. (Coronal fat-suppressed proton-density (PD) weighted) MR arthrography reveals intact cartilage. In order to delay the progress of osteoarthritis, an osteotomy with lengthening and valgisation of the femoral neck was performed with simultaneous filling of the cyst **c**. **d – h** Presentation of two cases with hereditary epiphyseal dysplasia, one in a 28-year-old male **d – f** and the other in a 28-year-old female **g – h**. In the male patient, the MRI (**d** coronal T1-weighting; **e** axial fat-suppressed PD; **f** coronal fat-suppressed PD) shows destruction of the femoral head with collapse of the joint surfaces, subluxation on the left side, and deformity of the femoral heads on both sides. However, the patient showed only limited clinical symptoms, so there was no indication for total joint replacement at his young age. In contrast, the female patient had significant restrictions in daily activities and continuous pain, so total hip arthroplasty was successfully performed **h**. Multiple epiphyseal dysplasia is an autosomal dominant hereditary disorder of the growth plates that affects enchondral ossification. It is important to distinguish between multiple epiphyseal dysplasia and Legg-Calvé-Perthes disease.

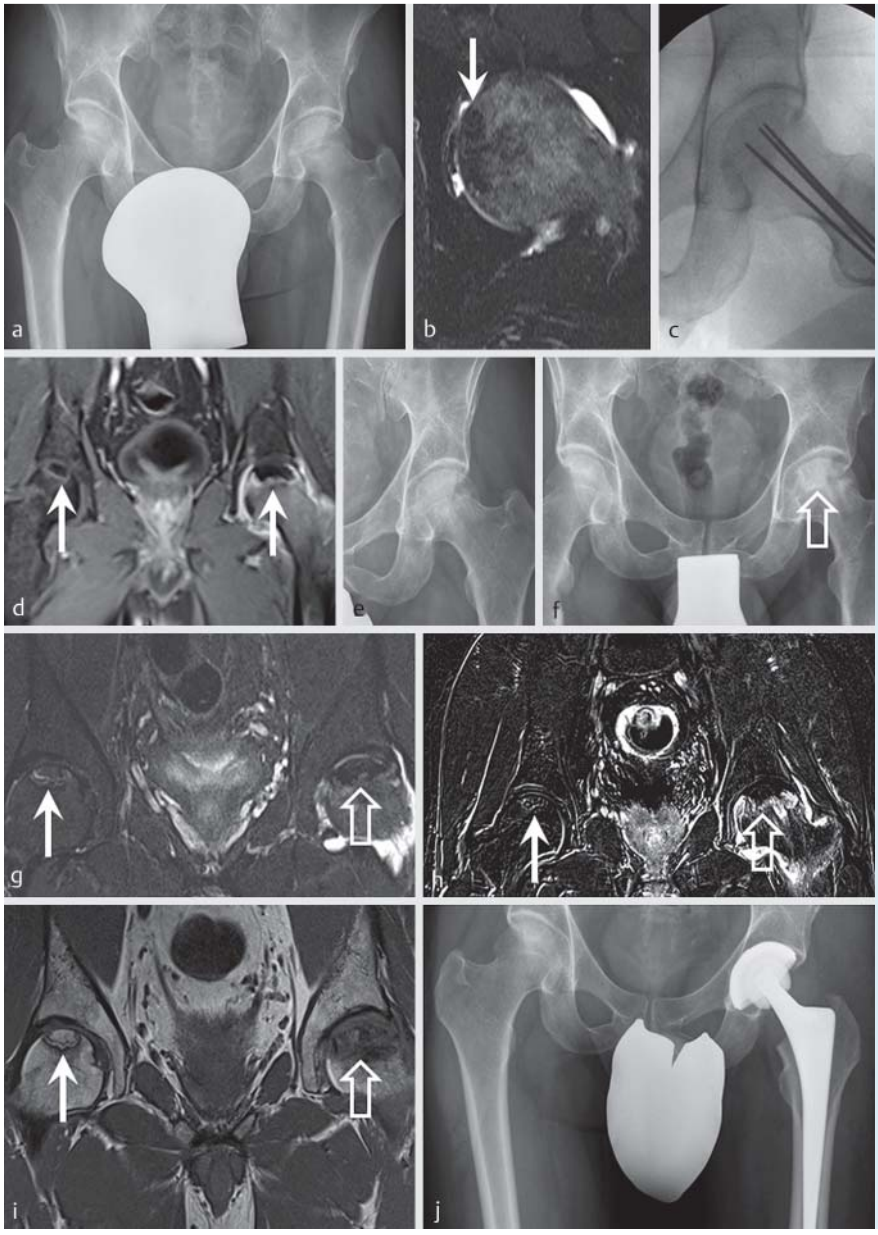

Fig. 13 37-year-old male after chemotherapy for non-Hodgkin's lymphoma two years ago. Illustration of ARCO (Association Research Circulation Osseous) Stage II femoral head avascular necrosis on the left side (arrow) which was treated with core decompression by K-wires (**a** X-ray; **b** axial fat-suppressed T2-weighting; **c** status after left-side core decompression one month later). Over the course of time, bilateral ARCO II necrosis appeared (arrows in **d** coronal, contrast-enhanced, fat-suppressed T1-weighting; **e** X-ray one month after core decompression) and six months later ARCO II on the right side (arrows) and ARCO IV on the left side (open arrows); **f** X-ray; **g** coronal STIR; **h** coronal subtraction (CE T1w – T1w); **i** coronal T1-weighting). Development of secondary osteoarthritis on the left side necessitated total hip arthroplasty eight months after first presentation **j**.

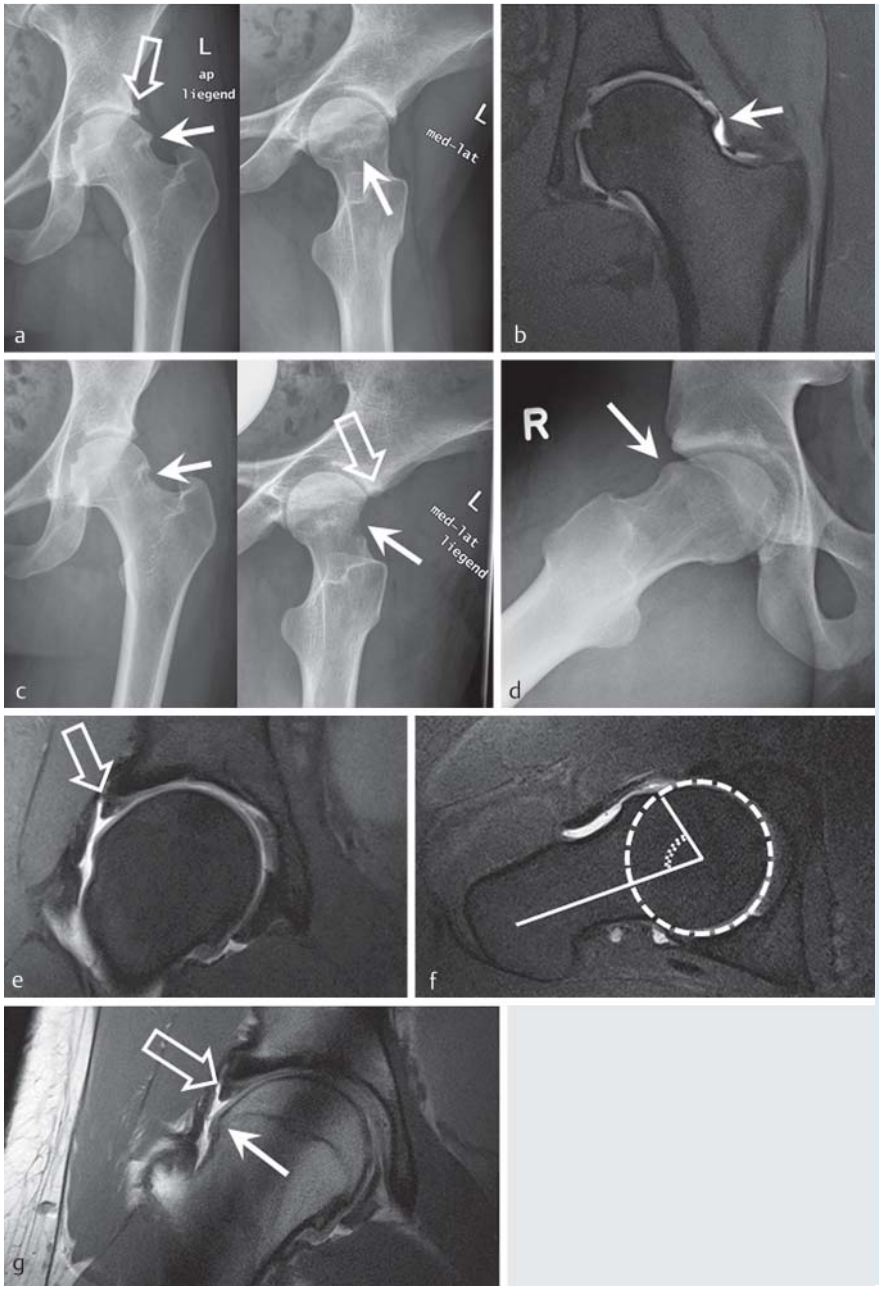

Fig. 14 23-year-old female with combined femoroacetabular impingement of the left hip with cam deformity (arrow) and pincer osteophyte (open arrow; **a** X-rays in two planes; **b** MR arthrography with coronal fat-suppressed T1-weighting). Using arthroscopy, both the pincer osteophyte and the epimetaphyseal bump were resected (**c** X-rays in two planes). 19-year-old male with cam-type impingement of the right hip (**d** axial X-ray; MR arthrography with **e** coronal proton-density weighting; **f** axial fat-suppressed T1-weighting parallel to the femoral neck, and **g** radial proton-density weighting). The arrow points to the epimetaphyseal bump and the labrum (open arrows) shows signal inhomogeneities that are a sign of beginning degeneration. The α-angle **f** is formed by the femoral neck axis and a second line that extends from the center of the femoral head through the point where the head contour leaves the sphericity and, in this case, is 76°. A reduced waist of the femoral head-neck junction is also referred to as a lack of femoral head-neck offset and is considered to be a pre-osteoarthritic deformity.

References

1 *Imhof H*, *Nöbauer-Huhmann I*, *Trattnig S*. Koxarthrose – ein Update. Radiologe 2009; 49: 400 – 409
2 *Sutter R*, *Zanetti M*, *Pfirrmann CW*. New developments in hip imaging. Radiology 2012; 264: 651 – 667
3 *Altman R*, *Alarcón G*, *Appelrouth D et al.* The American College of Rheumatology criteria for the classification and reporting of osteoarthritis of the hip. Arthritis Rheum 1991; 34: 505 – 514
4 *Imhof H*, *Czerny C*, *Gahleitner A et al.* Koxarthrose. Radiologe 2002; 42: 416 – 431
5 *Petchprapa CN*, *Recht MP*. Imaging of chondral lesions including femoroacetabular impingement. Semin Musculoskelet Radiol 2013; 17: 258 – 271
6 *Karachalios T*, *Karantanas AH*, *Malizos K*. Hip osteoarthritis: what the radiologist wants to know. Eur J Radiol 2007; 63: 36 – 48
7 *Moradi B*, *Rosshirt N*, *Tripel E et al.* Unicompartmental and bicompartmental knee osteoarthritis show different patterns of mononuclear cell infiltration and cytokine release in the affected joints. Clin Exp Immunol 2015; 180: 143 – 154
8 *Rehnitz C*, *Weber MA*. Morphologische und funktionelle Knorpeldiagnostik. Orthopäde 2015; 44: 317 – 336
9 *Zilkens C*, *Jäger M*, *Bittersohl B et al.* Delayed Gadolinium Enhanced MRI of Cartilage (dGEMRIC) – Molekulare MRT-Bildgebung des Hüftgelenkknorpels. Orthopäde 2009; 38: 591 – 599
10 *Burstein D*, *Velyvis J*, *Scott KT et al.* Protocol issues for delayed Gd (DTPA)(2-)-enhanced MRI (dGEMRIC) for clinical evaluation of articular cartilage. Magn Reson Med 2001; 45: 36 – 41
11 *Nishii T*, *Tanaka H*, *Sugano N et al.* Evaluation of cartilage matrix disorders by T2 relaxation time in patients with hip dysplasia. Osteoarthritis Cartilage 2008; 16: 227 – 233
12 *Yamamoto S*, *Watanabe A*, *Nakamura J et al.* Quantitative T2 mapping of femoral head cartilage in systemic lupus erythematosus patients with noncollapsed osteonecrosis of the femoral head associated with corticosteroid therapy. J Magn Reson Imaging 2011; 34: 1151 – 1158
13 *Dunn TC*, *Lu Y*, *Jin H et al.* T2 relaxation time of cartilage at MR imaging: comparison with severity of knee osteoarthritis. Radiology 2004; 232: 592 – 598
14 *Liess C*, *Lüsse S*, *Karger N et al.* Detection of changes in cartilage water content using MRI T2-mapping in vivo. Osteoarthritis Cartilage 2002; 10: 907 – 913
15 *Mosher TJ*, *Smith H*, *Dardzinski BJ et al.* MR imaging and T2 mapping of femoral cartilage: in vivo determination of the magic angle effect. Am J Roentgenol 2001; 177: 665 – 669
16 *Lattanzi R*, *Petchprapa C*, *Ascani D et al.* Detection of cartilage damage in femoroacetabular impingement with standardized dGEMRIC at 3 T. Osteoarthritis Cartilage 2014; 22: 447 – 456
17 *Bittersohl B*, *Hosalkar HS*, *Hesper T et al.* Advanced imaging in femoroacetabular impingement: Current state and future prospects. Front Surg 2015; 2: 34. DOI: 10.3389/fsurg.2015.00034 eCollection 2015.
18 *Tibor LM*, *Leunig M*. The pathoanatomy and arthroscopic management of femoroacetabular impingement. Bone Joint Res 2012; 1: 245 – 257
19 *Steppacher SD*, *Tannast M*, *Siebenrock KA*. Labrumläsionen des Hüftgelenks. Orthopädie und Unfallchirurgie up2date 2008; 3: 215 – 232
20 *Weber MA*, *Rehnitz C*, *Ott H et al.* Leistenschmerz beim Sportler. Fortschr Röntgenstr 2013; 185: 1139 – 1148
21 *Beck M*, *Leunig M*, *Parvizi J et al.* Anterior femoroacetabular impingement: part II. Midterm results of surgical treatment. Clin Orthop Relat Res 2004; 418: 67 – 73
22 *Weber MA*, *Egermann M*, *Thierjung H et al.* Moderne radiologische postoperative Diagnostik des Hüftgelenks im Kindes- und Erwachsenenalter. Fortschr Röntgenstr 2015; 187: 525 – 542
23 *Mamisch TC*, *Werlen S*, *Zilkens C et al.* Radiologische Diagnose des femoroazetabulären Impingements. Radiologe 2009; 49: 425 – 433
24 *Räuchle M*, *Cemerka M*, *Eibenberger B et al.* Arthrose – Update 2012. Radiologe 2012; 52: 149 – 155
25 *Sutter R*, *Zubler V*, *Hoffmann A et al.* Hip MRI: how useful is intraarticular contrast material for evaluating surgically proven lesions of the labrum and articular cartilage? Am J Roentgenol 2014; 202: 160 – 169
26 *Llopis E*, *Fernandez E*, *Cerezal L*. MR and CT arthrography of the hip. Semin Musculoskelet Radiol 2012; 16: 42 – 56
27 *Jesse MK*, *Petersen B*, *Strickland C et al.* Normal anatomy and imaging of the hip: emphasis on impingement assessment. Semin Musculoskelet Radiol 2013; 17: 229 – 247
28 *Reid GD*, *Reid CG*, *Widmer N et al.* Femoroacetabular impingement syndrome: an underrecognized cause of hip pain and premature osteoarthritis? J Rheumatol 2010; 37: 1395 – 1404
29 *Nötzli HP*, *Wyss TF*, *Stoecklin CH et al.* The contour of the femoral head-neck junction as a predictor for the risk of anterior impingement. J Bone Joint Surg Br 2002; 84: 556 – 560
30 *Pfirrmann CW*, *Mengiardi B*, *Dora C et al.* Cam and pincer femoroacetabular impingement: characteristic MR arthrographic findings in 50 patients. Radiology 2006; 240: 778 – 785
31 *Sutter R*, *Dietrich TJ*, *Zingg PO et al.* How useful is the alpha angle for discriminating between symptomatic patients with cam-type femoroacetabular impingement and asymptomatic volunteers? Radiology 2012; 264: 514 – 521
32 *Leunig M*, *Beck M*, *Kalhor M et al.* Fibrocystic changes at anterosuperior femoral neck: prevalence in hips with femoroacetabular impingement. Radiology 2005; 236: 237 – 246
33 *Ehrmann C*, *Rosskopf AB*, *Pfirrmann CW et al.* Beyond the alpha angle: Alternative measurements for quantifying cam-type deformities in femoroacetabular impingement. J Magn Reson Imaging 2015; 42: 1024 – 1031