

Endometriosis-associated Maternal Pregnancy Complications – Case Report and Literature Review

Maternale Endometriose-assoziierte Schwangerschaftskomplikationen – Fallbericht und Literaturübersicht

Authors

J. Petresin, J. Wolf, S. Emir, A. Müller, A. S. Boosz

Affiliation

Frauenklinik, Städtisches Klinikum, Karlsruhe

Key words

- endometriosis
- pregnancy
- complication
- delivery
- decidualization
- intraabdominal bleeding

Schlüsselwörter

- Endometriose
- Schwangerschaft
- Komplikation
- Hämoperitoneum



Deutsche Version unter:
<http://dx.doi.org/10.1055/s-0042-101026>

received 21.10.2015
revised 12.1.2016
accepted 17.1.2016

Bibliography

DOI <http://dx.doi.org/10.1055/s-0042-101026>
 Geburtsh Frauenheilk 2016; 76: 902–905 © Georg Thieme Verlag KG Stuttgart · New York · ISSN 0016-5751

Correspondence

Dr. med.
Alexander Stephan Boosz
 Städtisches Klinikum
 Frauenklinik
 Moltkestraße 90
 76133 Karlsruhe
 alexander.boosz@
 klinikum-karlsruhe.de

Abstract



The incidence of endometriosis is increasing. Particularly during pregnancy and labour, clinicians should be alert to possible endometriosis-associated complications or complications of previous endometriosis treatment, despite a low relative risk. In addition to an increased rate of early miscarriage, complications such as spontaneous bowel perforation, rupture of ovarian cysts, uterine rupture and intraabdominal bleeding from decidualised endometriosis lesions or previous surgery are described in the literature. Unfavourable neonatal outcomes have also been discussed. We report on an irreducible ovarian torsion in the 16th week of pregnancy following extensive endometriosis surgery, and an intraabdominal haemorrhage due to endometriosis of the bowel in the 29th week of pregnancy.

Introduction



Endometriosis is a chronic disease that affects 4–30% of all women of child-bearing age. The prevalence is even higher among women with infertility (up to 50%) [1]. Dysmenorrhea is the main clinical symptom of the disease, which is characterised by the presence of endometrial cells outside of the uterus. Endometriosis commonly occurs superficially in the peritoneal membrane however it can also infiltrate deeply into e.g. the bladder, rectum and other bowel segments. Serious maternal pregnancy complications mostly occur in association with this deeply infiltrating form of the disease.

After data adjustment for age and gestational age women with endometriosis have tubal pregnancies almost three times more often (odds ratio 2.7 [95% confidence interval 1.09–6.72]), and almost twice as many miscarriages (1.76 [1.44–2.15]) compared to women without endometriosis

Zusammenfassung



Durch die zunehmende Inzidenz der Endometriose muss, trotz des geringen relativen Risikos, gerade während Schwangerschaft und Entbindung bei diesen Patientinnen an eine Komplikation durch Endometriose oder vorherige Therapie gedacht werden. Neben einer erhöhten Abortrate in der Frühschwangerschaft werden in der Literatur Komplikationen wie spontane Darm- und Ovarialzystenruptur, Uterusruptur sowie intraabdominale Blutungen durch dezidualisierte Endometrioseherde oder vorangegangene Operationen beschrieben. In der Literatur wird sogar ein ungünstigeres neonatales Outcome diskutiert. Wir berichten über eine nicht mehr detorquierbare Stieldrehung in der 16. SSW nach ausgedehnter Endometrioseoperation und eine intraabdominale Blutung bei Darmendometriose in der 29. SSW.

[2]. The same study, with a study population of 5375 patients, found increased risk of placenta praevia (OR 2.24), antenatal haemorrhage of uncertain cause (OR 1.67) and postpartum haemorrhage (OR 1.26) [2].

Endometriosis does not always regress during pregnancy. Endometrial decidualisation in particular is responsible for many of the complications occurring during pregnancy. Increased progesterone production is causative [3]. The risk of endometriosis complications is particularly high in the second half of pregnancy and during labour. Risks described in the literature include spontaneous intraabdominal haemorrhage, uterine rupture, bowel perforation, endometriosis cyst perforation and ovarian torsion in the presence of ovarian endometrioma.

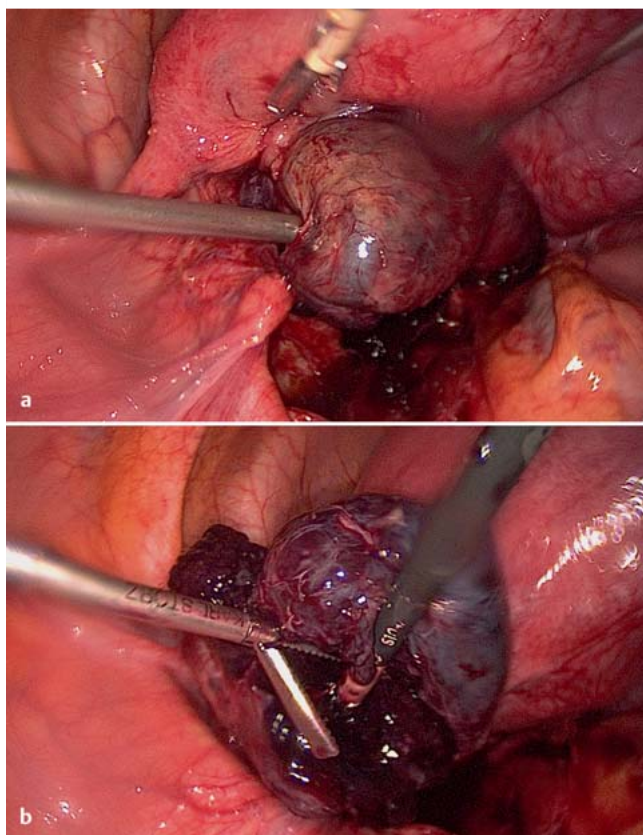


Fig. 1 a and b **a** Case 1 – left adnexal torsion: The mass is twisted three times on its long axis between the ovarian suspensory ligament and the ovarian ligament. Detorsion was impossible due to the size of the mass. The surgical instrument on the left is in the previously fenestrated broad ligament. **b** Case 1 – haemorrhagic left adnex: Haemorrhagic infarction secondary to torsion. The surface is ruptured on attempted detorsion with blunt instruments.

Case 1

A 33-year-old patient (gravida III, para I) had previously had extensive endometriosis surgery in 2009. Amongst other procedures she had had an extensive peritonectomy for peritoneal endometriosis. She subsequently underwent unsuccessful fertility treatment. She ultimately fell pregnant naturally in 2011 and the child was born in 2012 by caesarean section without complication. Her subsequent pregnancy, the one in question, was also natural.

The patient presented to us from an external hospital at 15+4 weeks gestation with severe left-sided lower abdominal pain that had been present for 3 days. Ultrasound showed an adnexal mass measuring approx. 60 × 40 mm. Symptoms improved with conservative management, and an expectant approach with analgesia was agreed on with the patient. After 2 days the patient's symptoms had not yet resolved and she was transferred to our hospital. On ultrasound the adnexal mass was found to have grown to a diameter of approx. 80 mm, the structure appearing mostly haemorrhagic. Under suspicion of a progressively enlarging, haemorrhagic ovarian cyst with persistent symptoms the decision was made to perform a laparoscopy.

Intraoperatively the uterus was appropriately enlarged for the pregnancy and the right adnex was normal. The left adnex was obviously enlarged, with black discoloration, and was adherent

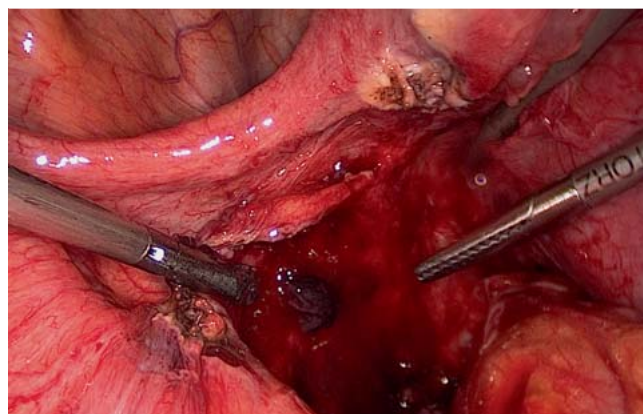


Fig. 2 Case 1 – postoperative status, left pelvic wall: The left adnex has been removed. Excision was performed at the ovarian suspensory ligament (at bottom left of picture) and the ovarian ligament (top right).

to the pelvic wall and sigmoid colon. After adhesiolysis and mobilisation of the sigmoid a necrotic adnexal torsion was found (● Fig. 1 a and b). Detorsion was unsuccessful. The left broad ligament had evidently been broken through, and the left adnex was twisted 3 times on its long axis both in the region of the ovarian suspensory ligament and the ovarian ligament (● Fig. 1 a). Because of the adnexal enlargement it was not possible to perform detorsion through the defect in the broad ligament. A left adnexectomy was thus performed (● Fig. 2). The patient was discharged home on the 4th postoperative day after an uneventful postoperative course. Fetal ultrasound before discharge was normal, the patient delivered via repeat caesarean section in the 39th week of gestation.

Case 2



This 25-year-old patient was admitted at 27+1 weeks gestation with vaginal bleeding and preterm labour. On history she was noted to have had a laparoscopic endometriosis operation in 2011 and a previous appendicectomy. At laparoscopy in an external centre endometriosis was noted between the rectum and posterior uterine wall but left in situ since consent to treat it operatively was lacking.

Initially placental abruption was suspected, however this was not confirmed and RDS prophylaxis with celestan as well as tocolysis with fenoterol bolus was carried out. Ultrasound, laboratory parameters and repeated CTGs showed no abnormalities. The patient's symptoms improved under tocolysis and on the third day of admission had completely resolved, including the bleeding. CTG and cervical findings were persistently normal and she was discharged.

At 28+2 weeks gestation she presented again, this time as an emergency, again with unusually heavy vaginal bleeding. The cervical length was 27 mm without funneling. She was admitted and tocolysis commenced with a partusisten bolus. On ultrasound there was again no evidence of placental abruption. The following day the patient was noted to have extremely severe abdominal pain that made micturition impossible. There was still no ultrasound evidence of placental abruption and both fetal heart rate and doppler indices were normal. Clinical signs were however suggestive of peritonitis, with extreme abdominal pain

and muscular defence, circulatory instability and raised CRP. At this point vaginal bleeding had stopped. The patient's condition was considered life-threatening and in the presence of recurrent vaginal bleeding of unknown cause the decision was made to perform a caesarean section despite the early gestation. Since the aetiology of the acute abdomen was unknown it was decided to operate under general anaesthesia. At surgery an extensive haemoperitoneum was found. After delivery of the child some dark blood clot was found in the uterus at the placental margins indicating a marginal sinus haemorrhage or early, partial placental abruption. The child was delivered without complication and after closure of the uterus the abdomen was explored to identify the source of the bleeding. Numerous actively bleeding serosal defects were found on the posterior uterine wall and anterior surface of the rectum, and a torn adhesion was found between bowel (sigmoid colon/rectum) and uterus. Attempted haemostasis using sutures was unsuccessful due to tissue vulnerability. The posterior uterine wall was thus covered with haemostatic fibrin glue and compression applied. A Robinson drain was also inserted. There were no postoperative complications, blood transfusion was not necessary and the patient was discharged on the 5th postoperative day.

Discussion



Case 1

To our knowledge this is the first case report of an endometriosis complication in pregnancy occurring 5 years after previous surgery. It is conceivable that deperitonealisation ventral and dorsal of the left ovary had been performed. During surgery the ovary may have been fixed temporarily to the abdominal wall to assist the complicated operation. It is impossible to exactly estimate when the torsion occurred. The possibly long-standing torsion may only have become symptomatic when the cyst increased in volume in addition to uterine enlargement.

Since ovary and Fallopian tube had completely twisted around the axis between the uterine suspensory ligament and the ovarian ligament adnexectomy was the only option. In view of the extreme pain the patient was experiencing we thought laparoscopy was indicated despite the minimally increased risk of intrauterine fetal death [4].

Case 2

This case illustrates a rare but typical endometriosis-associated pregnancy complication. Hospital admission and RDS prophylaxis were undertaken in view of vaginal bleeding of uncertain cause. Within a few hours the pain had become extreme and there were clinical signs of an acute abdomen, together clearly indicating the need for further investigation. Laparoscopy may also have identified the problem, though the size of the uterus may have been limiting [5]. In the context of recent onset vaginal bleeding in association with acute, severe pain we felt immediate delivery of the baby was indicated since the patient's condition was potentially life-threatening and the causative pathology still unknown.

Intraabdominal bleeding

Spontaneous peritoneal bleeding occurs in the second half of pregnancy, during labour and occasionally postpartum. The most important symptoms are acute or subacute abdominal pain followed by hypovolaemic shock and fetal distress [6]. The largest

study on the incidence of haemoperitoneum in pregnancy is a retrospective analysis of 800 women from a period of 5 years. The study describes three women (0.38%) with significant intra-abdominal bleeding during the third trimester due to endometriosis [7]. There are also a few reports of stillbirths [8] and early neonatal deaths [9] due to fulminant haemoperitoneum causing hypovolaemic shock.

In pregnant women with the triad of a history of previous endometriosis, severe abdominal pain and a fall in haemoglobin, intraabdominal haemorrhage must be considered [10]. Endometriosis can also rarely result in haemoperitoneum in non-gravid patients [11].

Endometrioma

The incidence of adnexal tumours in pregnancy is approximately 4% [12], the figure varying between studies. 11.5% of these tumours are endometriomas [13]. It is not possible to estimate the incidence of endometrioma-associated complications as there are too few cases reported. To date there have been four case reports of perforated endometrioma during pregnancy [14]. Symptoms are those of intraabdominal bleeding.

Bowel perforation

The incidence of this complication also remains unknown. A review article on the topic found 12 cases reports of bowel perforation during pregnancy that were caused by endometriosis [15]. All cases presented with an acute abdomen. All patients had emergency operations, either a Hartmann's procedure or a segmental resection. Sites of perforation were as follows: 2× small bowel, 1× caecum, 3× appendix and 6× rectum and sigmoid colon [15]. Bowel perforation is thought to be the result of increased traction on adherent endometriosis lesions by the growing uterus in combination with intractable pressure from faeces [16].

Uterine rupture

Spontaneous uterine rupture during pregnancy is very rare in the context of adenomyosis without previous uterine surgery; two case reports exist [17, 18]. Recent publications describe intrapartum uterine rupture following previous surgery for cystic adenomyosis [19, 20]. There is no clinical evidence supporting the resection of adenomyosis to improve fertility. The danger of uterine rupture must be considered in future patient care, especially when surgery has resulted in larger myometrial defects [21]. An optimal myometrial thickness of 9–15 mm following resection is described [22].

Surgery during pregnancy

Symptomatic ovarian cysts are operated most commonly at the end of the first and beginning of the second trimesters [4]. In a retrospective analysis one third of cysts became evident because of ovarian torsion [4]. Laparoscopic access and operative management is possible up until the 26th to 28th week of gestation, dependant on the surgeon's experience [23].

No general recommendation can be made to treat endometriosis operatively during or before pregnancy in order to avoid this complication, since there is no evidence that this improves pregnancy or pregnancy outcome [24].

Conclusion

The complications described here are rare (approx. 0.4%). A comprehensive history including symptoms of endometriosis and previous operations is decisive in the differential diagnosis. The risk of these endometriosis-associated complications is determined by endometriosis severity (superficial or deep infiltrating) as well as the extent of previous surgery. When the clinical presentation is unclear further investigation must be undertaken dependant on gestation and including diagnostic/operative laparoscopy when indicated. Alternatively there should be a low threshold for caesarean section, particularly at advanced gestations. Elective caesarean section may be indicated for both completely operated endometriosis and incompletely operated, deep infiltrating endometriosis. However, a general recommendation can not be made.

Conflict of Interest

None.

References

- Burghaus S, Klingsiek P, Fasching PA et al. Risk factors for endometriosis in a german case-control study. *Geburtsh Frauenheilk* 2011; 71: 1073–1079
- Kmietowicz Z. Endometriosis is linked to greater risk of complications in pregnancy and birth, study finds. *BMJ* 2015; 350: h3252
- Zaytsev P, Taxy JB. Pregnancy-associated ectopic decida. *Am J Surg Pathol* 1987; 11: 526–530
- Koo YJ, Lee JE, Lim KT et al. A 10-year experience of laparoscopic surgery for adnexal masses during pregnancy. *Int J Gynaecol Obstet* 2011; 113: 36–39
- Juhasz-Boss I, Solomayer E, Strik M et al. Abdominal surgery in pregnancy—an interdisciplinary challenge. *Dtsch Arztebl Int* 2014; 111: 465–472
- Brosens IA, Fusi L, Brosens JJ. Endometriosis is a risk factor for spontaneous hemoperitoneum during pregnancy. *Fertil Steril* 2009; 92: 1243–1245
- Katorza E, Soriano D, Stockheim D et al. Severe intraabdominal bleeding caused by endometriotic lesions during the third trimester of pregnancy. *Am J Obstet Gynecol* 2007; 197: 501.e1–501.e4
- Chiodo I, Somigliana E, Dousset B et al. Urohemoperitoneum during pregnancy with consequent fetal death in a patient with deep endometriosis. *J Minim Invasive Gynecol* 2008; 15: 202–204
- Mizumoto Y, Furuya K, Kikuchi Y et al. Spontaneous rupture of the uterine vessels in a pregnancy complicated by endometriosis. *Acta Obstet Gynecol Scand* 1996; 75: 860–862
- Cozzolino M, Corioni S, Maggio L et al. Endometriosis-related hemoperitoneum in pregnancy: a diagnosis to keep in mind. *Ochsner J* 2015; 15: 262–264
- Morgan TL, Tomich EB, Heiner JD. Endometriosis presenting with hemorrhagic ascites, severe anemia, and shock. *Am J Emerg Med* 2013; 31: 272.e1–272.e3
- Hill LM, Connors-Beatty DJ, Nowak A et al. The role of ultrasonography in the detection and management of adnexal masses during the second and third trimesters of pregnancy. *Am J Obstet Gynecol* 1998; 179: 703–707
- Bromley B, Benacerraf B. Adnexal masses during pregnancy: accuracy of sonographic diagnosis and outcome. *J Ultrasound Med* 1997; 16: 447–452; quiz 453–454
- Vigano P, Corti L, Berlanda N. Beyond infertility: obstetrical and postpartum complications associated with endometriosis and adenomyosis. *Fertil Steril* 2015; 104: 802–812
- Setubal A, Sidiropoulou Z, Torgal M et al. Bowel complications of deep endometriosis during pregnancy or in vitro fertilization. *Fertil Steril* 2014; 101: 442–446
- Costa A, Sartini A, Garibaldi S et al. Deep endometriosis induced spontaneous colon rectal perforation in pregnancy: laparoscopy is advanced tool to confirm diagnosis. *Case Rep Obstet Gynecol* 2014; 2014: 907150
- Donna A, Bosi D, Sommariva F. [Rupture of the endometriosis uterus in pregnancy]. *Cancro* 1967; 20: 400–410
- Kawabara H, Yazaki H, Hosobe S. [Endometriosis of the uterine wall and spontaneous rupture of the pregnant uterus]. *Jpn J Med Sci Biol* 1962; 48: 177–180
- Fettback PB, Pereira RM, Domingues TS et al. Uterine rupture before the onset of labor following extensive resection of deeply infiltrating endometriosis with myometrial invasion. *Int J Gynaecol Obstet* 2015; 129: 268–270
- Dim CC, Agu PU, Dim NR et al. Adenomyosis and uterine rupture during labour in a primigravida: an unusual obstetric emergency in Nigeria. *Trop Doct* 2009; 39: 250–251
- Pepas L, Deguara C, Davis C. Update on the surgical management of adenomyosis. *Curr Opin Obstet Gynecol* 2012; 24: 259–264
- Otsubo Y, Nishida M, Arai Y et al. Association of uterine wall thickness with pregnancy outcome following uterine-sparing surgery for diffuse uterine adenomyosis. *Aust N Z J Obstet Gynaecol* 2015; DOI: 10.1111/ajo.12419
- Pearl J, Price R, Richardson W et al. Guidelines for diagnosis, treatment, and use of laparoscopy for surgical problems during pregnancy. *Surg Endosc* 2011; 25: 3479–3492
- Leone Roberti Maggiore U, Ferrero S, Mangili G et al. A systematic review on endometriosis during pregnancy: diagnosis, misdiagnosis, complications and outcomes. *Hum Reprod Update* 2016; 22: 70–103