Posttreatment Imaging of the Knee: Cruciate Ligaments and Menisci

Andreas Heuck[1] Klaus Woertler[2]

[1] Radiologische Klinik und Poliklinik, Ludwig-Maximilian-University Hospital, Munich, Germany
[2] Institut für Diagnostische und Interventionelle Radiologie, Technical University of Munich, Munich, Germany

Address for correspondence Andreas Heuck, Radiologisches Zentrum München (RZM), Pippingerstr. 25, D-81245 Munich, Germany (e-mail: heuck@rzm.de).

Semin Musculoskelet Radiol 2022;26:230–241.

Abstract

Cruciate ligament reconstruction and meniscal surgery are frequently performed for restoration of knee joint stability and function after cruciate ligament and meniscus injuries, and they contribute to the prevention of secondary osteoarthritis. In cruciate ligaments, the most common procedure is anterior cruciate ligament (ACL) reconstruction. Meniscal surgery most frequently consists of partial meniscectomy and suture repair, rarely of a meniscus transplant. In patients with symptoms following surgery, imaging reevaluation for a suspected intra-articular source of symptoms is indicated and mainly consists of radiography and magnetic resonance imaging. For proper imaging assessment of cruciate ligament grafts and the postoperative meniscus, it is crucial to understand the surgical techniques applied, to be familiar with normal posttreatment imaging findings, and to be aware of patterns and specific findings of recurrent lesions and typical complications. This article presents an updated review of the techniques and the imaging of cruciate ligament reconstruction and meniscus surgery, recurrent lesions, treatment failure, and potential complications.

Keywords
- knee
- ligaments
- menisci
- cruciate ligament reconstruction
- meniscus repair
- magnetic resonance imaging
- computed tomography

Reconstruction of cruciate ligaments and meniscal surgery account for most surgical procedures in the knee and are routinely performed for restoration of posttraumatic knee joint stability and/or the prevention of secondary osteoarthritis. However, many individuals sustain subsequent knee injuries or have persistent pain, instability, or limited knee motion following surgery that require additional evaluation to assess for a suspected intra-articular source of symptoms. The evaluation typically begins with clinical examination and radiography, but magnetic resonance imaging (MRI) is commonly the modality of choice for detailed morphological assessment of potential intra-articular derangement. Multiplanar high-resolution computed tomography (CT) has a specific role in the evaluation of tunnel widening after cruciate ligament reconstruction and may serve in the form of CT arthrography as an alternative in patients with contraindications to MRI to evaluate ligament graft abnormalities or meniscal retears.

For proper interpretation of knee imaging after surgical treatment of cruciate ligament and meniscus injuries, the radiologist must understand the surgical techniques applied, the normal imaging appearance of the knee after cruciate ligament reconstruction and meniscal surgery, recurrent lesions, and potential complications associated with surgical procedures.[1–6]

Cruciate Ligaments

Anterior Cruciate Ligament Reconstruction

Single-Bundle and Double-Bundle Reconstruction

The classic procedure of anterior cruciate ligament (ACL) reconstruction is the single-bundle reconstruction (SBR) technique using one graft for the replacement of both the anteromedial and posterolateral bundle of the ligament. Because these two bundles act synergistically in the

Issue Theme Posttreatment Imaging (ESSR); Guest Editor, Marc-André Weber, MD, MSc

© 2022. Thieme. All rights reserved.
Thieme Medical Publishers, Inc., 333 Seventh Avenue, 18th Floor, New York, NY 10001, USA

DOI https://doi.org/10.1055/s-0041-1741516.
ISSN 1089-7860.

This document was downloaded for personal use only. Unauthorized distribution is strictly prohibited.

complete range of motion (ROM) from full knee extension to flexion and some patients experienced residual instability after SBR, double-bundle reconstruction (DBR) was introduced, aiming to restore knee biomechanics and rotational stability closer to the native knee. However, because DBR is technically more demanding and did not show significant advantages over SBR on mid- and long-term follow-up, it is still not yet commonly established.[7,8] Thus, this article focuses on imaging of SBR.

Grafts

Ipsilateral knee autografts, such as bone-patellar tendon-bone (BPTB) and hamstring tendon (HT) grafts, are most frequently used for ACL reconstruction.[8–11] BPTB grafts consist of a 9- to 11-mm-wide stripe from the middle third of the patellar tendon with attached bone plugs harvested from the patellar and tibial tendon attachment. HT autografts typically consist of segments from the semitendinosus and/or gracilis tendon that are harvested from their tibial insertion to the myotendinous junction. Usually these tendon segments are folded, sutured together, and doubled over to create a four-stranded graft.

For the fixation of grafts in femoral and tibial drilling tunnels, metallic or bioabsorbable interference screws may be used with both BPTB and HT techniques (central fixation). Alternatively, the graft may be docked in a tunnel with extracortical button fixation (peripheral fixation). Hybrid techniques use a mixture of central and peripheral graft fixation (►**Fig. 1a**). Other fixation materials (e.g., surgical staples, cross pins) are less frequently used today. Awareness of different fixation options is crucial for evaluation of postoperative imaging, especially for depiction of potential complications, such as loss of fixation with interference screws or inadequate application or position of extracortical buttons.[2,12,13]

Tunnels

Accurate location of the femoral and tibial tunnels is critical for proper graft function. An anatomical position of the *femoral tunnel* aperture is important for graft isometry during full knee ROM.[8] The femoral tunnel opening was originally recommended to be placed as far posteriorly as possible at the intersection of a line along the posterior femoral cortex and the Blumensaat line. More recently, the quadrant method has been preferably used to determine the articular femoral tunnel aperture more anatomically with its optimal position at the anteroinferior corner of the superoposterior quadrant on lateral radiographs, three-dimensional CT, or sagittal MR images (►**Fig. 1b**).[14–17] On anteroposterior radiographs and coronal MR or CT images, the femoral tunnel opening should be positioned above the lateral femoral condyle at the 1 to 2 o'clock position in the left knee and the 10 to 11 o'clock position in the right knee.

On sagittal images, the *tibial tunnel* should open posterior to the intersection of the Blumensaat line with the tibia and adjacent to the anterior root attachment of the lateral meniscus (►**Fig. 1b**). In the coronal plane, it should be oriented at 65 to 70 degrees to a horizontal tangent to the tibial plateau and enter the joint at the intercondylar eminence with the lateral edge of the tunnel through the apex of the lateral intercondylar spine.[3]

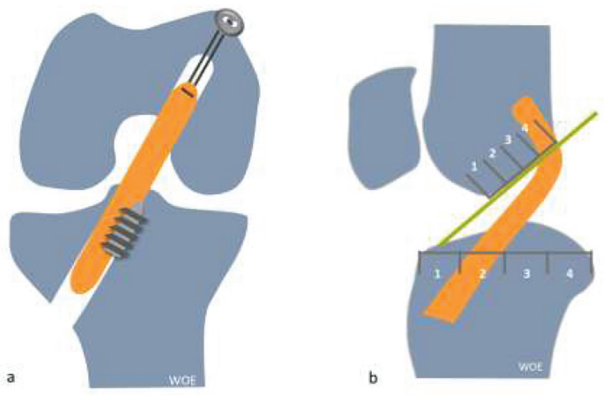

Fig.1 (**a**) Desired anterior cruciate ligament graft orientation and (**b**) tunnel position in the sagittal plane relative to the Blumensaat line and the quadrants of the intercondylar roof and tibial plateau.

Imaging after Anterior Cruciate Ligament Reconstruction

Imaging after cruciate ligament reconstruction is usually indicated in the setting of traumatic reinjury, atraumatic laxity, or other limitations of ROM. It routinely includes standard radiographs and MRI.[1–4,11,13,18,19] Radiographs allow for the assessment of potential fractures and for an overview on the reconstruction tunnels and fixation devices. Beyond that, MRI provides further specific information on tunnel location and complications as well as on the graft itself (e.g., intra-articular course, traumatic retear, degeneration, impingement). CT is best suited to evaluate tunnel enlargement and morphology.[20–22] Stress radiographs may be additionally obtained for an objective assessment of instability.

Normal Graft

Specific attention should be paid to the intra-articular course of the graft fibers and the tunnel positions because non-anatomical reconstruction remains the most common cause of graft failure.[15] ►**Fig. 2** shows the normal morphology and intra-articular course of a hamstring tendon autograft. Graft signal properties change with time in the postoperative period, typically displaying low signal from immediately after reconstruction up to 4 months. During revascularization and resynovialization (4–12 months), the graft may change to intermediate signal intensity on all pulse sequences. Typically, the graft signal intensity gradually returns to low after 12 months; however, signal changes due to normal graft maturation may persist up to 4 years and should not be interpreted as pathologic.[23] Hamstring grafts may display persistent linear areas of high T2-weighted signal intensity interposed between the folded tendon strands.

Abnormal Graft

Graft Tears

Graft tears may occur as a result of traumatic injury or chronic degeneration due to graft impingement. As in

 © 2022. Thieme. All rights reserved.

This document was downloaded for personal use only. Unauthorized distribution is strictly prohibited.

Fig. 2 Correct position and normal magnetic resonance morphology of anterior cruciate ligament graft (G) on sagittal intermediate-weighted turbo spin-echo image with fat suppression. Note artifact caused by metallic interference screw within tibial tunnel (asterisk).

injuries of the native ACL, graft rupture is diagnosed on the basis of discontinuity and/or abnormal orientation of graft fibers.[19]

In *complete graft tears*, MRI findings include absence of intact graft fibers or a fluid-filled defect, horizontal orientation of the graft, or resorption of graft fibers (►**Fig. 3a**). Secondary signs may consist of a pivot-shift–type bone marrow edema pattern (►**Fig. 3b**) and anterior tibial translation, although these signs are not entirely specific for graft tears because they may also be found in other instances of graft dysfunction.[2,19,23]

The diagnosis of *partial graft tears* may be challenging because several other causes of increased graft signal exist, such as revascularization, signal heterogeneity between individual bundles of hamstring grafts, mucoid degeneration, and focal changes related to graft impingement.[1,23]

Abnormal Intra-articular Course of the Graft

Graft Impingement

The most common type of ACL graft impingement is roof impingement. If the tibial tunnel is positioned too far anteriorly, roof impingement may occur as a result of early contact between the distal portion of the graft and the inferior portion of the intercondylar notch (intercondylar roof), particularly during complete knee extension. In this case, the graft commonly shows posterior bowing due to impingement against the roof of the notch, frequently accompanied by focal signal increase (distal two thirds) due to degenerative changes that may progress to chronic partial or complete graft tears (►**Fig. 4**). Impingement may also occur secondary to anterior tibial translation with anterior laxity in which also the tibial tunnel moves forward.[2,3] Less frequently, the tibial tunnel is placed too far laterally, leading to impingement of the graft on the lateral wall of the intercondylar fossa. Graft impingement may also be caused

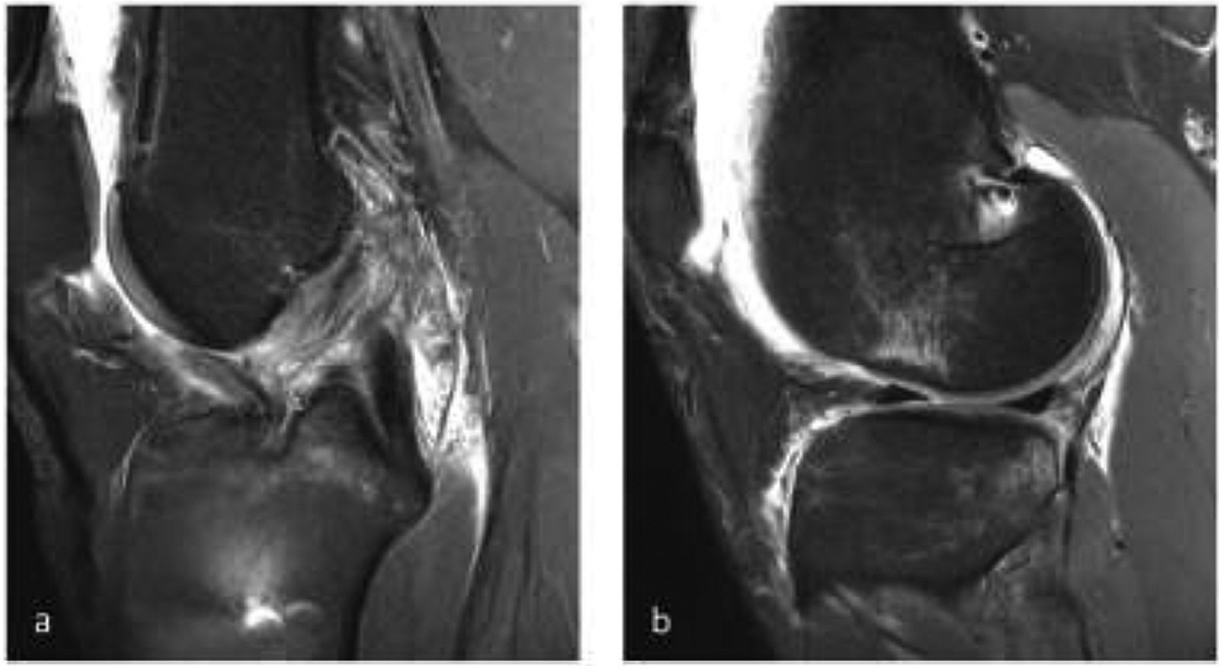

Fig. 3 Complete tear of an anterior cruciate ligament graft with a moderately posterior position of the tibial tunnel. Sagittal intermediate-weighted turbo spin-echo images with fat suppression. (**a**) Discontinuity of the graft and anterior displacement of its distal stump. The articular opening of the tibial tunnel is located posterior at the transition from the second to the third quadrant. (**b**) Bone bruises at the lateral femoral condyle and the posterior tibial plateau as indirect signs of acute graft tear.

 © 2022. Thieme. All rights reserved.

This document was downloaded for personal use only. Unauthorized distribution is strictly prohibited.

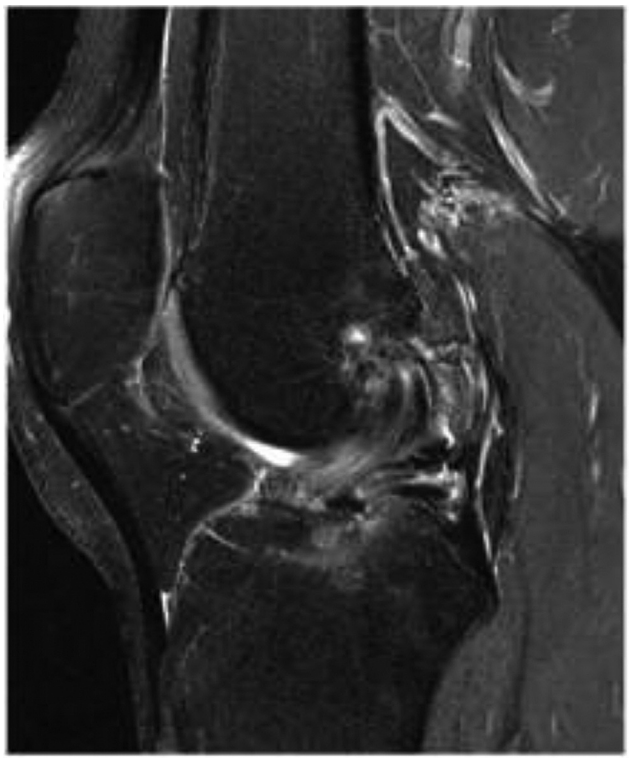

Fig. 4 Graft impingement. Sagittal intermediate-weighted turbo spin-echo image with fat suppression shows posterior bowing and increased signal intensity of the distal portion of a hamstring anterior cruciate ligament graft due to abnormal contact with the intercondylar roof.

or aggravated by osteophytes, a narrow intercondylar notch, or protruding interference screws.

Vertical Course of the Graft

A tibial tunnel placed too far posteriorly, particularly in combination with a more anteroproximal or central femoral tunnel aperture, results in a non-anatomical vertical orientation of the graft in both the sagittal and coronal planes. This misplacement commonly results in functional failure due to increased anterior tibial translation, residual pivot shift, and limited rotational stability (►**Fig. 5**).[24,25]

Other Complications

Tunnel Widening

Tunnel widening is a frequent phenomenon that predominantly occurs during the first 6 months after ACL reconstruction and stabilizes within 2 years.[26,27] It is defined as a progressive postoperative tunnel enlargement >2 mm on radiographs and mainly affects the tibial tunnel, particularly when hamstring autografts were used. CT is the most reliable tool to evaluate tunnel enlargement and morphology, whereas MRI was shown to be less reliable[20] (►**Fig. 6**). If revision surgery is considered in case of ACL graft failure, tunnel diameter should be determined by CT. If the diameter exceeds 15 mm, usually a two-stage procedure is performed with initial bone grafting to fill the tunnels, followed by revision surgery at least 3 months later.[22]

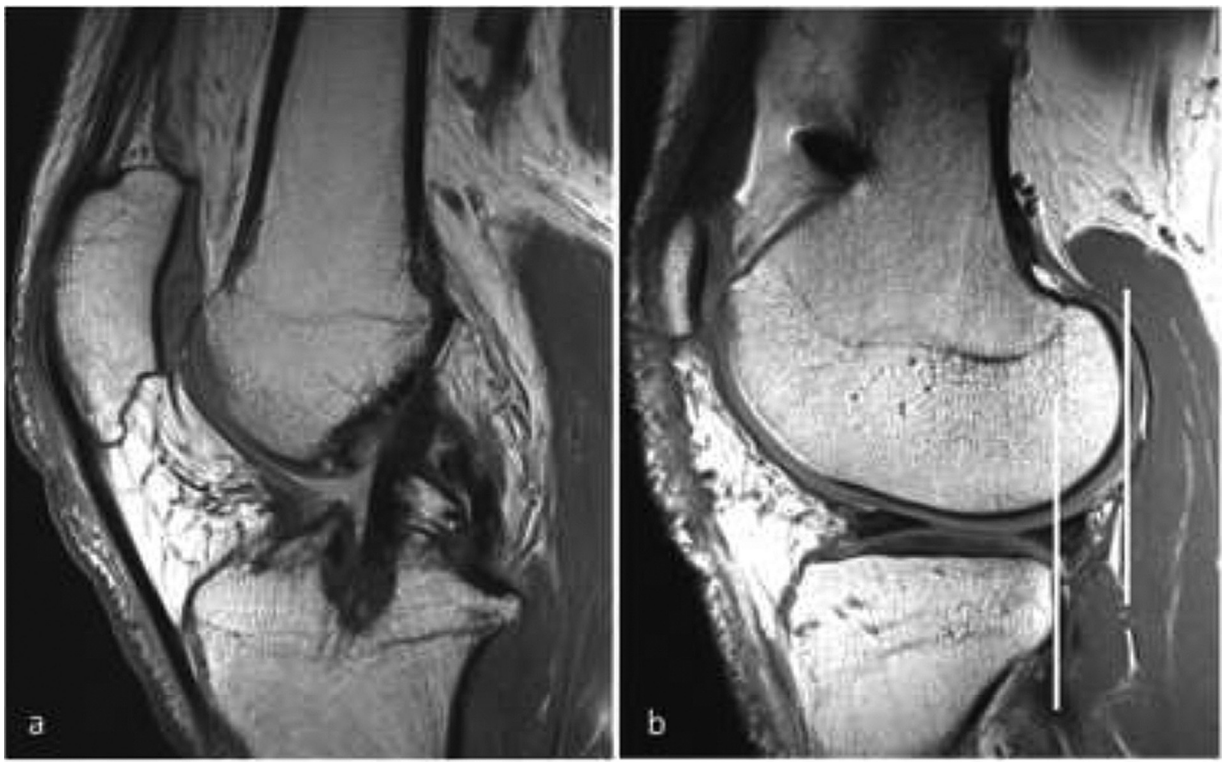

Fig. 5 Functional failure caused by vertical course of anterior cruciate ligament (ACL) graft. (**a**) Sagittal T1-weighted turbo spin-echo images with DRIVE pulse show vertical course of ACL graft due to a too far posterior position of the tibial tunnel. (**b**) Abnormal anterior tibial translation >5 mm corresponds to the clinical finding of knee instability.

 © 2022. Thieme. All rights reserved.

This document was downloaded for personal use only. Unauthorized distribution is strictly prohibited.

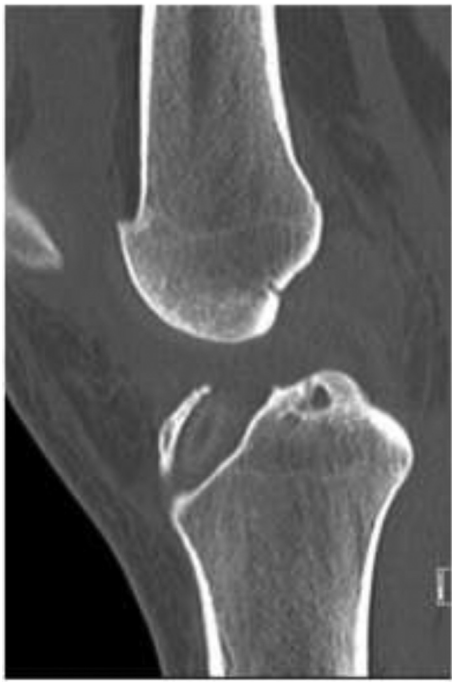

Fig. 6 Sagittal computed tomography reconstruction of exaggerated anterior position and moderately enlarged tibial tunnel after anterior graft cruciate ligament reconstruction with hamstring graft.

Fig. 7 Tunnel cyst. Sagittal intermediate-weighted turbo spin-echo image with fat suppression shows expansile cystic lesion within the tibial tunnel (arrow) on long-term follow-up after anterior cruciate ligament reconstruction with use of a hamstring graft. Note thickening and increased signal intensity of the entire graft due to mucoid degeneration.

Interestingly, there is no correlation between tunnel widening and graft failure. Little is known with respect to the etiology of tunnel widening. Various mechanical and biological causes are discussed, for example micro-motion due to non-anatomical graft fixation, suspensory fixation devices, BioScrew resorption and reaction, graft ganglia, and others.[9,22]

Tunnel Cysts

Small amounts of fluid within a tunnel can be a normal finding early after surgery and typically resolve within the first 18 months.[27] Cyst formation, predominantly within the tibial tunnel (►**Fig. 7**), is an uncommon and late complication of ACL reconstruction and may be an incidental finding or accompanied with clinical symptoms, such as pain, limited ROM, or, rarely, pretibial swelling when expanding into the anterior soft tissues over the tibial tunnel. The pathogenesis of tunnel cysts is unclear; they may result from mucoid degeneration of the graft, intravasation of joint fluid, foreign body reaction to bioabsorbable screw material, or incomplete graft integration within the tunnel.[21,27]

Hardware-related Complications

Metallic fixation devices may limit postoperative evaluation of MR images due to susceptibility artifacts (►**Fig. 2**). Bioabsorbable devices eliminate these artifact issues; however, interference screws, pins, EndoButtons, and other types of graft fixation materials can cause complications or even graft failure.

Biomaterials can generate foreign body inflammatory reactions that are usually mild. In more severe reactions, an intraosseous granuloma around the screw may develop and compromise the trabecular architecture, weakening the underlying bone with the risk of potential fractures.[28] Moreover, fixation materials can fragment (►**Fig. 8**), migrate into the joint space with subsequent impairment of articular structures such as cartilage, ligaments, or synovium, or outside the joint into the subcutaneous soft tissues where they can damage, for example, tendons, muscles, or even blood vessels or nerves.[12] Suspensory extracortical systems like EndoButtons can move inside the tunnel, causing reduction of graft tensioning. Iliotibial band friction syndrome was observed following hamstring graft fixation when pins migrate or break, resulting in contact and friction with the iliotibial band.[29]

Arthrofibrosis

Arthrofibrosis is a common complication of ACL reconstruction and refers to the presence of focal or diffuse scar tissue within and around the synovium in at least one joint compartment, frequently reducing knee ROM.

The *cyclops lesion* is a focal form of arthrofibrosis, named for its arthroscopic appearance resembling the eye of a cyclops. Its etiology is not entirely clear, but it is thought to develop as an inflammatory reaction around the distal stump of the native ACL. A cyclops lesion appears as an ovoid mass located anteriorly in the intercondylar notch and connected to the graft.[30] It is found in up to 10% of patients after ACL reconstruction, is mainly composed of fibrocartilaginous and granulation tissue, and may cause loss of terminal knee extension or a locking sensation. Most lesions, however, are

 © 2022. Thieme. All rights reserved.

This document was downloaded for personal use only. Unauthorized distribution is strictly prohibited.

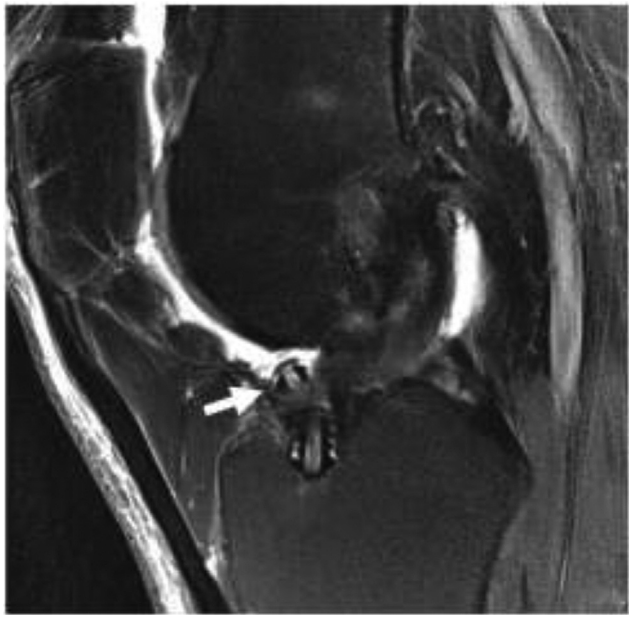

Fig. 8 Hardware failure. Sagittal intermediate-weighted turbo spin-echo image with fat suppression reveals fracture of a bioabsorbable interference screw used for anterior cruciate ligament graft fixation in the tibial tunnel. A fragment of the screw is dislocated into the anterior joint space (arrow). Breakage probably occurred due to misplacement of the screw protruding from the tibial tunnel.

not symptomatic. On MR images, cyclops lesions show hypointense to intermediate signal intensity (SI) on T1-weighted and variable signal on proton-density-weighted and T2-weighted images (►**Fig. 9**).

The *diffuse form of arthrofibrosis* is a result of inflammatory processes and may be seen as ill-defined areas of low to intermediate SI on T1-weighted and T2-weighted images surrounding the graft; it may extend anteriorly to the infrapatellar fat pad of Hoffa and the para-/suprapatellar recess or posteriorly between the ACL graft and the posterior cruciate ligament (PCL), and, rarely, the posterior joint capsule[2,30] (►**Fig. 10**). Diffuse arthrofibrosis is usually associated with significantly decreased knee mobility.

Infection

Postoperative joint infection is a rare complication (0.1–0.9%) of ACL reconstruction[2] and may be difficult to diagnose clinically because of the lack of classic symptoms of a septic joint, in particular with low-grade infections. Suggestive imaging signs of infection are appearances of synovitis, bony erosions, bone marrow edema, or even bone marrow replacement around the femoral and tibial tunnels, periarticular edema, fluid collections, or abscesses (►**Fig. 11**). However, the final diagnosis requires joint aspiration.[31]

Posterior Cruciate Ligament Reconstruction

The PCL is the strongest ligament in the knee, and injuries to the PCL occur significantly less commonly than injuries to the ACL. The treatment of isolated PCL tears includes both nonsurgical and surgical approaches with a preference for the nonsurgical option because most PCL injuries are partial-thickness tears that are adequately treated conservatively. Consequently, PCL reconstructions make up only 2 to 3% of cruciate ligament repairs.[32,33] In cases of nonsurgical treatment, MRI has lower accuracy in the evaluation of chronic PCL insufficiency because the signal and shape of the ligament can be deceptively restored through the healing

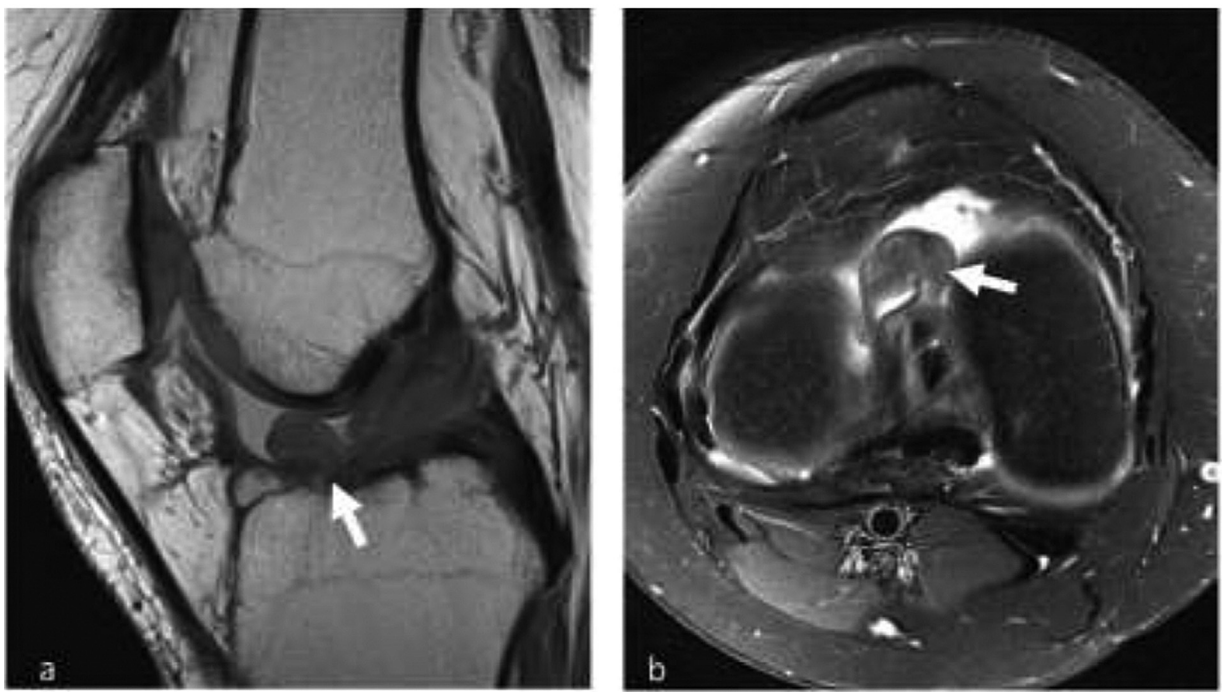

Fig. 9 Cyclops lesion. (**a**) Sagittal T1-weighted turbo spin-echo (TSE) image with DRIVE pulse and (**b**) axial intermediate-weighted TSE image with fat suppression show nodular soft tissue mass of intermediate to low signal intensity anterior to the anterior cruciate ligament (ACL) graft originating from the insertion site of the original ACL (arrows).

 © 2022. Thieme. All rights reserved.

This document was downloaded for personal use only. Unauthorized distribution is strictly prohibited.

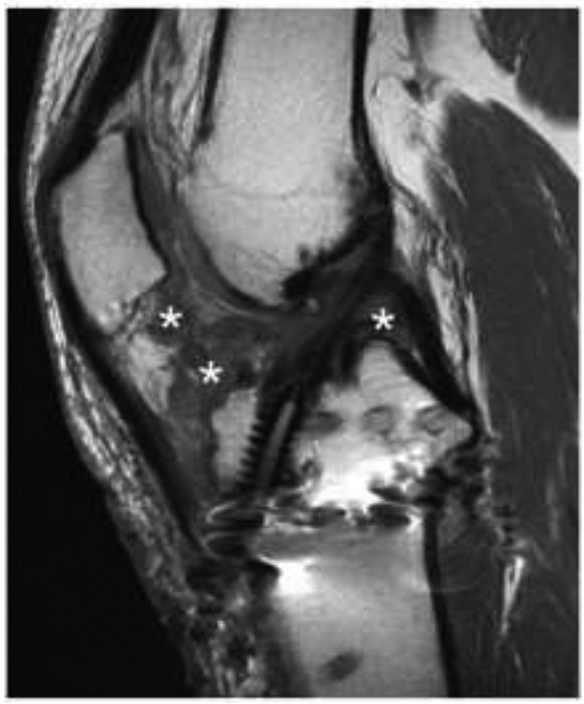

Fig. 10 Diffuse arthrofibrosis. Sagittal T1-weighted turbo spin-echo image with DRIVE pulse obtained after anterior cruciate ligament reconstruction and previous correction osteotomy of the tibia demonstrates scar tissue formation of low signal intensity extending from the graft to Hoffa's fat pad as well as to the posterior cruciate ligament (asterisks).

process despite the presence of residual laxity. Therefore, posterior tibial translation on stress radiography is an important objective measure of PCL laxity.

In PCL reconstruction, most commonly a single-bundle technique with one femoral and one tibial tunnel is used, but surgical variations also include tibial inlay and double-bundle techniques, and various types of grafts.

Imaging after Posterior Cruciate Ligament Reconstruction

After PCL reconstruction, radiographs are frequently obtained in the immediate postoperative period to assess the position of tunnels and fixation material. Postoperative MRI is not performed routinely but may be used as a baseline examination for the assessment of graft and tunnels and to rule out complications. The MR signal of the normal graft ideally should be low but can vary significantly depending on the type of graft, the fixation technique, and the time interval after surgery.[18,34,35] Similar to ACL reconstruction, a PCL tendon graft undergoes signal changes with maturation. During the revascularization phase (4 months to >1 year), high SI on images with T2 contrast may appear that should not be mistaken for partial tearing or signs of impingement, if fiber continuity is maintained. About 1 to 2 years after surgery, the graft should be hypointense on MR images of all pulse sequences.[34] Signal increase may, however, also occur with graft degeneration (►**Fig. 12**).

Complications

Residual laxity after PCL reconstruction is the most common complication and can have multiple causes. PCL graft tears following trauma or due to impingement can occur at any time after reconstruction with the most vulnerable period during revascularization, and direct MRI signs resemble those of ACL graft rupture. As an indirect sign of a torn graft, posterior tibial translation is frequently encountered and should be documented on stress radiographs.

Other complications include non-anatomical tunnel placement, tibial tunnel widening (►**Fig. 12**), pain caused by hardware, anterior knee pain, reduced motion caused by arthrofibrosis, and, rarely, infection. MRI is also valuable to diagnose concurrent meniscal, articular cartilage, and ligamentous injuries.

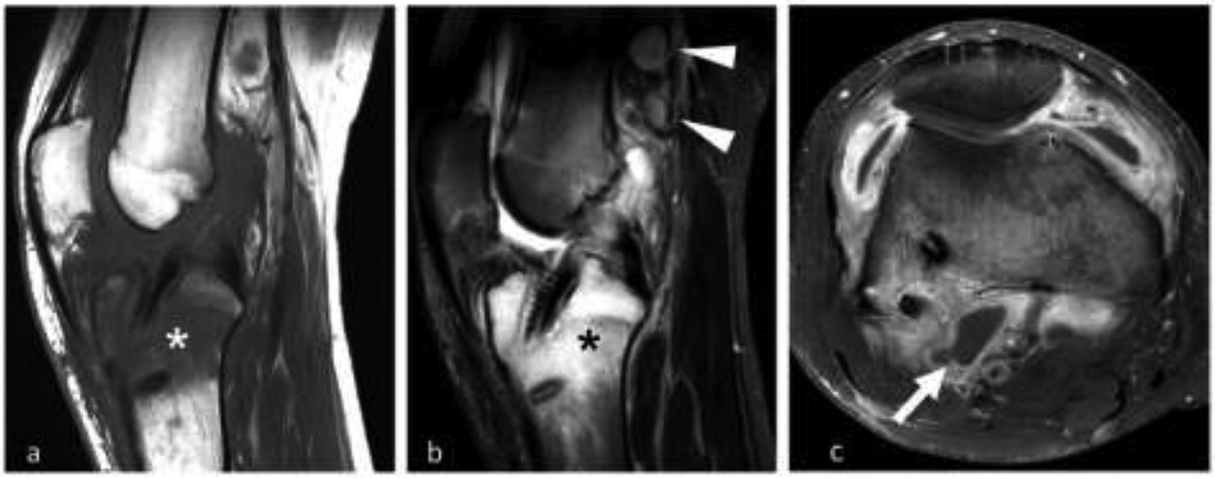

Fig. 11 Postoperative infection following anterior cruciate ligament (ACL) reconstruction. (**a**) Sagittal T1-weighted turbo spin-echo (TSE) image, (**b**) corresponding short tau inversion recovery image, and (**c**) axial contrast-enhanced T1-weighted TSE image with fat suppression show marked synovitis with synovial contrast enhancement and joint effusion, increased signal intensity of the intra-articular portion of the ACL graft, as well as abscess formation in the popliteal fossa (arrow). Bone marrow replacement indicative of osteomyelitis is seen in the proximal tibia (asterisks). Note enlargement of popliteal lymph nodes (arrowheads).

 © 2022. Thieme. All rights reserved.

This document was downloaded for personal use only. Unauthorized distribution is strictly prohibited.

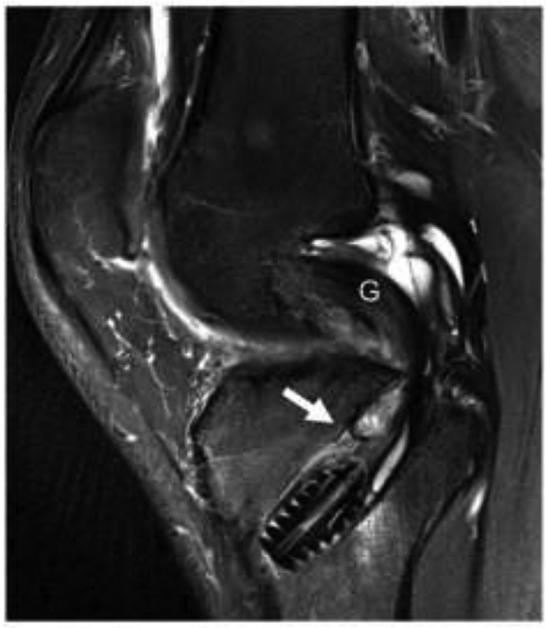

Fig. 12 Posterior cruciate ligament (PCL) reconstruction. Sagittal intermediate-weighted turbo spin-echo image with fat suppression shows moderate tibial tunnel widening (arrow) due to mucoid degeneration with otherwise intact PCL graft (G).

Menisci

The goal of meniscus surgery is to alleviate symptoms while maintaining or restoring meniscus function to prevent accelerated knee joint degeneration. Patients treated with surgery for a torn meniscus may have persistent or recurrent symptoms that require reevaluation, such as clinical examination, radiography, and MRI, to assess a potential intra-articular source of symptoms. For proper image interpretation, familiarity with the type and time of meniscal surgery, as well as current clinical symptoms, is crucial.

Techniques of Meniscal Surgery

Partial Meniscectomy

Partial meniscectomy (PM) has widely replaced total meniscectomy and is performed in degenerative meniscal tears and in non-reparable complex traumatic tears. In PM, torn and unstable parts of the meniscus are removed and as much stable meniscal tissue as possible is preserved.[36]

Meniscal Repair

Meniscal repair aims to restore meniscal morphology and to achieve healing of meniscal tears through the use of sutures. Longitudinal vertical tears in the vascularized area of the meniscus are the reference indication for suture repair.[36,37]

Meniscal Root Refixation

Posterior root tears are functionally equivalent to a total meniscectomy with loss of the meniscal resistance to withstand hoop stress and therefore are associated with a high risk of osteoarthritis. If the remaining tissue is adequate, meniscal root tears can be treated by tibial refixation using a transtibial tunnel.[38,39] Many root tears, however, are degenerative and cannot be repaired/ reconstructed.

Meniscal Transplantation

Meniscal allograft transplantation is commonly reserved for patients < 50 years of age who are not amenable to meniscal repair and have normal axial alignment.[40,41] For this procedure, most commonly a fresh or frozen cadaveric meniscus is used, attached by its anterior and posterior roots to a bone plug with a trapezoidal shape harvested from the donor tibia. The allograft bone plugs are inserted into matching tibial slots, and the periphery of the allograft meniscus is sutured to the joint capsule.

Imaging after Meniscal Surgery

MRI has excellent sensitivity and specificity ($\sim$ 90%) for primary meniscal tears; however, diagnostic performance is decreased following meniscal surgery because postoperative changes can mimic a recurrent or residual meniscus tear. Nevertheless, MRI is the preferred imaging modality for assessing patients with persistent or recurrent symptoms after meniscal surgery and may be performed conventionally or with an intra-articular contrast agent.[5,42–45]

Limitations in accuracy of conventional MRI have led to the introduction of direct magnetic resonance arthrography (MRA) to assess the postoperative meniscus. On MRA, due to imbibition of contrast material into a tear cleft, residual or recurrent tears can be diagnosed as areas of increased SI in the meniscus (similar to that of the intra-articular gadolinium contrast material), thereby allowing for better differentiation between tears, repair tissue, sutures, and degenerative changes.[46] In fact, MRA has revealed improved accuracy over conventional MRI in assessing the meniscus following $> 25\%$ resection and after meniscal repair, even if these improvements were not always statistically significant.[1,44,46]

CT arthrography is an alternative technique for patients with contraindications to MRI.[47]

After PM, variations in meniscal shape include diminution in the overall meniscus size or in the meniscal horns, blunting or irregularities of the central margin, and variable degrees of meniscal truncation (►**Fig. 13**). When the resected portion amounts for $< 25\%$ of meniscal tissue, the same diagnostic criteria used for native meniscus tears (i.e., linear intrasubstance increased signal extending to the articular surface, visualized on more than two images of 3 mm, either consecutively in the same orientation or in the same region in two different planes) can be applied to meniscus retears on conventional MRI and provide similar high accuracy.[1,46] Interestingly, retears after PM frequently present with a radial orientation.[44]

When $> 25\%$ of the meniscal substance has been resected or when meniscal repair has been performed, conventional MR criteria provide substantially lower accuracy (66–80%) because the margins of the meniscal remnant can be irregular, and abnormal linear SI on short TE images extending to the new articular surface can be seen not only in recurrent tears but also with preexisting mucoid degeneration and

 © 2022. Thieme. All rights reserved.

This document was downloaded for personal use only. Unauthorized distribution is strictly prohibited.

Fig. 13 Partial meniscectomy. (**a**) Four adjacent sagittal images and (**b**) axial image display diminished size and truncated central parts of the body and posterior horn of the lateral meniscus (arrowheads).

fibrovascular granulation or scar tissue, thus reducing the specificity of these findings considerably.

The absence of a line of increased signal through the meniscus extending to the articular surface on proton-density and T2-weighted images is a reliable MR finding for an untorn postoperative meniscus with 100% sensitivity.[5]

High specificity of a retorn meniscus, in contrast, is obtained when fluid-like high SI on T2-weighted images is extending into a meniscal cleft (92–96%) or when a displaced meniscal fragment is found (100%) (►**Fig. 14**). However, these signs are associated with limited sensitivity (40–66%) because not many retears display these features.[5,42]

More recently, Kijowski et al showed that high specificity (98%) and sensitivity (86%) can be achieved when a baseline MR examination, performed before the first arthroscopic surgery, is available for comparison and the actual SI pattern through the meniscus on intermediate-weighted or T2-weighted images has changed compared with the baseline study.[5] This observation emphasizes the importance of comparing pre- and postoperative MR images for evaluation of the postoperative meniscus.

On conventional MRI, specific signs of a retear following *meniscal repair* are essentially the same as those of a retorn meniscus after PM of > 25%. Increased signal intensity extending through the suture site on T2-weighted images, displaced meniscal fragments, and abnormal SI in a location distant from the site of repair indicate a retear (►**Fig. 14**). Although it has a lower accuracy than MRA in the evaluation of meniscal repair, conventional MRI is often used as the initial postoperative test to assess the knee for specific signs of a retear or for other internal derangement not involving the meniscus. However, hyperintense signal can persist in meniscal scars on conventional MR imaging (►**Fig. 15**) for a year or even longer and thus can lead to the false-positive diagnosis of a retear. Therefore, MRA should at least be considered for postoperative menisci with equivocal findings on conventional MR imaging because the presence of high gadolinium-like signal within the meniscus can allow for a more reliable detection or exclusion of a retear (►**Fig. 16**).

In general, a repaired meniscus can be considered as healed if there is no fluid or contrast signal in the suture area, partially healed if fluid or contrast signal extends into < 50% of the repair site, or not healed if the signal extends into > 50% of the repair site.

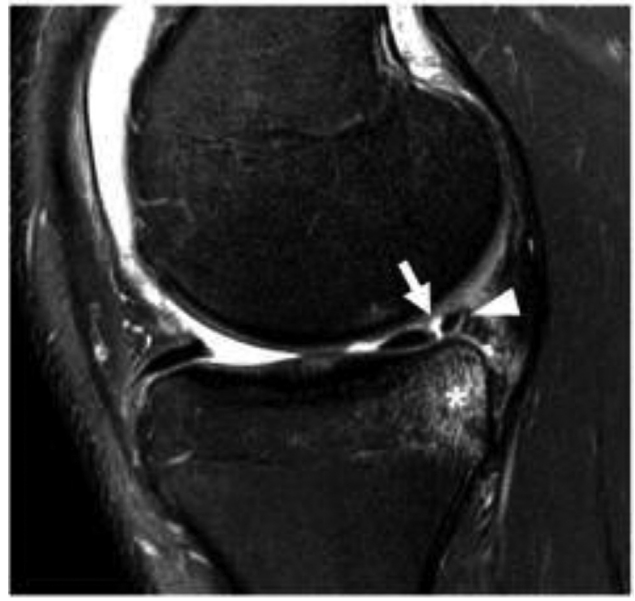

Fig. 14 Retear after meniscal repair. Sagittal intermediate-weighted turbo spin-echo image with fat suppression reveals vertical tear with fluid-like signal intensity and fragment displacement in the posterior horn of the medial meniscus (arrow). The meniscal scar following previous suture is seen posterior to the retear (arrowhead). Note reactive bone marrow edema in the posterior tibial plateau (asterisk).

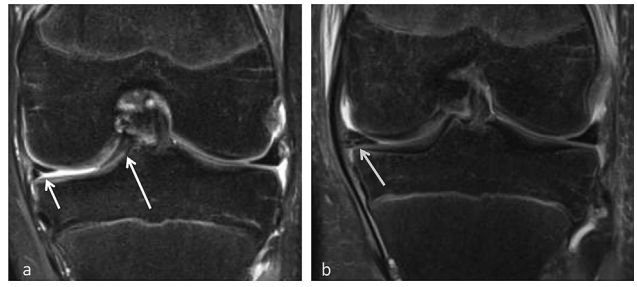

Fig. 15 Meniscal suture repair in a 16-year-old boy with a bucket-handle tear of the medial meniscus. Coronal intermediate-weighted turbo spin-echo images with fat suppression. (**a**) Bucket-handle tear of the medial meniscus with broad displaced fragment in the intercondylar notch (long arrow) and horizontal tear in the peripheral portion of the meniscus (short arrow). (**b**) Three months after reposition and suture repair: The bucket-handle fragment is in anatomical position, and there is moderately increased linear signal intensity through the suture area, not extending to the articular meniscal surface (arrow). This finding is consistent with reparative granulation tissue.

 © 2022. Thieme. All rights reserved.

This document was downloaded for personal use only. Unauthorized distribution is strictly prohibited.

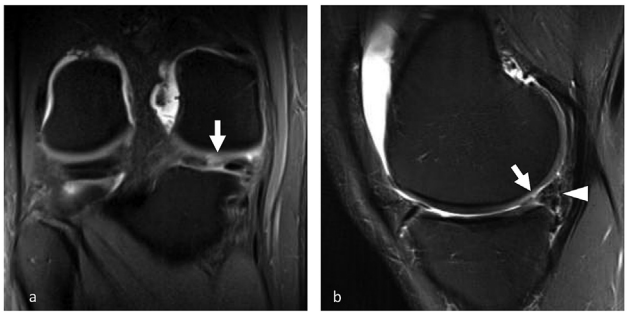

Fig. 16 Retear after meniscal repair. (**a**) Coronal and (**b**) sagittal T1-weighted magnetic resonance arthrograms with fat suppression show contrast media entering the anterior third of the posterior horn of the medial meniscus, indicating a new vertical tear (arrow). The suture area in the posterior two thirds appears intact (arrowhead).

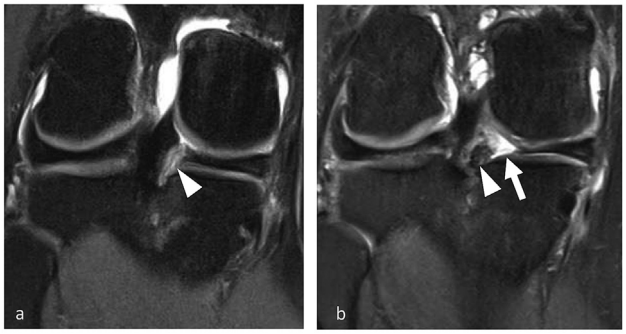

Fig. 17 Retear of the medial meniscus posterior horn 9 months following posterior meniscal root repair/ reconstruction. (**a**) Preoperative coronal intermediate-weighted image displays tear of the posterior root of the medial meniscus (arrowhead). (**b**) Nine months after repair/ reconstruction, the posterior root of the medial meniscus appears intact (arrowhead); however, a new tear occurred lateral to the root in the posterior horn (arrow).

Posterior *meniscal root repair* is being performed with increasing frequency and has been shown to have better outcomes and decreased risk of osteoarthritis compared with untreated posterior root tears. Because this is a relatively new procedure, few studies have been dedicated to MR evaluation of postoperative root repair. Conventional MRI is useful for evaluating posterior root morphology at the tibial tunnel fixation site, meniscal extrusion, and articular cartilage (►**Fig. 17**). Extrusion is commonly seen following root repair, and recent evidence suggests that decreased extrusion may correlate to better clinical outcomes.[48]

Following *meniscal transplantation* (►**Fig. 18**), the allograft may decrease in size or may extrude (78% on the medial side; 35% on the lateral side), but neither shrinkage nor extrusion is correlated with clinical outcomes.[40,45] Complications can occur in up to 21% of procedures with transplant failure by avulsion, bone plug incorporation, or bone bridge fracture.

In the detection of tears of the posterior and middle thirds of the meniscal allograft, conventional MRI provides high accuracy of 90 to 95% compared with arthroscopy, but the results for the anterior third were poor with a specificity of 35% and an accuracy of 45%. A frequent finding following meniscal transplantation is high-grade articular cartilage loss. Arthrofibrosis and synovitis are also relatively common.

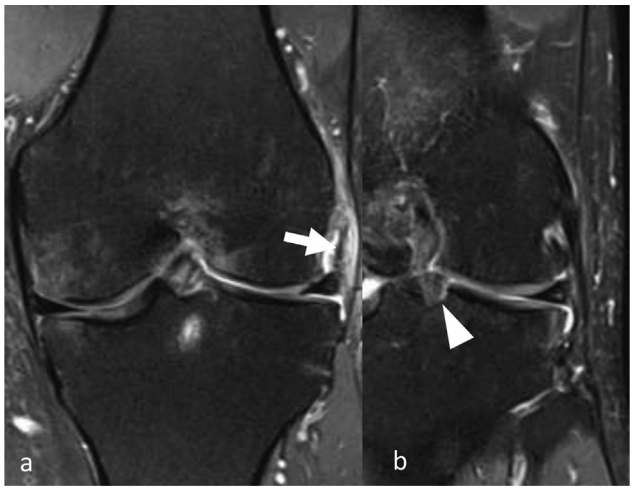

Fig. 18 A 39-year-old man with persistent lateral knee pain 5 months after lateral meniscus transplant. (**a**) The body of the intact lateral meniscus is mildly extruded. After suture of the allograft periphery to the joint capsule, there is thickening of the capsule (arrow) and reactive soft tissue edema between the capsule and the iliotibial band. In addition, moderate thinning of articular cartilage is seen. (**b**) At the tibial fixation site of the bone plug attached to the posterior meniscal root, moderately increased signal (arrowhead) indicates that healing is not yet fully completed.

Summary

Repair procedures of cruciate ligaments and menisci have increased in prevalence in the last decades, as have imaging studies of patients after such procedures. The mainstays of postoperative knee imaging are radiography and conventional MRI. Direct MRA may provide more accurate diagnostic information in the differentiation between residual or recurrent meniscal tears and degeneration or postoperative manifestations of healing. Multiplanar CT has a role in the evaluation of tunnel widening after cruciate ligament reconstruction, and CT arthrography can be an imaging alternative in patients with contraindications to MRI. It is important for the radiologist to understand the surgical repair techniques and to be able to recognize the normal MRI appearance of the knee after common repair procedures of cruciate ligaments and menisci, as well as complications associated with such procedures.

Conflict of Interest
Klaus Woertler reports support for attending meetings and/or travel from DGMSR Trainingskurs 2021 for reimbursement of travel expenses, and a leadership or fiduciary role in other board, society, committee, or advocacy groups, paid or unpaid from DGMSR and AG Knochentumoren.

References

1 White LM, Kramer J, Recht MP. MR imaging evaluation of the postoperative knee: ligaments, menisci, and articular cartilage. Skeletal Radiol 2005;34(08):431–452
2 Bencardino JT, Beltran J, Feldman MI, Rose DJ. MR imaging of complications of anterior cruciate ligament graft reconstruction. Radiographics 2009;29(07):2115–2126

 © 2022. Thieme. All rights reserved.

This document was downloaded for personal use only. Unauthorized distribution is strictly prohibited.

3 Meyers AB, Haims AH, Menn K, Moukaddam H. Imaging of anterior cruciate ligament repair and its complications. AJR Am J Roentgenol 2010;194(02):476–484
4 Grassi A, Bailey JR, Signorelli C, et al. Magnetic resonance imaging after anterior cruciate ligament reconstruction: a practical guide. World J Orthop 2016;7(10):638–649
5 Kijowski R, Rosas H, Williams A, Liu F. MRI characteristics of torn and untorn post-operative menisci. Skeletal Radiol 2017;46(10): 1353–1360
6 Meredick RB, Vance KJ, Appleby D, Lubowitz JH. Outcome of single-bundle versus double-bundle reconstruction of the anterior cruciate ligament: a meta-analysis. Am J Sports Med 2008;36 (07):1414–1421
7 Yang J, Fu S, Song Y. A prospective randomized controlled trial to evaluate clinico-radiological outcome of arthroscopic single bundle versus double bundle anterior cruciate ligament reconstruction. Int J Clin Exp Med 2017;10:1087–1093
8 Fineberg MS, Zarins B, Sherman OH. Practical considerations in anterior cruciate ligament replacement surgery. Arthroscopy 2000;16(07):715–724
9 Marrale J, Morrissey MC, Haddad FS. A literature review of autograft and allograft anterior cruciate ligament reconstruction. Knee Surg Sports Traumatol Arthrosc 2007;15(06):690–704
10 Reinhardt KR, Hetsroni I, Marx RG. Graft selection for anterior cruciate ligament reconstruction: a level I systematic review comparing failure rates and functional outcomes. Orthop Clin North Am 2010;41(02):249–262
11 Srinivasan R, Wan J, Allen CR, Steinbach LS. Knee imaging following anterior cruciate ligament reconstruction: the surgeon's and radiologist's perspectives. Semin Musculoskelet Radiol 2018;22 (04):386–397
12 Bush-Joseph CA, Bach BR Jr. Migration of femoral interference screw after anterior cruciate ligament reconstruction. Am J Knee Surg 1998;11(01):32–34
13 Geeslin AG, Geeslin MG, LaPrade RF. Ligamentous reconstruction of the knee: what orthopaedic surgeons want radiologists to know. Semin Musculoskelet Radiol 2017;21(02):75–88
14 Bernard M, Hertel P, Hornung H, Cierpinski T. Femoral insertion of the ACL. Radiographic quadrant method. Am J Knee Surg 1997;10 (01):14–21; discussion 21–22
15 Morgan JA, Dahm D, Levy B, Stuart MJMARS Study Group. Femoral tunnel malposition in ACL revision reconstruction. J Knee Surg 2012;25(05):361–368
16 Parkar AP, Adriaensen ME, Fischer-Bredenbeck C, et al. Measurements of tunnel placements after anterior cruciate ligament reconstruction—a comparison between CT, radiographs and MRI. Knee 2015;22(06):574–579
17 Dhawan A, Gallo RA, Lynch SA. Anatomic tunnel placement in anterior cruciate ligament reconstruction. J Am Acad Orthop Surg 2016;24(07):443–454
18 Sanders TG. MR imaging of postoperative ligaments of the knee. Semin Musculoskelet Radiol 2002;6(01):19–33
19 Collins MS, Unruh KP, Bond JR, Mandrekar JN. Magnetic resonance imaging of surgically confirmed anterior cruciate ligament graft disruption. Skeletal Radiol 2008;37(03):233–243
20 Marchant MH Jr, Willimon SC, Vinson E, Pietrobon R, Garrett WE, Higgins LD. Comparison of plain radiography, computed tomography, and magnetic resonance imaging in the evaluation of bone tunnel widening after anterior cruciate ligament reconstruction. Knee Surg Sports Traumatol Arthrosc 2010;18(08):1059–1064
21 Weber AE, Delos D, Oltean HN, et al. Tibial and femoral tunnel changes after ACL reconstruction: a prospective 2-year longitudinal MRI study. Am J Sports Med 2015;43(05):1147–1156
22 Rizer M, Foremny GB, Rush A III, et al. Anterior cruciate ligament reconstruction tunnel size: causes of tunnel enlargement and implications for single versus two-stage revision reconstruction. Skeletal Radiol 2017;46(02):161–169
23 Saupe N, White LM, Chiavaras MM, et al. Anterior cruciate ligament reconstruction grafts: MR imaging features at long-term follow-up–correlation with functional and clinical evaluation. Radiology 2008;249(02):581–590
24 Stevenson WW III, Johnson DL. "Vertical grafts": a common reason for functional failure after ACL reconstruction. Orthopedics 2007;30(03):206–209
25 DeFrate LE. Effects of ACL graft placement on in vivo knee function and cartilage thickness distributions. J Orthop Res 2017;35(06): 1160–1170
26 Fauno P, Kaalund S. Tunnel widening after hamstring anterior cruciate ligament reconstruction is influenced by the type of graft fixation used: a prospective randomized study. Arthroscopy 2005;21(11):1337–1341
27 Ghazikhanian V, Beltran J, Nikac V, Feldman M, Bencardino JT. Tibial tunnel and pretibial cysts following ACL graft reconstruction: MR imaging diagnosis. Skeletal Radiol 2012;41(11): 1375–1379
28 Konan S, Haddad FS. Femoral fracture following knee ligament reconstruction surgery due to an unpredictable complication of bioabsorbable screw fixation: a case report and review of literature. J Orthop Traumatol 2010;11(01):51–55
29 Pelfort X, Monllau JC, Puig L, Cáceres E. Iliotibial band friction syndrome after anterior cruciate ligament reconstruction using the transfix device: report of two cases and review of the literature. Knee Surg Sports Traumatol Arthrosc 2006;14(06): 586–589
30 Bradley DM, Bergman AG, Dillingham MF. MR imaging of cyclops lesions. AJR Am J Roentgenol 2000;174(03):719–726
31 Papakonstantinou O, Chung CB, Chanchairujira K, Resnick DL. Complications of anterior cruciate ligament reconstruction: MR imaging. Eur Radiol 2003;13(05):1106–1117
32 Owesen C, Sandven-Thrane S, Lind M, Forssblad M, Granan L-P, Årøen A. Epidemiology of surgically treated posterior cruciate ligament injuries in Scandinavia. Knee Surg Sports Traumatol Arthrosc 2017;25(08):2384–2391
33 Pache S, Aman ZS, Kennedy M, et al. Posterior cruciate ligament: current concepts review. Arch Bone Jt Surg 2018;6(01):8–18
34 Alcalá-Galiano A, Baeva M, Ismael M, Argüeso MJ. Imaging of posterior cruciate ligament (PCL) reconstruction: normal post-surgical appearance and complications. Skeletal Radiol 2014;43 (12):1659–1668
35 Sherman PM, Sanders TG, Morrison WB, Schweitzer ME, Leis HT, Nusser CA. MR imaging of the posterior cruciate ligament graft: initial experience in 15 patients with clinical correlation. Radiology 2001;221(01):191–198
36 Maak TG, Fabricant PD, Wickiewicz TL. Indications for meniscus repair. Clin Sports Med 2012;31(01):1–14
37 Hutchinson ID, Moran CJ, Potter HG, Warren RF, Rodeo SA. Restoration of the meniscus: form and function. Am J Sports Med 2014;42(04):987–998
38 Bhatia S, LaPrade CM, Ellman MB, LaPrade RF. Meniscal root tears: significance, diagnosis, and treatment. Am J Sports Med 2014;42 (12):3016–3030
39 LaPrade RF, Matheny LM, Moulton SG, James EW, Dean CS. Posterior meniscal root repairs: outcomes of an anatomic transtibial pull-out technique. Am J Sports Med 2017;45(04):884–891
40 Elattar M, Dhollander A, Verdonk R, Almqvist KF, Verdonk P. Twenty-six years of meniscal allograft transplantation: is it still experimental? A meta-analysis of 44 trials. Knee Surg Sports Traumatol Arthrosc 2011;19(02):147–157
41 Vundelinckx B, Vanlauwe J, Bellemans J. Long- term subjective, clinical, and radiographic outcome evaluation of meniscal allograft transplantation in the knee. Am J Sports Med 2014;42(07):1592–1599
42 Farley TE, Howell SM, Love KF, Wolfe RD, Neumann CH. Meniscal tears: MR and arthrographic findings after arthroscopic repair. Radiology 1991;180(02):517–522

 © 2022. Thieme. All rights reserved.

This document was downloaded for personal use only. Unauthorized distribution is strictly prohibited.

43 De Smet AA. MR imaging and MR arthrography for diagnosis of recurrent tears in the postoperative meniscus. Semin Musculoskelet Radiol 2005;9(02):116–124
44 Magee T. Accuracy of 3-Tesla MR and MR arthrography in diagnosis of meniscal retear in the post-operative knee. Skeletal Radiol 2014;43(08):1057–1064
45 Baker JC, Friedman MV, Rubin DA. Imaging the postoperative knee meniscus: an evidence-based review. AJR Am J Roentgenol 2018;211(03):519–527
46 White LM, Schweitzer ME, Weishaupt D, Kramer J, Davis A, Marks PH. Diagnosis of recurrent meniscal tears: prospective evaluation of conventional MR imaging, indirect MR arthrography, and direct MR arthrography. Radiology 2002;222(02):421–429
47 Mutschler C, Vande Berg BC, Lecouvet FE, et al. Postoperative meniscus: assessment at dual-detector row spiral CT arthrography of the knee. Radiology 2003;228(03):635–641
48 Chung KS, Ha JK, Ra HJ, Nam GW, Kim JG. Pullout fixation of posterior medial meniscus root tears: correlation between meniscus extrusion and midterm clinical results. Am J Sports Med 2017;45(01):42–49

This document was downloaded for personal use only. Unauthorized distribution is strictly prohibited.