



Musculocutaneous Latissimus Dorsi Phalloplasty

Marko Bencic¹ Borko Stojanovic¹ Marta Bizic¹ Miroslav L. Djordjevic¹

¹Belgrade Center for Urogenital Reconstructive Surgery, School of Medicine, University of Belgrade, Belgrade, Serbia

Address for correspondence Miroslav L. Djordjevic, MD, PhD, Department of Urology, School of Medicine, University of Belgrade, Tirsova 10, 11000 Belgrade, Serbia (e-mail: djordjevic@uromiros.com).

Indian J Plast Surg 2022;55:162–167.

Abstract

The treatment of gender dysphoria consists of psychiatric evaluation, initiation of hormonal therapy, and the final step in an individual's transition, performing gender-affirming surgery. Construction of the neophallus is one of the most demanding tasks in genital affirming surgery of transgender men. The main objectives of phalloplasty are to achieve a cosmetically acceptable and functional phallus, with a neourethra that allows voiding in standing position, sufficient length and strength for possible penetrative intercourse, preserved tactile and orgasmic sensation, and acceptable donor site morbidity. The musculocutaneous latissimus dorsi flap has reliable and suitable anatomy (good size, volume, and length of neurovascular pedicle) to meet the esthetic and functional requirements of neophallus reconstruction. Despite many advantages, the main disadvantage of this flap is the lack of sensitivity. Although the radial free forearm flap technique is the most commonly performed procedure, musculus latissimus dorsi flap is an acceptable choice in gender-affirming surgery.

Keywords

- ▶ transman
- ▶ phalloplasty
- ▶ latissimus dorsi flap
- ▶ urethroplasty

Introduction

The multidisciplinary approach in the treatment of gender dysphoria represents the gold standard in contemporary management. The approach to this condition consists of psychiatric evaluation, initiation of hormonal therapy and, as the final step in an individual's transition, performing genital gender affirmation surgery (GAS), according to the World Professional Association for Transgender Health (WPATH) standards of care.^{1,2} Prior to GAS, all patients need to have a complete psychiatric evaluation for further hormonal and surgical treatment and the appropriate documentation in line with the aforementioned standards of care.^{3,4} All patients have to undergo medically supervised hormonal treatments before surgical procedures can be initiated. Transgender men need to start with testosterone use to enlarge the clitoris, deepen the voice, and produce

facial and body hair. GAS includes chest reconstruction, removing internal female genitalia, and the creation of external male-like genitalia. Construction of the neophallus is one of the most demanding tasks in GAS of transmen.⁵ The main indications for neophallic reconstruction are gender dysphoria, disorder of sexual development, and congenital or acquired conditions, which result in partial or complete penile insufficiency.¹ The main objectives of phalloplasty are to achieve a cosmetically acceptable and functional phallus, with a neourethra that allows voiding in standing position, sufficient length and strength for possible penetrative intercourse, preserved tactile and orgasmic sensation, and acceptable donor site morbidity.^{5,6} Although there are various surgical techniques of neophallus creation, none of them represent an ideal solution for achieving an adequate final outcome. Therefore, patients' wishes regarding neophallus length and urinary and sexual function should be

published online
June 24, 2022

Issue Theme Gender
Incongruence

DOI <https://doi.org/10.1055/s-0041-1740382>.
ISSN 0970-0358.

© 2022. Association of Plastic Surgeons of India. All rights reserved. This is an open access article published by Thieme under the terms of the Creative Commons Attribution-NonDerivative-NonCommercial-License, permitting copying and reproduction so long as the original work is given appropriate credit. Contents may not be used for commercial purposes, or adapted, remixed, transformed or built upon. (<https://creativecommons.org/licenses/by-nc-nd/4.0/>)
Thieme Medical and Scientific Publishers Pvt. Ltd., A-12, 2nd Floor, Sector 2, Noida-201301 UP, India

considered when proposing a surgical approach, because an ideal procedure does not exist. Neophallic reconstruction relies on free-tissue flaps from different body sites or use of enlarged clitoral body to create a masculine neophallus, which allows for voiding while standing.⁶ Creation of an adult size neophallus has to be performed in several stages and represents one of the most difficult surgical challenges in genital reconstructive surgery. In this review article, we discuss the history of phalloplasty, the key elements of musculocutaneous latissimus dorsi (MLD) free flap phalloplasty, and thoughts on factors that, in our experience, lead to good outcomes.

Relevant Anatomy

The MLD flap can be raised as a muscle, musculocutaneous, osteomusculocutaneous, or even perforator flap. The fascia must also be taken when harvesting a musculocutaneous flap, because it nourishes the skin via perforators.^{7,8} The latissimus dorsi muscle has dual blood supply from the subscapular artery, and its branch thoracodorsal artery, and the posterior paraspinous perforators. Due to excellent interconnection between the double supply systems, if any of these two pedicles are interrupted, the muscle can still survive. Thoracodorsal artery is the dominant vessel supplying the MLD flap.⁹ Innervation of the latissimus dorsi is provided by the thoracodorsal nerve, which arises from the ventral rami of cervical nerve roots 6–8 in the posterior cord of the brachial plexus.⁷ The neurovascular hilum is located 8 to 9 cm from the axillary artery and courses 1.5 to 3.0 cm from the anterior edge of the muscle.⁹

Operative Technique

MLD phalloplasty is performed in several stages. Preoperatively, the donor, nondominant, site region has to be treated by massage to improve local skin elasticity, in order to allow primary closure.¹⁰ The first surgery consists of: removal of internal female genitalia, creation of a neophallus using latissimus dorsi-free flap with microvascular anastomosis, clitoral lengthening and incorporation into the neophallus, urethral reconstruction using vaginal and labia minora flaps, as well as insertion of testicle implants of appropriate size into the neoscrotum, created from labia majora.¹¹ Internal female genitalia can be removed by transvaginal or laparoscopic approach.⁶ Reconstruction of the neourethra begins with the reconstruction of its fixed part. A vaginal flap is harvested from the anterior vaginal wall, with its base close to the female urethral meatus.⁵ This flap is joined with the remaining part of the divided urethral plate, forming the fixed part of the neourethra in cases with well-developed and wide urethral plate. Further urethral reconstruction includes using all available vascularized hairless tissue to lengthen the neourethra to the maximum extent, preventing postoperative complications. The inner surface of both labia minora and clitoral skin are dissected to create a flap with appropriate dimensions, without detachment from the outer labial surface. This allows for excellent vascularization of the

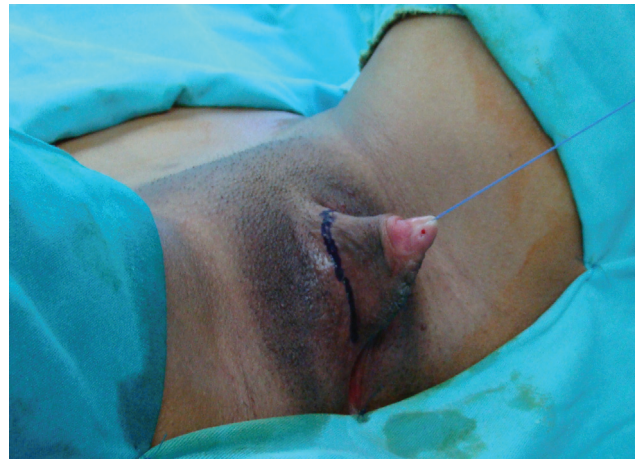

Fig. 1 Preoperative appearance of female genitalia. Incision line is marked.

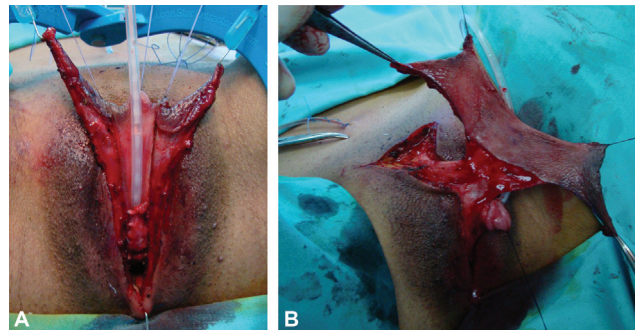


Fig. 2 Harvesting of vascularized flaps for urethral lengthening. (A). Bulbar neourethra (“pars fixa”) is created by joining of urethral plate and vaginal flap. Both labia minora are mobilized. (B). Long hairless skin flap is harvested from both labia minora and dorsal clitoral skin on abundant vascular pedicle. Labia minora and clitoral skin flaps are harvested with wide pedicle that provides excellent vascularization.

flap (→Figs. 1, 2). Flaps are joined to create a tube and lengthen the urethra from its bulbar part. The urethra is lengthened further using available clitoral skin. A “Y” incision is made in the infrapubic area above the clitoris for later fixation of the neophallus (→Fig. 3). After that, an inguinal incision is made to identify, dissect, and mobilize femoral artery, saphenous vein and ilioinguinal nerve.

The patient is placed in the lateral decubitus position using “beanbags,” with the upper torso placed in a full lateral position at 90° and the pelvis tilted at 30°, to provide access to the groin, allowing simultaneous flap harvesting and recipient-site preparation.⁹ Flap planning begins with marking the anterior and superior muscle border. The flap dimensions are planned to match the “normal” penile size in adults: 11 to 15 cm wide and 13 to 18 cm long (→Fig. 4). The glans is designed over the distal 5 cm of the flap; a 1 cm-wide skin strip between the future glans and penile shaft is deepithelialized to imitate the coronal sulcus.⁹

Flap elevation starts with an incision into the anterior skin margin, down to the deep fascia, and the plane is developed between the MLD and serratus anterior muscle, using sharp and blunt dissection. The flap is divided inferiorly and medially, cauterizing the large posterior perforators of the

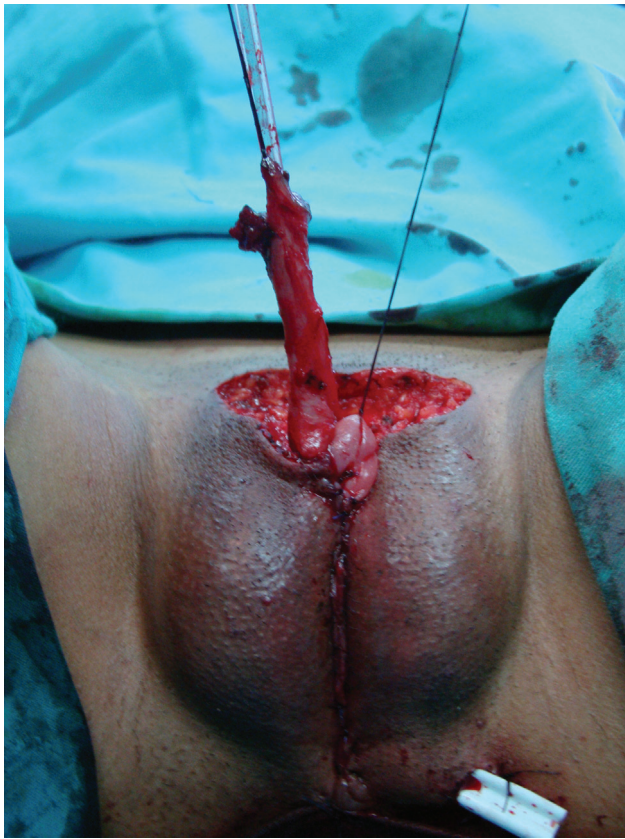

Fig. 3 A very long, well-vascularized neourethra is created by tubularization of the flaps over a silicone catheter. Labia majora are joined to create the scrotum, and testicular prostheses are implanted. A space above the clitoris is created for later fixation of the neophallus.

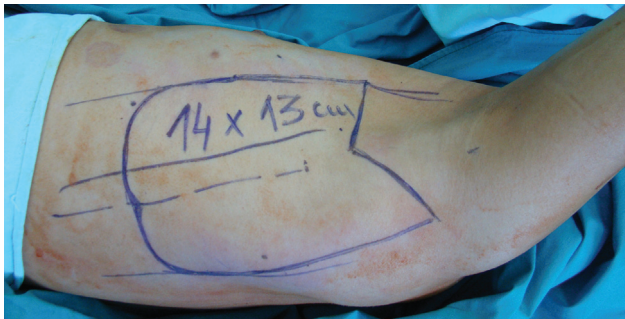


Fig. 4 Design of the appropriately sized and shaped latissimus dorsi flap.

intercostal vessels, and then lifted to expose the neurovascular pedicle. Only a small strip of muscle around the blood vessels is isolated, to decrease flap bulkiness and allow its safe tubularization.¹² All major branches are identified and carefully ligated; smaller vessels are cauterized. During dissection, care should be taken to avoid injury of the long thoracic nerve, which can cause “winging” of the scapula. The neophallus is created while the flap is still perfusing on its vascular pedicle by tubularizing the flap. The fully constructed neophallus is detached from the axilla after clamping and dividing the subscapular artery and vein, to achieve maximal pedicle length (►Fig. 5). The donor site defect is commonly closed by direct approximation; if direct approx-

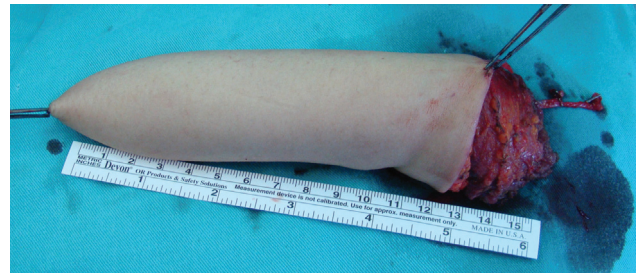

Fig. 5 A 15-cm-long neophallus is created by tubularization and detachment of the flap with its vascular pedicle.

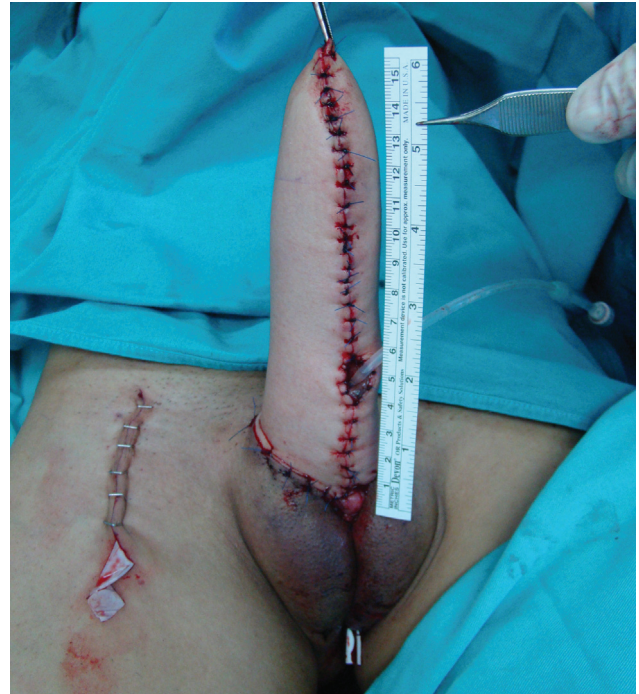

Fig. 6 Final outcome. Neophallus is fixed in the anatomically appropriate position. Clitoral glans is placed at the base of the neophallus, and urethral opening is positioned in the proximal third of the neophallus.

imation is not possible due to local anatomy, grafting with a split-thickness skin graft (STSG) is recommended.¹² The neophallus is transferred to the recipient area and microsurgical anastomoses are created between the thoracodorsal and femoral artery (end-to-side), and between the thoracodorsal and saphenous vein (end-to-end). Flap viability is assessed by clinical examination (i.e., skin color, local temperature, and capillary refill). After that, the clitoris is incorporated into the neophallus.⁶ Subsequently, using blunt and sharp dissection, a subcutaneous tunnel is created through the neophallus to insert the neourethra into the new urethral opening, which is commonly placed in the proximal part of neophallus, minimizing the requests for longer neophallic urethroplasty (►Fig. 6). All patients have suprapubic urine derivation catheter placed for a period of 3 weeks, followed by a urinary Foley catheter 12–14Ch for 2 weeks.⁶ Postoperative assessment of neophallic viability is performed by clinical examination (i.e., skin color, local

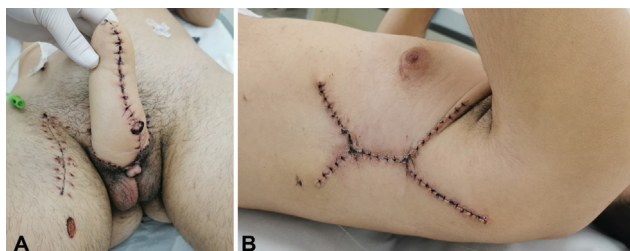


Fig. 7 Outcome 3 weeks after surgery. (A). Appearance of the neophallus, scrotum and anastomotic region. (B). Result after closure of donor area with direct approximation.

temperature, firmness, and capillary refill), and vascular patency is monitored by pocket Doppler device.¹² A special dressing is used to keep the graft in an elevated position, preventing pedicle kinking (►Figs. 7A, B).

The second stage, 6 to 9 months after the first one, includes further urethroplasty and insertion of penile prosthesis. To create the remaining part of neophallic urethra, we use oral mucosa grafts (either pairs or single, depending on the required width and length of the neourethra). Oral mucosa was harvested either from cheek or lower lip. Total dimension of buccal mucosa graft was measured during the surgery and ranged from 2 to 6 cm in length and 1.4 to 2.2 cm in width. When the healed grafts are ready for final stage tubularization and closure, it is important to incise the underlying tissue that will support the neourethra and avoid ischemia at the neourethral suture line. It is recommended to create a second layer from surrounding tissue, to cover and support the newly created urethra.¹¹ Glans contouring is commonly done by Norfolk technique in the second stage.¹² Insertion of penile prosthesis, either inflatable or semirigid, is performed by infrapubic (dorsal) or penoscrotal (ventral) approach (►Fig. 8). Lower part of the prosthesis cylinder is fixed to the pubic symphysis or pubic bone periosteum. In case of three-piece inflatable prosthesis, a pump is inserted in the appropriate neoscrotum, while the reservoir is inserted paravesically. In patients who requested clitoral covering, the glans is deepithelialized and covered with the surrounding skin at the phallic base at the same stage.

Recent Advances

Bogoras was the first who described phalloplasty in 1936.¹³ Many different phalloplasty techniques were described since none of them are ideal, and complications are common. Different surgical techniques for phalloplasty are available and each of them has its advantages and disadvantages. The most commonly used and described flaps are the radial forearm flap, the anterolateral thigh flap, and the abdominal flap.^{14,15} The MLD flap, first described by Baudet, has reliable and suitable anatomy (good size, volume, and length of neurovascular pedicle) to meet the esthetic and functional requirements of neophallic reconstruction.¹⁶ This is our method of choice, and we have published our first results with this technique in phallic reconstruction in boys with epispadias, micropenis, and intersex disorders.¹⁷ Since Chang and Hwang described their results for phalloplasty



Fig. 8 Result after second stage. Glans reconstruction and implantation of semirigid penile prosthesis are performed.

in cases after penile trauma or malignancy, radial forearm-free flap has become the most commonly used flap for phalloplasty worldwide.¹⁴ This technique yields a sensate neophallus with complete urethral lengthening at the same stage. However, drawbacks of this technique include the small size and circumference of the neophallus, as well as visible donor site scar that is considered stigmatizing for transgender men. Small volume of the neophallus sometimes presents a limitation for insertion of two penile prosthesis cylinders. The most common complications in radial forearm flap phalloplasty are related to urethroplasty. The Ghent group reported that 126 of 316 transgender men (40%) had urethral reconstruction complications. The authors reported implantation of an erectile prosthesis in 143 patients, with a complication rate of 41% requiring surgical revision.¹⁸ In another study, Garaffa et al reported results of one-stage phalloplasty with urethral reconstruction in 115 patients, out of which 112 were satisfied with the postoperative results and 99 reported good sensation of the neophallus.¹⁹

Even though there are many options for phalloplasty in transgender patients, the MLD flap technique is the preferred method in our center. This flap represents an acceptable choice for transgender men, giving an excellent volume of the neophallus and enabling feasible urethral reconstruction and full penile prosthesis implantation. Moreover, the phallus can be constructed to the size desired by the patient. Neophallus retraction seems less likely with muscle-based grafts than with fasciocutaneous forearm flaps, since well-vascularized muscle is less prone to contraction than connective tissue.¹² Another important advantage of the latissimus dorsi flap is the acceptable scar of the donor site, in

contrast to the stigmatizing visible scar left by the forearm flap phalloplasty.

Urethral reconstruction, which can sometimes lead to postoperative complications, is a multistage procedure and the most difficult part of phalloplasty.^{20–22} Urethral lengthening is usually performed simultaneously with phalloplasty, using all hairless vascularized genital flaps. Thus formed, the new urethra is insufficient to reach the tip of the neophallus, and additional neophallic urethroplasty is requested later. However, the new urethral opening, located either at the base or in the proximal half of the neophallus, is always sufficient to enable voiding in standing position.

Good results were obtained in the majority of the patients in all surgical aspects, appearance and size of the neophallus, voiding function, and erectile function with penile implants. However, there are disadvantages as well, including lack of tactile sensation of the neophallus and a significant rate of urethral complications that require surgical revision.^{22,23} Despite the fact that an anastomosis between the thoracodorsal (motoric) and the ilioinguinal (primarily sensory with some motor fibers) nerve was performed as a standard part of the phalloplasty, the neophallus still showed poor sensitivity, restricted to the clitoris incorporated at the base of the neophallus. Finally, all patients reported a good sensation of the glans clitoris, either with or without its covering.¹² This is achieved due to the complete preservation of the neurovascular bundle of the clitoris during its dissection in the first stage of phalloplasty.

Authors' Personal Experience

In the period since the first total MLD phalloplasty was performed in our center in 2007, 160 transgender men underwent GAS using the MLD flap until 2020. The follow-up period ranged from 6 to 152 months (mean 52 months). The average size of the neophallus was 15.2 cm (ranging from 11 to 21 cm) and 12.4 cm (ranging from 12 to 15 cm) in length and girth, respectively (►Fig. 7). In the early postoperative period, one partial and two total flap necrosis occurred. In two patients with total necrosis due to vein thrombosis, new phalloplasty with anterolateral thigh flap was performed in one case, while in the other, the MLD flap from opposite side was used; both procedures achieved successful final outcomes. In all remaining cases, the flap survived and good vascularization of the neophallus was confirmed by physical and Doppler examination. There was slight muscle atrophy which did not affect neophallic dimensions. There were no complaints of neophallic reduction in length during this follow-up period. Direct approximation for donor site closure was performed in 120 patients, while STSGs were used in the remaining cases (►Fig. 8). There were no complications related to internal genitalia removal in patients who had this surgery in the same stage as MLD phalloplasty. Total length of the reconstructed urethra, using all vascularized genital flaps in the first stage, was measured during the surgery and ranged from 13.4 to 21.7 cm (mean 16.4 cm). In all cases, the urethra was incorporated into the neophallus, either at the base or further along distally. The furthest

position achieved was in the middle third of the neophallus. Urethral caliber after all stages of urethral reconstruction is 14Ch.

Majority of patients (147), including some cases with urethral opening at the neophallic base, reported possibility of voiding while standing. We observed fistulas in 10 cases and strictures in 4 cases, which were repaired by minor surgery. Neophallic urethroplasty with staged oral mucosa graft tubularization was performed in 95 cases. Fistulas occurred in 30 patients and healed spontaneously in 10 patients, while the remaining patients required minor surgery to resolve the issue. Insertion of penile prosthesis was performed in 82 cases, 53 patients requested malleable, and the remaining inflatable penile prosthesis. Implant rejection due to infection and skin perforation occurred in six cases. Inflatable three-piece prostheses were replaced in three cases due to malfunctioning. Penetrative sexual intercourse without penile prosthesis implantation was reported in 17 cases. All patients were evaluated by either a psychiatrist or a psychologist and reported being satisfied with their surgery. According to patients' self-reports, except for those patients with postoperative flap necrosis, the majority were pleased with the aesthetic appearance of their male genitalia (123 "completely satisfied," 37 "somewhat satisfied"). Erogenous sensation based on clitoral stimulation was reported by all, while only 23 patients confirmed tactile sensation of the neophallus, based on sensitivity of clitoris and neourethra which were incorporated into it. Sexual intercourse with complete penetration was feasible in all patients with penile prosthesis.

Summary

Total phalloplasty in transgender men represents a great challenge. Despite the fact that the radial free forearm flap technique is the most commonly performed procedure, MLD flap is an acceptable choice in GAS. Possibilities for vaginal penetration, preserved erogenous sensibility, voiding while standing, and acceptable donor site morbidity are the main advantages for a successful outcome. The main advantage of this flap is its large surface area, allowing for an excellent penile size (length and circumference), large enough to allow urethroplasty and implantation of a penile prosthesis. Moreover, the neophallus can be constructed to the size desired by the patient. Neophallus retraction seems less likely with muscle-based grafts than with fasciocutaneous forearm flaps, since well-vascularized muscle is less prone to contraction than connective tissue. Sensitivity of neophallus is often limited in MLD phalloplasty, but the urethra, created from the labia minora, enables satisfactory sensitivity of the proximal part of neophallus. The sexual function of this neophallus remains problematic, as the flap lacks orgasmic sensitivity; it is restricted to the clitoral glans, with its preserved dorsal nerve bundle, incorporated at the base of the neophallus. Strong motivation and excellent cooperation of the partner are necessary for successful sexual intercourse. MLD phalloplasty is a feasible technique in transmen who have already had some GAS as well as in regret patients with gender dysphoria.

Funding

This work is supported by the Ministry of Science and Technical Development, Republic of Serbia, Project No. 175048.

Conflict of Interest

There are no conflicts of interest to declare.

References

- 1 Monstrey S, Houtmeyers P, Lumen N, Hoebeke P. Radial forearm flap phalloplasty. In: Djordjevic M, Santuci R, eds. *Penile Reconstructive Surgery*. LAP Lambert Academic Publishing, Saarbrücken; 2012:254–278
- 2 Coleman E, Bockting W, Botzer M, et al. 7th version of WPATH standards of care. *Int J Transgenderism* 2011;13:165–232
- 3 Gorton RN, Erickson-Schroth L. Hormonal and surgical treatment options for transgender men (female-to-male). *Psychiatr Clin North Am* 2017;40(01):79–97
- 4 Guerrero-Fernández J, Azcona San Julián C, Barreiro Conde J, et al. [Management guidelines for disorders/different sex development (DSD)]. *An Pediatr (Engl Ed)* 2018;89(05):315.e1–315.e19
- 5 Perovic SV, Djordjevic ML. Metoidioplasty: a variant of phalloplasty in female transsexuals. *BJU Int* 2003;92(09):981–985
- 6 Jun MS, Pušica S, Kojovic V, et al. Total phalloplasty with latissimus dorsi musculocutaneous flap in female-to-male transgender surgery. *Urology* 2018;120:269–270
- 7 Germann G, Öhlbauer M. Latissimus dorsi flap. In: Wei F, Mardini S, eds. *Flaps and Reconstructive Surgery*. 3rd ed. Philadelphia, PA: WB Saunders; 2009:287–303
- 8 Dennis M, Granger A, Ortiz A, Terrell M, Loukos M, Schober J. The anatomy of the musculocutaneous latissimus dorsi flap for neophalloplasty. *Clin Anat* 2018;31(02):152–159
- 9 Perovic SV, Djinovic R, Bumbasirevic M, Djordjevic M, Vukovic P. Total phalloplasty using a musculocutaneous latissimus dorsi flap. *BJU Int* 2007;100(04):899–905, discussion 905
- 10 Djordjevic ML, Bumbasirevic MZ, Vukovic PM, Sansalone S, Perovic SV. Musculocutaneous latissimus dorsi free transfer flap for total phalloplasty in children. *J Pediatr Urol* 2006;2(04):333–339
- 11 Bizic MR, Stojanovic B, Djordjevic ML. Genital reconstruction for the transgendered individual. *J Pediatr Urol* 2017;13(05):446–452
- 12 Djordjevic ML, Bencic M, Kojovic V, et al. Musculocutaneous latissimus dorsi flap for phalloplasty in female to male gender affirmation surgery. *World J Urol* 2019;37(04):631–637
- 13 Bogoraz N. Plastic construction of penis capable of accomplishing coitus. *Zentralbl Chir* 1936;63:1271–1276
- 14 Chang TS, Hwang WY. Forearm flap in one-stage reconstruction of the penis. *Plast Reconstr Surg* 1984;74(02):251–258
- 15 Monstrey S, Hoebeke P, Selvaggi G, et al. Penile reconstruction: is the radial forearm flap really the standard technique? *Plast Reconstr Surg* 2009;124(02):510–518
- 16 Djordjevic ML, Bumbasirevic MZ, Krstic Z, et al. Severe penile injuries in children and adolescents: reconstruction modalities and outcomes. *Urology* 2014;83(02):465–470
- 17 Djordjevic ML, Bizic MR, Duisin D, Bouman MB, Buncamper M. Reversal surgery in regretful male-to-female transsexuals after sex reassignment surgery. *J Sex Med* 2016;13(06):1000–1007
- 18 Doornaert M, Hoebeke P, Ceulemans P, T'Sjoen G, Heylens G, Monstrey S. Penile reconstruction with the radial forearm flap: an update. *Handchir Mikrochir Plast Chir* 2011;43(04):208–214
- 19 Garaffa G, Ralph DJ. Free flap phalloplasty for female to male gender dysphoria. *J Sex Med* 2016;13(12):1942–1947
- 20 Felici N, Felici A. A new phalloplasty technique: the free antero-lateral thigh flap phalloplasty. *J Plast Reconstr Aesthet Surg* 2006;59(02):153–157
- 21 Bettocchi C, Ralph DJ, Pryor JP. Pedicled pubic phalloplasty in females with gender dysphoria. *BJU Int* 2005;95(01):120–124
- 22 Rashid M, Tamimy MS. Phalloplasty: the dream and the reality. *Indian J Plast Surg* 2013;46(02):283–293
- 23 Hage JJ, Bouman FG, de Graaf FH, Bloem JJ. Construction of the neophallus in female-to-male transsexuals: the Amsterdam experience. *J Urol* 1993;149(06):1463–1468