Article published online: 2022-01-28

Abducens Nerve Schwannoma: Case Report and Literature Review

Schwannoma do nervo abducente: Relato de caso e revisão da literatura

Guilherme Finger[1] Bruno Loyola Godoy[1] Bruna Koeche da Silva[2] Rafael de Mello[3] Janio Nogueira[3] Antonio Aversa do Souto[1]

[1] Department of Neurosurgery, Instituto Nacional do Câncer, Rio de Janeiro, RJ, Brazil
[2] Department of Neurosurgery, Hospital Geral de Cuiabá, Cuiaba, MG, Brazil
[3] Deparment of Neurosurgery, Hospital Samaritano, Rio de Janeiro, RJ, Brazil

Address for correspondence Guilherme Finger, MD, 255 Eugenio du Pasquier, 91040-000, Brazil (e-mail: guilhermefingermd@gmail.com).

Arq Bras Neurocir 2022;41(2):e207–e211.

Abstract

The authors describe a rare case of abducens nerve schwannoma, manifested with headache and diplopia, associated to right side cerebellar syndrome. During surgery, the authors identified that the origin of the tumor was from the abducens nerve, and the histopathological diagnosis confirmed that it was a schwannoma. A gross total tumor resection was performed, and the patient recovered from her symptoms 1 month after surgery. The authors followed the Case Report guidelines (CARE) guideline and the patient authorized the authors to publish the present case report by signing an informed consent form.

Keywords
- case report
- neurilemmoma
- abducens nerve
- ocular motility disorders
- skull base neoplasm
- schwannoma

Resumo

Os autores descrevem um raro caso de Schwannoma do nervo abducente, cuja manifestação clínica foi com cefaleia e diplopia, associadas à síndrome cerebelar hemisférica direita. Durante a cirurgia, os autores identificaram que o tumor tinha sua origem junto ao nervo abducente, e o diagnóstico histopatológico confirmou schwannoma. Realizou-se uma ressecção completa do tumor e o paciente apresentou melhora total dos sintomas em um mês após a cirurgia. Os autores seguiram as diretrizes do CARE para produzir este relato e o paciente assinou o termo de consentimento livre e esclarecido, autorizando a publicação deste caso.

Palavras-chave
- relato de caso
- neurinoma
- nervo abducente
- paresia da motilidade ocular
- neoplasias da base do crânio
- schwannoma

received
June 16, 2021
accepted
September 6, 2021
published online
January 28, 2022

DOI https://doi.org/10.1055/s-0041-1740165.
ISSN 0103-5355.

© 2022. Sociedade Brasileira de Neurocirurgia. All rights reserved.
This is an open access article published by Thieme under the terms of the Creative Commons Attribution-NonDerivative-NonCommercial-License, permitting copying and reproduction so long as the original work is given appropriate credit. Contents may not be used for commercial purposes, or adapted, remixed, transformed or built upon. (https://creativecommons.org/licenses/by-nc-nd/4.0/)
Thieme Revinter Publicações Ltda., Rua do Matoso 170, Rio de Janeiro, RJ, CEP 20270-135, Brazil

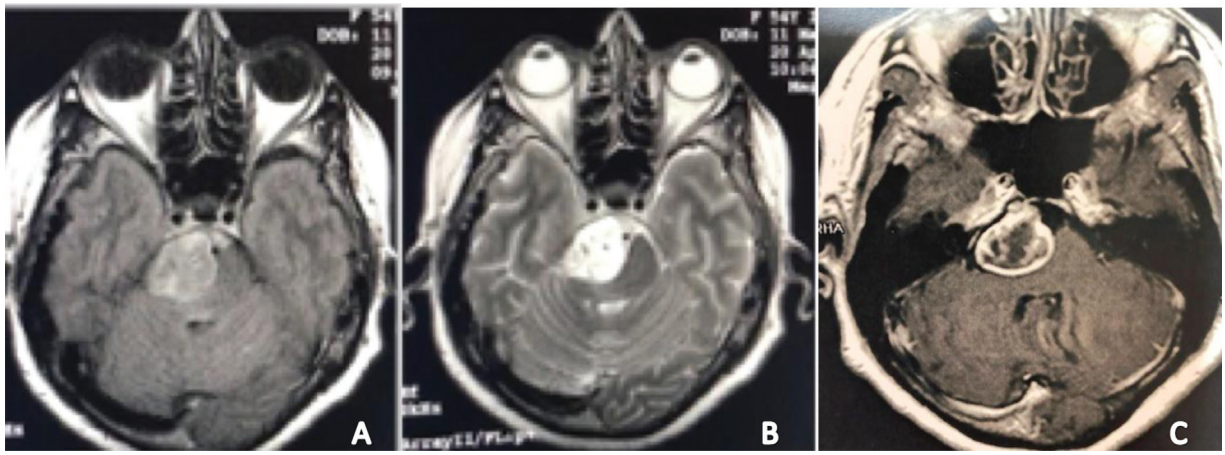

Fig. 1 Presurgical magnetic resonance imaging demonstrating a heterogenous but predominantly isointense signal on T1 images (A), hyperintense signal on T2 images (B) with a circumferential enhancement after gadolinium infusion (C).

Introduction

Schwannomas are benign slow growing tumors that arise from the Schwann cells of the neural sheath of the nerves and account for between 6 and 8% of all primary intracranial neoplasms.[1–3] Even though they can be seen in most cranial nerves (except from the optic and olfactory nerves),[3,4] they usually arise from sensory nerves (most frequently from the vestibular nerve, followed by the trigeminal nerve), with motor nerves being rarely affected.[3,5]

Schwannomas of the abducens nerve are rare. Since a schwannoma of the abducens nerve was first reported by Chen in 1981,[6] only 31 other cases had been reported worldwide by 2017.[7] The authors report a case of a patient who presented with headache and diplopia for 2 months, whose neurological exam demonstrated a right abducens nerve paresis. Investigation demonstrated an extra-axial lesion located in the prepontine cistern. During surgery, it was noticed that the tumor originated from the abducens nerve, and the histopathological diagnosis confirmed that it was a schwannoma. The patient completely recovered her ocular motricity after 1 month of follow-up.

Case Report

A 55-year-old previously healthy woman was referred to the department of oncological neurosurgery for investigation of a 2-month evolution of headache whose intensity was progressively increasing, associated with diplopia and loss of dynamic balance. The neurological exam of the patient demonstrated an inner horizontal deviation of the right eyeball secondary to paresis of the right abducens nerve. Other ocular movements were preserved. The patient presented no paresis, but coordination and delicate movements control were disturbed, since the patient presented a right sided dysdiadokokinesis, gait ataxia, and right-sided deviation of the dynamic balance. Magnetic resonance imaging (MRI) demonstrated an extra-axial lesion located in the prepontine cistern compressing the anterolateral right side of the pons. The tumor was predominantly isointense (compared with the brain parenchyma) on T1 images, with areas of hypointense signal. On T2 images, the tumor was hyperintense. After gadolinium infusion the tumor presented a heterogenous enhancement (►**Fig. 1**). The venous phase of an angioresonance demonstrated a significative right sigmoid sinus dominance. This was one of the reasons why the posterior petrosal approach was not considered a good option.

The patient was submitted to surgery by a lateral suboccipital right-sided retrosigmoid approach with complete removal of the tumor. During the surgery, it was noticed that the origin of the tumor was from rootlets of the right abducens nerve that emerged as two different roots. This duplicated origin of the nerve allowed the preservation of the main trunk in all its trajectory. A postoperative MRI scan showed gross total tumor resection (►**Fig. 2**). An anatomopathological analysis diagnosed the tumor as schwannoma, represented mostly by Antoni A areas consisting of closely apposed spindle-shaped cells in a palisading pattern (►**Fig. 3**).

During the early postoperative period, the patient persisted with right abducent palsy, but no other neurological deficits. By the 7th day of postoperative follow-up, the patient was discharged from hospital care, sustaining excellent wound healing and complete neurological recovery. Ocular motricity was completely recovered after 1 month of follow-

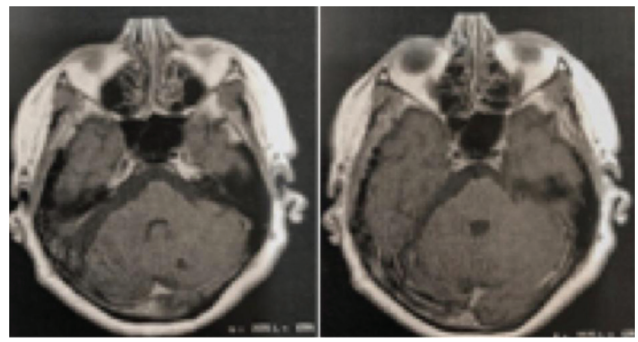

Fig. 2 Postsurgical magnetic resonance imaging demonstrating complete tumor resection

 © 2022. Sociedade Brasileira de Neurocirurgia. All rights reserved.

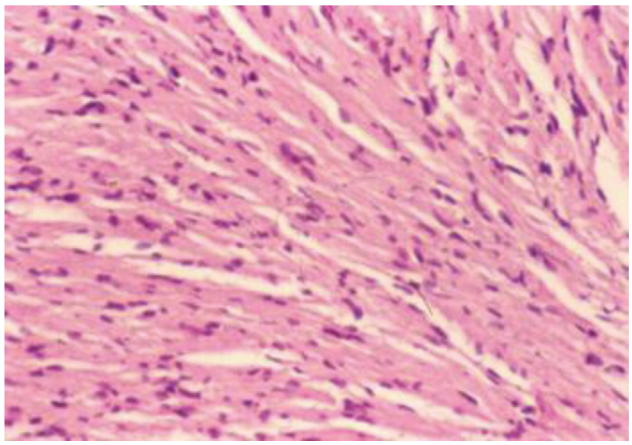

Fig. 3 Schwannoma consisting of closely apposed spindle-shaped cells in a palisading pattern (Antoni A).

up (►**Fig. 4**). The patient authorized the authors to publish the present case report by signing an informed consent form.

Discussion

The trigeminal nerve is the second most common site of schwannomas, representing ∼ 0.2% of all intracranial tumors.[5] Pure motor nerves that supply the ocular muscles (IIIrd, IVth and VIth nerves) are very rarely affected by this neoplasm.[4,8,9] Unlike the more common vestibular schwannomas, those of the VIth nerve usually arise distal from the glial-Schwann sheath junction. This transitional zone of the abducens nerve represents the junction of central and peripheral myelin and lies < 1 mm from the brainstem.[8,10,11]

Abducens nerve schwannomas are more frequent in females, with a mean age of 45 years old (peak of frequency in the 5th decade of life), characteristics that were also found in our case. The youngest patient ever described was 10 years old,[12] and the oldest was 66 years old.[13] Some of the cases described in the literature were associated with neurofibromatosis type 1 (NF-1).

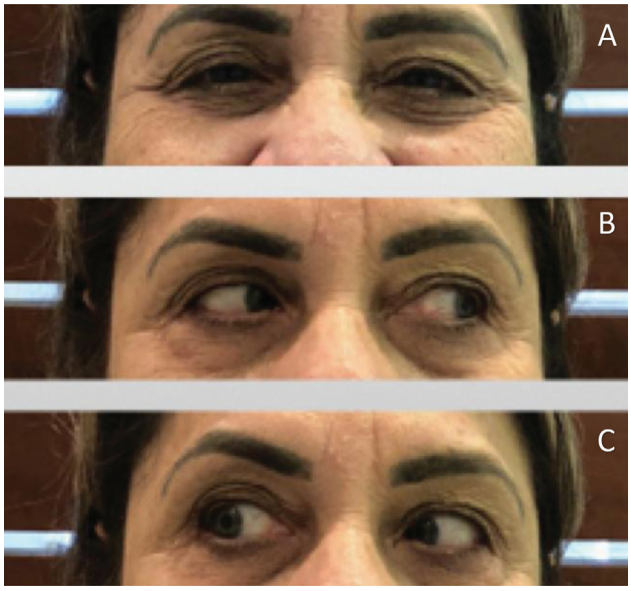

Fig. 4 Postsurgical ocular extrinsic exam demonstrating normal horizontal ocular movement. (A) Patient looking forward. (B) Patient looking to the left. (C) Patient looking to the right.

The abducens nerve emerges from the brainstem near the midline at the pontomedullary sulcus. It courses upwardly, laterally, and anteriorly in the prepontine cistern and passes underneath the Gruber ligament, entering the Dorello canal. The nerve enters in the cavernous sinus at the lower part of the posterior wall, crossing the sinus medially to the ophthalmic nerve and lateral to the internal carotid artery. Finally, the nerve enters the orbital cavity at the medial end of the superior orbital fissure.[10]

Abducens nerve schwannomas can arise from the intracranial or intraorbital portion of the nerve. Intracranial tumors can originate from the emergence of the nerve in the pontomedullary sulcus to the cavernous portion close to the superior orbital fissure. Tung et al. classified intracranial abducens schwannomas into two types depending their location: Type 1 occurs in the cavernous sinus (cavernous abducens schwannoma); and Type 2 occurs at the prepontine cistern (cisternal abducens schwannoma).[14] However, some cases involving cisternal and cavernous segments were described, named as cisternocavernous dumbbell-shaped type, and were assigned to a new category of abducens schwannomas (Type 3).[5] Based on the aforementioned classification, most abducens schwannomas arise from the cisternal portion, followed equally by the cavernous and cisternocavernous types.[8] A literature research has identified only two cases of extracranial intraorbital abducens nerve schwannomas.[4,15]

The clinical presentation differ according to the location of the tumor. Diplopia, secondary to isolated abducens nerve palsy, is the most frequent manifestation of Type 1 tumors.[3] In contrast, tumors located in the cistern may present with obstructive hydrocephalus and raised intracranial pressure, besides VIth nerve palsy.[8] Depending on the size of the cisternal tumor, other cranial nerves can be involved, such as the trigeminal, the vestibulocochlear and the facial nerves.[8,10] In such cases, patients may present with facial pain, facial numbness, hearing disturbance or oculomotor palsy.[3]

Clinical features and neuroradiologic image are frequently insufficient to reach an accurate preoperative diagnosis.[3] The diagnosis of abducens schwannoma is seldomly performed before operation and, typically, the primary suspicion is meningioma or trigeminal schwannoma.[8]

The typical MRI findings of schwannomas demonstrate an iso-to-hypointensity image in T1, hyperintensity in T2, and a heterogeneous contrast enhancement. Heterogeneous signal intensity and postcontrast enhancement are suggestive of internal hemorrhage and myxoid/cystic changes.[16] Besides, schwannomas can show degenerative changes, such as cyst formation, calcification, hemorrhage, and hyalinization,[17] characteristics that make the radiological diagnosis more difficult.

Most abducens schwannomas are solid, but a cystic variant with a ring-like enhancement is found in a significant percentage of cases.[8] Other indirect signs that highlight the

 © 2022. Sociedade Brasileira de Neurocirurgia. All rights reserved.

suspicion of nonvestibular Schwannomas are: normal size of the internal acoustic meatus and posterior displacement of the facial and vestibulocochlear nerve complex, which preclude the possibility of the vestibular origin.[3] A 3D-Constructive Interference in Steady State (3D-CISS) acquisition, a part of fast gradient echo sequences, can possibly define preoperatively the relationship details of the tumor and the cranial nerves adjacent to the neoplasm.[18]

A specific radiological characteristic was described in dumbbell-shaped schwannomas, which are often seen in the trigeminal nerves. But compared with the trigeminal tumors, the neoplasms arising from the abducens nerve present a different pattern. The neck constriction of dumbbell-shaped schwannomas forms an obtuse angle in trigeminal schwannomas, whereas in abducens schwannomas, it forms an acute angle.[5]

The first operated abducens schwannoma was described by Chen in 1981,[6] and, up to now, operation is the only therapy that has been reported to be successful.[8] Besides, the definite diagnosis of an abducens nerve schwannoma is established intraoperatively, when the surgeon can visualize the tumor attachment into the VIth nerve.[8]

The surgical technique and approach vary according to the location of the tumor. For schwannomas in the cavernous and parasellar regions (Type 1), the frontotemporal, subtemporal, orbitozygomatic, and anterior transpetrosal approaches have all been reported. For prepontine lesions (Type 2), the lateral suboccipital retrosigmoid, lateral suboccipital transcondylar, and anterior transpetrosal approaches have been reported.[5,8]

The surgical technique used to resect dumbbell-shaped tumors that extend both to the posterior and middle cranial fossae has not been described specifically for abducens schwannomas. The reports in the literature are for trigeminal schwannomas, in which case the anterior transpetrosal approach would be a good option.[19]

Preservation of nerve function as well as maximum tumor removal are critical in surgery for intracranial schwannomas, but abducens nerve function uncommonly recovers completely after removal of the abducens nerve schwannoma. To date, among the 32 cases of pathologically confirmed intracranial abducens nerve schwannoma reported, postoperative nerve function recovered completely in only 7 cases and partially in 3 cases.[8,9,20] Permanent or transient abducens nerve palsy occur postoperatively in most cases because the nerve was usually disturbed or sacrificed.

The reason for complete recovery of nerve function in the seven cases reported in the literature, as well as in the present case, may be the splitting of the nerve root or the existence of a separate trunk of the abducens nerve in the subarachnoid space.[8] The preservation of one of the nerve roots or the preservation of some nerve fascicles in patients with a single nerve root makes possible the recovery of ocular external gaze. This suggests that intentional subcapsular removal preserving part of the tumor capsule as a scaffold for regeneration of the nerve would potentiate functional recovery even in cases in which the course of the abducens nerve is not identified intraoperatively, as long as nerve function is preserved preoperatively.[8]

Finally, since the abducens nerve is a pure motor nerve, primary nerve repair using anastomosis would potentiate functional recovery. Direct end-to-end anastomosis after complete excision of the tumor may result in functional improvement during follow-up.[3]

Conclusion

The authors describe the 33rd case of abducens nerve schwannoma in the medical literature, but the 8th with full recovery of nerve function. Tumoral gross total removal remains the goal of the treatment, and the preservation of one the nerve roots (when multiple) or fascicles of the nerve (when single) is of paramount importance for the recovery of ocular movement.

Financial Support
There was no financial support or funding for the present project.

Conflict of Interests
The authors have no conflict of interests to declare.

Reference

1 Erlich SA, Tymianski M, Kiehl TR. Cellular schwannoma of the abducens nerve: case report and review of the literature. Clin Neurol Neurosurg 2009;111(05):467–471. Doi: 10.1016/j.clineuro.2009.01.001
2 Nakamizo A, Matsuo S, Amano T. Abducens Nerve Schwannoma: A Case Report and Literature Review. World Neurosurg 2019; 125:49–54. Doi: 10.1016/j.wneu.2019.01.123
3 Park JH, Cho YH, Kim JH, Lee JK, Kim CJ. Abducens nerve schwannoma: case report and review of the literature. Neurosurg Rev 2009;32(03):375–378, discussion 378. Doi: 10.1007/s10143-009-0203-7
4 Rato RMF, Correia M, Cunha JP, Roque PS. Intraorbital abducens nerve schwannoma. World Neurosurg 2012;78(3-4):375.e1–375.e4. Doi: 10.1016/j.wneu.2011.12.012
5 Shibao S, Hayashi S, Yoshida K. Dumbbell-shaped abducens schwannoma: case report. Neurol Med Chir (Tokyo) 2014;54 (04):331–336. Doi: 10.2176/nmc.cr2012-0304
6 Chen BH. Neurinoma of the abducens nerve. Neurosurgery 1981; 9(01):64–66. Doi: 10.1097/00006123-198107000-00011
7 Sun H, Sharma K, Kalakoti P, et al. Factors Associated with Abducens Nerve Recovery in Patients Undergoing Surgical Resection of Sixth Nerve Schwannoma: A Systematic Review and Case Illustration. World Neurosurg 2017;104:883–899. Doi: 10.1016/j.wneu.2017.04.146
8 Vachata P, Sameš M Abducens nerve schwannoma mimicking intrinsic brainstem tumor. Acta Neurochir (Wien) 2009;151(10): 1281–1287. Doi: 10.1007/s00701-009-0302-9
9 Nakamura M, Carvalho GA, Samii M. Abducens nerve schwannoma: a case report and review of the literature. Surg Neurol 2002;57(03):183–188, discussion 188–189. Doi: 10.1016/S0090-3019(01)00670-X
10 Mascarenhas L, Magalhães Z, Honavar M, et al. Schwannoma of the abducens nerve in the cavernous sinus. Acta Neurochir (Wien) 2004;146(04):389–392, discussion 391–392. Doi: 10.1007/s00701-003-0197-9

 © 2022. Sociedade Brasileira de Neurocirurgia. All rights reserved.

11 Celli P, Ferrante L, Acqui M, Mastronardi L, Fortuna A, Palma L. Neurinoma of the third, fourth, and sixth cranial nerves: a survey and report of a new fourth nerve case. Surg Neurol 1992;38(03): 216–224. Doi: 10.1016/0090-3019(92)90172-J
12 Leunda G, Vaquero J, Cabezudo J, Garcia-Uria J, Bravo G. Schwannoma of the oculomotor nerves. Report of four cases. J Neurosurg 1982;57(04):563–565. Doi: 10.3171/jns.1982.57.4.0563
13 Beppu T, Yoshida Y, Wada T, et al. Trochlear and abducens nerve neurinomas accompanied by a cerebellopontine angle meningioma–case report. Neurol Med Chir (Tokyo) 1997;37(05):416–421. Doi: 10.2176/nmc.37.416
14 Tung H, Chen T, Weiss MH. Sixth nerve schwannomas. Report of two cases. J Neurosurg 1991;75(04):638–641. Doi: 10.3171/jns.1991.75.4.0638
15 Irace C, Davì G, Corona C, Candino M, Usai S, Gambacorta M. Isolated intraorbital schwannoma arising from the abducens nerve. Acta Neurochir (Wien) 2008;150(11):1209–1210. Doi: 10.1007/s00701-008-0134-z
16 Cicero G, D'angelo T, Racchiusa S, Racchiusa S, Salamone I, Visalli C, Bottari A, Blandino A, Mazziotti S. Cross-sectional Imaging of Parotid Gland Nodules: A Brief Practical Guide. J Clin Imaging Sci 2018 Apr 16;8:14. Doi: 10.4103/jcis.JCIS_8_18. PMID: 29770262; PMCID: PMC5939036
17 Dahl I. Ancient neurilemmoma (Schwannoma). Acta Pathol Microbiol Scand - Sect A Pathol 1977. Doi: 10.1111/j.1699-0463.1977.tb03896.x
18 Besta R, Shankar YU, Kumar A, Rajasekhar E, Prakash SB. MRI 3D CISS–A novel imaging modality in diagnosing trigeminal neuralgia–A review. J Clin Diagn Res 2016;10(03):ZE01–ZE03. Doi: 10.7860/JCDR/2016/14011.7348
19 Okada Y, Shima T, Nishida M, Okita S. Large sixth nerve neuroma involving the prepontine region: case report. Neurosurgery 1997; 40(03):608–610. Doi: 10.1097/00041327-199712000-00020
20 Nakagawa T, Uchida K, Ozveren MF, Kawase T. Abducens schwannoma inside the cavernous sinus proper: case report. Surg Neurol 2004;61(06):559–563, discussion 563. Doi: 10.1016/S0090-3019(03)00580-9

 © 2022. Sociedade Brasileira de Neurocirurgia. All rights reserved.