



Van Neck-Odelberg Disease — A Rare or Underdiagnosed Condition?

Doença de Van Neck-Odelberg – Entidade rara ou subdiagnosticada?

Mafalda Moreira¹ Diana Alba¹ Hélder Nogueira¹ Sandra Teixeira¹

¹Department of Pediatrics, Centro Hospitalar do Tâmega e Sousa, Penafiel, Portugal

Address for correspondence Mafalda Moreira, Pediatrics Resident, Centro Hospitalar do Tâmega e Sousa, Porto, Portugal (e-mail: mafalda.moreira@campus.ul.pt).

Rev Bras Ortop

Abstract

Van Neck-Odelberg (VNO) disease is a rare osteochondrosis affecting the ischiopubic synchondrosis (IPS). This condition should be included in the differential diagnosis of children with lameness, inguinal pain, and functional limitation of the hip. In imaging tests, it is characterized by asymmetric IPS hypertrophy. We present the clinical case of a 4-year-old child, previously healthy, who visited the emergency department for left inguinal pain and lameness starting on the same day. There was no previous history of trauma or changes in inflammatory parameters. The patient underwent a pelvic radiography and magnetic resonance imaging (MRI), which revealed a radiopaque image with well-defined contours in the left ischiopubic branch, and IPS swelling. With a presumed diagnosis of VNO disease, the patient was medicated symptomatically, with complete recovery in 10 days. Lameness is a frequent reason for medical evaluation in the pediatric population. In subjects up to 5 years old, the most common causes of lameness include transient hip synovitis, septic arthritis, and Legg-Calvé-Perthes disease. In the absence of a history of trauma or infection-related clinical findings, VNO disease should be considered as a hypothesis. Its diagnosis requires a pelvic radiography, usually showing a unilateral fusiform opacification at the ischial level; an MRI may be necessary. The recommended treatment is conservative, with symptomatic recovery in 2 weeks. The knowledge and diagnosis of VNO disease allow a targeted approach, without the emotional burden for the patient and his/her family that may be associated to other conditions.

Keywords

- ▶ osteochondrosis
- ▶ child
- ▶ intermittent claudication

Resumo

A doença de Van Neck-Odelberg (VNO) é uma osteocondrose rara, que acomete a sincondrose isquiopúbica (SIP). Esta entidade deve ser incluída no diagnóstico

* Study performed at Centro Hospitalar do Tâmega e Sousa, Penafiel, Portugal.

received
December 14, 2020
accepted
February 11, 2021

DOI <https://doi.org/10.1055/s-0041-1739402>.
ISSN 0102-3616.

© 2022. Sociedade Brasileira de Ortopedia e Traumatologia. All rights reserved.

This is an open access article published by Thieme under the terms of the Creative Commons Attribution-NonDerivative-NonCommercial-License, permitting copying and reproduction so long as the original work is given appropriate credit. Contents may not be used for commercial purposes, or adapted, remixed, transformed or built upon. (<https://creativecommons.org/licenses/by-nc-nd/4.0/>)

Thieme Revinter Publicações Ltda., Rua do Matoso 170, Rio de Janeiro, RJ, CEP 20270-135, Brazil

diferencial de crianças com claudicação na marcha, dor inguinal e limitação funcional do quadril. Imagiologicamente é caracterizada por hipertrofia assimétrica da SIP. Apresentamos o caso clínico de uma criança de 4 anos, previamente saudável, atendida no serviço de emergência devido a dor inguinal no lado esquerdo e claudicação na marcha com início no mesmo dia. Não havia história prévia de trauma ou alteração dos parâmetros inflamatórios. Foi realizada uma radiografia da bacia e ressonância magnética nuclear (RMN) que evidenciou imagem radiopaca de contornos bem definidos no ramo isquiopúbico esquerdo e edema na SIP. Com diagnóstico provável de doença de VNO, o paciente foi medicado sintomaticamente, com resolução completa ao fim de 10 dias. A claudicação na marcha é um motivo frequente de avaliação médica na população pediátrica. Até os 5 anos de idade, as causas mais comuns são sinovite transitória do quadril, artrite séptica e Doença de Legg-Calvé-Perthes. Na ausência de história de trauma ou clínica sugestiva de infecção deverá ser equacionada a hipótese de doença de VNO. Para o seu diagnóstico, é fundamental a realização de radiografia da bacia, cujo achado mais comum é uma opacificação fusiforme unilateral, no nível do ísquion, podendo ser necessária a realização de RMN. O tratamento recomendado é conservador, com recuperação sintomática em 2 semanas. O conhecimento e o diagnóstico desta entidade permitem uma abordagem direcionada e sem a carga emocional para o paciente e seus familiares que outras patologias poderiam transmitir.

Palavras-chave

- ▶ osteocondrose
- ▶ criança
- ▶ claudicação intermitente

Introduction

Osteochondrosis, also called osteochondritis by some authors, results from changes in endochondral ossification at the level of developing bone nuclei at epiphyses and apophyses.^{1,2} Although its etiology remains unknown, vascular and microtraumatic changes seem to be play a role.² Osteochondrosis predominates in childhood and adolescence, and it is associated with growth spurts and hormonal changes. The most frequent osteochondroses include Köhler disease, Freiberg disease, Sever disease, and Osgood-Schlatter disease; in contrast, ischiopubic osteochondritis, or Van Neck-Odelberg (VNO) disease, is a rarely diagnosed osteochondrosis.¹

The first description of ischiopubic osteochondritis was made in 1923 by Van Neck, and later complemented by Odelberg in 1924; as such, it is known today as Van Neck-Odelberg disease.^{3,4} It is a benign, self-limiting condition characterized by imaging evidence of asymmetric ischiopubic synchondrosis (IPS) hypertrophy, associated with lameness, unilateral inguinal pain, and functional limitation of the hip.^{3,4} The differential diagnoses list include stress fracture, infectious conditions (i.e., osteomyelitis), or neoplastic diseases; some cases require magnetic resonance imaging (MRI) for diagnosis.^{3,5,6}

Case Report

A 4-year-old girl, otherwise healthy, visited the emergency department with lameness and left inguinal pain for 24 hours, with progressive worsening. She presented no fever, constitutional symptoms, or local inflammatory signs.

There was no previous history of trauma or recent infectious complications. An objective examination revealed pain during hip mobilization, with no local inflammatory signs.

An analytical study, including complete blood count, erythrocyte sedimentation rate (ESR), and C-reactive protein (CRP), revealed no major changes. A pelvic radiography showed a radiopaque image, about 1.8 × 1.4 cm in size, with well-defined contours, at the level of the left ischiopubic branch (► **Figures 1 and 2**). For etiological clarification, an MRI of the pelvis was performed, which showed edema at the level of the left ischiopubic synchondrosis, with no abnormalities in the adjacent soft tissues (► **Figure 3**).

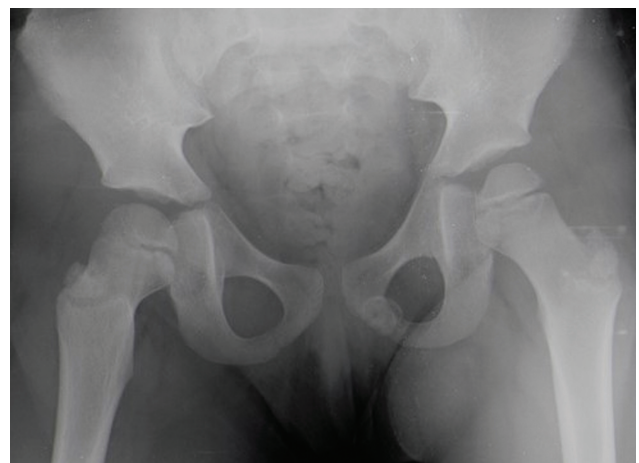

Fig. 1 Radiography of the pelvis (anteroposterior view), revealing a radiopaque image at the level of the left ischiopubic branch, with well-defined contours.

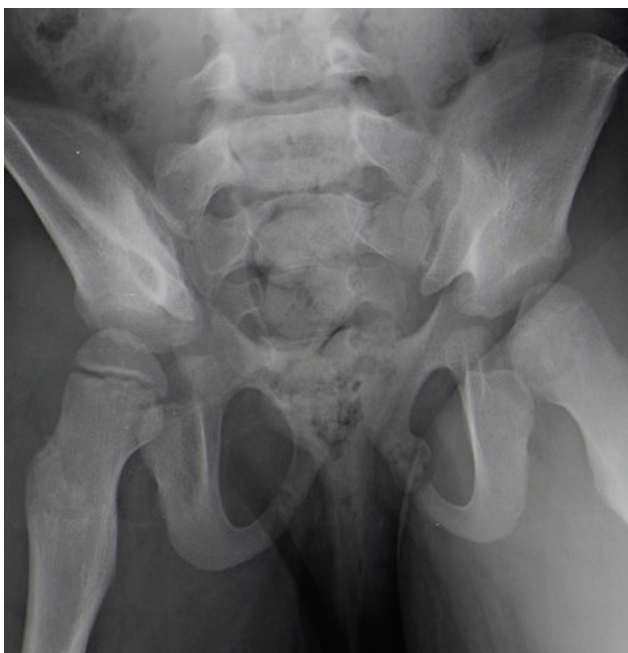

Fig. 2 Radiography of the pelvis (outlet view).

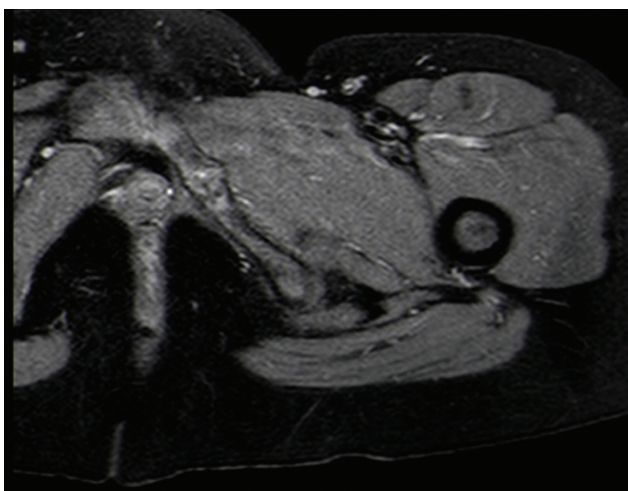


Fig. 3 Magnetic resonance imaging of the pelvis, revealing edema at the level of the left ischiopubic synchondrosis.

Excluding the hypotheses of infectious or tumoral etiology, a diagnosis of VNO disease was presumed. The patient was symptomatically medicated with oral antiinflammatory and rest. Ten days later, she was reassessed clinically, with no complaints.

A radiograph of the pelvis was repeated 6 months later and showed complete remodeling of the lesion area (► **Figure 4**). The patient presented no new episodes.

Discussion

Lameness is a frequent complaint in the pediatric population. Its differential diagnosis is very challenging due to the multiple potential etiologies, which vary according to the age group. In children with unilateral inguinal pain and

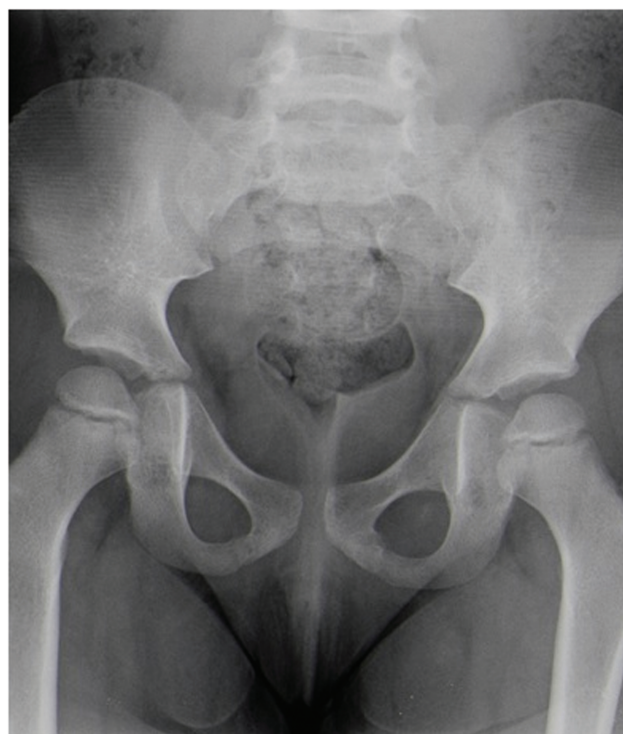

Fig. 4 Radiography of the pelvis (anteroposterior view), revealing complete recovery.

limited hip mobility but no fever, history of trauma, or recent infections, VNO disease is an important consideration.⁶

This condition results from the asymmetric ossification process of the IPS, which usually begins in childhood and ends before adolescence.⁵ In most cases, it does not cause symptoms. However, some children may present inguinal or gluteal pain and joint mobility limitation.

Van Neck-Odelberg disease is usually more frequent in the non-dominant lower limb, mostly the left one, as in the case of our patient. Some authors believe that this is due to body weight support mainly by the non-dominant lower limb compared to the contralateral one, which is used preferentially for movement execution.^{3,5} This force imbalance may delay the IPS closing at the non-dominant side, which, due to mechanical stress, may become painful.^{3,5}

Van Neck-Odelberg osteochondritis is a diagnosis of exclusion in children with lameness.⁶ Its diagnosis requires a pelvic radiography, which often reveals a unilateral fusiform opacification at the ischial level. Since IPS hypertrophy can mimic a tumor, an MRI is useful for differential diagnosis.⁷ Although it is not a diagnostic criterion for VNO disease, the lack of increased levels of inflammatory parameters, that is, leukocytes, CRP, and ESR, supports this hypothesis.^{6,8}

Conservative treatment is the most frequently recommended option, and it consists in antiinflammatory therapy and rest. It is associated with a favorable clinical evolution and disappearance of complaints in about 2 to 3 weeks.^{3,5,8} Imaging resolution is more prolonged and may take from several months to 1 year.³ When ossification is complete, the ischiopubic junction deformity disappears. It is important to note that radiological findings of delayed IPS fusion in

asymptomatic children do not result in an ischiopubic osteochondritis diagnosis.⁵

On the other hand, VNO disease knowledge and diagnosis as a benign, self-limited condition, allow a targeted approach, without the emotional burden for the patient and his/her family that may be associated to other conditions.

Financial Support

There was no financial support from public, commercial, or non-profit sources.

Conflict of Interests

The authors declare that there is no conflict of interests.

References

- 1 Danger F, Wasyliv C, Varich L. Osteochondroses. *Semin Musculoskelet Radiol* 2018;22(01):118-124
- 2 West EY, Jaramillo D. Imaging of osteochondrosis. *Pediatr Radiol* 2019;49(12):1610-1616
- 3 Chaudhari AP, Shah G, Patil SS, Ghodke AB, Kelkar SB. Van Neck-Odelberg Disease: A Rare Case Report. *J Orthop Case Rep* 2017;7(01):24-27
- 4 Akkari M, Waisberg G, Reis Braga S, et al. Osteocondrite de Van Neck-Odelberg. Relato de 4 casos. *Rev Bras Ortop* 2010;45:55-58
- 5 Oliveira F. Differential diagnosis in painful ischiopubic synchondrosis (IPS): a case report. *Iowa Orthop J* 2010;30(Suppl):195-200
- 6 Ferreira J. Van Neck-Odelber Disease: a rare cause of childhood limping. *Nascer Crescer* 2019;28(04):223-227
- 7 Morante Bolado I, Ortega Navaridas M, Clemente Garulo D, López Robledillo JC. Enfermedad de Van Neck-Odelberg: una causa más de cojera en la infancia. *Reumatol Clin* 2017;13(05):299-300
- 8 Wait A, Gaskill T, Sarwar Z, Busch M. Van neck disease: osteochondrosis of the ischiopubic synchondrosis. *J Pediatr Orthop* 2011;31(05):520-524