Dark Cartilage Lesions in the Knee: MRI Appearance and Clinical Significance

John Christopher Knoth, BS[1] Jeremiah R. Long, MD[2] James Derek Stensby, MD[3]

[1] Medical School, University of Missouri - Columbia, Missouri
[2] Department of Radiology, Mayo Clinic Arizona, Scottsdale, Arizona
[3] Department of Radiology, 1 Hospital Dr, University of Missouri, Columbia, Missouri

Address for correspondence James Derek Stensby, MD, Department of Radiology, University of Missouri, 1 Hospital Dr, Columbia, MO 65212 (e-mail: stensbyj@health.missouri.edu).

J Knee Surg 2022;35:470–474.

Abstract

Early investigations into the magnetic resonance imaging (MRI) appearance of articular cartilage imaging relied on assessment of the morphology, with subsequent investigators reporting identifying increased T2 signal intensity, bright signal, in degenerated cartilage. The cartilage "black line sign" is a finding that has recently been described in the radiology literature to characterize cartilage pathology. This sign refers to a focal linear hypointense signal within articular cartilage that is oriented perpendicular to the subchondral bone on T2-weighted MRI. The diagnostic significance and clinical relevance of this sign is debated. Since its first description, several papers have further delineated the etiology, prevalence, and clinical relevance of these and other dark cartilage abnormalities. The intent of this article is to summarize these findings, with hopes of bringing to light the importance of dark cartilage lesions and their clinical implication in the world of knee surgery. We will briefly discuss the most probable etiologies of dark cartilage abnormalities and the major factors determining the unique signal intensity. The described anatomical patterns of this finding, the clinical importance, potential mimics, and current treatment recommendations will be reviewed.

Keywords
- MRI
- cartilage
- cartilage fissure

Articular cartilage has a smooth, nearly frictionless surface, which veils the complex structure hidden beneath. This complex structure allows the hyaline articular cartilage to withstand substantial deforming forces.[1] The articular cartilage is composed of four layers: superficial, transitional, deep, and calcified zones.[2] Each layer contains chondrocytes in varying quantities and shape which produce, organize, and maintain the extracellular matrix in which they are embedded.[2] This extracellular matrix is composed of water, proteoglycans, collagens, and noncollagenous proteins.[2] The relative thickness of each layer of articular cartilage depends upon the joint and location within the given joint.[1,2]

MRI of Normal Cartilage

Adequate assessment of articular cartilage with magnetic resonance imaging (MRI) is a challenge due to its thin structure, the complex shape of articular surfaces, and normal variations in signal intensity. Many different MR pulse sequences are available to accurately assess the cartilage. To overcome these challenges, the principal goals of cartilage imaging are to achieve sufficient contrast between the cartilage and synovial fluid, achieve sufficient contrast between the cartilage and subchondral bone, achieve sufficient signal to noise to identify the internal signal of the cartilage, and achieve sufficient spatial resolution to identify

received
July 30, 2021
accepted
September 21, 2021
published online
November 15, 2021

Thieme Medical Publishers, Inc., 333 Seventh Avenue, 18th Floor, New York, NY 10001, USA

DOI https://doi.org/10.1055/s-0041-1739259.
ISSN 1538-8506.

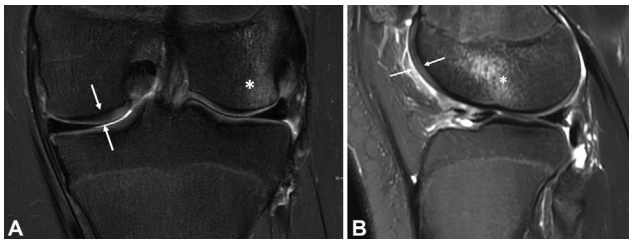

Fig. 1 Normal trilaminar appearance of articular cartilage. Coronal proton density (PD)-weighted, fat-suppressed (**A**) and sagittal T2-weighted fat suppressed (**B**) magnetic resonance images in a 14-year-old boy obtained to assess a transient patellar dislocation, resulting in marrow edema in the lateral femoral condyle (asterisks). Images demonstrate the normal trilaminar appearance of the articular cartilage (arrows). This appearance varies based on the orientation of the cartilage relative to the main magnetic field. The deep layer is low in signal intensity, the thicker intermediate layer is hyperintense, and the thin superficial layer is hypointense.

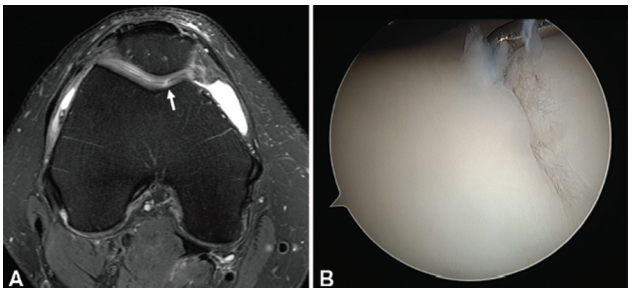

Fig. 2 Typical hyperintense cartilage fissure. Axial T2-weighted magnetic resonance image with fat suppression (**A**) in a 44-year-old man with anterior knee pain after playing basketball demonstrates the typical cartilage fissure (arrow) in the medial trochlear facet. The fissure is focally hyperintense on T2-weighted images and oriented

small cartilage defects.[3] At MRI, articular cartilage has a layered appearance which mimics its histology. This structure is best demonstrated with high-resolution images obtained, utilizing a dedicated knee coil on a high-field strength (1.5T or 3T) MRI scanner (►**Fig. 1**).

On most T2-weighted fast spin-echo sequences, the articular cartilage has variable signal intensity that reflects its complex structure. When imaged perpendicular to the main magnetic field, articular cartilage typically has a trilaminar appearance.[1,4,5] The layered appearance is predictable; however, it is not constant, changing with its orientation relative to the main magnetic field.[1,6] On T2-weighted images, the deep layer is low in signal intensity; the intermediate layer is thicker and hyperintense/bright; and the thin superficial layer is hypointense.[1,4,5] This appearance is influenced by anisotropy and the orientation relative to the main magnetic field as well as the magic angle phenomenon (artifactual increase in signal on short TE, T1 and proton density (PD)-weighted, MRI sequences experienced by highly organized tissues positioned $\sim$ 55 degrees from the main magnetic field; the main magnetic field is parallel to the bore of the magnet).[1,6] With these variables in mind, gradual changes in the signal intensity of the articular cartilage across the joint during MRI should be viewed as normal.

MRI of Abnormal Cartilage

In the detection of cartilage injuries, a recent meta-analysis of 27 studies found a sensitivity and specificity of 77.3% and 91.5%, respectively, for routine two-dimensional MR imaging and a sensitivity and specificity of 74.8% and 93.3%, respectively, for three-dimensional MRI sequences when compared with arthroscopy or surgery.[7] At MR evaluation, the extent of cartilage injury is more commonly underestimated, particularly for superficial lesions.[8,9] The complex structure of the articular cartilage necessitates that it be assessed in multiple imaging planes, particularly when evaluating a curved surface such as the femoral trochlea. Chondral degeneration can be seen as a focal change in the surface contour, ranging from mild surface irregularity and fibrillation to cartilage thinning, cartilage fissuring, and full thickness cartilage loss.[4,10,11] Any abrupt change in the signal intensity of the articular cartilage should be viewed with suspicion for cartilage injury.[1,5,12] Finally, given the frequent association of cartilage injury with edema in the subchondral bone, identification of subchondral marrow edema should prompt a careful assessment of the overlying cartilage.

Dark Cartilage Lesions

Cartilage fissures are typically hyperintense on T2-weighted images, oriented perpendicular to the articular surface, and involve a variable amount of the articular surface, ranging from partial to full thickness (►**Fig. 2**).[13,14] In 2011, Stephens et al published a case series with three patients who had cartilage fissures appearing hypointense or dark on T2-weighted images, termed the "black line sign," in the patellofemoral compartment.[13] Of their three cases, two were confirmed with arthroscopy and could be probed to bone, while the third was confirmed with contrast extension into the defect on CT arthrography (►**Fig. 3**).[13] This finding was further investigated by Wissman et al in a retrospective review of 1300 knee MRI scans in which the "black line sign" was identified in the trochlea of 1.9% ($n = 25$) of all patients.[15] Of the eight patients with the "black line sign" who underwent arthroscopy, only 1 (12.5%) had a cartilage abnormality documented in the arthroscopy report. The majority of linear dark cartilage lesions in the knee with arthroscopic correlate are seen in the patellofemoral compartment, 64.7%, with 20.6% and 14.7% in the medial and lateral compartments, respectively.[16] The "black line sign" was found at MRI in the trochlea of collegiate athletes at a much higher rate than that of the general population: 4 of 32 (12.5%) knees evaluated in 16 female college volleyball players.[17] These dark cartilage lesions are frequently associated with subchondral edema or cystic change.[18] Finally, a "black line" has also been described at MRI of the hip as an imaging finding of arthroscopically confirmed chondral fissures in the acetabular cartilage.[19]

A retrospective review of 898 knee MRI examinations in 887 patients with arthroscopy as the reference standard

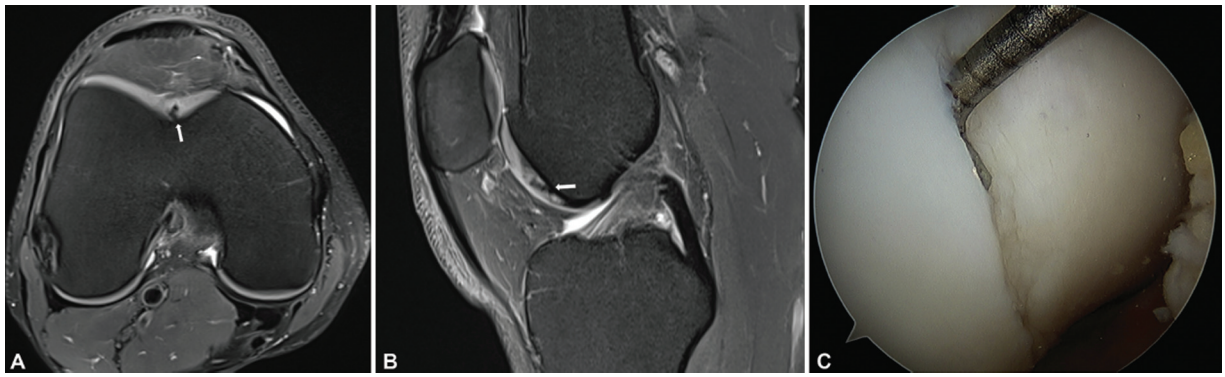

Fig. 3 The "black line sign." Axial (**A**) and sagittal (**B**) T2-weighted magnetic resonance images with fat suppression in a 36-year-old man with a 1-year history of atraumatic knee pain and catching. Images demonstrate focal hypointense linear signal perpendicular to the subchondral bone plate, the "black line sign," in the central trochlea (arrows). Subsequent arthroscopy performed for meniscal tear (not shown) demonstrates a near full thickness cartilage fissure being probed (**C**).

demonstrated 142 dark cartilage lesions at MRI in 131 patients (14.7%), with 36% having a linear morphology and 64% having an arthroscopic correlate.[16] Dark cartilage lesions were identified in all compartments of the knee: in the patellofemoral compartment in 8.3% of knees, the medial compartment in 1.8% of knees, and in the lateral compartment 5.7% of knees.[16]

Several theories exist regarding the difference in imaging appearance between the classic fluid signal T2 hyperintense chondral fissure and the more recently described hypointense chondral fissure. Stephens et al conjectured that the defect was too small to be fluid filled.[13] Wissman et al hypothesized that the clefts occur as a failure of the deep cartilage, which then cleaves the superficial layers. Those not seen at arthroscopy have been theorized to spare all but the most superficial layer of cartilage, rendering them occult at arthroscopy (►**Fig. 4**).[15] Alternate explanations include disruption in the normal anisotropy orientation, magnetization transfer, and chronic deposition of fibrocartilage; lesions involving the articular surface are more likely related to magnetization transfer, and those involving the subchondral bone are more likely hypointense due to fibrocartilage deposition.[18]

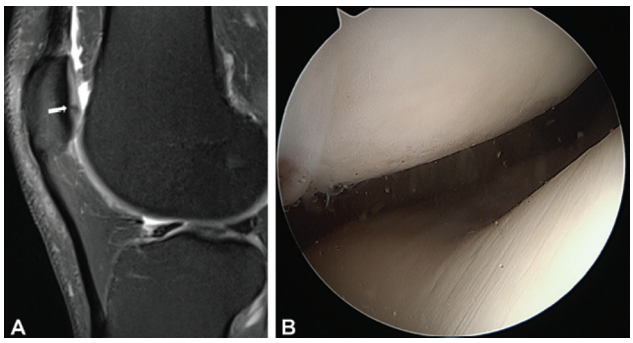

Fig. 4 The "black line sign." Sagittal T2-weighted magnetic resonance image with fat suppression (**A**) in a 36-year-old man with recent catching and locking demonstrates focal hypointense linear signal (arrow) in the lateral patellar facet. Subsequent arthroscopy performed for meniscal tear (not shown) demonstrates intact patellar articular cartilage (**B**).

Management of Dark Cartilage Fissures

Data from the Osteoarthritis Initiative, a longitudinal prospective multicenter cohort study, has shown that patients with abnormal signal in their articular cartilage are more likely to develop morphologic defects at 4 years than those with normal signal (57% vs. 4%), with no statistically significant difference in the rate of progression between hypointense and hyperintense cartilage lesions.[20] Articular cartilage defects in the knee have been identified at MRI in 62% of asymptomatic knees, with moderate or severe defects in 41% of knees, and most frequently involving the

Fig. 5 "Black line sign" mimic. Sagittal T2-weighted magnetic resonance image with fat suppression in a 44-year-old man with anterior knee pain demonstrates broad, hypointense signal in the deep trochlea (arrow), an area where the cartilage is consistently hypointense due to its orientation relative to the main magnetic field.

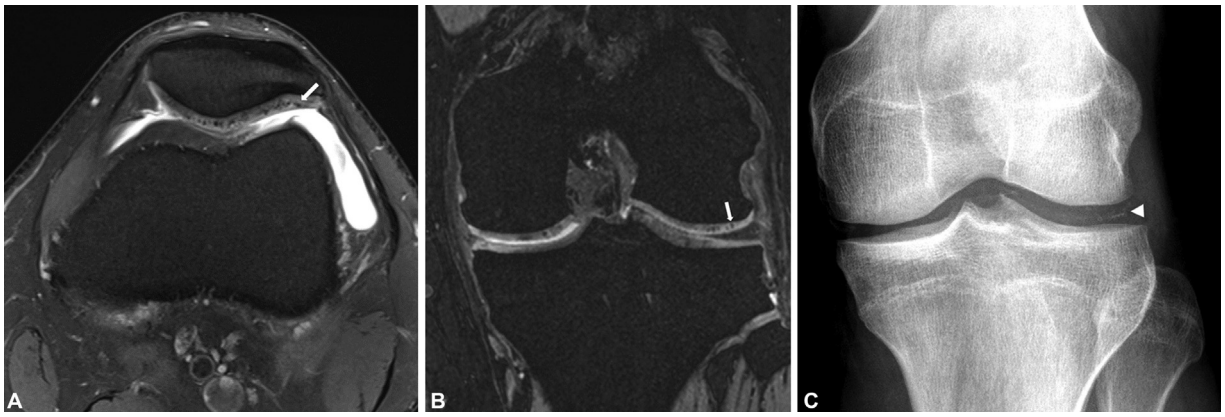

Fig. 6 "Black line sign" mimic. Axial T2-weighted magnetic resonance (MR) image with fat suppression (**A**) and coronal dual echo steady state, fluid sensitive gradient echo, MR image (**B**) in a 34-year-old man with severe medial knee pain following a twisting injury demonstrates multiple linear hypointense foci throughout the articular cartilage (arrows). Anteroposterior (AP) radiograph confirms the diagnosis of chondrocalcinosis (arrowhead) (**C**).

patellofemoral compartment.[21] Further underscoring the importance of treating the patient rather than his or her imaging findings is that cartilage defects are identified at MRI in approximately half of asymptomatic professional basketball players.[22,23] A trial of conservative therapy for a cartilage injury focused on restoring strength and flexibility should be considered.[24] If symptoms persist, a variety of surgical options exist, including both marrow stimulating and restorative procedures. For small lesions, including cartilage fissures, debridement and microfracture is preferred.[24]

Dark Cartilage Lesion Mimics

When evaluating MR images of the knee, knowledge of the mimics and normal variants that result in hypointense signal in the articular cartilage can assist in accurate assessment of the cartilage. As described earlier, the signal intensity of articular cartilage at MR imaging is multifactorial. One key to interpretation is that the change in signal intensity in normal articular cartilage should be gradual.[1] One area that is consistently hypointense on T2-weighted MR images of the knee with standard positioning is the distal trochlea (►**Fig. 5**).[25] Another mimic for a hypointense cartilage fissure is chondrocalcinosis. The calcification deposited in the articular cartilage results in linear hypointense signal, particularly evident on gradient echo sequences (►**Fig. 6**).[26] This pitfall can be avoided with careful comparison to standard radiographs.

Conclusion

Hypointense cartilage lesions are most frequently seen in the patellofemoral compartment of the knee; however, they may be seen in any part of the joint and have been described in other joints as well. Young, athletic patients may be at particular risk for this pathology due to repetitive high compressive forces across the joint.[17] While some of the lesions may not be visible at arthroscopy,[15] they are at risk of progressive cartilage degeneration.[20] Due to poor intrinsic ability of cartilage to heal,[27] identification of a hypointense cartilage fissure may warrant activity modification and/or weight loss to prevent progressive cartilage degeneration.[18,28]

Funding
None.

Conflict of Interest
None declared.

References

1 Goodwin DW. MRI appearance of normal articular cartilage. Magn Reson Imaging Clin N Am 2011;19(02):215–227
2 Huber M, Trattnig S, Lintner F. Anatomy, biochemistry, and physiology of articular cartilage. Invest Radiol 2000;35(10): 573–580
3 Hayes CW, Conway WF. Evaluation of articular cartilage: radiographic and cross-sectional imaging techniques. Radiographics 1992;12(03):409–428
4 Recht MP, Goodwin DW, Winalski CS, White LM. MRI of articular cartilage: revisiting current status and future directions. Am J Roentgenol 2005;185(04):899–914
5 Forney M, Subhas N, Donley B, Winalski CS. MR imaging of the articular cartilage of the knee and ankle. Magn Reson Imaging Clin N Am 2011;19(02):379–405
6 Rubenstein JD, Kim JK, Morova-Protzner I, Stanchev PL, Henkelman RM. Effects of collagen orientation on MR imaging characteristics of bovine articular cartilage. Radiology 1993;188(01): 219–226
7 Shakoor D, Guermazi A, Kijowski R, et al. Diagnostic performance of three-dimensional MRI for depicting cartilage defects in the knee: a meta-analysis. Radiology 2018;289(01):71–82
8 Bredella MA, Tirman PF, Peterfy CG, et al. Accuracy of T2-weighted fast spin-echo MR imaging with fat saturation in detecting cartilage defects in the knee: comparison with arthroscopy in 130 patients. AJR Am J Roentgenol 1999;172(04):1073–1080
9 Kijowski R, Blankenbaker DG, Woods MA, Shinki K, De Smet AA, Reeder SB. 3.0-T evaluation of knee cartilage by using three-dimensional IDEAL GRASS imaging: comparison with fast spin-echo imaging. Radiology 2010;255(01):117–127
10 Sonin AH, Pensy RA, Mulligan ME, Hatem S. Grading articular cartilage of the knee using fast spin-echo proton density-weighted MR imaging without fat suppression. Am J Roentgenol 2002; 179(05):1159–1166

11 Potter HG, Linklater JM, Allen AA, Hannafin JA, Haas SB. Magnetic resonance imaging of articular cartilage in the knee. An evaluation with use of fast-spin-echo imaging. J Bone Joint Surg Am 1998;80(09):1276–1284
12 Broderick LS, Turner DA, Renfrew DL, Schnitzer TJ, Huff JP, Harris C. Severity of articular cartilage abnormality in patients with osteoarthritis: evaluation with fast spin-echo MR vs arthroscopy. AJR Am J Roentgenol 1994;162(01):99–103
13 Stephens T, Diduch DR, Balin JI, Gaskin CM. The cartilage black line sign: an unexpected MRI appearance of deep cartilage fissuring in three patients. Skeletal Radiol 2011;40(01):113–116
14 Winalski CS, Gupta KB. Magnetic resonance imaging of focal articular cartilage lesions. Top Magn Reson Imaging 2003;14(02):131–144
15 Wissman RD, Ingalls J, Nepute J, et al. The trochlear cleft: the "black line" of the trochlear trough. Skeletal Radiol 2012;41(09): 1121–1126
16 Markhardt BK, Kijowski R. The clinical significance of dark cartilage lesions identified on MRI. AJR Am J Roentgenol 2015;205 (06):1251–1259
17 Wissman RD, England E, Mehta K, et al. The trochlear cleft: initial experience in elite athletes. J Comput Assist Tomogr 2014;38(04): 499–502
18 Markhardt BK, Chang EY. Hypointense signal lesions of the articular cartilage: a review of current concepts. Clin Imaging 2014;38(06):785–791
19 Pfirrmann CWA, Duc SR, Zanetti M, Dora C, Hodler J. MR arthrography of acetabular cartilage delamination in femoroacetabular cam impingement. Radiology 2008;249(01):236–241
20 Schwaiger BJ, Gersing AS, Mbapte Wamba J, Nevitt MC, McCulloch CE, Link TM. Can signal abnormalities detected with MR imaging in knee articular cartilage be used to predict development of morphologic cartilage defects? 48-month data from the Osteoarthritis Initiative. Radiology 2016;281(01):158–167
21 Horga LM, Hirschmann AC, Henckel J, et al. Prevalence of abnormal findings in 230 knees of asymptomatic adults using 3.0 T MRI. Skeletal Radiol 2020;49(07):1099–1107
22 Kaplan LD, Schurhoff MR, Selesnick H, Thorpe M, Uribe JW. Magnetic resonance imaging of the knee in asymptomatic professional basketball players. Arthroscopy 2005;21(05):557–561
23 Walczak BE, McCulloch PC, Kang RW, Zelazny A, Tedeschi F, Cole BJ. Abnormal findings on knee magnetic resonance imaging in asymptomatic NBA players. J Knee Surg 2008;21(01):27–33
24 Kane PW, Tucker BS, Frederick R, Ciccotti MG, Freedman KB. Cartilage restoration of the patellofemoral joint. JBJS Rev 2017; 5(10):e7
25 Yoshioka H, Stevens K, Genovese M, Dillingham MF, Lang P. Articular cartilage of knee: normal patterns at MR imaging that mimic disease in healthy subjects and patients with osteoarthritis. Radiology 2004;231(01):31–38
26 Beltran J, Marty-Delfaut E, Bencardino J, et al. Chondrocalcinosis of the hyaline cartilage of the knee: MRI manifestations. Skeletal Radiol 1998;27(07):369–374
27 Bedi A, Feeley BT, Williams RJ III. Management of articular cartilage defects of the knee. J Bone Joint Surg Am 2010;92(04): 994–1009
28 Gersing AS, Schwaiger BJ, Nevitt MC, et al. Is Weight Loss Associated with Less Progression of Changes in Knee Articular Cartilage among Obese and Overweight Patients as Assessed with MR Imaging over 48 Months? Data from the Osteoarthritis Initiative. Radiology 2017;284(02):508–520

