



# Using Nonscalp Hair in Scalp Hair Restoration—Theory and Execution

Robert H. True<sup>1</sup>

<sup>1</sup>True and Dorin Medical Group, New York, New York, United States

Indian J Plast Surg 2021;54:463–470.

Address for correspondence Robert H True, MD, MPH, Diplomate American board of Hair Restoration Surgery, True and Dorin Medical Group, 499 Seventh Avenue, 24<sup>th</sup> floor, South Tower, New York, NY 10018, United States (e-mail: drtrue@hairlossdoctors.com).

## Abstract

Harvesting of beard and body hair follicles for transplantation can be an effective form of treatment for appropriate patients. These patients may have had prior scalp transplantation and require repair but do not have sufficient scalp donor follicles remaining. Other patients will have these hairs mixed with scalp hairs to produce a greater density of hair on the bald scalp. Follicular unit excision (FUE) is preferred for body and beard follicle harvesting. Not all body hair is suitable for transplantation. Only hairs that are similar in appearance and behavior to scalp hair are suitable for transplantation to the scalp. The best nonscalp sources are the beard and anterior torso. Hairs from other body sites may be used for transplantation to the eyebrows. The standard techniques of FUE harvesting and anesthesia must be modified from those used in scalp harvesting to be safe and effective. With proper patient selection and technique, a significant cosmetic benefit can be achieved from these procedures.

## Keywords

- ▶ Body hair FUE
- ▶ Beard hair FUE
- ▶ Hair Transplant Repair
- ▶ Body hair characteristics
- ▶ Minimizing transection
- ▶ Low-dose anesthesia

## Introduction

Nonscalp body hair has emerged as a reliable and valuable donor resource in hair restoration surgery.<sup>1,2</sup> Prior to the advent of follicular unit excision (FUE), reports of transplanting body hair were rare.<sup>3</sup> It was the advent of FUE that opened the door to effective use of body hair.<sup>4</sup>

We are now at the point in hair restoration surgery where assessment of beard and body hair resources should be a routine part in the initial evaluation of all male patients, and utilization of these resources must be part of overall long-term planning for patients. Beard and body hair can be used effectively throughout all stages of treatment, not just after scalp resources are exhausted.

The traditional and best source for follicles to transplant to the scalp is the scalp. However, scalp donor is a finite resource, and for patients with advanced balding, use of nonscalp donor hair will allow for denser and more extensive coverage. Use of

nonscalp hair allows for treatment of patients who have undergone previous traditional hair-restoration procedures and are in need of cosmetic repair but have no more scalp donor supply. Such cases include those who may have visible and unsightly surgical scars and/or those who have unnatural-looking transplanted hair. The advent and refinement of follicular unit excision (FUE) harvesting technology over the past two decades has opened a new avenue for the repair of these cases via harvesting and transplanting of hair follicles from nonscalp body sources.<sup>5–13</sup> The utilization of body hair also allow us to provide more coverage for patients with advanced balding and preserve scalp donor in younger patients. When transplanting a nonscalp body area, the same area's hair is best suited if present in sufficient quantity, for example, beard hair is taken from below the jawline transplanted to the cheek beard.

Experience shows that the best body donor follicles for transplantation to the scalp are those that produce hair most

published online  
December 20, 2021

DOI <https://doi.org/10.1055/s-0041-1739242>.  
ISSN 0970-0358.

© 2021. Association of Plastic Surgeons of India. All rights reserved. This is an open access article published by Thieme under the terms of the Creative Commons Attribution-NonDerivative-NonCommercial-License, permitting copying and reproduction so long as the original work is given appropriate credit. Contents may not be used for commercial purposes, or adapted, remixed, transformed or built upon. (<https://creativecommons.org/licenses/by-nc-nd/4.0/>)  
Thieme Medical and Scientific Publishers Pvt. Ltd., A-12, 2nd Floor, Sector 2, Noida-201301 UP, India

## HUMAN HAIR FOLLICLE VARIATIONS BY BODY REGION

Body Site	%Anagen	%Telogen	Anagen Duration	Telogen Duration	Density (Hairs)	Follicle Depth
Scalp	85%	15%	2-6 years	3-4 months	350/sq.cm	5-7mm
Beard	70%	30%	1 year	10 weeks	500/sq.cm	2-4mm
Upper Lip	65%	35%	16 weeks	6 weeks	500/sq.cm	1-2.5mm
Armpit	30%	70%	4 months	3 months	65/sq.cm	4-5mm
Chest/Back	30%	70%	1-2 years	3-6 months	70/sq.cm	2-5mm
Arms	20%	80%	13 weeks	5 months	80/sq.cm	2-4mm
Legs	20%	80%	16 weeks	6 months	60/sq.cm	2-4.5mm
Pubic Area	30%	70%	4 months	3 months	70/sq.cm	4-5mm
Eyebrows	10%	90%	4-8 weeks	3 months	40/sq.cm	2-2.5mm

**Fig. 1** Variations in hair cycles by body region.

similar in length, texture, and behavior to scalp hairs. The hairs of the beard and torso are generally most similar to scalp hair and so these are the preferred nonscalp donor areas. Harvesting from the extremities is infrequently useful, as these hairs are typically much finer and shorter than scalp hair and offer little cosmetic benefit. Besides, it is a common perception among experienced practitioners, including Drs John Cole and James Harris and myself, that the survival rate of extremity hair grafts can be low and unpredictable. Nevertheless, there are case reports of successful use of extremity body hair.<sup>14</sup> Body hair has also been successfully transplanted in cases of cicatricial alopecia.<sup>15,16</sup>

In the 2020 Practice Survey among members of the International Society of Hair Restoration Surgery, scalp donor hair was used in 92.5% of cases, beard hair in 7.5% of cases, and chest hair in 2.4% of cases. Use of body hair from other areas was rare, with belly 0.3%, leg 0.2%, and other 0.5%. In the vast majority of cases, the most useful of nonscalp donor areas is the beard, and the second most useful area is the anterior torso.

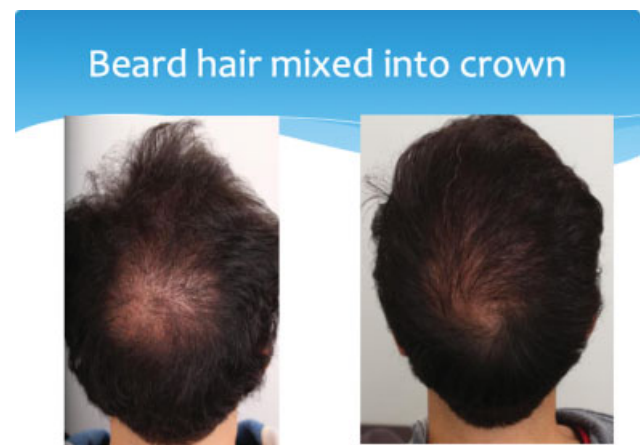### Harvesting from the Beard

There are up to 5 million hair follicles on the body. Their expression is androgen-dependent. The follicles vary widely in hair character and behavior. Body hair varies in multiple characteristics by region (see ► Fig. 1 for body hair cycles).<sup>17,18</sup>

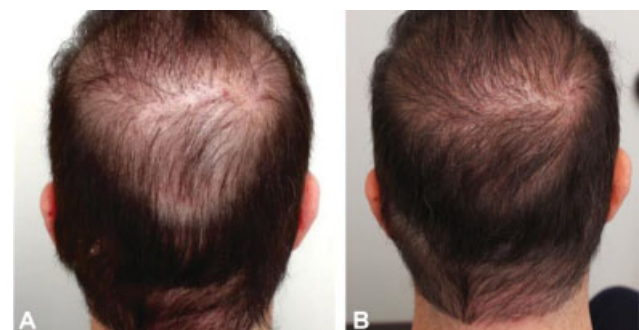
The unique characteristics of beard hair include the following: beard follicles are 70% anagen/30% telogen versus scalp which is 90% anagen/10% telogen; beard has the longest anagen phase along with scalp and the shortest telogen phase. The shortest follicles are in the upper lip and eyebrow, and the longest follicles are in the scalp, pubic region and beard. Scalp and beard have the highest density. Beard follicles are single hair FUs, with occasional 2's and 3s. They are the most robust in growth rate and shaft thickness of all body hairs, and typically beard hairs are much thicker than scalp hair and have twice as many cuticle layers.<sup>19</sup> Because of these characteristics, beard hair is not suitable for transplantation to the hairline or temple regions. It is best used when mixed among transplanted scalp hairs in the rear

frontal zone, midscalp, and crown (► Fig. 2). Only in instances where the scalp and beard hairs are very similar should the beard hairs be placed alone in a recipient area (► Fig. 3 a, b). Beard hairs are also useful in transplanting scalp donor scars and when increasing local beard hypodensity.

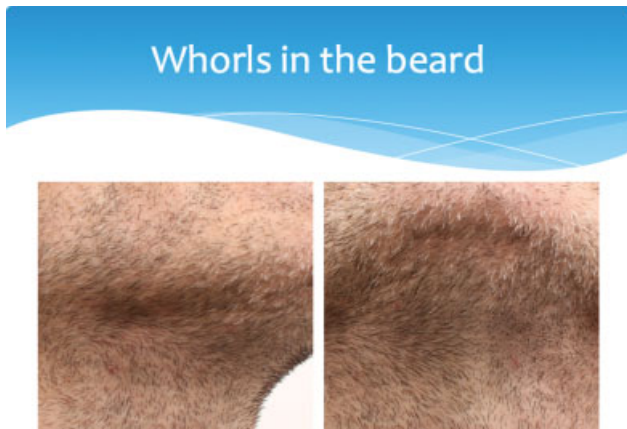
Beard hairs vary widely in the angle and direction of hair emergence, even in the same patient. Hair grows inferiorly along the mandible, but very commonly, there are whorls located on the neck below the mandible. Hairs below the tuberculum mentale grow inferiorly toward the neck, but the



**Fig. 2** Beard hair mixed with transplanted scalp hairs.



**Fig. 3** (A, B) Beard hairs placed alone in the lower vertex (scalp and beard hair with similar characteristics).



**Fig. 4** Beard hair orientation.

follicles then begin to radiate in a spiral toward the angle of the mandible. Further, if whorls are present (and they often are), then the angle of hair direction changes 360 degrees, and the hair grows in a superior direction in the beard area of the neck (►Fig. 4). Follicles along the lower margin of the mandible and in the submental region have the most obtuse angle of emergence, whereas those on the neck and face have the most acute emergence angle. Therefore, the direction and angle of punch insertion must constantly be adjusted when extracting from the beard. All of these changes of hair direction present challenges to the surgeon, in that there needs to be not only frequent changes of position both for the surgeon and the patient, but also frequent changes of hand position, which can contribute to incorrect alignment and increased transection.

### Harvesting Torso Hair

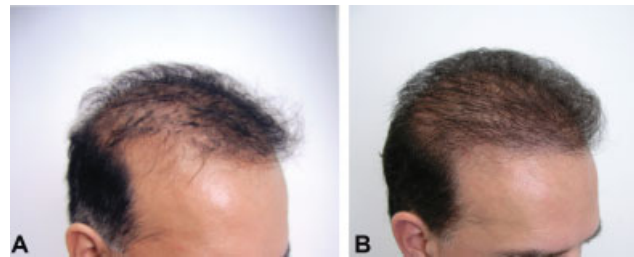Some ethnicities genetically have little torso hair to harvest. It is rare for a woman of any race to have much torso hair. There is also wide variance in torso hair among men. Interestingly, for men, torso hair increases in the sixth decade of life. Torso hair has a low anagen to telogen ratio (30%/70%) and anagen is shorter than scalp hair (1–2 years) and telogen longer (3–6 months).

It is possible to provide a rational framework for determining the candidacy for torso-to-scalp FUE.<sup>20</sup>

There are five characteristics to consider when evaluating torso hair as the donor for hair transplant: (1) density which may be more than 40 FU/cm<sup>2</sup>, (2) similarity between scalp and torso hair, (3) proportion of 2 to 3 hair FUs (which may be greater than 30%), (4) the size of the hair-bearing area, and (5) the maximal length of the torso hair. Each patient is rated from 0 to 2 for each of these five characteristics and the sum is added to determine their torso donor index (TDI) score, as shown in ►Fig. 5. Those with TDI scores of 8 to 10 are ideal candidates. They have a great supply of follicles that produce hair similar to scalp hair.<sup>5</sup> It should be noted that even for these ideal candidates, the torso hair still does differ from scalp hair in texture, maximum length, and hair cycle. Torso hair characteristics are better than the beard for transplantation to the hairline and temples (►Fig. 6).

TORSO DONOR INDEX (TDI)				
	0	1	2	Score
DENSITY	<20 fu/cm <sup>2</sup>	20 - 40 fu/cm <sup>2</sup>	>40 fu/cm <sup>2</sup>	
TEXTURE	Very Different	Somewhat Similar	Very Similar	
2-3 HAIR FUs	<20%	20 -30%	>30%	
SURFACE AREA	< 50 cm <sup>2</sup>	50 - 200/ cm <sup>2</sup>	> 200 cm <sup>2</sup>	
HAIR LENGTH	<2cm	2 - 5 cm	>5cm	
Total				

**Fig. 5** Torso donor index (TDI) scoring table.



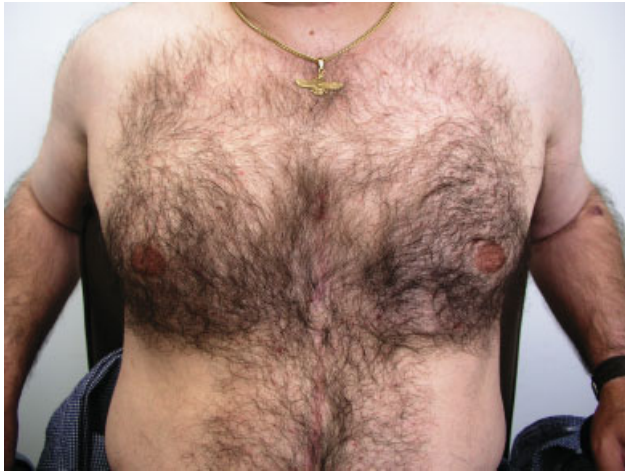**Fig. 6** (A, B) Repair using torso hair.

Whorls are also typically present in the chest area. The hairs on the chest, starting from the skin overlying the superior sternum area, emerge in a radial pattern, spiraling clockwise on the right and counterclockwise on the left over and around the pectorals. The hairs directly overlying the sternum are directed inferiorly. Torso hairs exit the skin and lie in the dermis in very flat angles. The hairs overlying the sternum have the least acute angle of emergence, whereas those superior, lateral, and inferior to the nipple of the breast are most acute (►Fig. 7).

### Technique for Beard and Torso Harvesting

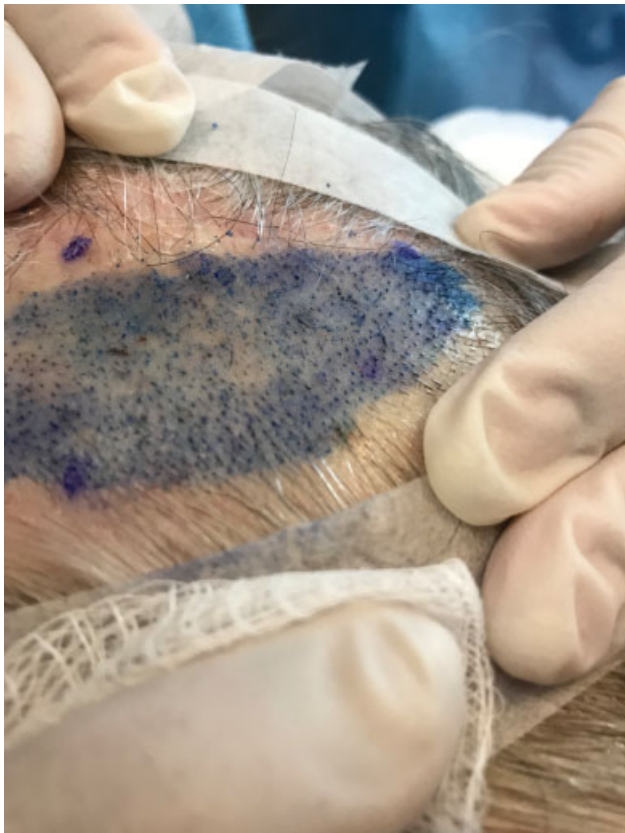#### Patient Preparation

- Patients are instructed to wet shave the chest and abdomen 5 days before the procedure, and for the beard, 4 days before. When they present for surgery, anagen hairs will have grown to an ideal length for extraction. This approach has been well-described by Poswal.<sup>21</sup>
- If we are harvesting from or transplanting to the beard, we will have patients with a history of recurrent oral herpes take 3 days of valacyclovir as prophylaxis, beginning the morning of the procedure.
- Patients wash the beard and torso with chlorhexidine the morning of the procedure, and a topical antiseptic is applied to each area just prior to beginning excisions. The patients may apply topical prilocaine/lidocaine covered with plastic wrap 2 hours before the procedure, which diminishes the pain of anesthesia injection.



**Fig. 7** Chest hair orientation.

- If the beard or torso contain white hairs, we apply 2% methylene blue intraoperatively. When it is dry wiped, the white hairs and their entry points into the skin are easily seen (►**Fig. 8**). With this approach, it is not necessary to apply hair dyes before the procedure. Hair dyes contain many chemicals, some are potentially cytotoxic, and if the dye is not completely removed from the skin, it may bleach into the graft holding solution, potentially damaging the grafts. Some patients will also experience contact dermatitis with hair dyes, which is avoided by methylene blue.



**Fig. 8** Methylene blue staining for white hair.

- We give oral sedation with diazepam, 5 mg p.o. and 5 mg s. l. prior to initiating anesthesia.

### Anesthesia for Beard and Torso

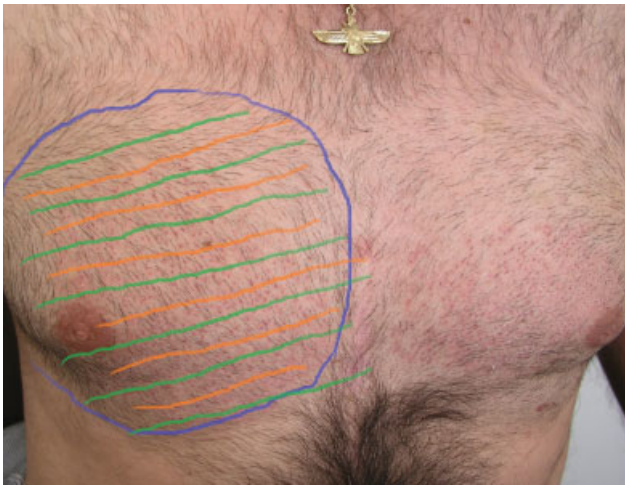
The technique of anesthesia is critical to both the comfort and safety of the procedure. The face is a particularly sensitive area which experiences pain when with local anesthesia is injected. When anesthetizing the beard area, we start with a mental nerve block, which anesthetizes the chin. We then advance the anesthesia laterally and inferiorly onto the neck. Pinching and elevating the skin during injection reduces discomfort. Giving the patient small inhalations of 50/50 nitrous oxide and oxygen prior to injection also makes anesthesia much more comfortable. The use of microcannulas for injection further diminishes injection pain. The author uses 4% articaine diluted 3 to 1 with normal saline. After anesthesia is achieved, the harvest field may be painlessly superficially injected with a solution made with 200 mL normal saline, 40 mg triamcinolone, and 1 mL of 1:1000 epinephrine. This solution reduces bleeding, swelling, and postoperative itching.

Ring blocks are ineffective on the torso. A field block is required, but because the areas are large and the subcutaneous tissue very porous, with standard local anesthesia, it is possible to administer large amounts of anesthetic when harvesting large torso areas, pushing the limit of a safe total dose. To reduce the amount of local anesthetic administered, we dilute 4% articaine 3:1 with saline and superficially (just beneath the epidermis) inject parallel lines 1 cm apart. While pinching and elevating the skin, the needle or microcannula is advanced slowly, beginning each injection within the margin of the previous injection. Saline is injected between these lines superficially in the same way. This technique will produce anesthesia lasting hours with a minimal amount of total anesthesia dosage (►**Fig. 9**).

### FUE Harvesting Technique for Beard and Torso

Although sharp punch manual and motorized techniques can be used, the author prefers to use two motorized FUE systems, the WAW by Devroye instruments and the Trivellini Instruments Nano device for all body hair graft excisions. The punches vary in diameter from 0.8 mm to 0.9 mm. The punch diameter that will give the lowest transection rate and create the smallest excision site wound is selected. When follicles are very large, a larger punch is selected to minimize transection. The difference in the size of the hypopigmented area in the healed excision site varies negligibly with punch sizes in this range. In my opinion, the best punches currently being manufactured are the serrated-edge hybrid punches produced by Devroye Instruments and the Edge Out and flared-tip punches of Trivellini Instruments. These are punches that are designed to be "follicle-sparing," in that they do not expose the deep portions of the follicles to a cutting edge and help to reduce transection while using smaller diameter punches.

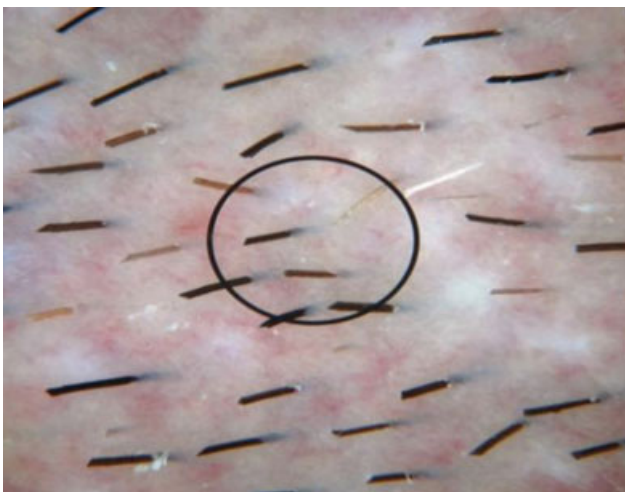
Anagen follicles can be identified with 4.5X or higher surgical loupes as having a blush of color within the



**Fig. 9** Anesthesia for torso harvest. Blue line indicates field perimeter, green lines indicate diluted articaine lines 1 cm apart, and orange lines indicate normal saline injected in lines between the articaine lines.

epidermis that extends deeper than the point of the hair shaft entry into the skin (**Fig. 10**). When inserting the punch, it must be aimed and centered on this point, that is, the point at which the blush of color disappears within the epidermis, not on the point of exit of the hair from the skin. This is an important detail. This approach reduces the transection rate during follicle excision. Beard and torso follicles do not curl beneath the epidermis, so the external curl should be ignored in directing the punch. Cutting the external hair 1 mm or less in length is ideal. Many practitioners have patients begin applying topical minoxidil daily 4 to 6 weeks before the procedure to maximize the percentage of follicles in anagen phase, thus increasing the potential graft harvest number.<sup>22,23</sup>

When using hybrid and edge-out punches, punch insertion has two phases. In the first, the punch is held firmly against the epidermis while the punch movement cuts the epidermis. In the second phase, the punch is advanced by its



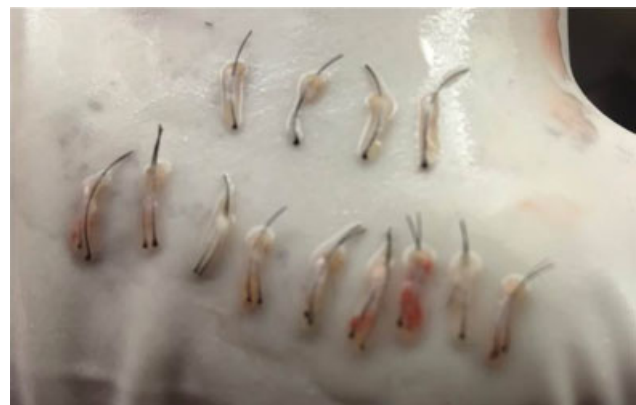**Fig. 10** Magnified view of anagen torso follicles showing the visible "blush of color" portion within the epidermis.

motion and light insertion pressure as it penetrates deeper. The angle of the follicle in the dermis can be verified by superficially scoring a few grafts, lifting them, and observing the follicle course and angle. The punch only needs to be inserted 2.0 to 2.5 mm for both beard and torso. The tethering forces of the torso and beard skin are much less than with scalp hair; thus, the excisions do not need to be as deep to free the follicles for extraction.

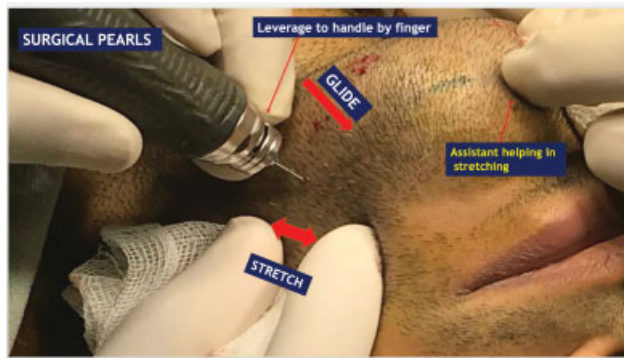
Follicles extracted from the torso and beard have very little supportive fatty or connective tissue (**Fig. 11**); they are very fragile and require constant hydration and minimal manipulation. Therefore, harvesting and graft placement is done in batches of 300 to 500 grafts to assure minimum time out of body. To promote the best possible survival, grafts are immediately transferred to HypoThermosol, mixed with liposomal ATP (10:1 ratio), and maintained at 8 °C until placed. Because the grafts are very easily desiccated and traumatized during insertion, only our most experienced placers insert the grafts. There must be a very light touch with a single movement for insertion. Grafts are grasped with the forceps away from the bulbs to reduce risk of crush injury. Recipient sites must always be tested at the beginning of the procedure and size adjusted to assure atraumatic insertion. The use of graft implanters may offer the least traumatic method for FUE body hair graft insertion.

As mentioned above, it is best to use shallow punch insertions, unusually shallower than with scalp hair harvesting, because even though beard follicles are typically in the 4 to 5 mm or more length range, the tethering forces are much weaker than in the scalp. Torso hairs may not be as long as scalp hairs, but again shallow insertions are sufficient to free the grafts while decreasing the transection rate associated with deeper punch insertions. Target the anagen hairs. Providing stretching and tensioning of the skin during graft excision and extraction is very important (**Fig. 12**). This is more important than tumescence. Tumescence to large areas is not effective, as it disperses too rapidly.

Injecting tumescence into a 2 to 4 cm area just before excision is started in the area and does last long enough to aid excision to some extent. The process is repeated when moving to each new harvest area.



**Fig. 11** Typical torso hair grafts.



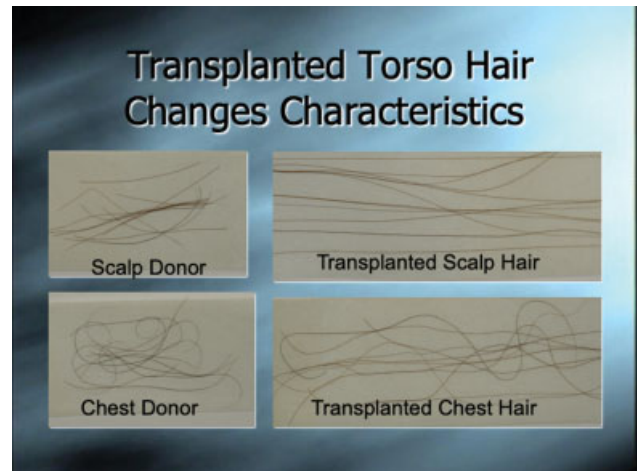**Fig. 12** Stretching of skin.

Patient positioning is a challenge for body hair extraction. For the beard, we have the patient lie in three positions: left lateral decubitus, right lateral decubitus, and supine with the neck draped over a support that hyperextends the area below the chin and neck. When harvesting the chest and abdomen, the patient is once again supine. It is helpful to place a support under one side of the back, so that the patient is rolled slightly toward the surgeon with the assistant on the other side of the table. We elevate the table, so that we can stand comfortably with minimal stress on our necks and backs. In both the beard area under the chin and in the pectoral regions, the follicles are often oriented in whorls. The surgeon must be attentive to the changes in follicle orientation and make frequent adjustments in the direction and angle of punch insertion.

Much is made about the transection rate in FUE. With proper equipment, that is, hybrid punches, of the proper size and design, inserted at the correct angle and level, rotating or oscillating with the correct speed and force, transection rates will be low.

Survival rate is even more important than transection rate.<sup>24</sup> Graft storage and handling and atraumatic insertion are key to good yields. We always tell the patient that the first session of body hair extraction is, in a way, a test. The ease of extraction, graft yield, donor-site healing, and the likelihood of success with further treatment will be determined. Accordingly, usually this first session size does not exceed 1,000 grafts. With beard excision, in the initial session, the excisions are confined to under the jaw line, so that if the patient does heal with any visibility of the extraction sites, there should not be a noticeable cosmetic problem.

While the genetics of the donor follicle are dominant in hair transplantation, the recipient area exerts influence on graft survival and behavior.<sup>25</sup> There is a significant difference between the thickness of the dermis of the scalp and body. It may be that these recipient-tissue differences may prevent reliable survival of follicles transplanted from a much different body-site environment. For this reason, it is essential to give realistic expectations to a patient, and the first body hair transplant (BHT) session should always be conservative in nature and presented to the patient as a test. If good survival is not achieved in this first session, further BHT is ill advised. If survival is good, there is a basis to continue with further sessions with relative confidence. There is some recipient-



**Fig. 13** Change in character of torso hair transplanted to scalp (recipient influence).

site influence on the character of the body hair follicles transplanted to the scalp.<sup>20,26</sup> Torso hairs tend to lose some degree of their wave and curl and may grow slightly longer hairs (► **Fig. 13 A, B**) Beard hairs retain most of their native characteristics. The native hair cycle of transplanted body follicles is retained, so that there may be greater fluctuations of density over time than seen with transplanted scalp hair. It is also important to keep in mind that torso and body hairs are largely androgen-dependent.<sup>27</sup> If, later in life, the testosterone levels drop, there may be a loss of transplanted torso hairs. Patients should always be advised that the long-term viability and cycling behavior of body hairs transplanted to the scalp is yet to be determined.

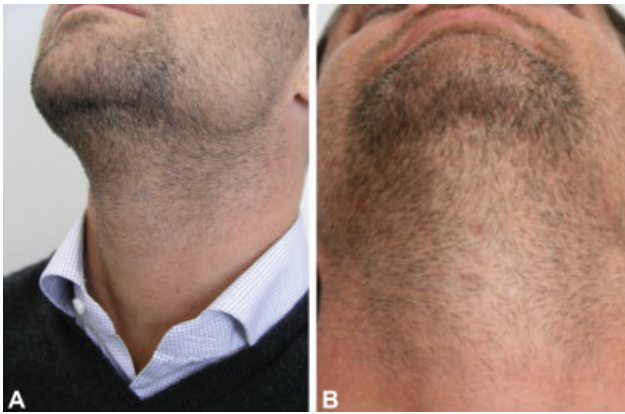### Postoperative Care

At the end of the procedure, we apply a coat of Aquaphor (liquid petrolatum) to the excision sites, and the patient is instructed to continue to apply the Aquaphor two to three times daily in the first 4 postoperative days. A light gauze dressing is applied, and the patient is instructed to wet and remove the dressing the morning after the procedure. Thereafter, the patient is asked to wash the area with soap and water twice daily. The use of Aquaphor minimizes any crusting of the excision sites and speeds healing. After 4 days, twice daily application of moisturizer helps to reduce itching and drying as the skin continues to heal. It is rare for the patient to have any significant pain in the donor area postoperatively. Typically, over-the-counter nonsteroidal anti-inflammatory steroids (NSAIDs) are all that is required. Prophylactic antibiotics are of unproven value.

### Complications

Potential complications with nonscalp FUE are similar to those with scalp FUE and include shock loss, graft burying and ingrown hairs and cysts, hypo and hyperpigmentation, hypertrophic scarring, and temporary facial paresis.

Typically, the healed beard-extraction sites are not distinctly visible, and hypopigmentation is not an issue using today's small diameter punches, with the possible exception

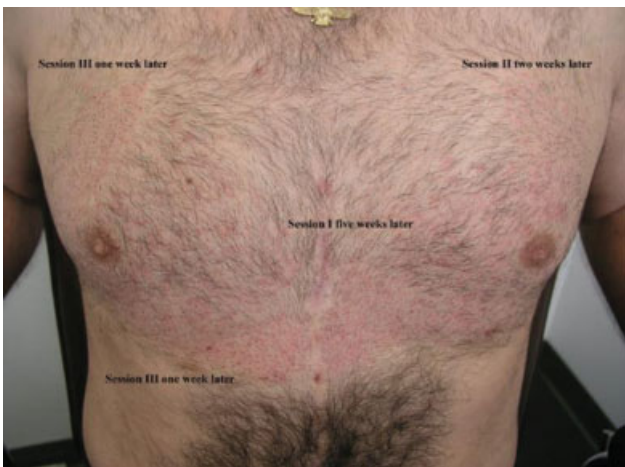

**Fig. 14** (A, B) Healing of beard excisions.

of very dark-skinned patients. The beard area simply looks less dense (► **Fig. 14 A, B**).

On the torso, hypopigmentation occurs to a somewhat greater extent, but the excision sites are still not typically visible, particularly if body hair remains in the area (► **Fig. 15**). It is important to note that in torso hair, at any point in time, many of the follicles are in telogen phase. So that, even when you think you have taken all of the hair, a lot still grows back. It is best to caution patients that if they tan, there may be a more mottled appearance to their torso. There have been case reports of hypertrophic healing with harvesting over the sternum and in the beard area. The author has not seen this in his practice. Perhaps this is due to the fact that our practice involves injecting a dilute solution containing triamcinolone at the time of the procedure.

In beard harvest patients, temporary lower facial paresis can occur and last 4 to 6 hours after surgery before fully resolving. The cause is likely a combination of migration of local anesthetics to the mandibular branch of the facial nerve and firm pressure applied over the course of the nerve during harvesting along the jaw line. To our knowledge, there are no reported cases of permanent partial facial paresis arising from beard FUE. Nevertheless, the risk of experiencing temporary facial paresis is common enough to warrant



**Fig. 15** Stages of torso healing after follicular unit excision (FUE) and torso 7 months after harvesting 3000.

including it in informed consent for patients undergoing beard FUE.

In the technique described, we have not seen patients with postoperative swelling, loss of sensation, inclusion cysts, buried grafts, or infections. These problems have been reported by others using different techniques.

Unique issues may occur when harvesting from extremities. One of the worst complications I have seen was an attractive young woman who went to another clinic for eyebrow transplantation. The doctor decided to harvest hair from the lower anterior legs using FUE. She developed swelling and an anterior compartment syndrome. She ended up with large necrotic areas on both legs which required skin grafting.

## Summary

Beard and body hair harvesting is now an established component of hair restoration surgery. Nonscalp donor follicles can be used to achieve greater coverage and density for those with extensive balding. They also can be used in corrective cases with depleted scalp donor supplies. With proper technique, success rates are high.

### Conflict of Interest

None declared.

## References

- 1 True R. FUE from the Beard and Body. In: Lam S, Williams K, eds. *Hair Transplant: Follicular Unit Extraction*. 11th ed. Vol. 4. New Delhi India: Jaypee Brothers Medical Publishers (P) Ltd; 2016: 417–34
- 2 True RH. The beard issue. *Hair Transplant Forum International* 2015;25(04):133
- 3 Brandy DA. Chest hair used as donor material in hair restoration surgery. *Dermatol Surg* 1997;23(09):841–844
- 4 Woods R, Campbell AW. Chest hair micrografts display extended growth in scalp tissue: a case report. *Br J Plast Surg* 2004;57(08): 789–791
- 5 Rassman WR, Bernstein RM, McClellan R, Jones R, Worton E, Uyttendaele H. Follicular unit extraction: minimally invasive surgery for hair transplantation. *Dermatol Surg* 2002;28(08): 720–728
- 6 True RH. Harvesting beard hair for scalp transplantation. *Hair Transplant Forum International* 2015;25(04):155–156
- 7 Yu J, Yu A. Beard to scalp. In: Unger W, Shapiro R, Unger R, Unger M, eds. *Hair transplantation*. 5th ed. New York: Informa Healthcare; 2011:299–303
- 8 Mysore V. Body hair transplantation: case report of successful outcome. *J Cutan Aesthet Surg* 2013;6(02):113–116
- 9 Saxena K, Savant SS. Body to scalp: evolving trends in body hair transplantation. *Indian Dermatol Online J* 2017;8(03):167–175
- 10 Zhu DC, He Y, Fan ZX, et al. Large-scale beard extraction enhances the cosmetic results of scalp hair restoration in advanced androgenetic alopecia in East Asian men: a retrospective study. *Dermatol Ther (Heidelb)* 2020;10(01):151–161
- 11 Poswal A. Use of body and beard donor hair in surgical treatment of androgenic alopecia. *Indian J Plast Surg* 2013;46(01):117–120
- 12 Mahadevia B. Donors other than scalp: beard and chest. In: Mysore V, ed. *Hair Transplantation*. New Delhi India: Jaypee Brothers Medical Publishers (P) Ltd; 2016:307–312
- 13 Umar S. The transplanted hairline: leg room for improvement. *Arch Dermatol* 2012;148(02):239–242

- 14 Saxena K, Saxena DK, Savant SS. Successful hair transplant outcome in cicatricial lichen planus of the scalp by combining scalp and beard hair along with platelet rich plasma. *J Cutan Aesthet Surg* 2016;9(01):51–55
- 15 Meyer-Gonzalez T, Bisanga C. [Body-hair transplant for cicatricial alopecia]. *Actas Dermosifiliogr* 2012;103(02):163–164
- 16 Saitoh M, Uzuka M, Sakamoto M. Human hair cycle. *J Invest Dermatol* 1970;54(01):65–81
- 17 Paus R, Cotsarelis G. The biology of hair follicles. *N Engl J Med* 1999;341(07):491–497
- 18 Tolgyesi E, Coble DW, Fang FS, Kairinen EO. A comparative study of beard and scalp hair. *J Soc Cosmet Chem* 1983;34:361–382
- 19 Cole J. Body hair. Paper presented: at European FUE Society Annual Workshop; June 2016; Brussels, Belgium
- 20 True, RH. Torso to scalp hair transplantation. Paper presented at: World Congress of the International Society of Hair Restoration Surgeons; October 2006; San Diego, CA
- 21 Poswal A. The preshaving protocol in body hair-to-scalp transplant to identify hair in anagen phase. *Indian J Dermatol* 2010;55(01):50–52
- 22 Umar S. Use of body hair and beard hair in hair restoration. *Facial Plast Surg Clin North Am* 2013;21(03):469–477
- 23 Messenger AG, Rundegren J. Minoxidil: mechanisms of action on hair growth. *Br J Dermatol* 2004;150(02):186–194
- 24 Gupta J, Chouhan K, Kumar A, Chandrasegaran A. A comparative study on the rate of anagen effluvium and survival rates of scalp, beard, and chest hair in hair restoration procedure of scalp. *J Cutan Aesthet Surg* 2019;12(02):118–123
- 25 Orentreich N. Autografts in alopecias and other selected dermatological conditions. *Ann N Y Acad Sci* 1959;83:463–479
- 26 Hwang ST, Kim HY, Lee SJ, Lee WJ, Kim DW, Kim JC. Recipient-site influence in hair transplantation: a confirmative study. *Dermatol Surg* 2009;35(06):1011–1014
- 27 Randall VA. Androgens and human hair growth. *Clin Endocrinol (Oxf)* 1994;40(04):439–457