



Surgical Treatment of Multilevel Degenerative Cervical Myelopathy: Open-Door Laminoplasty and Fixation via Unilateral Approach. A Feasibility Study

Gregor Schmeiser¹ Janina Isabel Bergmann¹ Luca Papavero¹ Ralph Kothe²

¹Department of Spine Surgery, Schoen-Klinik Hamburg-Eilbek, Hamburg, Germany

²Clinic for Spine Surgery, Schoen Clinic Hamburg Eilbek, Academic Hospital of the Eppendorf University Medical Center, Hamburg, Germany

Address for correspondence Gregor Schmeiser, Department of Spine Surgery, Schoen-Klinik Hamburg-Eilbek, Hamburg, Germany (e-mail: GSchmeiser@schoen-klinik.de).

J Neurol Surg A Cent Eur Neurosurg 2022;83:494–501.

Abstract

Objective We compared open-door laminoplasty via a unilateral approach and additional unilateral lateral mass screw fixation (uLP) with laminectomy and bilateral lateral mass screw fixation (LC) in the surgical treatment of multilevel degenerative cervical myelopathy (mDCM).

Methods A retrospective cohort analysis of 46 prospectively enrolled patients (23 uLP and 23 LC). The minimum follow-up was 1 year. Neck and arm pains were evaluated with visual analog scales and disability with the Neck Disability Index (NDI). Myelopathy was rated with the modified Japanese Orthopaedic Association (mJOA) score. Cervical sagittal parameters were measured on plain and functional X-ray films with a specific software. The statistical significance was set at $p < 0.05$. Fusion was defined as < 2 degrees of intersegmental motion on flexion/extension radiographs.

Results The two groups were similar in age and comorbidities. The mean operation time and the mean hospital stay were shorter in the uLP group ($p = 0.015$). The intraoperative blood loss did not exceed 200 mL in both groups. At follow-up, the groups showed comparable clinical outcome data. The sagittal profile did not deteriorate in either group. Fusion rates were 67% in the uLP group and 92% in the LC group. No infections occurred in either group. In the LC group, one patient developed a transient C5 palsy. Revision surgery was required for a malpositioned screw (LC) and for one implant failure (uLP).

Conclusion Laminoplasty and unilateral fixation via a unilateral approach achieved comparable clinical and radiologic results with laminectomy and bilateral fixation, despite a lower fusion rate. However, the surgical traumatization was less.

Keywords

- ▶ cervical myelopathy
- ▶ laminoplasty
- ▶ laminectomy
- ▶ Lateral mass screws

received
December 21, 2020
accepted after revision
April 23, 2021
published online
December 15, 2021

DOI <https://doi.org/10.1055/s-0041-1739224>.
ISSN 2193-6315.

© 2021. The Author(s).

This is an open access article published by Thieme under the terms of the Creative Commons Attribution-NonDerivative-NonCommercial-License, permitting copying and reproduction so long as the original work is given appropriate credit. Contents may not be used for commercial purposes, or adapted, remixed, transformed or built upon. (<https://creativecommons.org/licenses/by-nc-nd/4.0/>)

Georg Thieme Verlag KG, Rüdigerstraße 14, 70469 Stuttgart, Germany

Introduction

Degenerative cervical myelopathy is the leading cause of spinal cord dysfunction worldwide.¹ The goals of surgical treatment are effective decompression, preservation or restoration of the cervical lordosis, and fixation of the unstable cervical spine. In patients with multilevel impingement of the spinal cord, laminoplasty and laminectomy with fixation and fusion are widely accepted treatment options.² A recent systematic review showed that both procedures provide similar clinical outcomes. In 2000, Roselli et al described a laminoplasty technique via a unilateral approach to decrease the surgical traumatization of the neck muscles.³ In 2004, we adopted this technique for posterior cervical decompression with additional fixation and fusion. The preliminary results showed an improved clinical outcome with respect to neck pain. Furthermore, the degree of postoperative cervical kyphosis and range of motion (ROM) compared well with that of the conventional laminoplasty technique requiring bilateral muscle dissection. However, in our experience the less invasive unilateral lateral mass screw fixation (uLP) was indicated only in patients with preserved lordotic cervical alignment, no segmental instability, and no, or only moderate, neck pain. Otherwise, we chose the bilateral approach for conventional lateral mass screw fixation (LC). Postoperative C5 palsy is a well-known complication of multisegmental cervical decompression, but the pathologic mechanism is still poorly understood. Recent studies have shown a higher incidence of C5 palsy following laminectomy and fusion, compared with laminoplasty.^{4,5} This might be partly due to the excessive dorsal shift of the spinal cord. Theoretically, laminoplasty could combine the advantages of an effective posterior open-door decompression with additional fixation decreasing the risk of postoperative kyphosis. Both goals could be achieved with less surgical traumatization of the neck muscles. A similar concept has been recently described by Liu et al, who suggested unilateral laminoplasty with unilateral stabilization as a novel technique in patients with ossification of the posterior longitudinal ligament.⁶ In the present study, the clinical and radiologic outcomes of

patients treated with uLP were compared with that of patients who underwent LC.

Materials and Methods

Between April 2013 and May 2018, 23 patients affected by multilevel degenerative cervical myelopathy (mDCM) were prospectively enrolled and treated with uLP. The control group was an age-matched cohort of patients who underwent LC. Inclusion criteria were minimum age (18 years at the time of surgery), clinical diagnosis of DCM, and multilevel stenosis (>2 levels) of the subaxial cervical spinal canal. Exclusion criteria were fixed cervical kyphosis >10 degrees, previous cervical spine surgery, tumors, fractures, and infections of the cervical spine. Demographic data, the American Society of Anesthesiologists (ASA) physical status classification, and the number of surgical levels were documented. The clinical outcome was assessed with the modified Japanese Orthopaedic Association (mJOA) score (total points = 17). The neurologic function recovery rate (i.e., improvement ratio) was calculated as follows: $(\text{JOA score at follow-up} - \text{preoperative JOA score}) / (17 - \text{preoperative JOA score}) \times 100 (\%)$.⁷

All patients had provided written consent to participate in the internal hospital registry.

Surgical Procedures

The surgical goals were the direct and indirect (by dorsal shift) decompression of the cervical spinal cord via a posterior approach, along with preservation or restoration of the cervical lordosis.

Unilateral Laminoplasty and Fixation

In the conventional "open-door" laminoplasty, the neck muscles are dissected on both sides. After a laminotomy on the opening side, a monocortical trough is drilled on the hinge side to weaken the laminae. The "opening of the door" is stabilized with specific titanium mini-plates. In the laminoplasty via a unilateral approach, the same opening is achieved by elevating on the approach side the cut lamina

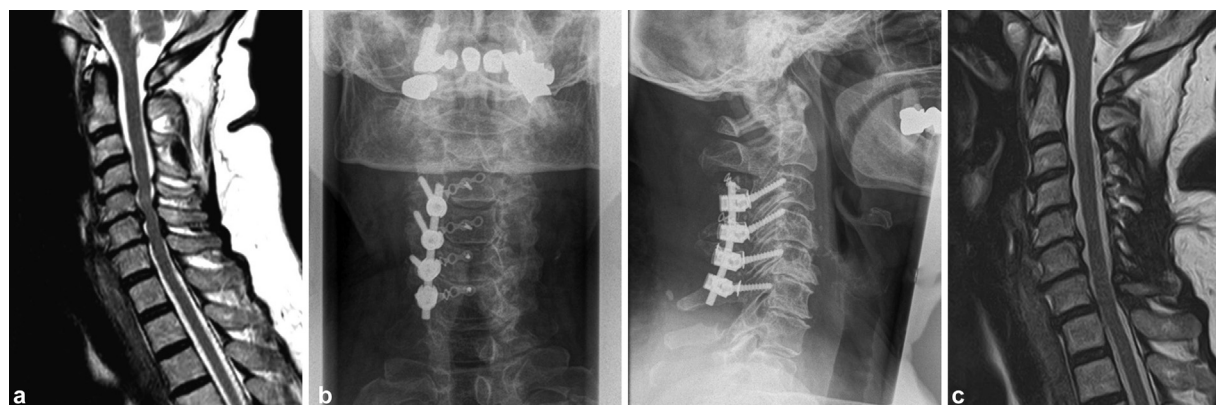

Fig. 1 Clinical case of unilateral laminoplasty and stabilization in a 63-year-old male patient, with multisegmental degenerative cervical myelopathy. The preoperative modified Japanese Orthopaedic Association (mJOA) score was 12/17, whereas the postoperative mJOA was 16/17. (a) Preoperative sagittal T2 magnetic resonance imaging (MRI). (b) Postoperative anteroposterior (left) and sagittal (right) X-rays. (c) Postoperative sagittal T2 MRI.

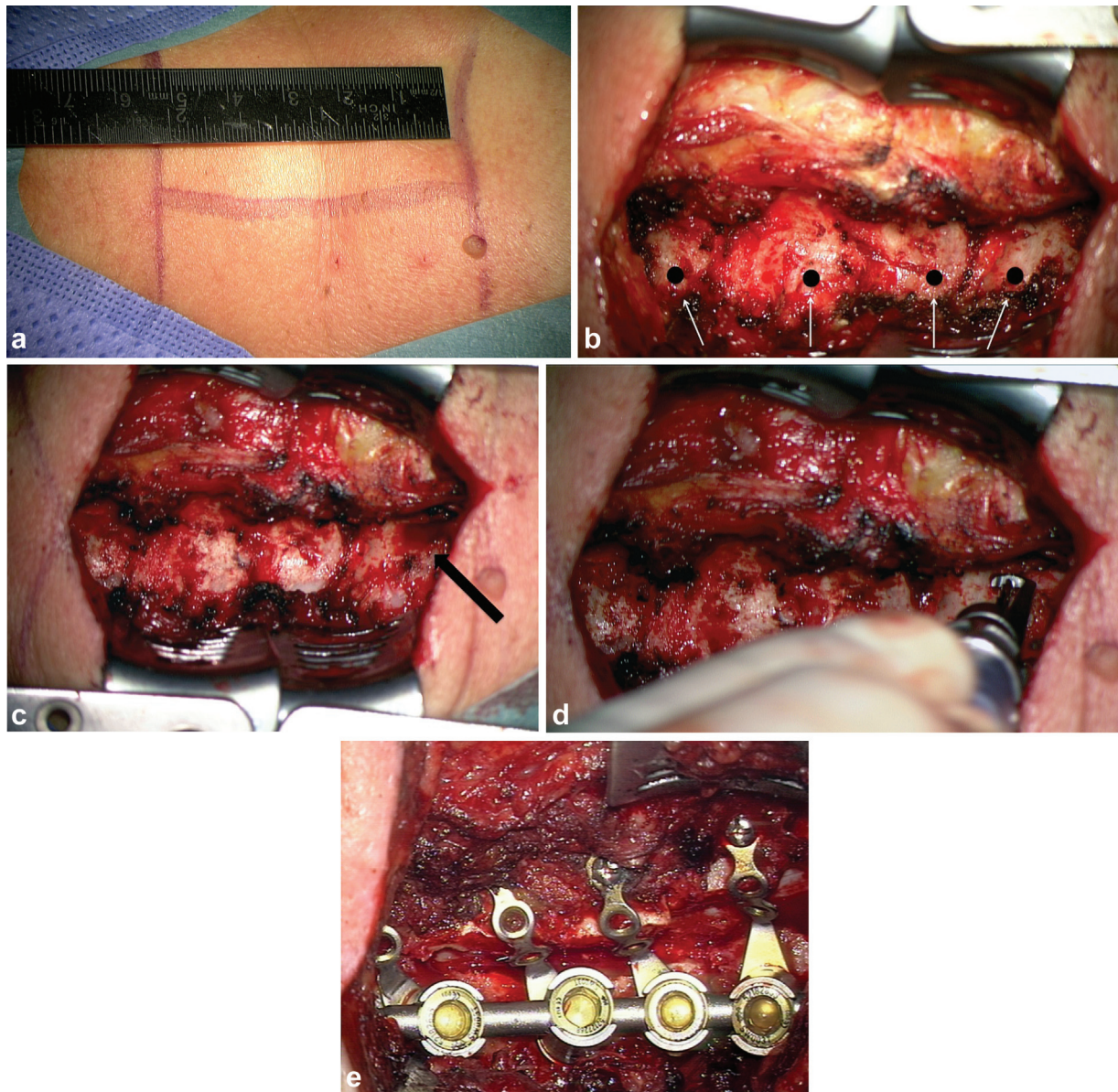


Fig. 2 Clinical case of unilateral laminoplasty and stabilization in a 63-year-old male patient with multisegmental degenerative cervical myelopathy. The preoperative modified Japanese Orthopaedic Association (mJOA) score was 12/17, whereas the postoperative mJOA score was 16/17. (a) Skin incision. (b) Lateral mass (LM) after hole preparation for LM screws (arrows). (c) Preparation of the entry point at the lamina of C6 with a punch (arrow). (d) Laminotomy performed with a baby craniotome. (e) LM screw instrumentation and plate fixation after laminoplasty.

until it “fractures” (resistance loss) at the contralateral lamina–facet junction. This is accomplished by gripping the lamina with a punch and simultaneously applying force on the spinous process with the thumb. Thus, the median ligament complex and the neck muscles on the hinge side are preserved. Typically, the opening encloses the four laminae from C6 to C3. Furthermore, an undercutting is performed at the cranial and caudal ends to provide a smooth dorsal shift of the spinal cord. In this study, the unilateral open-door laminoplasty was followed by a uLP via the same approach side (►Figs. 1 and ►Video 1). The fixation was performed with the S4 Cervical System (Aesculap AG, Tuttlingen, Germany). The 3.5-mm lateral mass screws were 14 to 18 mm long. The custom-made mini-plates (Medicon eG,

Tuttlingen, Germany) featured the last lateral hole larger to allow for the passage of the lateral mass screw.

Laminectomy and Bilateral Fixation

The conventional laminectomy and bilateral fixation was performed via a midline approach (►Fig. 3). First, a subperiosteal incision exposed the laminae and the lateral masses. Care was taken to cut the nuchal ligament in its avascular zone to prevent postoperative bleeding and muscle atrophy. Next, the lateral mass screws were inserted with the help of lateral fluoroscopy. After fixation of the screw–rod system, a trough was drilled in the laminae medially to it on both sides. The laminae were removed en bloc. All fixations were performed with the same hardware used in the study group.

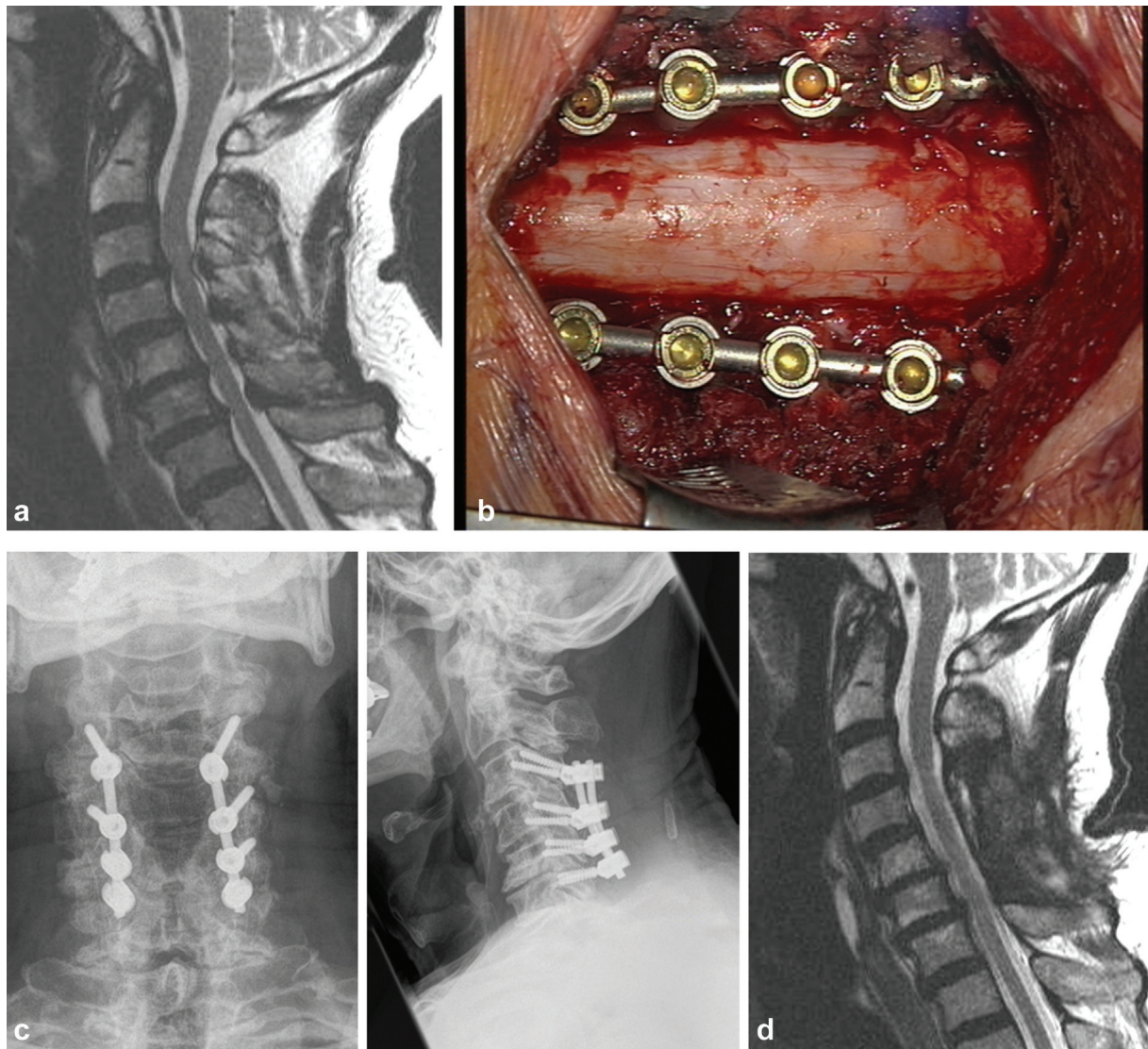


Fig. 3 Clinical case of a laminectomy with bilateral stabilization in a 67-year-old female patient with multisegmental degenerative cervical myelopathy. The preoperative modified Japanese Orthopaedic Association (mJOA) score was 10/17 and the postoperative mJOA score was 14/17. (a) Preoperative sagittal T2 magnetic resonance imaging (MRI). (b) Intraoperative situs. (c) Postoperative anteroposterior (*left*) and sagittal (*right*) X-rays. (d) Postoperative sagittal T2 MRI.

Postoperative Treatment

All patients were treated according to the same protocol: low-dose opioid analgesia, antibiotics 30 minutes before and up to 24 hours after surgery, mobilization the day after surgery, and no collar.

Clinical Outcome

Follow-up examinations were performed at 3 and 12 months. The clinical scores were compared with the preoperative status of the patient and with the clinical performance of patients of the other group.

Radiologic Outcome

Plain and flexion/extension radiographs were performed preoperatively and at 3 and 12 months after surgery. The cervical sagittal balance was defined by the following parameters: sagittal view of the vertical axis, C1–C7 Cobb angle, C2–C7 Cobb angle, C0–C2 Cobb angle, C7 slope, and the range of

motion (ROM) for C3–C7. The measurements were performed by an independent Imaging Software Laboratory (Raylytic GmbH, Leipzig, Germany). An automated and validated software was applied for unbiased and extremely accurate analysis.

Statistical Analysis

Data were analyzed with descriptive and inferential statistics (*t*-test, one-way analysis of variance [ANOVA], and $\alpha = 0.05$). Fusion was defined as intersegmental motion < 2 degrees in flexion/extension radiographs.⁸ The statistical significance was set at $p < 0.05$.

Results

Twenty-three (13 females) patients were enrolled in the uLP group and 23 (10 females) in the LC group. The mean age was 69 years (range: 57–82 years) without significant difference between the groups.

Intraoperative Parameters

In both groups, the intraoperative blood loss did not exceed 200 mL. The mean surgical time was 86 minutes in the uLP group and 136 minutes in the LC group ($p < 0.001$). Radiation time was 0.12 and 0.20 minutes in the uLP and LC groups, respectively ($p < 0.001$). The mean hospital stay was significantly shorter in the uLP group (9 days) than in the LC group (12 days; $p = 0.015$). The overall length of the hospital stay was influenced by the reimbursement regulations.

Clinical Outcome

All patients were followed for at least 12 months (averages: 13 and 23 months for the uLP and LC groups, respectively). The longest follow-up was 60 months (LC group). The mean mJOA score increased significantly in the uLP group, from 12.6 points preoperatively to 15.1 points at 3 months, and 15.7 at 12 months ($p < 0.001$ for preoperative vs. 12 months). In the LC group, the mean mJOA score was 12.3 points preoperatively, 14.6 points at 3 months, and 15.5 at 12 months ($p < 0.001$ for preoperative vs. 12 months). These improvements in mJOA scores from before surgery to the last follow-up were both statistically significant and clinically relevant.⁹ The neurologic function improvement ratio averaged 64%. Among the 46 patients, 75% showed a good neurologic recovery (ratio $>50\%$; uLP = 19 patients; LC = 17 patients), and 25% showed a poor recovery (ratio $<50\%$; uLP = 4 patients; LC = 6 patients). The differences between the groups were not significant (→ **Table 1**).

The Neck Disability Index (NDI) was assessed preoperatively, at 3 months postoperatively, and at the last follow-up (→ **Figs. 4 and 5**). In the uLP group, the initial mean NDI was 26 points, and it improved to 14 points at 12 months. In the LC group, the initial mean NDI was 28 points, and it improved to 18 points at the last follow-up. The difference between the groups was statistically significant for NDI and visual analog scale (VAS) of the neck at 3 months of follow-up but not for the VAS arm. After 12 months, the difference in the groups did not reach statistical significance, but it reached the required level of substantial clinical benefit.¹⁰

Postoperative Complications

In the uLP group, no postoperative iatrogenic neurologic deterioration or C5 palsy, infection, spinal fluid leak, non-**Table 1** Comparison at 3-month follow-up of the clinical outcomes in patients treated for mDCM with uLP and with LC

Outcome at 3-mo follow-up	uLP (n = 23)	LC (n = 23)	p value
NDI	25	42	0.017 ^a
VAS neck	1.4	3.0	0.01 ^a
VAS arm	0.5	0.6	n.s.
mJOA	15.1	14.6	n.s.

Abbreviations: LC, lateral mass screw fixation; mDCM, multilevel degenerative cervical myelopathy; mJOA, modified Japanese Orthopaedic Association; NDI, Neck Disability Index; n.s., not significant; uLP, unilateral lateral mass screw fixation; VAS, visual analog scale.

^aStatistically significant and clinically relevant

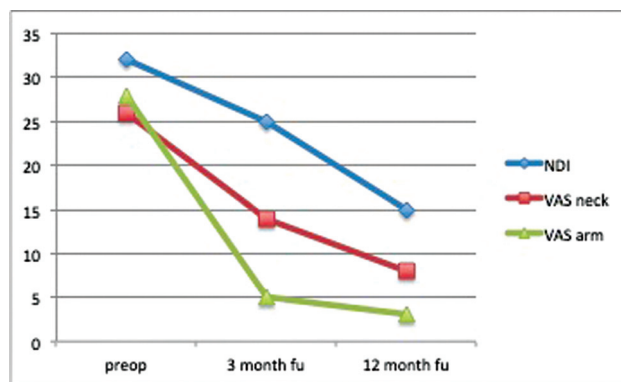


Fig. 4 Clinical outcomes in patients treated for multilevel degenerative cervical myelopathy (mDCM) with unilateral lateral mass screw fixation (uLP).

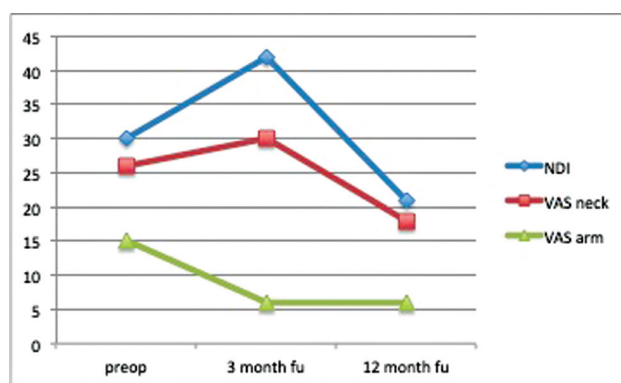


Fig. 5 Clinical outcomes in patients treated for multilevel degenerative cervical myelopathy (mDCM) with lateral mass screw fixation (LC).

union, or rod breakage was observed. At the 3-month follow-up, one patient showed a loose lateral mass screw along with postoperative kyphosis. This patient underwent revision surgery 4 months after the primary procedure, via a combined approach, resulting in a fusion procedure between C3 and T2. In the LC group, one patient complained of a transient (3 months) C5 palsy, which recovered spontaneously and completely. One patient reported C6 postsurgical radicular pain, due to a malpositioned lateral mass screw. Revision was performed, and the patient recovered completely. One patient suffered from postoperative delirium and was observed two nights in the intermediate care unit. Last but not least, an 83-year-old patient experienced transitory cerebral ischemia, almost 3 weeks after surgery.

X-ray Analysis

Twenty patients of each group were available for X-ray analysis 1 year after surgery. The ROMs of the instrumented levels were reduced in both groups (mean before/after ROMs: uLP–23/5 degrees; LC–20/2 degrees). These findings were correlated with fusion rates of 67% (uLP) and 92% (LC). At 1 year after surgery, cervical lordosis (C2–C7) was almost preserved in the uLP group but was reduced (though not significantly) in the LC group (mean before/after lordosis: LP –19/16 degrees; LC–14/7 degrees). Craniocervical lordosis

Table 2 Radiologic outcomes of the functional X-ray analysis in patients treated for mDCM with uLP and with LC

Outcome	Preoperative	12-mo follow-up
uLP, N = 20		
ROM (C3–C7)	23 degrees	5 degrees ($p < 0.001$)
Fusion rate		67%
Cervical lordosis (C2–C7)	19 degrees	16 degrees ($p = 0.57$)
Craniocervical lordosis (C0–C2)	28 degrees	28 degrees ($p = 0.432$)
SVA (C2–C7)	26 mm	28 mm
LC, N = 20		
ROM (C3–C7)	20 degrees	2 degrees ($p < 0.001$)
Fusion rate		92%
Cervical lordosis (C2–C7)	14 degrees	7 degrees ($p = 0.045$)
Craniocervical lordosis (C0–C2)	30 degrees	33 degrees ($p = 0.153$)
SVA (C2–C7)	30 mm	34 mm ($p = 0.611$)

Abbreviations: LC, lateral mass screw fixation; mDCM, multilevel degenerative cervical myelopathy; ROM, range of motion; SVA, sagittal vertical axis; uLP, unilateral lateral mass screw fixation.

Note: Values are the mean measurements.

(C0–C2) remained unchanged in the uLP group but increased with more rigid fusion (mean before/after lordosis: uLP–28/28 degrees; LC–30/33 degrees). The C2–C7 sagittal vertical axis was only marginally affected in both groups (mean before/after axis lengths: uLP–26/28 mm; LC–30/34 mm). The radiologic data are summarized in ►Table 2.

Discussion

DCM is one of the most common causes of spinal cord dysfunction in elderly patients. To date, surgical decompression is the only effective therapy in progressive disease. However, due to the usually advanced age of the patients, we must take into account their potentially risky comorbidities, the prevalence of perioperative complications, and the often limited effectiveness of postoperative rehabilitation. Consequently, the minimal as possible surgical traumatization should be mandatory. Despite the many procedures of cervical spine surgery described, laminoplasty and laminectomy remain the benchmark procedures for posterior multilevel decompression.² These procedures can be considered equivalent in terms of clinical efficacy. Anatomical studies have shown that the “open-door” laminoplasty increases the axial cross-section of the spinal canal up to 200%.^{11,12} However, no differences were observed between these procedures in the postoperative clinical outcome.^{13,14} Also, the present study confirmed the clinical equivalence of the laminoplasty and laminectomy procedure. In both groups, the mJOA score improved significantly by 3 points. This value

is considered clinically important.⁹ Moreover, the NDI and the VAS arm and neck scores showed a substantial, clinically relevant, improvement after 1 year (►Table 1).¹⁰

The laminoplasty via a unilateral approach, and therefore traumatizing less the soft tissue and the neck muscles, was first described by Roselli et al.³ The goal was to reduce the prevalence of postoperative wound-healing disturbances and the degree of neck muscles atrophy, and therefore to boost the rehabilitation. In this study, delayed wound healing and clinically relevant muscle atrophy did not occur in either group. As it was expected, the mean operating time in the uLP group (86 minutes) was significantly shorter than in the LC group (136 minutes). Furthermore, the duration of the hospitalization, which could influence the entire postoperative recovery process, was also significantly shorter in the uLP group (9 days) than in the LC group (12 days). Of course, the duration of the inpatient stay depends on various reimbursement and social factors, but these were homogenous in the identical hospital setting. A further potential benefit of the “controlled” decompression provided by laminoplasty and of the resulting “controlled” dorsal shift of the spinal cord could be a lower prevalence of C5 palsy compared with laminectomy. Liu et al recently described a technique that was similar to uLP for treating ossification of the posterior longitudinal ligament. Instead of an open-door laminoplasty, they performed a hemilaminectomy to decompress the spinal cord. The rationale for that approach was to reduce the prevalence of postoperative C5 palsy and to preserve the cervical lordosis. In 146 patients, they observed no case of C5 palsy, and the lordotic angle did not change significantly over time.⁶ The present study showed a comparable trend: no C5 weakness occurred in the uLP group, and one transient C5 palsy occurred in the LC group. However, due to the small number of patients treated in the present study, we cannot draw any firm conclusion. Currently, cervical laminectomy is usually combined with bilateral fixation and fusion to restore cervical lordosis and/or reduce the risk of postoperative kyphosis.¹⁵ In contrast, laminoplasty is associated with postoperative kyphosis.^{16,17} This side effect, which may cause considerable neck pain, is particularly frequent among elderly patients.¹⁸ To reduce the risk of postoperative kyphosis, a unilateral laminoplasty can be “stabilized” with unilateral fixation and fusion. The biomechanical effects of bilateral subaxial lateral mass stabilization have been demonstrated in various studies.^{19,20} As a consequence, bilateral LC is commonly performed in the clinical practice. On the contrary, there is still a knowledge gap about cervical fixation with unilateral lateral mass screws. Therefore, we had evaluated previously in a cadaver model the biomechanical stability of a multilevel construct in the subaxial spine.²¹ The study did not show any significant difference between unilateral and bilateral LC regarding the ROM and the neutral zone. Also, Su et al could show in a retrospective clinical study that the curvature after bilateral laminoplasty and uni- or bilateral fixation was similar in both groups.²²

In the present study, we evaluated the C-spine stabilization in terms of the intersegmental motion measured on the

digitalized functional X-ray films with a sophisticated software. That allowed for a ROM error less than 0.2 degrees.²³ Fusion was defined as less than 2 degrees of intersegmental motion on flexion and extension X-rays between fixed segments. According to this method, at the 1-year follow-up, the fusion rate was 67% in the uLP group and 92% in the LC group. Thus, bilateral fixation led to a significant higher fusion rate than unilateral stabilization. However, we do not consider this as a disadvantage, because the primary goal of unilateral stabilization is the preservation of the cervical lordosis. The parameters of the cervical sagittal alignment, sagittal vertical axis, and lordosis of the C-spine did not change significantly after surgery in either group. However, the lordosis decreased moderately in the LC group. That was probably due to our surgical technique, because, in the beginning, we did not actively restore the cervical lordosis after decompression adjusting the Mayfield clamp.

A limitation of this study was the lack of randomization. Therefore, we could not exclude a potential bias in patient selection. The uLP group tended to present with less pain and with a lower functional level than the LC group. However, the differences were almost insignificant. The mean follow-up for the patients of the uLP group was 13 months up to now. We have not seen any implant failure so far, but it could occur by the time passing. Finally, the number of patients studied is small. As mentioned in the introduction, the indication for uLP is very selective and therefore limited the number of suitable patients.

Conclusion

Laminoplasty and unilateral fixation via a unilateral approach achieved comparable clinical and radiologic results with laminectomy and bilateral fixation, despite a lower fusion rate. Operating time and inpatient stay were shorter and neck pain at 3 months was less.

Video 1

Technique for unilateral laminoplasty and lateral mass screw stabilisation Online content including video sequences viewable at: <https://www.thieme-connect.com/products/ejournals/html/10.1055/s-0041-1739224>.

Conflict of Interest

None declared.

Acknowledgments

This study was partially supported by a research grant from the German Arthrosis Aid (Deutsche Arthrose Hilfe e.V.) and the World Arthrosis Organization.

References

- Karadimas SK, Gatzounis G, Fehlings MG. Pathobiology of cervical spondylotic myelopathy. *Eur Spine J* 2015;24(Suppl 2):132–138
- Bartels RHMA, van Tulder MW, Moojen WA, Arts MP, Peul WC. Laminoplasty and laminectomy for cervical spondylotic myelopathy: a systematic review. *Eur Spine J* 2015;24 (Suppl 2):160–167
- Roselli R, Pompucci A, Formica F, et al. Open-door laminoplasty for cervical stenotic myelopathy: surgical technique and neurophysiological monitoring. *J Neurosurg* 2000;92(1, Suppl):38–43
- Nakashima H, Imagama S, Yukawa Y, et al. Multivariate analysis of C-5 palsy incidence after cervical posterior fusion with instrumentation. *J Neurosurg Spine* 2012;17(02):103–110
- Nassr A, Eck JC, Ponnappan RK, Zanoun RR, Donaldson WF III, Kang JD. The incidence of C5 palsy after multilevel cervical decompression procedures: a review of 750 consecutive cases. *Spine* 2012;37(03):174–178
- Liu K, Shi J, Jia L, Yuan W. Surgical technique: Hemilaminectomy and unilateral lateral mass fixation for cervical ossification of the posterior longitudinal ligament. *Clin Orthop Relat Res* 2013;471 (07):2219–2224
- Hirabayashi K, Miyakawa J, Satomi K, Maruyama T, Wakano K. Operative results and postoperative progression of ossification among patients with ossification of cervical posterior longitudinal ligament. *Spine* 1981;6(04):354–364
- McAfee PC, Boden SD, Brantigan JW, et al. Symposium: a critical discrepancy—a criteria of successful arthrodesis following interbody spinal fusions. *Spine* 2001;26(03):320–334
- Tetreault L, Nouri A, Kopjar B, Côté P, Fehlings MG. The minimum clinically important difference of the modified Japanese Orthopaedic Association Scale in patients with degenerative cervical myelopathy. *Spine* 2015;40(21):1653–1659
- Carreon LY, Glassman SD, Campbell MJ, Anderson PA. Neck Disability Index, short form-36 physical component summary, and pain scales for neck and arm pain: the minimum clinically important difference and substantial clinical benefit after cervical spine fusion. *Spine J* 2010;10(06):469–474
- Wang X-Y, Dai L-Y, Xu H-Z, Chi Y-L. Prediction of spinal canal expansion following cervical laminoplasty: a computer-simulated comparison between single and double-door techniques. *Spine* 2006;31(24):2863–2870
- Yang L, Gu Y, Shi J, et al. Modified plate-only open-door laminoplasty versus laminectomy and fusion for the treatment of cervical stenotic myelopathy. *Orthopedics* 2013;36(01):e79–e87
- Lee C-H, Lee J, Kang JD, et al. Laminoplasty versus laminectomy and fusion for multilevel cervical myelopathy: a meta-analysis of clinical and radiological outcomes. *J Neurosurg Spine* 2015;22 (06):589–595
- Phan K, Scherman DB, Xu J, Leung V, Virk S, Mobbs RJ. Laminectomy and fusion vs laminoplasty for multi-level cervical myelopathy: a systematic review and meta-analysis. *Eur Spine J* 2017;22 (01):94–103
- Albert TJ, Vacarro A. Postlaminectomy kyphosis. *Spine* 1998;23 (24):2738–2745
- Kato M, Namikawa T, Matsumura A, Konishi S, Nakamura H. Effect of cervical sagittal balance on laminoplasty in patients with cervical myelopathy. *Global Spine J* 2017;7(02):154–161
- Nowinski GP, Visarius H, Nolte LP, Herkowitz HN. A biomechanical comparison of cervical laminoplasty and cervical laminectomy with progressive facetectomy. *Spine* 1993;18(14):1995–2004
- Sakaura H, Ohnishi A, Yamagishi A, Ohwada T. Differences in postoperative changes of cervical sagittal alignment and balance after laminoplasty between cervical spondylotic myelopathy and cervical ossification of the posterior longitudinal ligament. *Global Spine J* 2019;9(03):266–271
- Kothe R, Rütther W, Schneider E, Linke B. Biomechanical analysis of transpedicular screw fixation in the subaxial cervical spine. *Spine* 2004;29(17):1869–1875
- Dmitriev AE, Kuklo TR, Lehman RA Jr, Rosner MK. Stabilizing potential of anterior, posterior, and circumferential fixation for multilevel cervical arthrodesis: an in vitro human cadaveric study

- of the operative and adjacent segment kinematics. *Spine* 2007;32(06):E188–E196
- 21 Schmeiser G, Schilling C, Grupp TM, Papavero L, Püschel K, Kothe R. Unilateral laminoplasty with lateral mass screw fixation for less invasive decompression of the cervical spine: a biomechanical investigation. *Eur Spine J* 2015;24(12):2781–2787
- 22 Su N, Fei Q, Wang B-Q, et al. Comparison of clinical outcomes of expansive open-door laminoplasty with unilateral or bilateral fixation and fusion for treating cervical spondylotic myelopathy: a multi-center prospective study. *BMC Surg* 2019;19(01):116
- 23 Schulze M, Trautwein F, Vordemvenne T, Raschke M, Heuer F. A method to perform spinal motion analysis from functional X-ray images. *J Biomech* 2011;44(09):1740–1746