



# Use of Groin Neurectomies for Noniatrogenic Testicular and Groin Pain

Sanchit Sachdeva, BA<sup>1</sup> Avneesh Chhabra, MD<sup>2</sup> Joan Reisch, PhD<sup>3</sup> Shai M. Rozen, MD<sup>1</sup>

<sup>1</sup>Department of Plastic and Reconstructive Surgery, University of Texas Southwestern Medical Center, Dallas, Texas

<sup>2</sup>Musculoskeletal Radiology Division, Department of Radiology, University of Texas Southwestern Medical Center, Dallas, Texas

<sup>3</sup>Division of Biostatistics, Department of Population and Data Sciences, University of Texas Southwestern Medical Center, Dallas, Texas

Address for correspondence Shai M. Rozen, MD, Department of Plastic and Reconstructive Surgery, University of Texas Southwestern Medical Center, 1801 Inwood Road, Dallas, TX 75390-8593 (e-mail: shai.rozen@utsouthwestern.edu).

J Reconstr Microsurg Open 2021;6:e70–e78.

## Abstract

**Background** Chronic groin neuralgia is a life-debilitating condition that plagues patients worldwide. While groin neuralgia is usually traced to iatrogenic causes (inguinal hernia repairs, vasectomy, and hysterectomy), there is a unique subset of patients that present with noniatrogenic groin neuralgia. The diagnosis and treatment of these patients present a particular challenge.

**Methods** A total of 30 patients (current mean age, 46.5 [range: 19–72] years) who presented with noniatrogenic groin neuralgia and received neurectomies on the iliohypogastric, ilioinguinal, and genitofemoral nerves between 2008 and 2017 were identified. A retrospective review of preoperative and immediate postoperative pain scores was compared with prospectively collected current pain on a Likert's scale (0–10). Additionally, patients were asked to complete a Short Form (SF)-20 and identify current pain medications. A two-sided Wilcoxon–Mann–Whitney test was used to analyze the data.

**Results** Of the 30 patients identified, 16 could participate (mean follow-up = 61 months). The average pain reduction for the entire group was 62.7%. When using an established 30% reduction pain as a marker for clinical significance, 12 successful and 4 unsuccessful patients had an average reduction of 81.1 and 7.68%, respectively (success rate of 75%). Patients with successful group showed a statistically significant increased social functioning ( $p = 0.012$ ) and near-significant increase in mental health ( $p = 0.063$ ). Improvements, albeit nonsignificant, in mean scaled scores for every other SF-20 quality of life (QoL) category were observed when comparing both groups.

**Conclusion** Neurectomy is a potentially beneficial surgery that can assuage pain and improve quality of life for patients with noniatrogenic groin neuralgia.

## Keywords

- ▶ noniatrogenic
- ▶ groin neuralgia
- ▶ neurectomy
- ▶ quality of life

received  
March 28, 2021  
accepted after revision  
August 2, 2021

DOI <https://doi.org/10.1055/s-0041-1736421>.  
ISSN 2377-0813.

© 2021. The Author(s).

This is an open access article published by Thieme under the terms of the Creative Commons Attribution-NonDerivative-NonCommercial-License, permitting copying and reproduction so long as the original work is given appropriate credit. Contents may not be used for commercial purposes, or adapted, remixed, transformed or built upon. (<https://creativecommons.org/licenses/by-nc-nd/4.0/>)

Thieme Medical Publishers, Inc., 333 Seventh Avenue, 18th Floor, New York, NY 10001, USA

Patients with groin and testicular neuropathic pain often experience substantial decrease in their quality of life (QoL), generally proportionate to the severity of their groin neuralgia. The most common etiology of chronic neuropathic groin pain is nerve injury as a result of surgical intervention in the lower abdomen, most commonly involving the iliohypogastric, ilioinguinal, or genitofemoral nerves. Suggested mechanisms of injury include neuroma formation, nerve entrapment, or direct nerve irritation from suture or surgical mesh and subsequent granuloma formation.<sup>1</sup> With approximately 500,000 inguinal hernia repairs, 600,000 hysterectomies, and 500,000 vasectomies performed annually, it is estimated that 2 to 10% develop some degree of chronic postoperative pain.<sup>2-5</sup> A recent study of 100 patients showed that 44.7% of patients with neuropathic pain experienced reduced work schedules, with average annual health care costs of \$11,846 and 29,617 in direct and indirect costs, respectively, while patients with severe neuropathic pain spent an upwards of \$15,602 and 44,540, respectively.<sup>6</sup>

Though surgical injury is the most common etiology for chronic nerve pain, a unique and understudied subgroup of patients exists, presenting with groin or testicular pain without obvious preceding surgery or other clear etiology such as trauma, muscle tears, or sports hernia. These patients pose a significant diagnostic and treatment challenge as they are frequently misdiagnosed, leading to unwarranted treatments, that is, antibiotics for presumed infections, such as epididymitis or prostatitis, surgical procedures such as bowel resections or orchiectomies, and life-long pain medications including opioids, antiepileptics, antidepressants, and nonsteroid anti-inflammatory drugs.<sup>6</sup>

This study reports our experience and long-term follow-ups with this unique group of patients discussing diagnostic methods, surgical approaches, and outcomes of selective neurectomies on pain and QoL.

## Patients and Methods

This study was approved by Institutional Review Board (IRB) at the University of Texas Southwestern Medical Center (Study 2019-0563). Patients included were only those suffering from groin, testicular or labial pain without any preceding surgery identified as the cause of pain. All patients underwent neurectomy of the iliohypogastric, ilioinguinal, and/or genitofemoral nerves. A small number of patients in this group underwent previous surgeries to address their original neurogenic pain which persisted postoperatively leading to the subsequent neurectomies. Retrospective review included patient demographics (→Table 1), surgical history, pain medication usage, location of pain, response to nerve blocks, intraoperative details, pathology, and imaging results. A prospective telephone survey was performed in which the Short Form (SF)-20 Quality of Life questionnaire, current pain levels (measured using Likert's score, 0–10), and current use of pain medications were assessed. SF-20 scaled scores were calculated. Every category except for the SF-20 Pain Scaled Score had a maximum value of 100 while the best possible SF-20 Pain Scaled Score was 0 indicating no current

pain. To evaluate pain in this study, the Likert score was primarily used. Mean and standard deviations were calculated for each variable. A 30% pain reduction postoperatively was considered significant as suggested by Farrar et al<sup>7</sup> and the subsequent "core outcomes measures for chronic pain clinical trials" publication.<sup>8</sup> A two-sided Wilcoxon–Mann–Whitney test was used to analyze the data. A *p*-value of less than 0.05 was considered statistically significant.

## Diagnosis

All patients underwent a thorough history and physical examination with an emphasis on pain characterization, that is, duration, type, location, level, and frequency and events preceding the pain including potential etiologies; innocuous incisions patients may have forgotten. Additionally, two separate nerve blocks were given in clinic unless the patients' physical examination (i.e., obesity) prohibited accurate placement or in cases of refusal (i.e., fear of needles) in which case blocks were mostly computed tomography (CT) guided or very rarely, foregone. These included (1) ilioinguinal and iliohypogastric nerve blocks placed approximately 5 cm medial and inferior to the anterior superior iliac spine (ASIS), and (2) genitofemoral nerve block placed approximately 2.5-cm superior and lateral to the pubic tubercle. In most cases of this subgroup, we attempt to obtain magnetic resonance neurography (MRN), though occasionally, these are not approved by the insurance companies or patients refuse due to claustrophobia.

## Surgical Technique

An incision ranging between 6 and 8 cm is performed approximately 3 cm above a line drawn between the ASIS and the pubic tubercle representing the inguinal (Poupart's) ligament. This incision allows an approach to both ilioinguinal, iliohypogastric nerves, and the more medial genitofemoral nerve. The external oblique fascia is incised and retracted, usually readily providing visualization of the more cranial iliohypogastric and ilioinguinal nerves. Following the spermatic cord medially that usually provides visualization of the genitofemoral nerve in the inferoposterior aspect of the cord, we have encountered variability in branching patterns. Once the relevant branches are identified, any type of etiology—traumatic or compressive—is explored. In most cases, the nerves are neurectomized and freed to the extent that when buried either in the internal oblique muscle or pre peritoneum, it may be done without tension. We recently started exploring targeted muscle reinnervation (TMR) and regenerative peripheral nerve interface (RPNI) techniques that were not included in this patient group to avoid introducing an additional confounder.

## Results

Thirty patients were identified who fit the inclusion criteria. Of the 30 patients, 4 patients declined to participate, 9 patients could not be reached, and 1 patient had passed away. Sixteen patients (13 males and 3 females) with a mean age of 46.5 (range: 19–72) years agreed to participate. Mean

**Table 1** Patient characteristics at the time of final evaluation

Patient ID	Sex	Age	BMI	Location of pain	Possible preoperative diagnosis	Prior abdominal surgical procedures attempting to resolve pain (months before neurectomy)	Follow-up time (mo)
Successful neurectomy group							
1	M	46	25.2	Testicular pain	Unknown	None	95.5
2	M	53	18.6	Testicular pain	Unknown	None	69.0
3	M	30	23	Testicular pain	Traction neuropathy	None	53.5
4	M	22	27.5	Groin pain	Unknown	None	51.0
5	M	19	27.5	Testicular pain	Venous varicocele	None	39.0
6	F	60	35.0	Groin pain	Unknown	Total hysterectomy (~288 months)	86.0
7	M	20	19.3	Testicular pain	Unknown	Varicocele repair (approx. 24 months) RFA (~12 months)	45.5
8	M	65	25.4	Groin pain	Unknown	None	27.5
9	M	71	35.2	Testicular pain	Unknown	Neurectomy involving distal spermatic cord (unknown)	18.5
10	M	46	32.3	Testicular pain	Unknown	2 inguinal hernia repair (~60 and 72 months)	97.0
11	F	30	20.0	Groin pain	Nuck's cyst	None	76.0
12	F	49	30.3	Groin pain	Unknown	Hysterectomy (11 months) D&C procedure (~156 months) Left groin hernia repair (~7 months)	75.5
Mean		42.6	26.6	–		–	61.0
Unsuccessful neurectomy group							
13	M	72	26.9	Groin pain	Unknown	None	29.5
14	M	42	29.3	Testicular pain	Unknown	Back surgery (36 months) Bilateral inguinal hernia repair (~60 months)	108.5
15	M	60	28.7	Testicular pain	Unknown	Excision of epididymal cyst (unknown)	99.0
16	M	59	30.0	Testicular pain	Unknown	Inguinal hernia repair (8 months)	34.5
Mean		58.3	28.7	–		–	68.0
All patients							
Mean		46.5	27.1	–		–	63.0
Difference in groups ( <i>p</i> -value)		0.20	0.52	–		–	<i>p</i> = 0.77

Abbreviations: BMI, body mass index; D&C, dilatation and curettage; F, female; M, male; RFA, radio frequency ablation.

Note: Data are organized to represent all patients, successful surgery patients, unsuccessful surgery patients, and the associated *p*-values if applicable.

follow-up was  $61 \pm 24$  months. Average body mass index (BMI) was  $27.1 \pm 5.09$  kg/m<sup>2</sup>. Of the 13 males, 10 patients presented primarily with testicular pain, while 3 presented with generalized groin pain. All females presented with generalized groin pain without labial pain. Fourteen of the 16 patients received diagnostic nerve blocks prior to surgery. One patient preferred not to receive it and proceeded to an MRN followed by surgery, while the other refused it. All who received blocks experienced improvement in the pain. The

average pain reduction for the entire group of 16 was 62.7%. The average pain reduction for the 12 patients (75%) who experienced more than a 30% reduction in Likert's pain score was 81.1% and for the 4 patients (25%) who did not was 7.68% (**► Table 2**). Patients with significant pain reduction showed a statistically significant increase in social functioning (*p* = 0.012) while nonstatistically significant increases were seen in physical functioning (*p* = 0.112), role functioning (*p* = 0.118), mental health (*p* = 0.063), health perception

**Table 2** Evolution of preoperative to current pain levels

Patient ID	Preoperative Likert's score (worst pain)	Current Likert's score (worst pain)	% reduction
Successful neurectomy group			
1	8	0	100
2	10	5	50
3	8	0	100
4	10	0	100
5	10	0	100
6	7	4	42.9
7	8	0	100
8	10	7	30
9	9	0	100
10	10	0	100
11	10	0	100
12	10	5	50
Mean	9.4	1.4	81.1
Unsuccessful neurectomy group			
13	7	8	-14.3
14	8	6	25
15	10	10	0
16	10	8	20
Mean	8.8	8	7.68
All patients			
Mean	9.1	3.3	62.7

Note: Data are organized to represent all patients, successful surgery patients, and unsuccessful surgery patients with associated pain reduction calculations.

( $p = 0.097$ ) as assessed by the SF-20 (► Fig. 1). Our statistical analysis did not reveal any correlations between pain reduction to patient age, sex, BMI, past medical history, or past-surgical history.

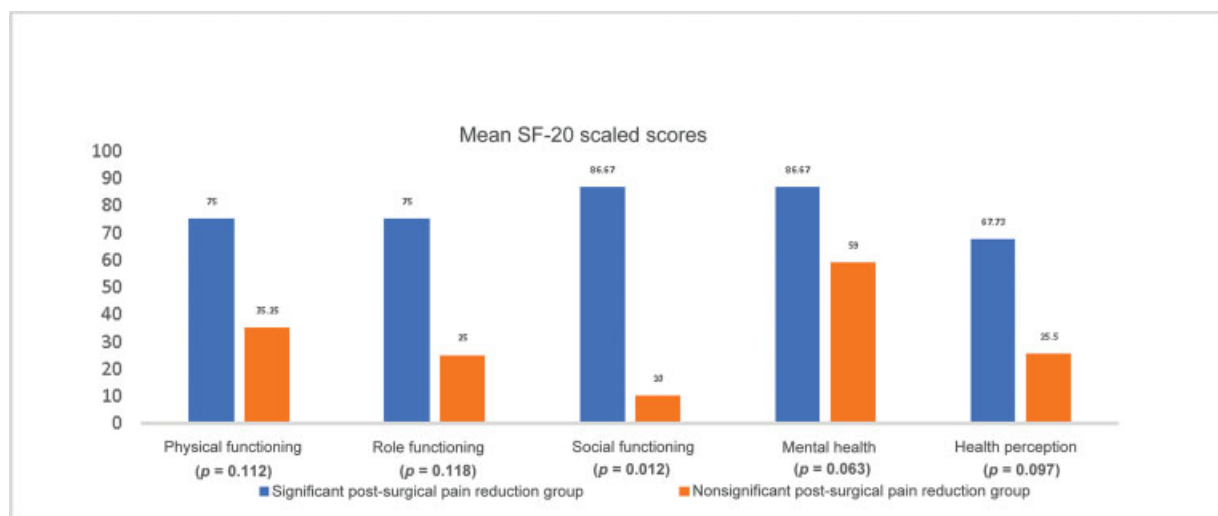
While a concrete statistical analysis on pain medication usage could not be performed, some data were ascertained (► Table 3). Out of the 12 patients with successful surgeries, 8 patients (66%) discontinued the use of any pain medications and 3 (25%) decreased their pain medication usage. One patient in the successful surgery group was not using pain medications pre- and postoperatively. Out of the four patients with unsuccessful surgeries, two patients decreased their pain medication usage, while one patient increased their pain medications usage. One patient in the unsuccessful surgery group was not using pain medications pre- and postoperatively.

A working preoperative diagnosis could be established in 3 (18.8%) patients of patients, and no clear diagnosis was established in the remaining 13 (81.2%) patients.

### Discussion

Chronic groin and/or testicular neuropathic pain is an acknowledged risk of surgeries in the lower abdominal region. Neurectomy of the iliohypogastric, ilioinguinal, and genitofemoral nerves has been reported as a viable and effective treatment for iatrogenic chronic groin neuropathic pain.<sup>9</sup> However, this approach for noniatrogenic chronic groin and testicular neuropathic pain has not been explored.

While there is no standard procedure of diagnosing neuropathic pain, a comprehensive history and physical examination are crucial. Clinicians must initially make a distinction between nociceptive pain and neurogenic pain, the latter including symptoms of altered sensations, allodynia, hypoalgesia/hyperalgesia, and characteristic verbal pain descriptors such as “burning,” “electrical,” and “stabbing”

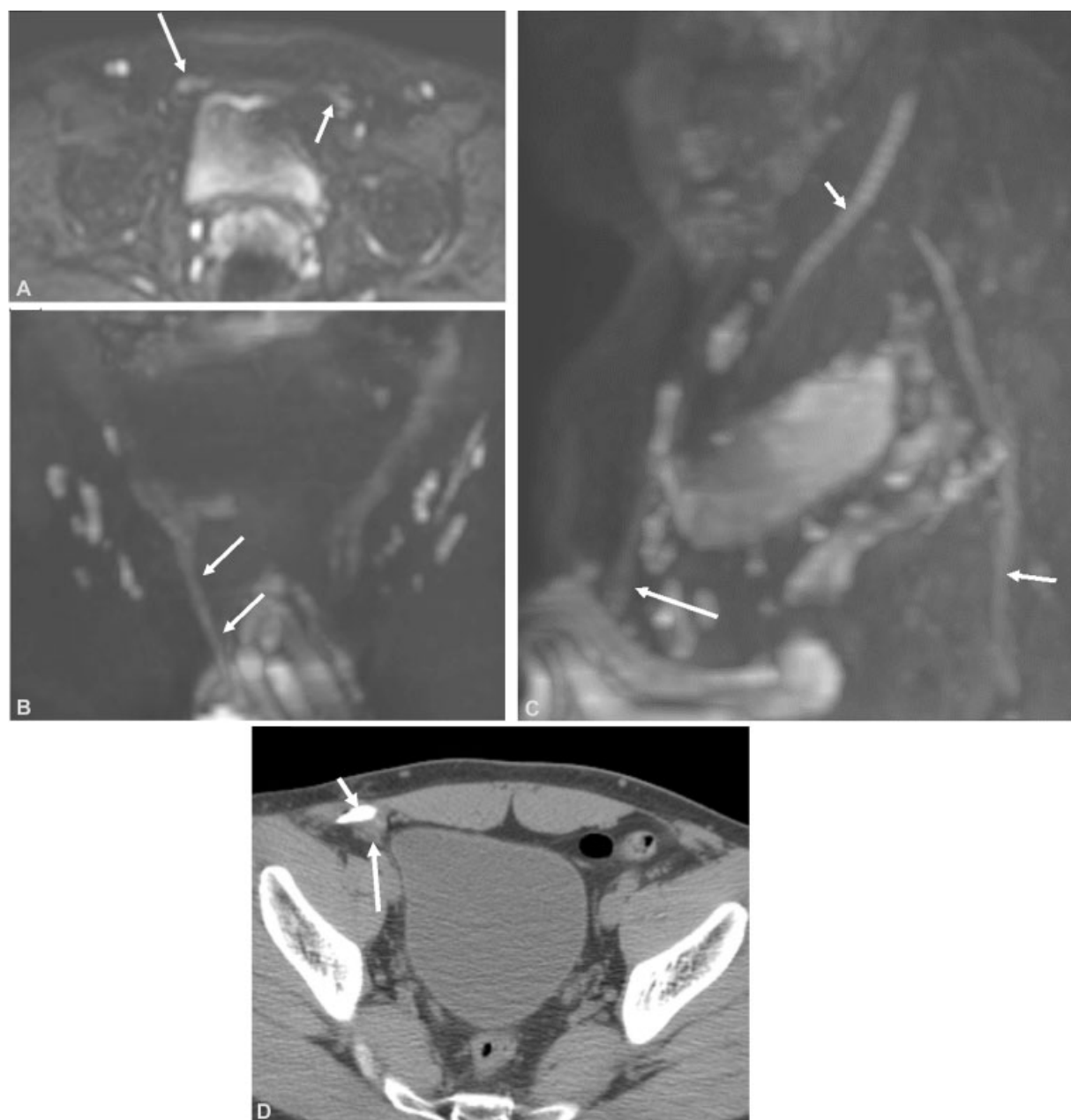


**Fig. 1** Computed mean SF-20 scaled scores reveal a significant increase in Social Functioning postoperatively between successful and unsuccessful surgeries. However, improvements in all categories of quality of life are seen. SF, Short Form.

**Table 3** Pre- and postoperative pain medication usage by patients

Patient ID	Preoperative medications	Postoperative medications
<b>Successful neurectomy group</b>		
1	Lortab (unspecified) Ibuprofen: 800 mg Tramadol: 50 mg TID Naproxen: 220 mg QID	None
2	10–325 hydrocodone-acetaminophen QID Baclofen: 10 mg TID Diazepam: 5 mg BID 0.25 mg alprazolam 2% lidocaine jelly TID	Oxycodone: 15 mg QID
3	Tramadol: 50 mg QID Lorazepam: 1 mg Diazepam: 5 mg Ibuprofen: 400 mg TID	None
4	Codeine: 30 mg QID Hydrocodone-acetaminophen: 5–325 mg QID Meloxicam: 7.5 mg Gabapentin: 300 mg TID Cyclobenzaprine: 5 mg TID Lorazepam: 1 mg QID Risperidone: 1 mg BID Tramadol: 50 mg TID Ibuprofen: 600 mg TID Citalopram: 200 mg	None
5	Hydrocodone-acetaminophen: 10–325 mg Gabapentin: 100 mg TID	None
6	Duloxetine: 60 mg Topiramate: 25 mg	Baclofen: 10 mg TID Gabapentin: 200 mg BID
7	Duloxetine: 60 mg Topiramate: 25 mg	None
8	Ibuprofen: 200 mg QID Atomoxetine: 100 mg	None
9	Hydrocodone-acetaminophen: 10–325 mg QID Naproxen: 500 mg BID Tramadol: 50 mg TID Ibuprofen: 800 mg TID Methocarbamol: 500 mg TID	Hydrocodone-acetaminophen: 10–325 mg 8 times/d Gabapentin: 300 mg TID
10	Hydrocodone-acetaminophen: 7.5–325 mg QID Tramadol: 50 mg Q4H	None
11	None	None
12	Hydrocodone-acetaminophen: 7.5–325 mg QID Lamotrigine: 150 mg BID	None
<b>Unsuccessful neurectomy group</b>		
13	Ketorolac: 10 mg BID Aspirin: 80 mg Ranolazine: 1,000 mg BID	Tramadol: 50 mg QID Tylenol PRN
14	Hydrocodone-acetaminophen: 5–500 4–8 times Methadone: 10 mg QID Oxycodone: 15 mg QID Pregabalin: 225 mg BID Amitriptyline: 50 mg	Nucynta (10 mg ER and 50 mg IR) PRN Gabapentin 600 mg 6 times/d for 8 years Tizanidine 5 mg 4 times/d PRN
15	Hydrocodone-acetaminophen: 5–325 mg QID Pregabalin TID Alprazolam: 0.25 mg	Pregabalin: 100 mg TID Ibuprofen: 800 mg TID Linzess: 290 mg QID Lisinopril: 5 mg QID Hydrocodone-acetaminophen: 10–325 mg PRN
16	None	None

Abbreviations: BID, twice a day; TID, three times a day; QID, four times a day; Q4H, every 4 hours; PRN, as needed; ER, extended release; IR, immediate release.



**Fig. 2** A 24-year-old man with 2-year history of right testicular pain. (A) Diffusion weighted axial MR neurography ( $b = 600\text{s/mm}^2$ ) shows an asymmetrically prominent right genital branch of the genitofemoral nerve (large arrow) and normal corresponding left nerve (small arrow). Coronal (B) and sagittal (C) maximum intensity projection (MIP) reconstructions show the full extent of the distally enlarged and hyperintense genital branch of the right genitofemoral nerve (large arrow), presumed traction neuropathy (corresponding to Sunderland class-III injury). Notice normal right femoral (small arrow) and sciatic nerves (medium arrow) with normal distal tapering and gradual loss of hyperintense signal. (D) CT-guided injection with injected nonionic contrast (small arrow) and injectate of local anesthetic and steroid (large arrow) around the genitofemoral nerve. CT, computed tomography; MR, magnetic resonance.

over the distributions of affected nerves. A history of trauma, previous infections such as prostatitis, orchitis, varicoceles, ligament or muscle strain, diabetic neuropathy, and various granulomatous disease, should be investigated as possible etiologies.<sup>1,10</sup>

Previous unreported surgeries should be sought as patients will occasionally fail to recognize certain procedures, such as groin lines and even exploratory laparoscopy as invasive or surgical. Examination may reveal surgical scars since some of these patients have had previous surgeries in

an attempt to alleviate the pain which may have included exploratory laparoscopies, lysis of adhesions, and even partial bowel resections (→ **Table 1**). It is important to establish that the current presenting pain is similar to that prior to such surgeries and not a result from them.

A diagnostic nerve block is one of the mainstays of diagnosis and should preferably be performed by the treating physician followed by a discussion with the patient, 20 to 30 minutes after the block. Evaluating the effects of the block on activities that generally elicit pain, provides valuable



information, and allows the physician both direct evaluation via questions and indirect assessment of nonverbal cues. Patient comments, such as experiencing a pain-free period after a block, which they have not experienced for months or years are invaluable. In very rare cases, a block in clinic is not possible as in patients who are obese, or in those who refuse to have it. In the latter group, the importance of the block should be reemphasized, and the surgeon will decide whether they wish to proceed. We generally choose to proceed if we think good rapport and understanding exist with the patient.

Although not uniformly available, MRN can provide valuable insight into the anatomy and underlying cause of groin neuralgia.<sup>11</sup> MRN allows direct nerve visualization of the normal nerves which are easily separable from the vessels on this high-resolution imaging modality. The imaging criteria for nerve identification include nonbranching linear structure, isointense to minimally hyperintense signal on T2-weighted images, mildly hyperintense signal on diffusion images due to excellent background and vascular signal suppression, and typical location and course along the neurovascular bundle.<sup>12</sup> Neuropathy is identified based on asymmetrical nerve enlargement or attenuation, prominent fascicles, focal enlargement with abnormally disrupted fascicles suggesting a neuroma, and supporting organic findings of surrounding perineural fibrosis and mass lesion.<sup>11</sup> The Sunderland grading of injury related neuropathy is also possible on MRN.<sup>13,14</sup> Though the included MRN images used in this article seem to be of low quality, these are actually the highest resolution for diffusion-weighted MR imaging (MRI).<sup>15</sup>

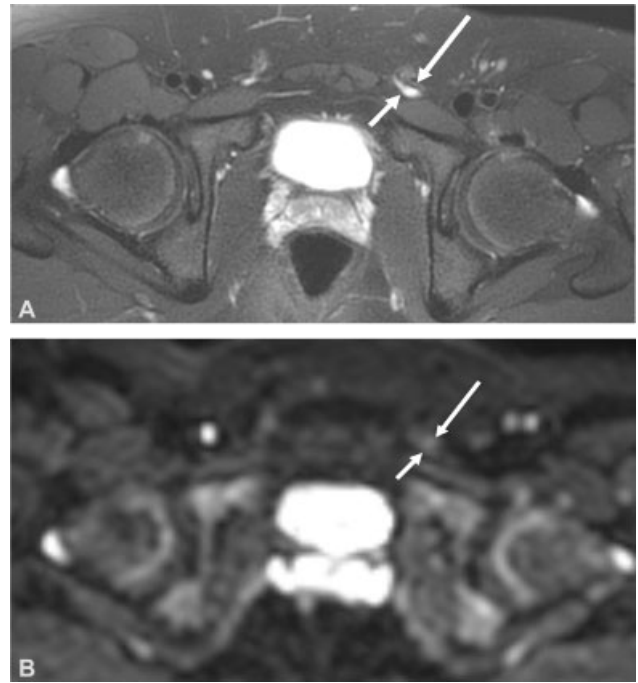
In one case, preoperative MRN of a patient (aged 24 years) showed a traction neuropathy corresponding to the Sunderland class-III injury of the right genitofemoral nerve (►Fig. 2). Subsequent neurectomies led to complete resolution of the neuropathic groin pain, as well as near complete return to a normal lifestyle.

While groin neuralgia usually presents in adults, two teenagers (aged 14 and 15 years, respectively) presented with testicular pain and one teenager (aged 17 years) presented with generalized groin pain. All three of them underwent successful surgeries with complete resolution of their groin pain and complete return to a normal lifestyle. Preoperative MRN of the 14-year-old patient revealed varicosities in the vicinity of the left genitofemoral nerve, leading to a compression neuropathy (►Fig. 3).

Another notable case revealed the formation of the Nuck cyst impinging on the right genitofemoral nerve in a 24-year-old female (►Figs. 4 and 5).

When analyzing which patients responded and who did not, three (25%) patients with successful surgeries had a preoperative diagnosis, while no diagnosis was found in all patients who had unsuccessful surgeries. No statistical difference was noted between successful and failed responses as relating to prediagnosis.

The exact time frame for which the physician and patient should wait prior to any intervention after the onset of pain is not clear; however, it is likely advisable to wait 6 to 12 months to allow inflammation to subside.<sup>1</sup> Serotonin-norepinephrine reuptake inhibitors, tricyclic antidepressants,

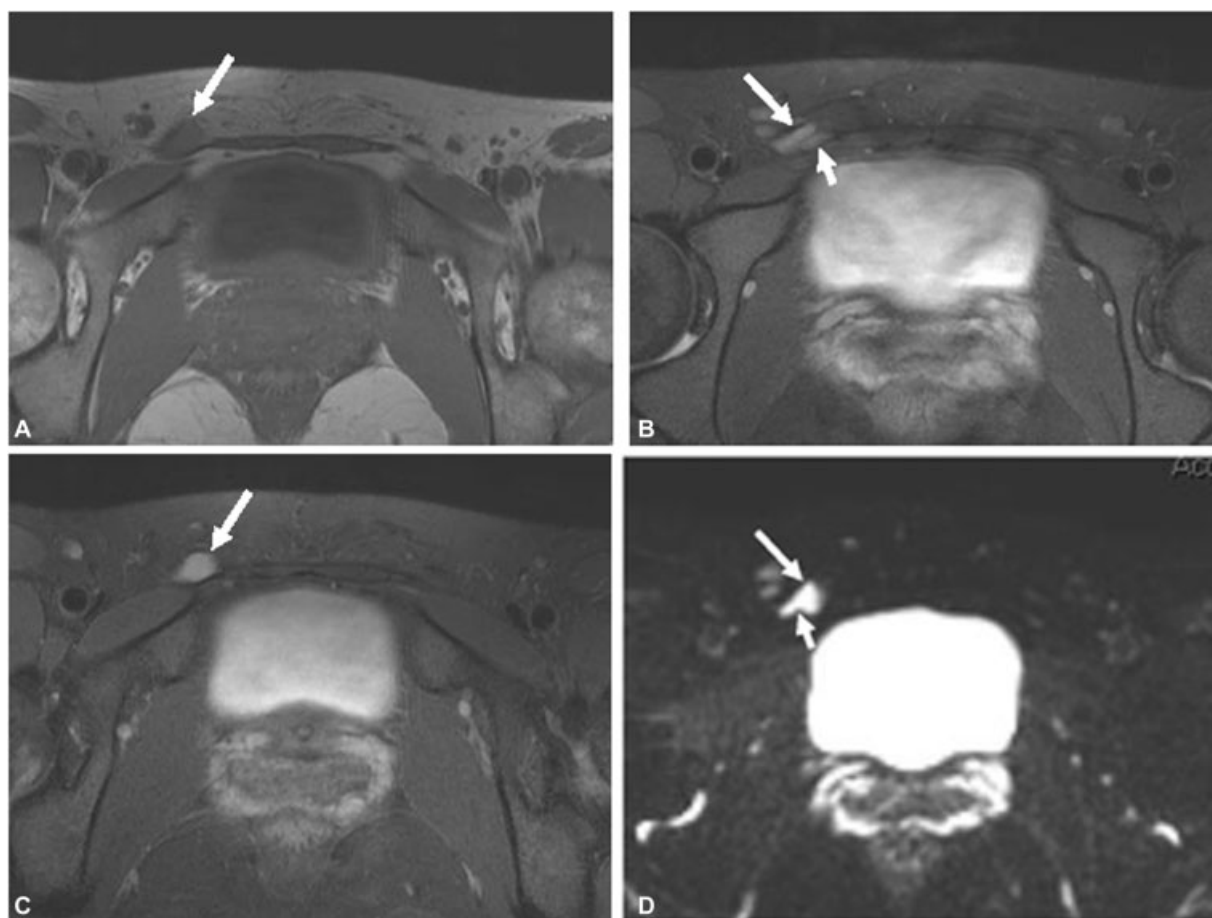


**Fig. 3** A 14-year-old boy with 8-month history of left testicular pain. (A) Axial T2 SPAIR (spectral adiabatic inversion recovery) shows a varicosity abutting the genital branch of the left genitofemoral nerve (large arrow). (B) Corresponding diffusion weighted image shows signal suppression of the varicosity (small arrow) and prominent abnormal signal of the genital branch of the left genitofemoral nerve (large arrow) consistent with neuropathy. Corresponding grade of Sunderland class injury would be II.

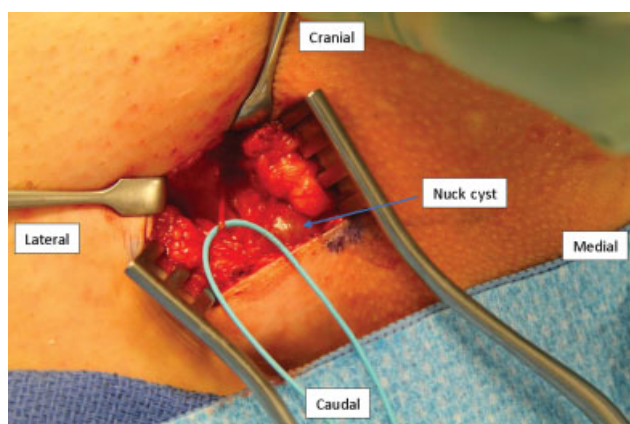
sants, and gabapentin can be used to partially alleviate neuropathic pain in the interim.<sup>16</sup>

What is considered a clinically meaningful reduction in pain has yet to be established and without doubt the subjectivity of pain renders numbers alone insufficient in providing the entire patients experience. Reduction of 30% in one individual may be life-changing while 60% in another may result in unceasing complaints of residual pain and continuous pain seeking behavior. We used the 30% reduction as definition of success, albeit the aforementioned limitations, based on the IMMPACT recommendations.<sup>8</sup> Without doubt, many other scoring systems exist, each with their advantages and disadvantages. This said that the average pain reduction for the entire group was 62.7%, the successful group was 81.1%, and the failed group was 7.68%.

The reported success rate of 75% in this case series is similar to previously published rates of postsurgical chronic groin pain.<sup>9</sup> However, it is important to consider that the diagnosis of pain etiology is often more elusive and difficult to define in this patient group, as opposed to the iatrogenic group which is commonly more clearly associated to an intervention. This may certainly lead to increased misdiagnosis, whether it be other nerve involvement or nonorganic reasons for pain. Also, some of these patients have had major surgery, such as partial bowel resections or orchiectomies, in an attempt to relieve the pain which retrospectively may have been misguided (►Table 1). Such patients often develop



**Fig. 4** A 24-year-old female with right groin pain and positive Tinel's sign. Axial T1W (A), T2 SPAIR (B, C), and diffusion tensor (D) images show a canal of the Nuck cyst (large arrows) compressing the right genitofemoral nerve (small arrow). The nerve is abnormally hyperintense consistent with neuropathy change. The patient underwent successful resection of the cyst with neurolysis of the impinged nerve. T1W, T1 weighted.



**Fig. 5** Intraoperative photo of a 24-year old female with the Nuck cyst compressing the right genitofemoral nerve previously mentioned in ► Fig. 4.

physical and emotional sequelae to such surgeries that may negatively bias the results of pain and QoL assessments.

The technique we chose is more of the traditional technique of burying the distal end of the neurectomized nerve into the muscle or pre peritoneum. This approach represents the school of thought that allowing the nerve to “do nothing” decreases the chance of neuroma formation. In recent years, there is an

increased interest in promising novel techniques, such as TMR) or RPNI, and recently a combination of both. This approach represents the school of thought that allowing the nerve to “do something” decreases the chance of neuroma formation. We have started exploring these procedures but having included such patients in this study would have “contaminated” the data by introducing another technique, hence another variable. Prospective comparisons of techniques are encouraged and are underway in several centers to our knowledge.

Additionally, our approach can perhaps be defined as more sensitive but less specific, since we prefer to perform neurectomies of all three suspected culprits, the iliohypogastric, ilioinguinal, and genitofemoral nerves if found. Opponents of this technique based on their arguments on the assumption that no sensory overlap exists between these nerves and that the only nerve that innervates the testicle and scrotum is the genitofemoral nerve. We would disagree with that claim since the ilioinguinal nerve may provide some sensation to the testis and certainly the anterior scrotal sac via the anterior scrotal nerves. Also, some patients may complain of posterior scrotal sac pain which is innervated by the posterior scrotal nerves originating from the pudendal nerve. We have had very little success in this latter group. Additionally, some who oppose neurectomizing these three nerves state that this may increase postoperative chronic



pain if a “normal” nerve is cut. This is a legitimate concern but we have not found this to be the case, especially in the environment of the abdominal wall which is rich with areas of muscle in which the nerve endings may be readily embedded without tension. We prefer this more “sensitive” rather than “specific” approach since we believe and have experienced that the benefit of cutting all three nerve and obtaining pain reduction outweighs the risk of creating new pain. Furthermore, it is important to note that neurectomy has been shown to be an effective means of reducing pain in other nerve distributions as well, including the perineal branches of the pudendal nerve and posterior femoral cutaneous nerve.<sup>17,18</sup>

## Limitations

There are several limitations to this study. The first is the study dropout. Of the 30, only 16 participated. One patient died, four refused to participate, and nine were lost to follow-up. For the latter group, we maximized the three permitted contact attempts as permitted by the IRB. With this limitation noted, it is also important to note that the average length of follow-up was over 3 years, a significant strength of the study. This, in our opinion, is crucial in any pain studies. There is a plethora of pain studies which have follow-ups of no longer than a year, an insufficient time frame to evaluate the effect of procedures intended for relieve pain. Even in carefully planned and randomized controlled trial (RCT), such long-term follow-ups are difficult to obtain and result increased number of patients lost to follow-up.

The smaller sample size may have led to only significant results in the social functioning category in the SF-20. This may have resulted in the nonsignificant results in physical functioning, role functioning, mental health, and health perception. Similarly, we were not able to derive any clear conclusion regarding changes in morphine equivalents due to our small sample size. Another limitation involves the potential for a response or lack of response bias. Of the four patients who declined participation, chart reviews indicated that two cited complete resolution of pain, one noted over 50% reduction, and one denied any improvement. It would be reasonable to assume that recurrence of pain was a major reason for refusal to participate. A similar pattern is seen with the nine patients who could not be reached. Three of these patients had complete resolution of their pain while one patient cited a 50% reduction in pain in their last reported follow-up. However, it is important to note the possibility that their pain may have relapsed at a later date which may have discouraged them from participating, in effect increasing the chance for a type-1 error.

## Conclusion

In conclusion, even with the aforementioned limitations, the strength of this study is its long-term follow-up, albeit high drop out. The data suggest that even in the unique subpopulation of patients with noniatrogenic chronic groin and testicular pain, neurectomy may be a viable treatment option

at relieving pain when all conservative options have been exhausted. A thorough history and examination, use of preoperative nerve blocks, and use of MRN will likely reduce misdiagnosis and mistreatment. Undoubtedly, larger-scale studies, preferably RCTs, would provide a better understanding of this unique population and their management.

## Conflict of Interest

None declared.

## References

- Cesmebasi A, Yadav A, Gielecki J, Tubbs RS, Loukas M. Genito-femoral neuralgia: a review. *Clin Anat* 2015;28(01):128–135
- Correll D. Chronic postoperative pain: recent findings in understanding and management. *F1000 Res* 2017;6:1054
- Kingsnorth A, LeBlanc K. Hernias: inguinal and incisional. *Lancet* 2003;362(9395):1561–1571
- Wu JM, Wechter ME, Geller EJ, Nguyen TV, Visco AG. Hysterectomy rates in the United States, 2003. *Obstet Gynecol* 2007;110(05):1091–1095
- Barone MA, Hutchinson PL, Johnson CH, Hsia J, Wheeler J. Vasectomy in the United States, 2002. *J Urol* 2006;176(01):232–236, discussion 236
- Parsons B, Schaefer C, Mann R, et al. Economic and humanistic burden of post-trauma and post-surgical neuropathic pain among adults in the United States. *J Pain Res* 2013;6:459–469
- Farrar JT, Young JP Jr., LaMoreaux L, Werth JL, Poole MR. Clinical importance of changes in chronic pain intensity measured on an 11-point numerical pain rating scale. *Pain* 2001;94(02):149–158
- Dworkin RH, Turk DC, Farrar JT, et al; IMMPACT. Core outcome measures for chronic pain clinical trials: IMMPACT recommendations. *Pain* 2005;113(1,2):9–19
- Nagarkar P, Ramanadham S, Chamseddin K, Chhabra A, Rozen SM. Neurectomy for the treatment of chronic postoperative pain after surgery of the trunk. *Plast Reconstr Surg* 2017;139(01):204–211
- Nguyen DK, Amid PK, Chen DC. Groin pain after inguinal hernia repair. *Adv Surg* 2016;50(01):203–220
- Poh F, Xi Y, Rozen SM, Scott KM, Hlis R, Chhabra A. Role of MR neurography in groin and genital pain: ilioinguinal, iliohypogastric, and genitofemoral neuralgia. *AJR Am J Roentgenol* 2019;212(03):632–643
- Fritz J, Dellon AL, Williams EH, Rosson GD, Belzberg AJ, Eckhauser FE. Diagnostic accuracy of selective 3-T MR neurography-guided retroperitoneal genitofemoral nerve blocks for the diagnosis of genitofemoral neuralgia. *Radiology* 2017;285(01):176–185
- Chhabra A, Ahlawat S, Belzberg A, Andreseik G. Peripheral nerve injury grading simplified on MR neurography: as referenced to Seddon and Sunderland classifications. *Indian J Radiol Imaging* 2014;24(03):217–224
- Zuniga JR, Mistry C, Tikhonov I, Dessouky R, Chhabra A. Magnetic resonance neurography of traumatic and nontraumatic peripheral trigeminal neuropathies. *J Oral Maxillofac Surg* 2018;76(04):725–736
- Chilla GS, Tan CH, Xu C, Poh CL. Diffusion weighted magnetic resonance imaging and its recent trend—a survey. *Quant Imaging Med Surg* 2015;5(03):407–422
- Attal N, Cruccu G, Baron R, et al. EFNS guidelines on the pharmacological treatment of neuropathic pain: 2010 revision. *Eur J Neurol* 2010;17(09):1113–e88
- Wan EL, Goldstein AT, Tolson H, Dellon AL. Injury to perineal branch of pudendal nerve in women: outcome from resection of the perineal branches. *J Reconstr Microsurg* 2017;33(06):395–401
- Kachniarz B, Dellon AL. Relief of sitting pain by resecting posterior femoral cutaneous nerve, and elucidation of its anatomical branching pattern. *J Reconstr Microsurg* 2021 (e-pub ahead of print). Doi: 10.1055/s-0041-1726027