



# Superradical Hysterectomy for Cervical Cancer as an Alternative to the Usual Okabayashi-Type Radical Hysterectomy

Masaki Mandai, MD, PhD<sup>1</sup> Ken Yamaguchi, MD, PhD<sup>1</sup> Junzo Hamanishi, MD, PhD<sup>1</sup>  
Kentaro Sekiyama, MD<sup>1</sup> Eiji Kondoh<sup>1</sup>

<sup>1</sup>Department of Gynecology and Obstetrics, Graduate School of Medicine, Kyoto University, Sakyo-ku, Kyoto, Japan

Address for correspondence Masaki Mandai, MD, PhD, Department of Gynecology and Obstetrics, Graduate School of Medicine, Kyoto University, 54 Shogoin Kawahara-cho, Sakyo-ku, Kyoto 606-8507, Japan (e-mail: mandai@kuhp.kyoto-u.ac.jp).

Surg J (NY) 2021;7(suppl S2):S108–S114.

## Abstract

### Keywords

- ▶ superradical hysterectomy
- ▶ cervical cancer
- ▶ internal iliac vessels
- ▶ locally advanced
- ▶ Mibayashi

Radical hysterectomy is a standard operation for invasive cervical cancers. However, if the invasion to the parametrium is more advanced than estimation in the operation, it is difficult to perform usual radical hysterectomy. Superradical hysterectomy was developed by Prof. Ryukichi Mibayashi of Kyoto University and was published in 1941, and has been performed for the limited cases by a part of Japanese gynecologic surgeons. Superradical hysterectomy is a procedure in which the soft tissues in the pelvis are removed en bloc by sequential processing of the internal iliac vessels, which leads to a complete dissection of the lymphatic tissue in the pelvis to the pelvic wall.

Radical hysterectomy is a standard operation for invasive cervical cancers. It is a rational procedure based on pelvic anatomy, and its application ranges from stage IA2 to stage IIB. Usually, the operability is judged by physical examination and by imaging such as magnetic resonance imaging. However, if the invasion to the parametrium is more advanced than estimation in the operation, it is difficult to perform usual radical hysterectomy. In such cases, radical hysterectomy is not only challenging as an operation but is also likely to result in incomplete surgery in terms of radicality. In addition, we sometimes feel that lymph nodes located behind the internal iliac vessels cannot be completely removed even after careful lymphadenectomy with radical hysterectomy in locally advanced cases. Superradical hysterectomy has recently attracted attention for such cases. Superradical hysterectomy was developed by Prof. Ryukichi Mibayashi of Kyoto University and was published in 1941<sup>1</sup> (originally published in Japanese), more than 50 years ago. Originally, it was developed to apply for stage IIIB cervical cancer. Subsequently, this method has been continuously improved in Japan, and it has been performed until now in some surgeons. Nevertheless, this procedure is not still recognized as a general operative procedure compared with usual

radical hysterectomy, and it has only been performed for the limited cases by a part of gynecologic surgeons.

Superradical hysterectomy, in a word, is a procedure in which the soft tissues in the pelvis are removed en bloc by sequential processing of the internal iliac vessels rather than by ligating and cutting the uterine arteriovenous vessels that drain directly into the uterus (▶Fig. 1A). This leads to a complete dissection of the lymphatic tissue in the pelvis to the pelvic wall (▶Fig. 1B).

## Surgical Steps

1. Laparotomy and intraperitoneal observation  
↓
2. Dissection of the round ligament and development of the retroperitoneal space  
↓
3. Pelvic lymphadenectomy  
↓
4. Identification and detachment of the ureter

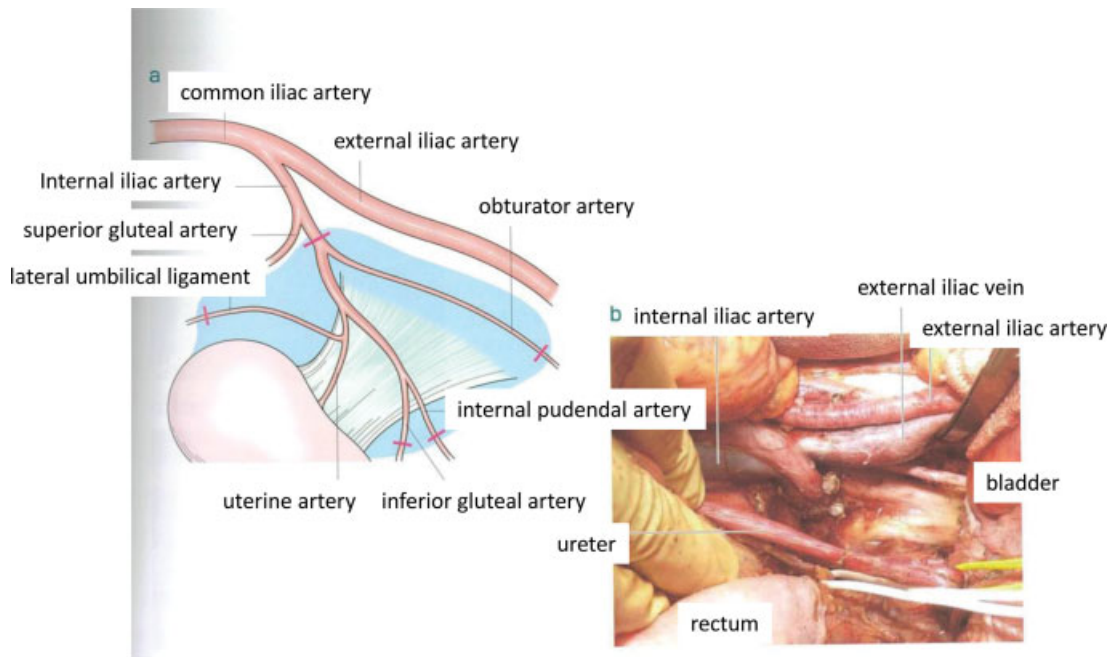
published online  
October 22, 2021

DOI <https://doi.org/10.1055/s-0041-1736177>.  
ISSN 2378-5128.

© 2021. The Author(s).

This is an open access article published by Thieme under the terms of the Creative Commons Attribution-NonDerivative-NonCommercial-License, permitting copying and reproduction so long as the original work is given appropriate credit. Contents may not be used for commercial purposes, or adapted, remixed, transformed or built upon. (<https://creativecommons.org/licenses/by-nc-nd/4.0/>)

Thieme Medical Publishers, Inc., 333 Seventh Avenue, 18th Floor, New York, NY 10001, USA



**Fig. 1** (A, B) Concept of superradical hysterectomy.

- ↓
5. Identification, isolation, and cleavage of the uterine artery
- ↓
6. Development of the paravesical space and the pararectal space
- ↓
7. Dissection of the obturator artery and vein
- ↓
8. Dissection of the internal iliac artery
- ↓
9. Dissection of the internal iliac vein
- ↓
10. Disconnection of the soft tissue medially from the lateral wall
- ↓
11. Dissection of the internal pudendal artery and vein
- ↓
12. Dissection of the inferior gluteal artery and vein
- ↓
13. Pull up the uterine artery and deep uterine vein to the uterine side
- ↓
14. Detachment of the rectum from the uterus
- ↓
15. Detachment of the bladder from the uterus
- ↓
16. Dissection of the paravaginal tissue (paracolpium)
- ↓
17. Hysterectomy
- ↓
18. Closed abdomen

1. *Laparotomy and intraperitoneal observation*: The laparotomy is performed by the incision to the supraumbilicus, and the peritoneal cavity is closely observed. If there is no indication for surgery due to intraperitoneal dissemination or metastatic to other organs, or if there is direct invasion of the rectum or bladder and it is judged that radicality cannot be achieved even with a superradical procedure, a different strategy should be chosen.
2. *Dissection of the round ligament and development of the retroperitoneal space*: The round ligament is dissected and the retroperitoneal space is widely deployed. Identify the ureter. Then, the medial side of the internal iliac artery is deployed dorsally, and the rectal space is tentatively deployed. The paravesical space is also tentatively deployed lateral to the lateral umbilical ligament, and further isolate the lateral umbilical ligament from the bladder.
3. *Pelvic lymphadenectomy (to the level of obturator nerve)*: Pelvic lymph dissection to the level of the obturator nerve is performed. If possible, the dorsal side of the obturator nerve should be isolated as clean as possible so that the course of the internal iliac vein can be identified. If this can be done easily, this procedure is likely to be relatively easy; however, in many cases, it is difficult due to enlarged lymph nodes. Even in this case, it is important to remove as large a lymph node tissue as possible to debulk the tumor, and to keep the surgical field as clean as possible so that the procedure can be performed safely.
4. *Identification and detachment of the ureter*: The ureter is detached from the posterior mesenchyme as is the usual radical hysterectomy and separated to the entrance of the ureteral tunnel. If the ureter is completely involved by the tumor, consider whether to remove it.

### 5. Identification, isolation, and cleavage of the uterine artery:

This procedure is similar to radical hysterectomy. It is not necessarily necessary to cut the uterine artery when performing a superradical procedure, but it is better to perform this procedure to smoothly perform an anterior procedure. The cut uterine artery separates the intersection with the ureter to reveal the entrance of the ureteral tunnel.

6. *Development of the paravesical space and the pararectal space:* This operation is not easy in many cases in which the superradical operation is necessary. Conversely, if these side cavities can be cleanly opened, it is considered that the usual radical hysterectomy is possible. However, to clarify the anatomy, the space that can be opened should be kept as open as possible. Approximately, at this stage, it is imperative to decide whether to perform a usual radical procedure or to switch to a superradical procedure.

7. *Dissection of the obturator artery and vein:* When the decision is made to perform a superradical hysterectomy, it is good to start with the cutting of the obturator artery and vein. Even in the presence of lesions at the origin of the cardinal ligament or obturator nodes, the pelvic floor on the caudal side of the paravesical space is often not involved, and the pelvic floor can be clarified by cutting the obturator artery and vein. There are usually no large vessels other than the obturator artery and vein on the caudal side of the paravesical space, so first, the adipose tissue is carefully removed to expose the pelvic floor muscles and to expose the pelvic floor as far cranially as possible.

8. *Dissection of the internal iliac artery:* Dissection of the internal iliac artery is relatively easy unless the lesion involves the internal and external arterial bifurcations. The artery from the bifurcation is revealed and the internal iliac artery is cut on the peripheral side just distal to the bifurcation of the superior gluteal artery (►Fig. 2). The central side should always be double ligated. The thread of peripheral side should be kept long so that it can be pulled up in subsequent manipulation.

9. *Dissection of the internal iliac vein:* It is often more difficult compared with dissection of the internal iliac artery. First, the inside and outside of the vein are clearly revealed. The external iliac artery and vein are separated to free from the iliopsoas muscles so that the external and internal iliac vein bifurcations can be exposed to the external side of the internal iliac vein. Further open the cranial side of the pararectal space and expose the internal iliac vein from the medial side to the dorsal side while cleaning the adipose tissue. After careful preparation of the cut site so as to isolate the vein, the vessel is ligated, and cut with forceps (►Fig. 3). The central side is always double ligated, and the peripheral thread is left long.

10. *Disconnection of the soft tissue medially from the lateral wall:* Soft tissue in the pelvis, including lymph nodes, is drawn toward the cardinal ligament while the thread left

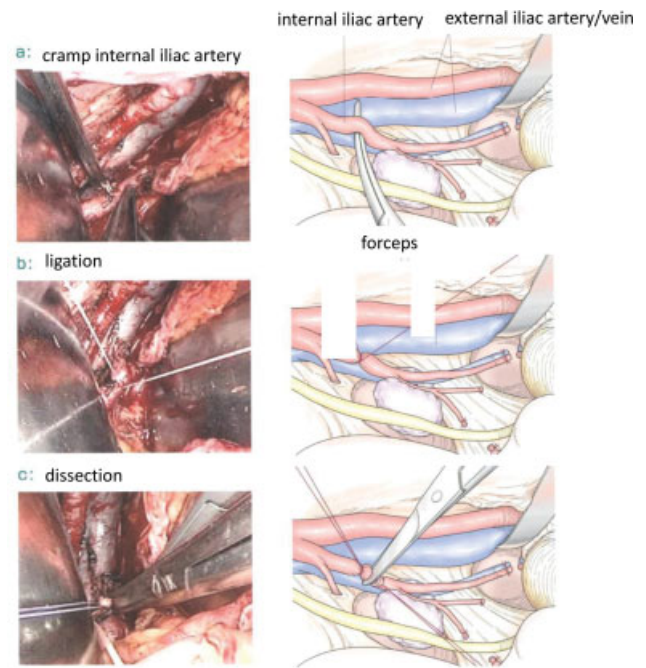


Fig. 2 Dissection of the internal iliac artery.

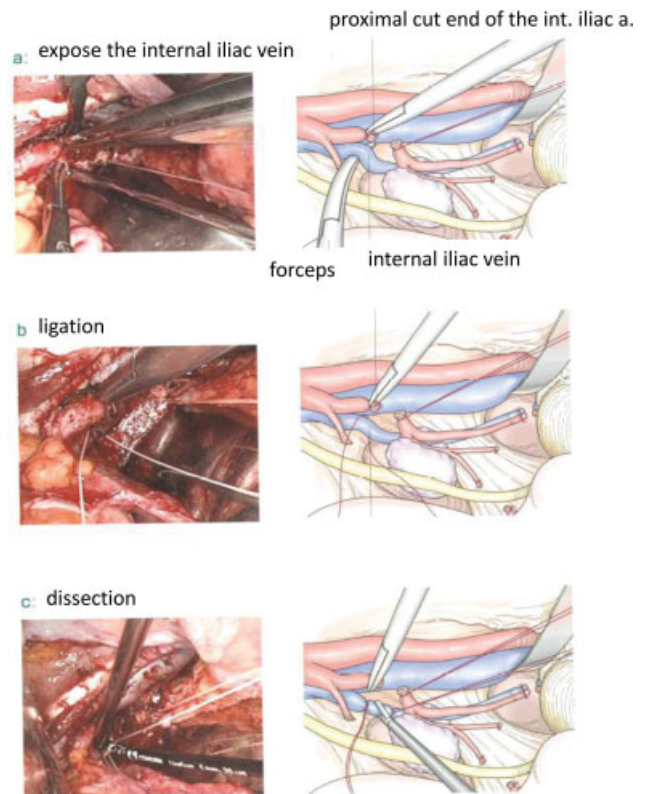
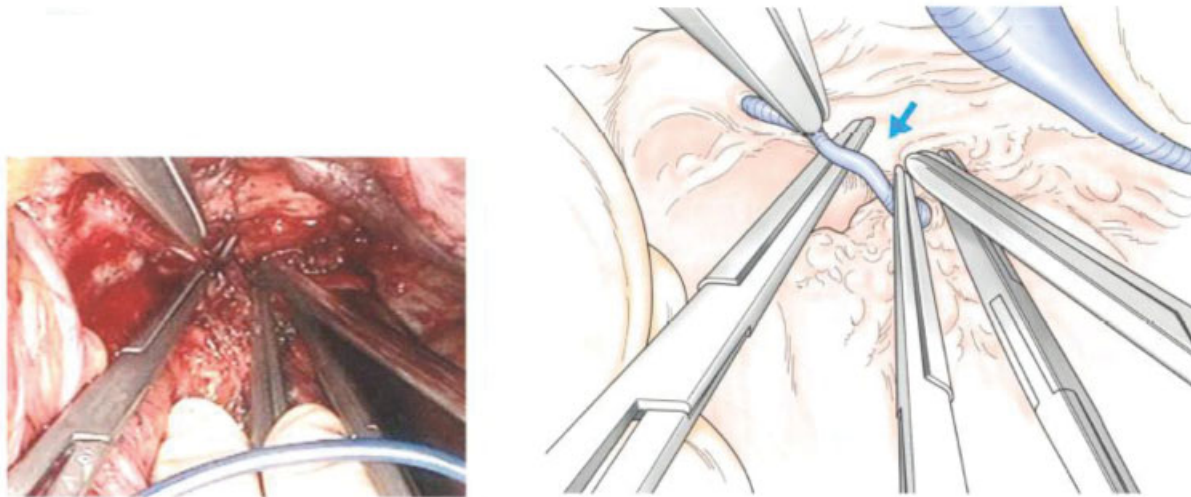


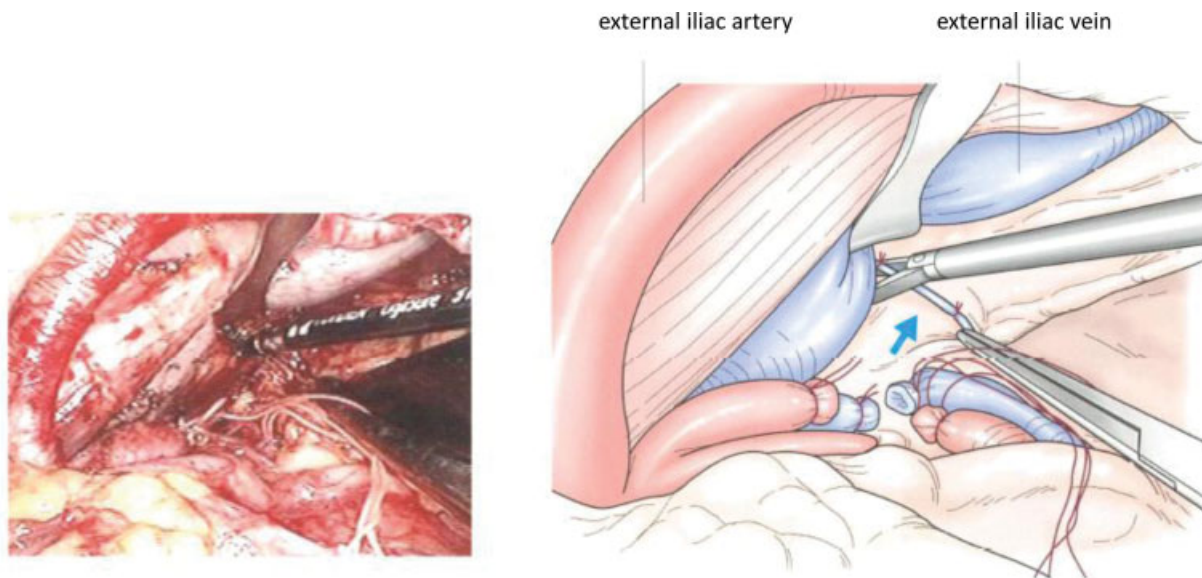
Fig. 3 Dissection of the internal iliac vein.

at steps 8 and 9 is pulled up medially. Since several communicating vessel branches exist between the pelvic wall, they are carefully separated and cut so as not to be pulled off (►Fig. 4). These blood vessels can be processed without any problem even with a LigaSure (►Fig. 5).





**Fig. 4** Dissection of the communicating vessels from the pelvic wall—no. 1.



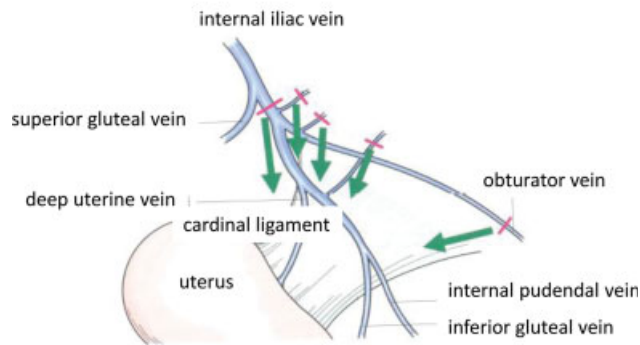
**Fig. 5** Dissection of the communicating vessels from the pelvic wall—no. 2.

11. *Dissection of the internal pudendal artery and vein:* The internal pudendal artery and vein may be ligated and cut after dissection of the inferior gluteal vessels (step 12). The vessels of the pelvic floor vary widely and it is often difficult to separate and cut as written in the book. Rather, this procedure can be performed safely by dissecting the tissue from the side of the pelvic wall toward the cardinal ligament, and by carefully dissecting the vessels exposed during the procedure (► **Fig. 6**). If there is a space, most of the vessels may be processed by a LigaSure, but in some cases, there is no space for inserting the device, and in this case, ligation and cutting are performed securely by a narrow right angle forceps (► **Fig. 7**). Vascular clips can be used if you are familiar with them. Cutting vessels are safe if they can be exposed as clearly as possible.

12. *Dissection of the inferior gluteal artery and vein:* Remaining vessels from the pelvic floor are carefully processed (► **Fig. 8**). This makes the tissue in the pelvis connected only with the cardinal ligament so that they can be removed en bloc with the uterus.

13. *Pull up the uterine artery and deep uterine vein to the uterine side:* Tissue is pulled medially to the cervix with caution for other remaining vessels.

14. *Detachment of the rectum from the uterus:* This procedure is performed as in usual radical hysterectomy. In the case in which the cardinal ligament invasion is recognized, many of them also show the invasion to sacrouterine ligament and rectovaginal ligament. In these cases, nerve preservation is not considered, and sufficiently radical resection should be performed. That is, the rectum is completely separated and both ligaments are cut close to the rectum.



**Fig. 6** Dissection of the internal pudendal artery and vein.

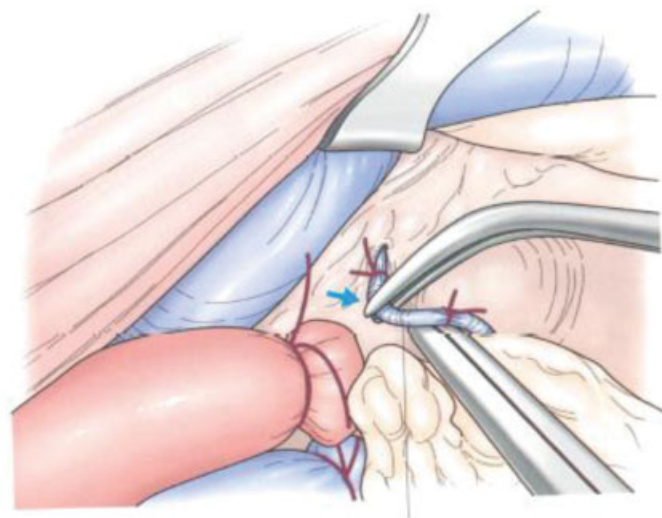
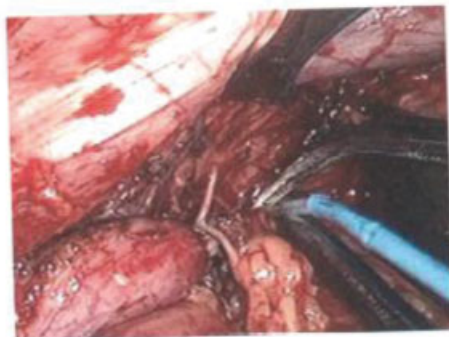
15. **Detachment of the bladder from the uterus:** This procedure is also performed as in usual radical hysterectomy. However, in cases requiring a superradical procedure, it may have invasion in the posterior layer of the vesicouterine ligament close to the bladder. Therefore, in this case, the adipose tissue in the paravesical space is carefully removed, which reveal the bladder outline, and the posterior layer of the bladder uterine ligament is cut as close as possible to the bladder.
16. **Dissection of the paravaginal tissue (paracolpium):** The paravaginal tissue is cut at a level close to the pelvic floor so that the vaginal wall can be dissected sufficiently.
17. **Hysterectomy:** The appropriate portion of vaginal dissection should be reviewed again before uterine extraction. Check for residual tissue around the vaginal canal, and make additional dissection of rectovaginal ligaments if it is insufficient. Cut the vagina at a level that is adequately radical. The vaginal stump is sutured with absorbent thread, similar to the usual total hysterectomy.
18. **Closure:** When closing the abdomen, thoroughly check for hemostasis and look again carefully for any remaining tissue (► **Fig. 9**). When the uterus is removed, the pelvic

floor is better visualized, and it may be noticed that adipose tissue or lymphoid tissue remain and are removed additionally. Presacral lymph nodes are more likely to be dissected after hysterectomy. If enlarged lymph nodes are found, they should be submitted for rapid intraoperative pathology, and the results will determine whether further cranial lymph node dissection should be performed. In our department, dissection to the common iliac lymph node is performed if obvious pelvic lymph node metastasis is not found intraoperatively, while para-aortic lymph node dissection to the level of the inferior mesenteric artery is added when the pelvic lymph node metastasis is found.

Closure is similar to radical hysterectomy. A drain is inserted and the abdomen is closed in the usual manner.

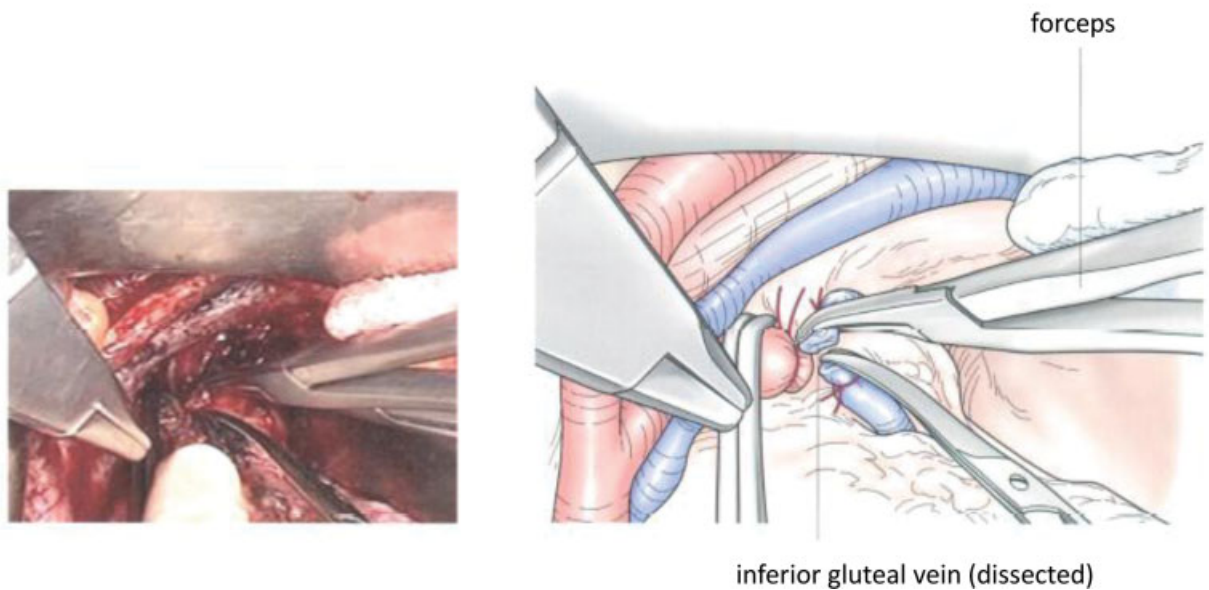
### Superradical Hysterectomy and Nerve Preservation

Superradical procedure and preservation of the pelvic nerve are not necessarily technically contradictory. Pelvic nerve preservation is a manipulation medial to the internal iliac vessels beside the uterus, and superradical hysterectomy is a manipulation lateral of the internal iliac vasculature. Theoretically, it is possible to combine superradical surgery with nerve preservation if the normal anatomy is kept. In reality, however, in most of the cases where superradical hysterectomy is indicated, it is impossible to preserve the pelvic nerve from a technical point of view or from a radical point of view because big tumor occupies near the cardinal ligament. That is to say, the voiding function must be sacrificed if this operative method is necessary in both sides. If the contralateral side is minimally invasive and the usual radical procedure is considered sufficient, nerve-sparing techniques can significantly improve the patient's postoperative quality of life.

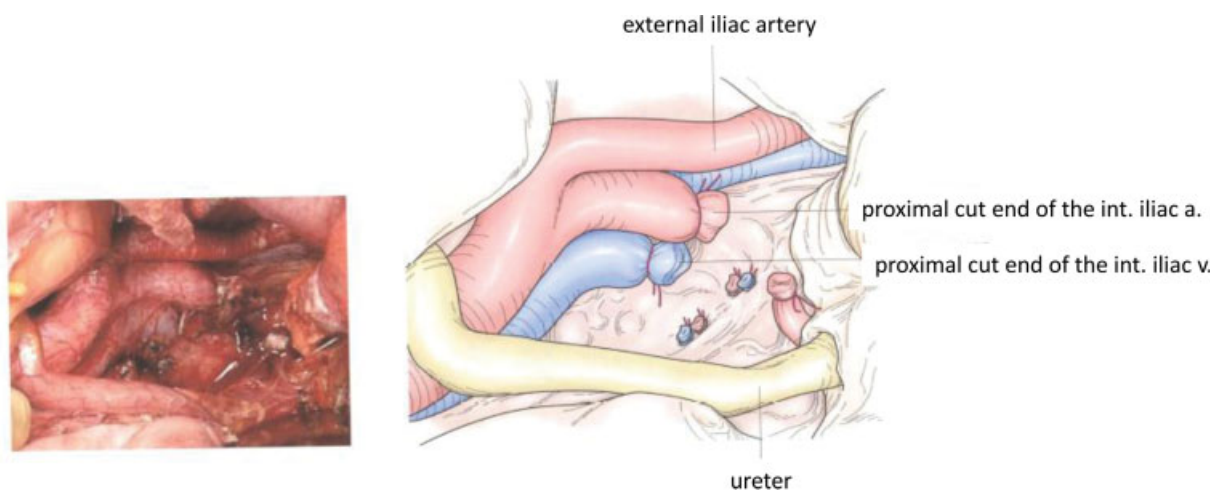


internal pudendal vein

**Fig. 7** Dissection of the internal pudendal vein.



**Fig. 8** Dissection of the inferior gluteal vein.



**Fig. 9** Postoperative pelvic view.

### Indication for Superradical Hysterectomy

Superradical hysterectomy is not yet a well-established procedure and has no clear indication for which cases to perform. In our department, the analysis of pathological specimens after neoadjuvant chemotherapy for patients with stage IIb cervical cancer has shown that minute lymph node metastases are often retained in these patients, and we assume that in such cases, a superradical procedure may be planned from the beginning to ensure complete dissection of lymph nodes in the pelvis. However, such indications should be clarified in the future by clinical studies.

Therefore, the main indication for superradical hysterectomy at present is the case in which we judged preoperatively that the resection was possible by usual radical hysterectomy, but the intraoperative findings indicate that the complete extraction was difficult by usual radical hysterectomy, and it was judged that resec-

tion was likely to be only achieved by performing the superradical operation method. In other words, superradical hysterectomy would be essentially a type of surgery that is performed intraoperatively and as an emergency evacuation.

### Further Application of Superradical Hysterectomy

The extent of resection in superradical hysterectomy may be applicable to other surgeries. For example, in pelvic exenteration, if the lesion is only in the central region, the lateral side may be dissected within the extent of radical hysterectomy, that is, medial to the internal iliac vessels. However, in cases where the lesion extends somewhat to the pelvic side, dissection should be performed to the pelvic wall as far as the extent of the superradical procedure. Also, when a large mass of ovarian cancer involves in the Douglas fossa that



invades the lateral lymph nodes of the rectum, a superradical procedure may be required to remove it.

### Essential Concept of Superradical Hysterectomy in Terms of Other Similar Procedures

The procedure was named as superradical hysterectomy by Prof. Ryukichi Mibayashi, Kyoto University, and has been commonly used in Japan, while it is somewhat vague to describe the procedure properly. Recently, similar conceptual procedures have been shown in countries other than Japan with some differences in extent of resection, and they have been reported under the names, laterally extended parametrectomy<sup>2</sup> and laterally extended endopelvic resection.<sup>3</sup> In Querleu and Morrow's criteria,<sup>4</sup> superradical hysterectomy may correspond to type D1 hysterectomy. Furthermore, similar concept of radical surgery including extirpation of internal iliac vessels are intensively applied not only in gynecologic surgery but also in other pelvic surgeries. Therefore, at present, superradical hysterectomy should be taken as a modification of pelvic lymphadenectomy procedure to intend complete resection of lymphatic tissues to the pelvic side. In this view, this procedure can be more easily performed under laparoscopy or by robotic

surgery, and standardization of the procedure should be established.

### Conclusion

Superradical hysterectomy may be effective than usual radical hysterectomy in limited cases of cervical cancer, though the procedure is more complicated. Exact application of this method should be determined in future trial.

#### Conflict of Interest

None declared.

### References

- 1 Mikami M, Ungar L, Matsu K. Indication, technique, and outcome of super-radical hysterectomy for cervical cancer. In: *Surgery for Gynecologic Cancer*. Singapore: Springer Nature Singapore Pte Ltd; 2019:117–133
- 2 Ungar L, Palfalvi L. Surgical treatment of lymph node metastases in stage IB cervical cancer: the laterally extended parametrectomy (LEP) procedure. *Int J Gynecol Cancer* 2003;13(05):647–651
- 3 Höckel M. Laterally extended endopelvic resection. Novel surgical treatment of locally recurrent cervical carcinoma involving the pelvic side wall. *Gynecol Oncol* 2003;91(02):369–377
- 4 Querleu D, Morrow CP. Classification of radical hysterectomy. *Lancet Oncol* 2008;9(03):297–303