




# Allinside Anatomic Arthroscopic (3A) Reconstruction of Irreparable TFCC Tear

Andrea Atzei, MD<sup>1</sup>  Fabio Andrés Tandioy-Delgado, MD<sup>2</sup> Lucian Lior Marcovici, MD<sup>3</sup>   
 Thomas W. Aust, Dipl. Ing.<sup>4</sup> Riccardo Luchetti, MD<sup>5</sup> 

<sup>1</sup>Pro-Mano, Hand Surgery and Rehabilitation, Treviso, Italy

<sup>2</sup>Hand Surgery, Clinica las Américas, Medellín, Antioquia, Colombia

<sup>3</sup>Hand & Microsurgery Unit, Jewish Hospital of Rome, Rome, Italy

<sup>4</sup>Arthrex GmbH, München, Germany

<sup>5</sup>Rimini Hand and Upper Limb Surgery & Rehabilitation Center, Rimini, Italy

Address for correspondence: Andrea Atzei, MD, Pro-Mano, Hand Surgery and Rehabilitation, Treviso, Italy  
 (e-mail: andreatzei@gmail.com).

J Wrist Surg 2023;12:2–8.

## Abstract

**Background** In recent years, new arthroscopic techniques have been introduced to address the irreparable tears of the triangular fibrocartilage complex (TFCC) (Palmer type 1B, Atzei class 4) by replicating the standard Adams–Berger procedure. These techniques, however, show the same limitations of the open procedure in relation to the anatomically defective location of the radial origins of the radioulnar ligaments (RUL) and the risk of neurovascular and/or tendon injury. Aiming to improve the quality of reconstruction and reduce surgical morbidity, a novel arthroscopic technique was developed, with the advantages of reproducing the anatomical origins of the RUL ligaments and providing all-inside tendon graft (TG) deployment and fixation.

**Description of Technique** The Allinside anatomic arthroscopic (3A) technique is indicated for TG reconstruction of irreparable TFCC tears in the absence of distal radioulnar joint (DRUJ) arthritis. Standard wrist arthroscopy portals are used. A small incision in the radial metaphyseal area and arthroscopic control are required to set a Wrist Drill Guide and create two converging tunnels, whose openings are at the radial anatomical origins of the RUL. An ulnar tunnel is drilled at the fovea from inside-out via the 6U portal. A 3-mm tendon strip, from the palmaris longus or extensor carpi radialis brevis, is woven through the tunnels and then secured into the ulnar tunnel with an interference screw. Postoperative immobilization with restricted forearm rotation is discontinued at 5 weeks, and then postoperative rehabilitation is started.

**Patients and Methods** The 3A technique was applied on 5 patients (2 females and 3 males), with an average age 42 years. DRUJ stability, range of motion (ROM), pain (0–10 visual analogue scale [VAS]), grip strength, modified Mayo wrist score (MMWS), and patient satisfaction were used for evaluation before surgery and at follow-up.

**Results** No intraoperative or early complications were registered. At a mean follow-up of 26 months, DRUJ was stable in all patients, which recovered 99% ROM. Pain VAS decreased from 7 to 0.6. Grip strength increased from 38 to 48.8 Kgs. There were 4 excellent results and 1 good result on MMWS. All patient showed high satisfaction.

## Keywords

- ▶ Wrist
- ▶ Arthroscopy
- ▶ TFCC
- ▶ Chronic Tear
- ▶ DRUJ
- ▶ Instability
- ▶ Reconstruction
- ▶ Tendon Graft

received

April 14, 2021

accepted

August 10, 2021

article published online

October 5, 2021

© 2021. Thieme. All rights reserved.  
 Thieme Medical Publishers, Inc.,  
 333 Seventh Avenue, 18th Floor,  
 New York, NY 10001, USA

DOI <https://doi.org/10.1055/s-0041-1735981>.  
 ISSN 2163-3916.

**Conclusions** Although the 3A technique requires dedicated instrumentation and arthroscopic expertise, it takes advantage of improved intra-articular vision and minimized surgical trauma to reduce the risk of complications and obtain promising functional results.

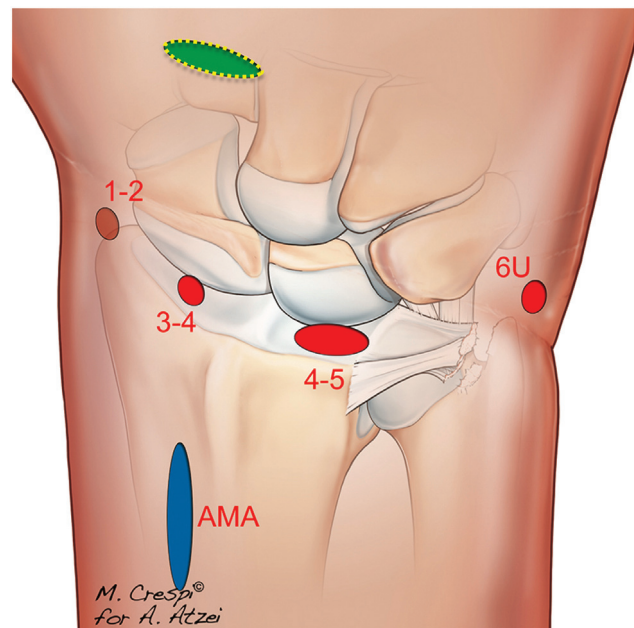
Technical advancements of wrist arthroscopy have allowed a continuous improvement in diagnosis and treatment of traumatic injuries of the triangular fibrocartilage complex (TFCC). In recent years, many arthroscopic-assisted techniques (AATs) have been introduced to reproduce surgical procedures originally described to repair tears of the peripheral TFCC, the so-called Palmer type 1-B tear,<sup>1</sup> and restore stability of the distal radioulnar joint (DRUJ). The enhanced intra-articular visualization provided by the arthroscope has allowed a more accurate diagnostic approach not only to assess tear's location and the competence of the foveal insertions but also evaluate the quality of tear's edges. This is a key factor to define which tear is amenable to either repair or reconstruction. In the absence of DRUJ arthritis, irreparable TFCC peripheral tears are defined as class 4 of the classification system proposed by Atzei and Luchetti<sup>2</sup> and reconstruction with a tendon graft (TG) is indicated. Currently, the technique published by Adams and Berger<sup>3</sup> is considered the gold standard for reconstruction of posttraumatic DRUJ instability, following irreparable TFCC tears. The whole palmaris longus (PL) is used as a TG, which is introduced into a sagittal tunnel, drilled through the distal radius, at the convergence of the lunate facet and sigmoid notch, directed into another tunnel through the distal ulna, and then sutured to itself around the ulnar neck. The conversion of this technique into an AAT was intended to improve the quality of reconstruction and reduce surgical morbidity.<sup>4</sup> The enhanced intra-articular view permits a more precise location of the ulnar tunnel, and the deployment of the TG through the palmar ulnocarpal ligaments (UCL), to achieve a "complete" reconstruction of the TFCC, not of the radio-ulnar ligaments (RUL) alone, as in the open technique. However, by keeping the same position of the radial tunnel as in the original open technique, this arthroscopic approach still fails to replicate the anatomical area of insertion of the RUL on the radius. Nonetheless, there is still considerable risk of injuring the ulnar neurovascular bundle (UNVB), the extensor tendons and/or the dorsal sensory branch of the ulnar nerve (DSBUN) through the three miniopen approaches required to expose the palmar and dorsal aspect of the radius and the medial aspect of the ulnar neck. Moreover, tunnel drilling requires fluoroscopic guidance.<sup>5,6</sup> Several techniques have been proposed to address these latter issues either by open, arthroscopic, or even combined approaches. The present technical note is aimed to describe the technical details and early clinical experience with a new arthroscopic procedure of TG reconstruction of the TFCC, which was developed as a minimally invasive procedure, with the advantages of reproducing the anatomical origins of the RUL using arthroscopic guidance, thus avoiding the need of intraoperative fluoroscopy, and allowing for an all-inside

TG deployment and fixation, thus also avoiding the need of accessory para-articular miniopen incisions. Starting from the aforementioned premises, this technique has been named as the Allinside anatomic arthroscopic (3A) technique.

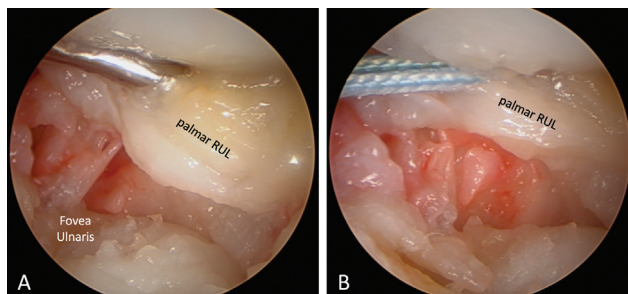
## Surgical Technique

The procedure is indicated for DRUJ instability following an irreparable TFCC peripheral tear (Palmer type 1-B, Atzei class 4), as diagnosed by a preliminary diagnostic arthroscopy. Contraindications are as follows: positive ulnar variance greater than 4 mm, DRUJ arthritis, gross longitudinal forearm instability, and retained hardware from prior internal fixation of distal radius fracture.

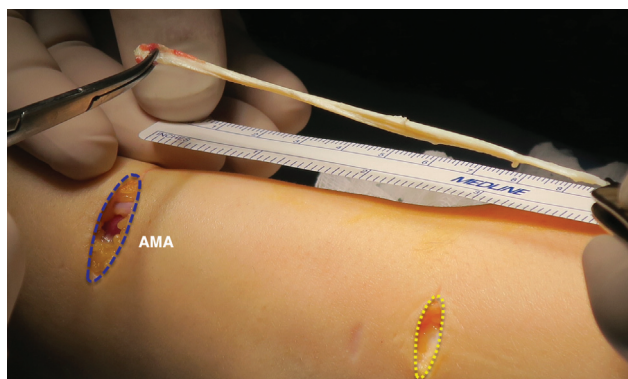
A standard wrist dry arthroscopy setup is used<sup>7</sup> (→Fig. 1). The 1–2 viewing portal is preferred in small wrists. The 4–5 and 6U portals are used to debride the TFCC and expose the fovea ulnaris. To protect the DSBUN, careful blunt dissection of the 6U portal and use of dry arthroscopy are recommended. A 4.0-mm cannulated drill bit creates the ulnar tunnel via the 6U portal from the fovea to perforate the ulnar neck. The interval between the UCL is opened by blunt dissection, using a mosquito via the 4–5 portal. A shuttle



**Fig. 1** Arthroscopic portals and accessory miniopen approach (AMA) required for the Allinside Anatomic Arthroscopic (3A) technique. The 1–2 viewing portal is preferred in small wrists. The AMA is centered approximately 3 cm proximal to the Lister's tubercle on the ulnar aspect of the extensor carpi radialis brevis (ECRB) tendon. It can also be used to harvest a strip of the ECRB, and then a counterincision at the base of the 2nd metacarpal is required (yellow dotted line).

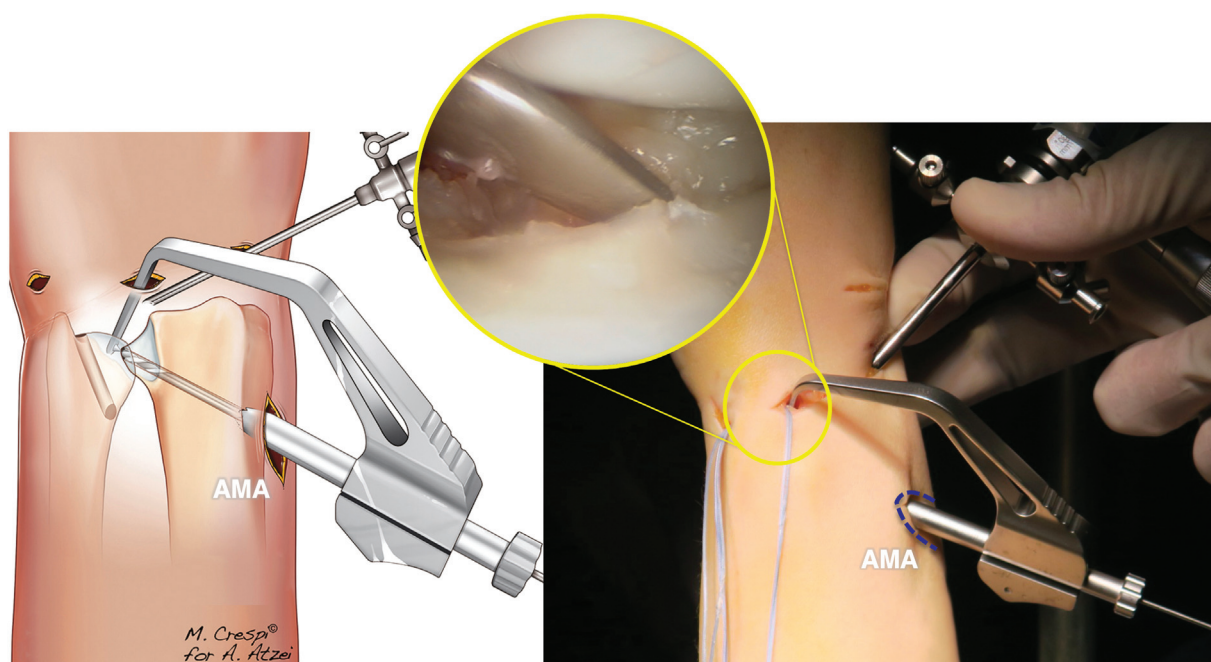


**Fig. 2** After debridement of the central disk, the interval between the ulnocarpal ligaments is perforated just distal to the palmar radioulnar ligament (RUL) (A) and a shuttle suture is introduced (B) for later passage of the tendon graft.

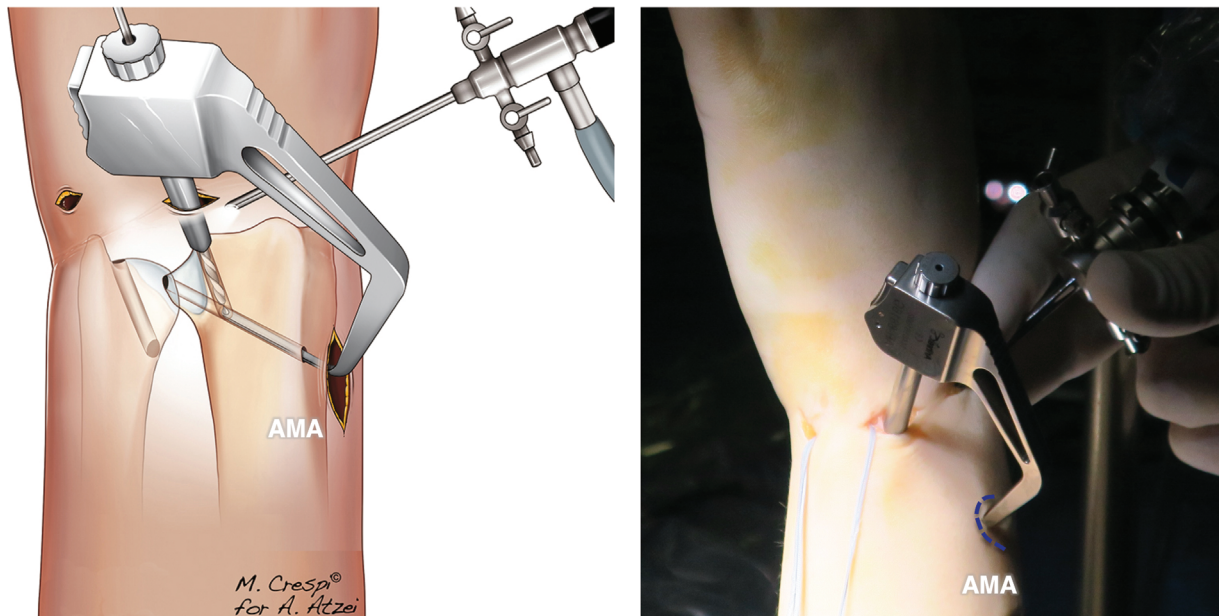


**Fig. 3** A 10- to 12-cm strip of extensor carpi radialis brevis tendon is harvested through the accessory miniopen approach (AMA) and a counterincision at the base of the 2nd metacarpal is required (yellow dotted line), as an alternative to the standard palmaris longus graft. A 3-mm width usually suffices.

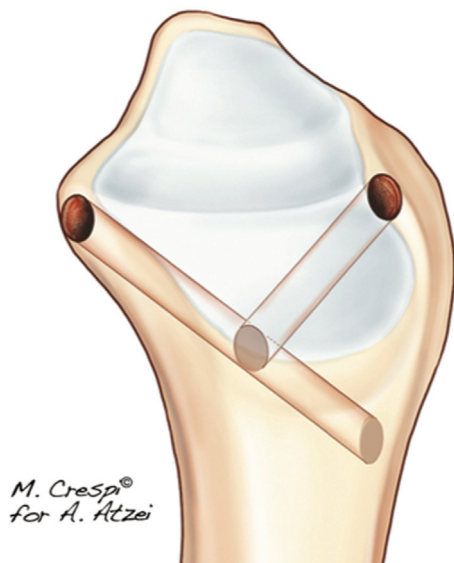
suture (SS) is loaded on a SutureLasso (Arthrex Co., Naples, FL) and introduced in the interval between the UCL (►Fig. 2) and then left outside 4–5 and 6U portals. An accessory miniopen approach (AMA) is created ulnar to the extensor carpi radialis brevis (ECRB) tendon, centered approximately 3 cm proximal to the Lister's tubercle. In selected cases, as an alternative to the standard 10 to 12 cm long PL graft, a 3-mm strip of the ECRB is harvested through the AMA and a counterincision at the base of the 2nd metacarpal (►Fig. 3). The sleeve of the Wrist Drill Guide (WDG - Arthrex Co., Naples, FL) is accommodated against the radial cortex at the AMA, and the aiming tip is set, under arthroscopic guidance via the 4–5 portal, over the origin of the RUL on the palmar corner of the radius (►Fig. 4). A 3.0-mm cannulated drill bit is used to create the palmar tunnel (PT). The WDG's aiming tip is introduced in the PT through the AMA, and its sleeve is set over the origin of the RUL, the dorsal corner of the radius, via the extended 4–5 portal (►Fig. 5), taking care to protect the extensor digiti quinti tendon. Using a 3.0-mm cannulated drill bit, a half-tunnel is created to join the PT in a Y-shaped configuration (►Fig. 6). A FiberTape (Arthrex Co., Naples, FL) is deployed within the tunnel, so that both extremities are retrieved outside the 4–5 portal (►Fig. 7). The FiberTape is swung back and forth several times to compact the metaphyseal cancellous bone and allow for a later safe passage of the TG. The extremities of the TG are whipstitched for easier shuttling past the radial tunnel (and the UCL interval for the palmar extremity) through the 6U portal. Then, both whipstitches are loaded on a SutureLasso (Arthrex Co., Naples, FL) and shuttled through the ulnar tunnel across the skin (►Fig. 8). Consequently, both extremities of the TG are pulled into the ulnar tunnel. A 4 × 10 mm



**Fig. 4** On artist's rendering and intraoperative pictures: The Wrist Drill Guide (Arthrex Co., Naples, FL) is accommodated with the sleeve against the radial cortex at the accessory miniopen approach (AMA) and the aiming tip over the origin of the radioulnar ligaments on the palmar corner of the radius, via the 4–5 portal, under arthroscopic guidance (see round insert). The palmar tunnel is created using a 3.0-mm cannulated drill bit.



**Fig. 5** On artist's rendering and intraoperative pictures: the aiming tip of the Wrist Drill Guide is introduced in the palmar tunnel (PT) through the accessory miniopen approach (AMA) and its sleeve is set over the origin of the radioulnar ligaments, the dorsal corner of the radius, via the extended 4–5 portal. Care is taken to protect the extensor digiti quinti tendon.



**Fig. 6** Artist's rendering of the Y-shaped tunnel created in the radial metaphysis. Note the placement of the tunnels' entrances at the anatomical origins of the radioulnar ligaments.

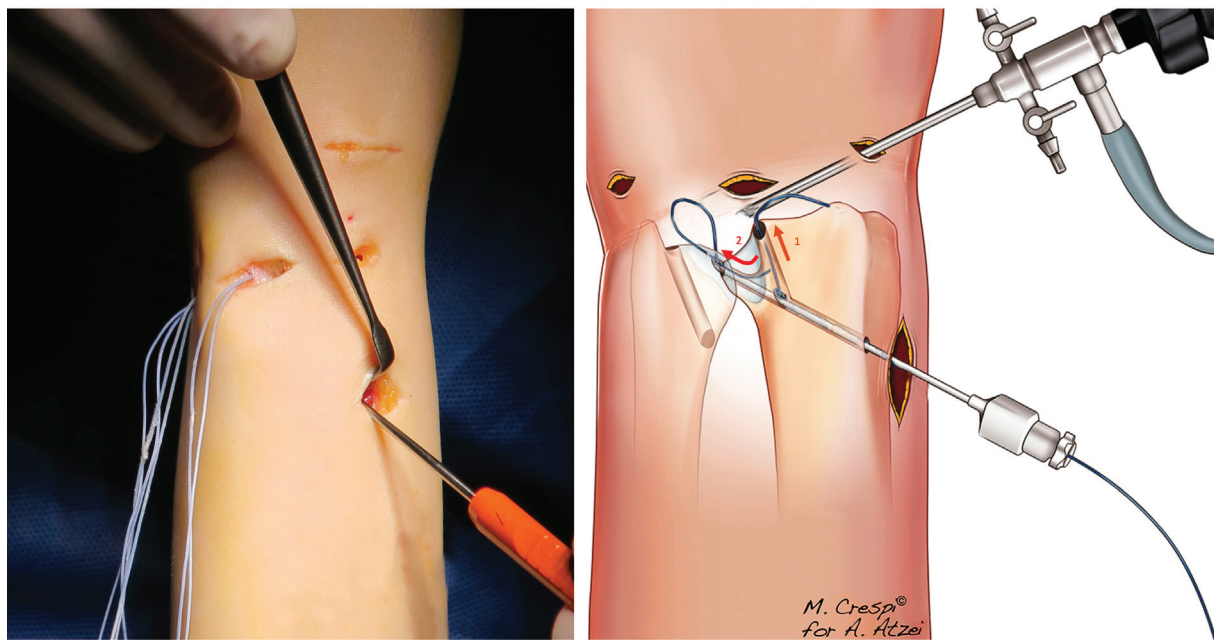
polyether ether ketone (PEEK) interference screw (Tenodesis screw, Arthrex Co., Naples, FL), introduced in a retrograde (inside-out) fashion from the 6U portal, is used to secure the TG into the ulnar tunnel (► **Fig. 9**). After wound closure, a long arm slab is applied in neutral forearm rotation and maintained for 3 weeks, and then it is replaced with a removable muenster splint to allow for light protected use of the hand. The splint is removed only for rehabilitation until the 5th week and then is progressively discontinued. Strengthening exercises are allowed after the 12th week.

## Case Series

The 3A technique was employed in 5 patients, 3 males and 2 females, with a mean age of 42 years. The injured side included 3 right and 2 left wrists. All male patients were heavy manual workers. Presenting symptoms were chronic ulnar-sided wrist pain and gross DRUJ instability lasting for more than 2 years. No previous surgeries were reported. Diagnostic arthroscopy confirmed that all patients fulfilled the inclusion criteria. Patient pre- and postoperative evaluation included the following: DRUJ stability, range of motion (ROM), pain (0–10 visual analogue scale [VAS]), grip strength, and modified Mayo wrist score (MMWS). Patient satisfaction was reported as poor, fair, or high.

The 3-mm tendon strip was taken from the PL in 2 cases and from the ECRB in 3 cases. Operating time averaged 101 minutes. The following specific intraoperative complications were sought out, but none of them were identified: injury to the DSBUN, superficial radial nerve, or lateral antebrachial cutaneous nerve; chondral damage to the lunate facet and/or sigmoid notch; fracture of the ulnar head; TG rupture or loss of TG fixation; hardware breakage; or infection.

At a mean follow-up of 26 (min 17–max 34) months, DRUJ was stable in all patients. ROM averaged 99% of contralateral side. VAS score decreased from 7/10 to 0.6/10. Grip strength improved from 38 to 48.8 kg. Patients showed 4 excellent and 1 good MMWS score. Heavy manual workers returned to their work activity at a mean 7 months after surgery, being able to complete their tasks with minimal exertional pain. All patients showed high satisfaction with the results.



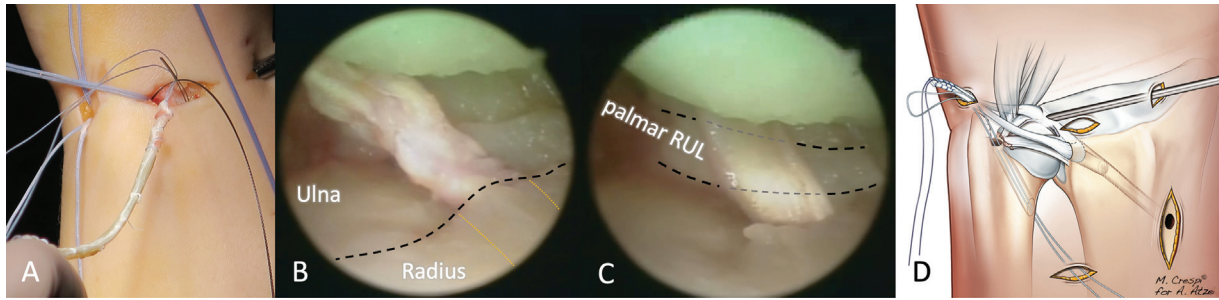
**Fig. 7** On intraoperative pictures and artist's rendering: A SutureLasso (Arthrex Co., Naples, FL) is used to deploy a shuttle suture within the Y-shaped tunnel with a back and forth maneuver, so that both extremities are retrieved outside the 4–5 portal. Taking advantage of the curvature of the SutureLasso, the extremity of the suture is deployed through the exit of the dorsal tunnel firstly (1), then the SutureLasso is introduced in the palmar tunnel, so that the suture protrudes into the joint, creating a loop (2), which is easily retrieved and deployed outside the joint. Then, a FiberTape (Arthrex Co., Naples, FL) is switched and swing back and forth several times to compact the metaphyseal cancellous bone of the radius.

## Discussion

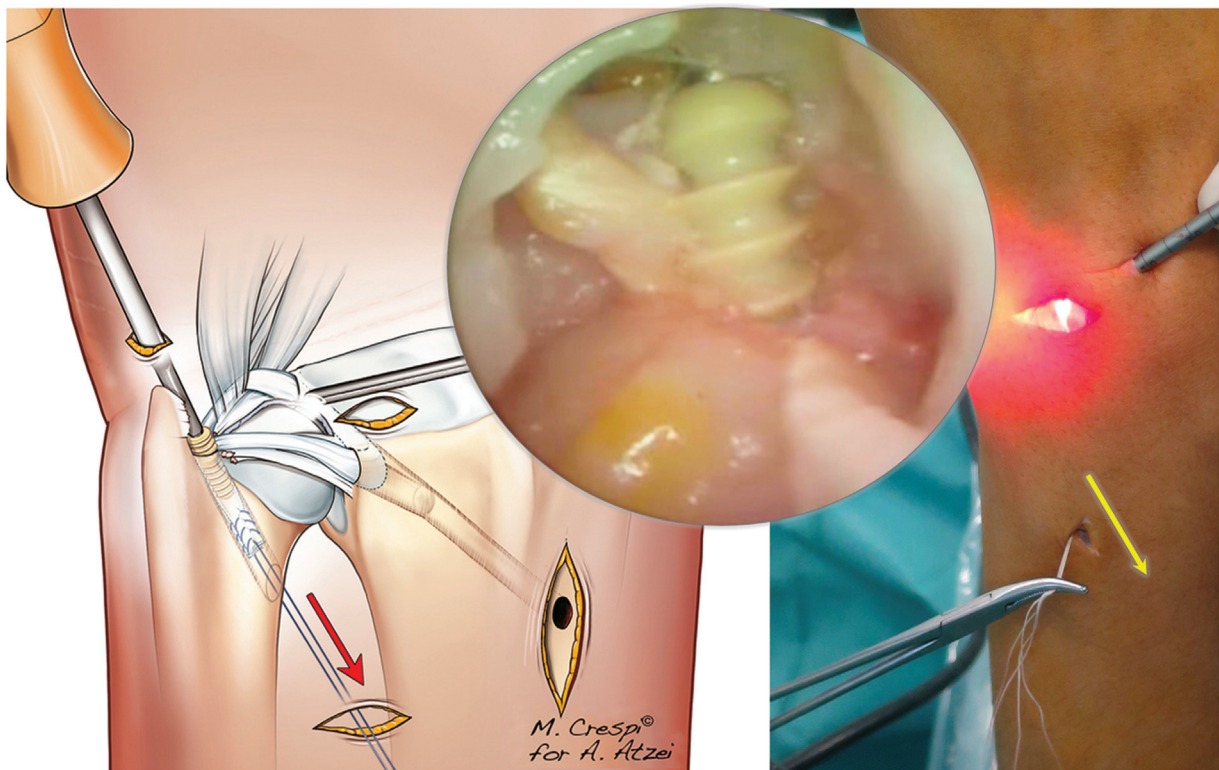
In 1983, Mansat established the concept of restoring RUL following irreparable tears of the TFCC by creating a transosseous tunnel in the distal radius to accommodate a free TG.<sup>8</sup> The Adams–Berger procedure also introduced a transosseous tunnel for ulnar fixation, replicating the anatomy of RUL foveal attachment.<sup>3</sup> The same anatomical accuracy was not warranted for the placement of the radial tunnel, whose openings fail to replicate the radial anatomical attachments of RUL. Biomechanical testing indicates that this reconstruction is unable to fully restore DRUJ stability without limiting forearm rotation.<sup>9</sup> In the clinical setting, these findings may convert in either restriction of forearm rotation or elongation, and even rupture, of the TG, causing recurrent DRUJ instability. Adams and Berger<sup>3</sup> reported the outcome of 14 open TFCC reconstructions and showed 14.3% of recurrent DRUJ instability at a mean follow-up of 2.2 years. Teoh and Yam reviewed 9 patients and found 22.2% of DRUJ instability at 9 years follow-up.<sup>10</sup>

A series of 95 Adams–Berger procedures showed a 14% overall failure rate.<sup>11</sup> Also, at last follow-up (median 38.5 months), 5.3% of patients had an unstable DRUJ, and 3.4% had some residual laxity.<sup>11</sup> At an average of 13.3 months postoperatively, 60% of failures required revision surgeries to treat DRUJ instability. TG was elongated in 8 (9.1%) cases and ruptured in 2 (2.3%) cases: one at the ulnar tunnel and one at the radial tunnel volarly.<sup>11</sup> In a retrospective evaluation of 22 patients treated with the Adams–Berger procedure, Kootstra et al attributed the reason for the three TG ruptures (13.6%) to the acute kinking at the sharp entrance of the radial tunnel.<sup>12</sup> Recently, new open surgical techniques were developed to restore a more accurate

anatomy for the radial tunnels and overcome these problems. Scheker and Ozer described an open technique using angled tunnels over the anatomical origins of the RULs and reported no DRUJ instability in 56 patients reviewed at an average follow-up of 4 years.<sup>13</sup> Major limitations of this technique were the wide exposure and the complexity of the multiple tunneling across the radial metaphysis. Following the biomechanical studies by Martineau et al,<sup>14</sup> Henry developed a simpler open technique using coronally oriented oblique tunnels.<sup>15</sup> However, wide exposure of the ulnar side of the wrist, to address both the palmar and dorsal corners of the sigmoid notch, and a radial counter incision, to retrieve the two ends of the TG, are required. The stratagem to use oblique tunnels to replicate the radial attachments of the RUL at the corners of the sigmoid notch is crucial to preserve the cartilage of both the lunate facet and sigmoid notch, especially at the level of the palmar lip the radius, whose thin shape may break even with 2.5-mm drilling. As an alternative, Bowers described an open reconstruction, recreating the dorsal and palmar RUL by drilling within the sigmoid notch, with good clinical outcomes.<sup>16</sup> Biomechanical testing confirmed the ability to restore of DRUJ but, intuitively, it is likely that joint kinematics must be altered as the size of the sigmoid notch is decreased because of placement of the TG.<sup>9</sup> Compared with the standard Adams–Berger technique, the AATs<sup>4,5</sup> have brought further improvements, such as the inclusion of the UCL into the reconstruction, which is technically easier to perform under arthroscopic assistance, and fixation of the TG in the ulnar tunnel with an interference screw, which is a common device in the arthroscopic armamentarium. The AATs seem to show a reduced recurrence of DRUJ instability. Only 2 cases (7%) and 1 case (9%) were reported by Chu-Kay Mak and



**Fig. 8** On artist's rendering and intraoperative pictures: the palmar extremity of the tendon graft is shuttled from 4–5 portal (A) to the palmar origin of the radioulnar ligament (RUL) (B) and through the interval of the ulnocarpal ligaments (interrupted line shows the medial border of the lunate facet); yellow dotted lines represent tunnel's profile under the lunate facet (C). It exits through the 6U portal (interrupted lines show the palmar RUL), where the dorsal extremity is also retrieved (D).



**Fig. 9** On artist's rendering and intraoperative pictures: the tendon graft is pulled percutaneously and secured into the ulnar tunnel using a 4 × 10 mm polyether ether ketone (PEEK) interference screw.

Ho<sup>17</sup> and Luchetti and Atzei,<sup>6</sup> respectively. It is probably due to the rerouting of the TG through the 4–5 arthroscopic portal and the palmar capsule/UC interval, rather than taking it directly into the foveal tunnel, as in the open procedure. However, since three miniopen incisions are still required to drill the tunnels, and for TG deployment and fixation, a true minimal invasivity cannot be achieved. Intraoperative complications are reported to arise especially from damage to the UNVB, which is at risk also in the arthroscopic procedures. In a series of 95 patients treated by open Adams–Berger reconstruction,<sup>11</sup> neuropraxia of the ulnar nerve was reported in 6 patients (6.3%) and a painful neuroma, requiring excision, in another patient (1%). Using the AAT in 28 patients, Chu-Kay Mak and Ho reported neuropraxia of the ulnar nerve in 3 patients (10.5%): in 1 patient (3.5%) being

entrapped by the TG and in 2 other patients (7%) sustaining forceful retraction during operation.<sup>17</sup> Discomfort over the ulnar incision, although without true paresthesia of the DSBUN, is also a common complication of the AAT, accounting for 10.5%<sup>17</sup> up to 45.5%.<sup>6</sup> These findings confirm the need for a truly minimally invasive technique. With this purpose and aiming to improve the anatomical accuracy of reconstruction, an arthroscopic modification of Bowers technique has been recently described, which takes advantage of improved intra-articular vision through the arthroscope and sophisticated miniaturized tenodesis screws to minimize surgical trauma.<sup>18</sup> However, as a dorsal and palmar 3.0-mm drilling of the sigmoid notch is required to accommodate the TG, the same limitations and concerns can be raised for Bowers technique. Complications may also arise from

TG fixation at the ulnar tunnel. One case of tendon loosening<sup>17</sup> and one case of painful scalloping of the ulnar neck<sup>6</sup> were reported with the loop-around-the-ulnar-neck fixation method, which may also give reason for some persistent pain of unknown origin in the open series.<sup>11</sup> Use of the interference screw in an out-in fashion was related to increased rate of procedural and mechanical failure in the open Adams–Berger procedure, especially if an allograft tendon is used.<sup>11</sup> Luchetti and Atzei, using a 4.0-mm interference screw with the AAT, reported one case of ulnar fracture, which resulted in a stable DRUJ following the standard postoperative immobilization period.<sup>6</sup> To overcome the above-mentioned issues, the 3A technique was developed as a minimally invasive arthroscopic-assisted procedure, requiring only a small incision in a safe area over the radial metaphysis, clear from the major neurovascular structures of the wrist. Under the magnification provided by the arthroscope, use of a wrist guide facilitates and improves the accuracy of tunnel placement at the anatomical origins of the RUL. Drilling oblique tunnels prevents fracture of the palmar lip of the radius. As an additional advantage of using arthroscopic guidance, intraoperative fluoroscopy is no longer necessary, thus simplifying the technique and reducing the operating time. Inside-out application of the interference screw, which advances in the same direction of the pulling of the TG, improves fixation by providing for an increased tension. Furthermore, the conical shape of the interference screw prevents TG abrasion at the edge of the ulnar tunnel. In our clinical series, no complications occurred: particularly, the DSBUN was not disturbed during the retrograde (in-out) drilling of the ulnar tunnel via the 6U portal nor tendon adhesions developed with percutaneous tensioning of the ends of the TG out of the ulnar tunnel. Functional assessment indicates promising results: DRUJ was stable in all patients, which recovered nearly full ROM and showed 4 excellent and 1 good result at the last follow-up. Some limitations to this study can be acknowledged. First, sample size is limited. Second, the average follow-up of 26 months is short, although long enough to cover the 13.3 months' time frame during which technical failures may be detected.<sup>11</sup> Third, the lack of an objective method to assess DRUJ stability precludes conclusive results in comparison to different techniques. In conclusion, although the 3A technique requires dedicated instrumentation and advanced arthroscopic skills, the advantages in terms of functional outcome and reduction of complications seem to reward the endeavor.

#### Note

The study was performed at Pro-Mano, Hand Surgery and Rehabilitation, Treviso (Italy) and Casa di Cura Giovanni XXIII, Monastier di Treviso, Treviso (Italy).

#### Conflict of Interest

None declared.

#### References

- Palmer AK. Triangular fibrocartilage complex lesions: a classification. *J Hand Surg Am* 1989;14(04):594–606
- Atzei A, Luchetti R. Foveal TFCC tear classification and treatment. *Hand Clin* 2011;27(03):263–272
- Adams BD, Berger RA. An anatomic reconstruction of the distal radioulnar ligaments for posttraumatic distal radioulnar joint instability. *J Hand Surg Am* 2002;27(02):243–251
- Atzei A. New trends in arthroscopic management of type 1-B TFCC injuries with DRUJ instability. *J Hand Surg Eur Vol* 2009;34(05):582–591
- Tse WL, Lau SW, Wong WY, et al. Arthroscopic reconstruction of triangular fibrocartilage complex (TFCC) with tendon graft for chronic DRUJ instability. *Injury* 2013;44(03):386–390
- Luchetti R, Atzei A. Arthroscopic assisted tendon reconstruction for triangular fibrocartilage complex irreparable tears. *J Hand Surg Eur Vol* 2017;42(04):346–351
- Badur N, Luchetti R, Atzei A. Arthroscopic wrist anatomy and setup. In: Geissler WB, ed. *Wrist and Elbow Arthroscopy: A Practical Surgical Guide to Techniques*. New York: Springer Science & Business Media; 2015:1–28
- Mansat M, Mansat Ch, Martinez Ch. L'articulation radio-cubitale inférieure. Pathologie traumatique. In: Razemon JP, Fisk GR, eds. *Le poignet*. Monographies du Groupe d'Etude de la Main. Paris: Expansions Scientifiques Francaise; 1983:187–195
- Goffon WT, Gordon KD, Dunning CE, Johnson JA, King GJ. Comparison of distal radioulnar joint reconstructions using an active joint motion simulator. *J Hand Surg Am* 2005;30(04):733–742
- Teoh LC, Yam AK. Anatomic reconstruction of the distal radioulnar ligaments: long-term results. *J Hand Surg [Br]* 2005;30(02):185–193
- Gillis JA, Soreide E, Khouri JS, Kadar A, Berger RA, Moran SL. Outcomes of the Adams–Berger Ligament Reconstruction for the Distal Radioulnar Joint Instability in 95 Consecutive Cases. *J Wrist Surg* 2019;8(04):268–275
- Kootstra TJM, van Doesburg MH, Schuurman AH. Functional effects of the adams procedure: a retrospective intervention study. *J Wrist Surg* 2018;7(04):331–335
- Scheker LR, Ozer K. Ligamentous stabilization of the distal radioulnar joint. *Tech Hand Up Extrem Surg* 2004;8(04):239–246
- Martineau PA, Bergeron S, Beckman L, Steffen T, Harvey EJ. Reconstructive procedure for unstable radial-sided triangular fibrocartilage complex avulsions. *J Hand Surg Am* 2005;30(04):727–732
- Henry M. Anatomic reconstruction of the radioulnar ligament. *Hand (N Y)* 2012;7(04):413–419
- Bowers WH. The distal radioulnar joint. In: Green DP, Hotchkiss RN, Peterson WC, eds. *Green's Operative Hand Surgery*. 4th ed. Philadelphia: Churchill Livingstone; 1999:986–1032
- Chu-Kay Mak M, Ho PC. Arthroscopic-assisted triangular fibrocartilage complex reconstruction. *Hand Clin* 2017;33(04):625–637
- Carratalá Baixauli V, Lucas García FJ, Martínez Andrade C, Carratalá Baixauli R, Guisasola Lerma E, Corella Montoya F. All-arthroscopic triangular fibrocartilage complex ligamentoplasty for chronic DRUJ instability. *Tech Hand Up Extrem Surg* 2019;23(01):44–51