



# Internal Fixation of Scaphoid Nonunion with Humpback Deformity Using Iliac Graft and Volar Plate: Series of Eight Cases

## *Fixação interna de pseudoartrose de escafoide com deformidade angular associada utilizando enxerto de íliaco e placa volar: Série de oito casos*

Amanda Favaro Cagnolati<sup>1</sup> Fernanda Ruiz Andrade<sup>1</sup> Luis Guilherme Rosifini Alves Rezende<sup>1</sup>   
Nilton Mazzer<sup>2</sup> Raquel Metzker Mendes Sugano<sup>3</sup> Larissa Martins Garcia<sup>3</sup>

<sup>1</sup>Hand Surgery Program, Department of Orthopedics and Anesthesiology, Hospital das Clínicas, Faculdade de Medicina de Ribeirão Preto, Universidade de São Paulo, Ribeirão Preto, SP, Brazil

<sup>2</sup>Hand Surgery Division, Department of Orthopedics and Anesthesiology, Hospital das Clínicas, Faculdade de Medicina de Ribeirão Preto, Universidade de São Paulo, Ribeirão Preto, SP, Brazil

<sup>3</sup>Rehabilitation Center, Hospital das Clínicas, Faculdade de Medicina de Ribeirão Preto, Universidade de São Paulo, Ribeirão Preto, SP, Brazil

Address for correspondence Amanda Favaro Cagnolati, MD, Departamento de Ortopedia e Anestesiologia, Hospital das Clínicas, Faculdade de Medicina de Ribeirão Preto, Universidade de São Paulo, Campus Universitário, Ribeirão Preto, SP, 14049-900, Brazil (e-mail: amandafavaro@terra.com.br).

Rev Bras Ortop 2021;56(5):588–593.

### Abstract

**Objectives** The aim of the present article is a clinical and radiographic evaluation of scaphoid nonunion with humpback deformity using an iliac graft and a volar plate.

**Methods** Eight patients were followed-up prospectively, all male, with a mean age of 39.6 years old, with scaphoid waist nonunion, with an average of 19 months of trauma without previous surgery. The patients were treated with a graft removed from the iliac crest and a 1.5 mm blocked volar scaphoid plate (Medarthris AG, Basel, Switzerland). The patients were followed-up with radiographic evaluations and computed tomography (CT) scans in the preoperative period and 1 month, 3 months, 6 months and 1 year after the operation. The carpal height and the scaphosemilar and intrascaphoid angles were measured preoperatively, 3 months, and 1 year postoperatively. The function was assessed preoperatively and repeated 1 year postoperatively using the Disabilities of the Arm, Shoulder, and Hand (DASH) and Patient-related Wrist Evaluation (PWRE scores), as well as by measurement of forceps clamp and wrist and thumb range of motion.

**Results** All cases were consolidated, with an average time of 3.38 months. Two complications were observed: an infection of the iliac surgical wound and a plaque

### Keywords

- internal fixation
- pseudarthrosis
- scaphoid bone
- bone plates
- transplants

received  
December 16, 2020  
accepted  
April 12, 2021

DOI <https://doi.org/10.1055/s-0041-1735830>.  
ISSN 0102-3616.

© 2021. Sociedade Brasileira de Ortopedia e Traumatologia. All rights reserved.

This is an open access article published by Thieme under the terms of the Creative Commons Attribution-NonDerivative-NonCommercial-License, permitting copying and reproduction so long as the original work is given appropriate credit. Contents may not be used for commercial purposes, or adapted, remixed, transformed or built upon. (<https://creativecommons.org/licenses/by-nc-nd/4.0/>)

Thieme Revinter Publicações Ltda., Rua do Matoso 170, Rio de Janeiro, RJ, CEP 20270-135, Brazil

element placed in the scapholunate space. Two patients opted to remove the implant because they had a painful click at maximum wrist flexion. There was improvement in the parameters of wrist and thumb range of motion and pinch strength in all measurements, with statistical significance for the PRWE and the scapholunate angle.

**Conclusion** Although our sample was small, we achieved consolidation in all cases; the complications were expected in the literature and there were improvements in the radiographic patterns, in the functional assessment, and in the pain scale of our patients.

## Resumo

**Objetivos** A finalidade do presente artigo é avaliar os resultados clínicos, radiográficos e funcionais de pseudoartroses de escafoide com deformidade angular utilizando enxerto de íliaco e placa volar.

**Métodos** Foram seguidos prospectivamente 8 pacientes, todos do sexo masculino, com idade média de 39,6 anos, com pseudoartrose de cintura de escafoide, com tempo médio de 19 meses de trauma sem cirurgias prévias. Os pacientes foram tratados com enxerto retirado da crista ilíaca e placa volar para escafoide. Os pacientes foram submetidos a avaliações radiográficas e tomográficas no pré-operatório e em 1 mês, 3 meses, 6 meses e 1 ano de pós-operatório. A altura carpal e os ângulos escafossemilunares e intraescafoides foram medidos no pré-operatório e aos 3 meses e 1 ano do pós-operatório. A função foi avaliada no pré-operatório e repetida em 1 ano pós-operatório através do escore Disabilities of the Arm, Shoulder, and Hand (DASH, na sigla em inglês) e Patient-related Wrist Evaluation (PWRE, na sigla em inglês), assim como pela aferição de força de pinças e de amplitude de movimento do punho e do polegar.

**Resultados** Houve consolidação em todos os casos, com tempo médio de 3,38 meses. Foram observadas duas complicações: uma infecção de ferida operatória do íliaco e um parafuso da placa colocado no espaço escafossemilunar. Houve melhora nos parâmetros de amplitude de movimento do punho e do polegar e de força de pinça em todas as avaliações funcionais, com significância estatística do PRWE e do ângulo escafossemilunar.

**Conclusão** Apesar da nossa amostra ter sido pequena, obtivemos consolidação em todos os casos operados, com complicações esperadas na literatura e melhoras tanto no padrão radiográfico quanto na avaliação funcional e na escala de dor dos nossos pacientes.

## Palavras-chave

- fixação interna
- pseudoartrose
- osso escafoide
- placas ósseas
- enxertos

## Introduction

Scaphoid fractures are more common in men aged 15 to 40 years old. The major risk factors for pseudoarthrosis include deviated fractures, delayed medical attention, lack of diagnosis (hidden fractures), and fractures of the proximal pole of the scaphoid due to the increased risk of decreased arterial supply to this fragment.<sup>1,2</sup> Scaphoid pseudoarthrosis can be defined as stable or unstable. In unstable pseudoarthrosis, forces through the wrist induce a flexion movement of the proximal fragment of the scaphoid, resulting in a hump-back deformity. The loss of this radial carpal stabilization causes the wrist to collapse in a deformity pattern characterized by dorsal deviation of the lunate in lateral radiographies (dorsal intercalated segment instability [DISI]).<sup>1</sup> Since the edges of the unconsolidated proximal

and distal fragments of the scaphoid rub against each other, repeated loading cycles result in progressive erosion and bone loss.<sup>3</sup>

Conventional treatment of scaphoid pseudoarthrosis with bone loss typically involves the use of a corticocancellous bone graft placed between the proximal and distal fragments of the nonunion, possibly associated with an internal fixation. The graft can be harvested from the iliac crest or from the distal third of the radius, with no difference in consolidation rates according to the literature. Historically, Kirschner wires (k-wires) were used with the graft, followed by headless compression screws, isolated or in pairs. More recently, scaphoid-specific support plates were introduced.<sup>4,5</sup>

Studies on volar scaphoid plates placed with grafts appeared in 2016. Dodds et al.<sup>4</sup> used plates with pediculated

vascularized grafts based on the radial artery in nine patients and demonstrated that these devices could withstand the deforming forces resulting from an old scaphoid fracture and held the graft in place. In August 2016, Jurkowitsch et al.<sup>6</sup> concluded that, in biomechanical studies comparing compression plates and screws, fixation with plate was biomechanically superior to an isolated screw and equivalent to 2 compression screws.

A 1.5-mm scaphoid-specific plate was used in the present series of 8 cases of scaphoid pseudoarthrosis with bone resorption and hump deformity, along with a structured corticocancellous graft of the iliac crest. The objective was to evaluate consolidation, correction of radiographic parameters, and to perform functional and pain assessments during a follow-up period of 1 year after surgery.

## Material and Methods

The inclusion criteria were patients presenting a scaphoid fracture for at least 6 months, with no previous surgery, and with bone loss at the nonunion site and a hump deformity classified as type IIB (unstable pseudoarthrosis, with anterior bone defect and DISI) according to Alnot.

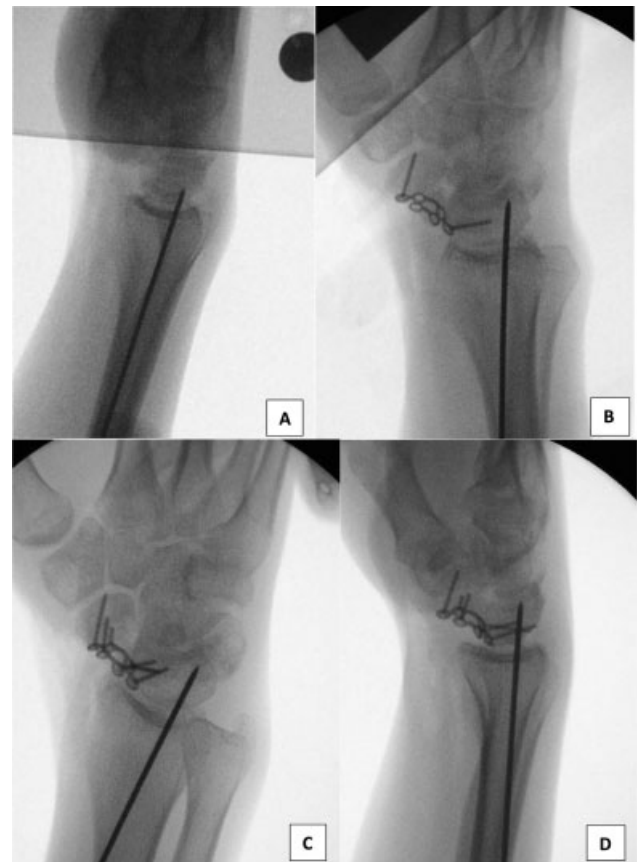
Anteroposterior (AP) and lateral radiographies of the affected wrist were performed for determination of the carpal height and of the scapholunate and intrascaphoid angles before surgery. Surgical planning also included radiographs of the contralateral wrist and a computed tomography (CT) scan of the affected wrist to ensure the correct length of the graft to be harvested and scaphoid size after grafting.<sup>4</sup>

Surgery was performed under general anesthesia with brachial plexus block on the affected side and an inflatable tourniquet on the arm. The classic Russe anterior approach was used. Curettage of the scaphoid edges was performed until viable bone was found, removing any potential interposed fibrous tissues. The volar defect was measured after opening the pseudoarthrosis focus, which was facilitated by 1.0-mm k-wires placed in each bone fragment to act as joysticks.

An image intensifier was used to ensure the proper correction of the scaphoid deformity. Lunate rotation was corrected with the insertion of a 1.5-mm k-wire to fixate the radius and the lunate. After measuring the bone defect, the contralateral iliac region of the patient was infiltrated with 2% lidocaine with a vasoconstrictor and incised over the iliac crest. The iliac graft was harvested with an oscillatory saw, creating a tricortical wedge with a core of corticocancellous graft, slightly bigger than the defect. A cancellous graft was also harvested and placed subsequently next to the plate.

A low-profile, locked plate (Medarthis AG, Basel, Switzerland) was applied to the volar face of the scaphoid. The plate was centered by AP fluoroscopy. Fixation started with two cortical screws, one in each fragment. Three screws were placed in each bone fragment. There was no need for routine locked screws, since the patients presented a good bone stock (—Figure 1).

The patients used a plaster cast immobilization, including the thumb, for 2 weeks postoperatively. After removal of the suture, the patients used an orthosis until consolidation



**Fig. 1** Images of intraoperative fluoroscopy. (A) Correction of the lunate extension using a Kirschner wire. (B) Placement of a cortical screw in each fragment. (C) Oblique view to confirm the correct size of the screws. (D) Last lateral radiograph showing the plate in the correct position, the coapted graft, and ideal screw sizes.

criteria, based on postoperative radiographs and CT scans, were met. Consolidation criteria included lack of pain, radiographic evidence of bone bridge through the graft (> 50% of bone trabeculae crossing the fragments on CT), and absence of signs of implant loosening.<sup>3</sup>

Outpatient follow-up visits occurred at 2 weeks (suture removal and immobilization replacement), 4 weeks (k-wire removal), 3 months, 6 months, and 1 year postoperatively. Radiographs were taken 4 weeks, 3 months, 6 months, and 1 year after surgery. Computed tomography scans were performed at 3 months and were repeated every 3 months if there was any doubt regarding consolidation.

Assessments were carried out with the physical therapy team before surgery and at 3, 6 and 12 months postoperatively. The evaluation was excluded from the study 6 months after surgery due to the nonattendance of some patients. These evaluations included lateral pinch strength test with a hydraulic dynamometer (PinchGauge), active range of motion of the thumb and wrist (flexion, extension, radial and palmar abduction of the thumb; flexion, extension, radial and ulnar deviations, pronation, and supination of the wrist), visual analog scale (VAS) for pain (at rest and during movement), and the Disabilities of the Arm, Shoulder, and Hand (DASH) and Patient-Rated Wrist Evaluation (PRWE) questionnaires.

Due to the small sample size, data were described as median, minimum, maximum, and standard deviation (SD) values. The Wilcoxon test compared physical therapy findings from the preoperative period and 1 year after surgery. Student t-tests compared radiographic parameters obtained preoperatively and 3 months and 1 year after surgery. Statistical significance was set at  $p < 0.05$ .

## Ethics

The present study was approved by the research ethics committee, according to resolution CNS 466/2012, on August 7, 2017, opinion number 2.204.444.

## Results

Eight male patients with scaphoid pseudoarthrosis on the dominant hand underwent surgery; the right side was affected in seven subjects, and the left side was affected in one patient. The average age of the patients was 39.6 years old (range: 27 to 65 years old).

The average time from trauma to surgery was 19 months (range: 6 to 24 months).

Bone consolidation was achieved in 100% of the patients at an average time of 3.38 months (only 1 patient had definite radiographic consolidation 6 months after surgery; the remaining patients presented definite radiographic consolidation at 3 months). All patients underwent CT scans 3 months after surgery; CT was repeated in 1 patient 6 months after the procedure due to doubts regarding consolidation.

One patient presented with severe pain as a complication, and the presence of a proximal plate screw at the scapholunate space was noted. The plate was removed 4 months after the procedure, when tomographic signs of consolidation were observed. One patient had an acute infection (28 days postoperatively) of the surgical wound in the iliac region. Surgical debridement and culture-guided antibiotic therapy resulted in wound healing.

Regarding radiographic parameters, the scapholunate angle, indicating carpal alignment, went from 65° (SD: 14.8) to 40° (SD: 40.2) after surgery, with  $p = 0.006$ . All functional parameters improved when comparing preoperative and 1-year postoperative findings: radial thumb abduction increased from an average value of 49.63° to 56°; the mean radial deviation increased from 12° to 14°; the ulnar deviation increased from 23° to 28°; the average wrist flexion increased from 53° to 61°; and wrist extension increased from 37° to 46°. Pinch strength and flexion and extension of the metacarpophalangeal joint of the thumb remained unaltered. Pain at rest decreased from 3 to 1.5, while pain during movement decreased from 8 to 5.3. The quick-DASH score decreased from 56 to 34 points, and the PRWE score decreased from 68 to 31 points, with  $p = 0.0190$  (► **Tables 1 and 2**).

## Discussion

The treatment of scaphoid pseudoarthrosis with plates has been described by Huene et al.,<sup>7</sup> who used a plate in the proximal fragment along with a screw in the distal fragment in complex cases in which screw fixation was not ideal. Plates must be reserved for cases with scaphoid hump deformity, unsuccessfully operated and with no room for an isolated screw. The plate acts as a latch, holding the graft in place, preventing its extrusion and nullifying the flexion forces that act on the scaphoid waist.<sup>8</sup>

The literature reports consolidation rates ranging from 71 to 95% with several grafts and headless Herbert-type compression screws. In 2011, Gohneim<sup>3</sup> reported consolidation in 93% of the 14 cases operated with a 1.5-mm Medartis plate. Dodds et al.<sup>4,8</sup> achieved an 87% consolidation rate, that is, in 8 out of 9 cases operated with a vascularized radial graft and scaphoid plate after an initial treatment failure. In 2017, these same authors increased this series to 20 subjects, observing consolidation in 18 cases (90%), with improved function and pain. As such, they demonstrated that this

**Table 1** Preoperative functional assessment of patients undergoing surgical treatment

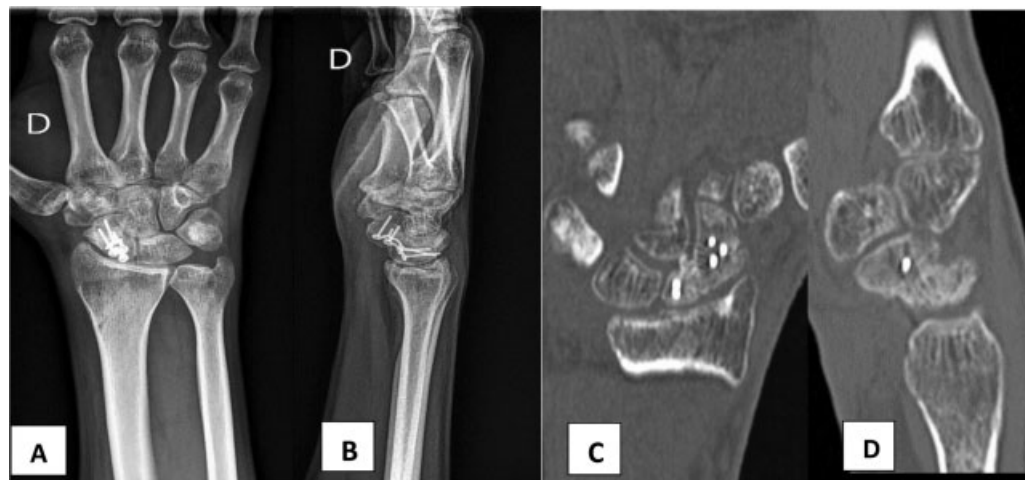PREOP	RADIAL ABD THUMB	FLEX MCP THUMB	EXT MCP THUMB	RADIAL DEV	ULNAR DEV	W FLEX	W EXT	REST VAS	VAS ROM	LPS	CLPS	QUICK DASH	PRWE
1	60	70	−6	20	38	90	66	0	9	7.6	7.8	52.27	57
2	50	50	0	10	25	45	35	2	5	19.3	22	80	78
3	40	50	0	15	20	60	10	3	9	5.3	9.3	34	55
4	65	60	0	20	25	85	60	5	10	10	10.5	82.3	89
5	24	40	20	20	20	46	40	5	10	10.5	11.7	86.3	80.5
6	48	60	0	20	16	24	24	7	9	6.5	9.5	27.3	55.5
7	60	54	0	20	20	50	24	2	8	9.7	10.7	45	66
8	50	60	0	20	20	30	42	0	4	4.2	9.2	45.5	63.5

Abbreviations: CLPS, contralateral lateral pinch strength; EXT MCP THUMB, extension of the metacarpophalangeal joint of the thumb; FLEX MCP THUMB, flexion of the metacarpophalangeal joint of the thumb; LPS, lateral pinch strength; PREOP, Preoperative; RADIAL ABD THUMB, radial abduction of the thumb; RADIAL DEV, radial deviation; REST VAS, visual analog scale for pain at rest; ULNAR DEV, ulnar deviation; VAS ROM, visual analog scale for range of motion; W EXT, wrist extension; W FLEX, wrist flexion.

**Table 2** One-year postoperative functional assessment of patients undergoing surgical treatment

POSTOP	RADIAL ABD THUMB	FLEX MCP THUMB	EXT MCP THUMB	RADIAL DEV	ULNAR DEV	W FLEX	W EXT	REST VAS	VAS ROM	LPS	CLPS	QUICK DASH	PRWE
1	60	60	0	20	30	70	40	0	8	9	9	40	38.5
2	60	60	0	14	42	80	70	2	3	4.7	11	11.8	24
3	54	60	0	6	18	54	22	0	3	9.3	10.3	18.2	27.5
4	60	60	0	8	30	56	64	2	2	10.7	10.5	25	29
5	24	40	0	18	20	46	40	5	10	10	11.7	86.3	80.5
6	60	56	0	10	30	60	40	0	4	9.83	8.3	37	9.09
7	68	50	0	8	30	30	40	0	6	11.6	14	15.5	14.5
8	62	60	0	28	24	92	52	3	9	7.2	9	40.9	27.5

Abbreviations: CLPS, contralateral lateral pinch strength; EXT MCP THUMB, extension of the metacarpophalangeal joint of the thumb; FLEX MCP THUMB, flexion of the metacarpophalangeal joint of the thumb; LPS, lateral pinch strength; PREOP, Preoperative; RADIAL ABD THUMB, radial abduction of the thumb; RADIAL DEV, radial deviation; REST VAS, visual analog scale for pain at rest; ULNAR DEV, ulnar deviation; VAS ROM, visual analog scale for range of motion; W EXT, wrist extension; W FLEX, wrist flexion.



**Fig. 2** Three months after surgery. (A) Anteroposterior radiograph showing a well-placed plate and consolidated pseudoarthrosis. (B) Lateral radiograph showing total integration between the fragments. (C) Frontal section of a computed tomography (CT) scan showing a bone bridge between the fragments. (D) Lateral CT image showing consolidation of pseudoarthrosis.

surgery was an alternative to salvage procedures in reoperated patients. Esteban-Feliu et al.,<sup>9</sup> in 2017, followed-up 15 patients for 3 years and achieved 87% of consolidation. The follow-up of the present study was of 12 months, and 100% consolidation was achieved in the 8 operated cases (→Figure 2).

The fact that the plate has a volar support and that it is placed within the joint can cause problems. Technically, in the intraoperative period, countless fluoroscopy images are recommended. These images must be in oblique views to determine scaphoid reduction, graft location, and the positioning of the plate and the screws. The penetration of intra-articular screws can be difficult to avoid, especially in the radioscapoid and, distally, the scaphotrapezotrapezoid joint. In addition, the plate must be removed 9 to 12 months after surgery in patients presenting an impact at maximal

wrist flexion and a painful click during wrist flexion.<sup>8,9</sup> Plate removal was required in one case because a screw was at the scapholunate space, and in two cases due to pain and limited wrist flexion. In more recent studies, from 2019, Burgos et al., despite achieving 100% consolidation in their series of 8 cases also operated with iliac crest grafts and volar plates, reported a decrease in range of motion and in grip strength 12 weeks after surgery.<sup>10</sup> In the functional evaluation of the present study, carried out 1 year after the procedure, all evaluated parameters improved; in addition, the PRWE score presented a significant improvement, dropping from 68 to 31 points ( $p = 0.01$ ).

The success of our cases is not exclusively due to the use of plates. Factors such as a relatively short pseudoarthrosis time (19 months), young patients with no comorbidities and with a good bone stock certainly influenced the success of



consolidations. The present series of cases has limitations, such as the small number of patients; we emphasize the need for a comparative study with headless screws. Due to the scarcity and high cost of plates compared with the wider availability and diversity of headless screws for the scaphoid bone, we believe that this technique will hardly be used in the short-term and routinely. However, it can be an option in selected cases and in recalcitrant pseudoarthrosis with previous consolidation failure.

## Conclusion

The use of a plate with an iliac graft in scaphoid pseudoarthrosis with angular deformity improved the carpal alignment, wrist mobility, and pain of the patients compared with preoperative findings. In addition, it increased DASH scores and presented consolidation and complication rates similar to those described in the literature. The need for further studies is emphasized, with a control group using Herbert-type screws and greater availability of the material used.

### Note

The present study was developed at the Department of Orthopedics and Anesthesiology of the Hospital das Clínicas, Faculdade de Medicina de Ribeirão Preto, Universidade de São Paulo (HC-FMRP-USP), Ribeirão Preto, SP, Brazil.

### Financial Support

There was no financial support from public, commercial, or non-profit sources.

### Conflict of Interests

The authors have no conflict of interests to declare.

## References

- 1 Bindra R, Bednar M, Light T. Volar wedge grafting for scaphoid nonunion with collapse. *J Hand Surg Am* 2008;33(06):974–979
- 2 Buijze GA, Ochtman L, Ring D. Management of scaphoid nonunion. *J Hand Surg Am* 2012;37(05):1095–1100
- 3 Ghoneim A. The unstable nonunited scaphoid waist fracture: results of treatment by open reduction, anterior wedge grafting, and internal fixation by volar buttress plate. *J Hand Surg Am* 2011;36(01):17–24
- 4 Dodds SD, Halim A. Scaphoid Plate Fixation and Volar Carpal Artery Vascularized Bone Graft for Recalcitrant Scaphoid Nonunions. *J Hand Surg Am* 2016;41(07):e191–e198
- 5 Cooney WP, Linscheid RL, Dobyns JH, Wood MB. Scaphoid nonunion: role of anterior interpositional bone grafts. *J Hand Surg Am* 1988;13(05):635–650
- 6 Jurkowitsch J, Dall'Ara E, Quadlbauer S, et al. Rotational stability in screw-fixed scaphoid fractures compared to plate-fixed scaphoid fractures. *Arch Orthop Trauma Surg* 2016;136(11):1623–1628
- 7 Huene DR, Huene DS. Treatment of nonunions of the scaphoid with the Ender compression blade plate system. *J Hand Surg Am* 1991;16(05):913–922
- 8 Dodds SD, Williams JB, Seiter M, Chen C. Lessons learned from volar plate fixation of scaphoid fracture nonunions. *J Hand Surg Eur Vol* 2018;43(01):57–65
- 9 Esteban-Feliu I, Barrera-Ochoa S, Vidal-Tarrason N, Mir-Simon B, Lluch A, Mir-Bullo X. Volar Plate Fixation to Treat Scaphoid Nonunion: A Case Series With Minimum 3 Years of Follow-Up. *J Hand Surg Am* 2018;43(06):569.e1–569.e8
- 10 Burgos FH, Nakamoto JC, Nakamoto HA, Iwase FDC, Mattar R. Treatment of scaphoid nonunion with volar locked plate. *Acta Ortop Bras* 2019;27(03):141–145