




Combined Pipeline Embolization Device with Endoscopic Endonasal Fascia Lata/Muscle Graft Repair as a Salvage Technique for Treatment of Iatrogenic Carotid Artery Pseudoaneurysm

Ann Liu¹  Jordina Rincon-Torroella¹ Matthew T. Bender^{1,2} Cameron G. McDougall¹
Anthony P. Tufaro^{3,4} Nyall R. London Jr⁵ Alexander L. Coon^{1,6} Douglas D. Reh^{5,7} Gary L. Gallia^{1,5}

¹ Department of Neurosurgery, Johns Hopkins Hospital, Baltimore, Maryland, United States

² Department of Neurosurgery, University of Rochester Medical Center, Rochester, New York, United States

³ Department of Plastic and Reconstructive Surgery, Johns Hopkins Hospital, Baltimore, Maryland, United States

⁴ Division of Plastic Surgery, Department of Surgery, The University of Oklahoma Health Sciences Center, Oklahoma City, Oklahoma, United States

⁵ Department of Otolaryngology-Head and Neck Surgery, Johns Hopkins Hospital, Baltimore, Maryland, United States

Address for correspondence Gary L. Gallia, MD, PhD, Department of Neurosurgery, Johns Hopkins Hospital, 600 North Wolfe Street, Baltimore, MD 21287, United States (e-mail: ggallia1@jhmi.edu).

⁶ Department of Neurosurgery, Carondelet Neurological Institute, Tucson, Arizona, United States

⁷ Department of Otolaryngology-Head and Neck Surgery, Greater Baltimore Medical Center, Baltimore, Maryland, United States

J Neurol Surg Rep 2021;82:e43–e48.

Abstract

Keywords

- ▶ endoscopic endonasal
- ▶ fascia lata
- ▶ iatrogenic carotid injury
- ▶ muscle graft
- ▶ pituitary adenoma
- ▶ Pipeline embolization
- ▶ pseudoaneurysm

The incidence of internal carotid artery (ICA) injury associated with endoscopic endonasal approaches to the pituitary is less than 1%. While parent vessel sacrifice has historically been the choice of treatment, vessel-preserving endovascular techniques have been reported. Although flow diversion offers endoluminal reconstruction, its major limitation is the delay in obtaining complete occlusion. We describe the use of a combined Pipeline embolization device (PED) with endoscopic endonasal repair using a fascia lata/muscle graft to treat an iatrogenic ICA pseudoaneurysm and report long-term radiographic follow-up. Further investigation into the utility of directed endoscopic endonasal repair of iatrogenic pseudoaneurysms initially treated with PED is necessary, especially given the need of post-PED anticoagulation and the rate of permanent neurological deficit after ICA sacrifice.

Introduction

Internal carotid artery (ICA) injury is a feared complication of transsphenoidal surgery (TSS). The incidence of ICA injury from TSS, either microscopic or endoscopic, has been reported to be less than 1%.^{1–6} Pseudoaneurysm formation

is a possible sequelae of ICA injury and can be difficult to treat. While parent vessel sacrifice has historically been the choice of treatment, vessel-preserving endovascular techniques, including embolization and endoluminal reconstruction, have been reported in the literature.^{7,8} Here, we describe the use of a combined approach of flow diversion

received
September 15, 2020
accepted after revision
January 14, 2021

DOI <https://doi.org/10.1055/s-0041-1735284>.
ISSN 2193-6358.

© 2021. The Author(s).

This is an open access article published by Thieme under the terms of the Creative Commons Attribution-NonDerivative-NonCommercial-License, permitting copying and reproduction so long as the original work is given appropriate credit. Contents may not be used for commercial purposes, or adapted, remixed, transformed or built upon. (<https://creativecommons.org/licenses/by-nc-nd/4.0/>)

Georg Thieme Verlag KG, Rüdigerstraße 14, 70469 Stuttgart, Germany

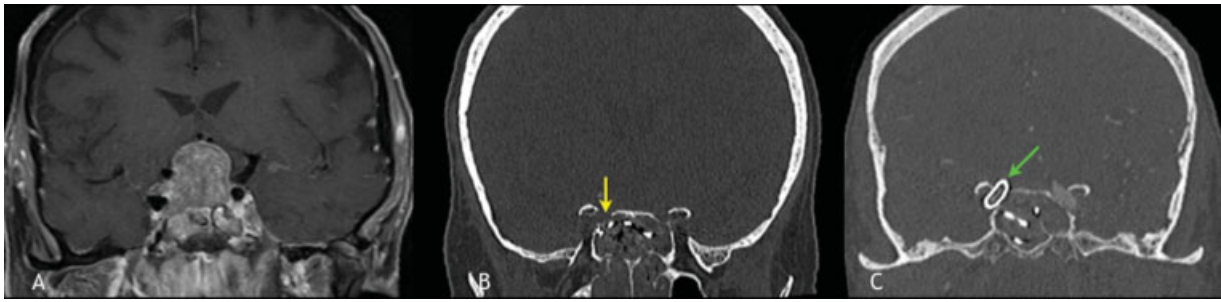

Fig. 1 (A) Coronal MRI of the brain with contrast demonstrating sellar and suprasellar mass with significant elevation of the optic apparatus, chiasmatal compression, and invasion of the right cavernous ICA. (B) Coronal CT without contrast demonstrating bony defect at the ICA injury site (yellow arrow). (C) Coronal CT angiogram with contrast demonstrating PED covering the ICA injury (green arrow), with normal position/nonectatic anterior genu of the ICA. CT, computed tomography; ICA, internal carotid artery; MRI, magnetic resonance imaging; PED, Pipeline embolization device.

with Pipeline embolization device (PED) and endoscopic endonasal repair using a fascia lata/muscle graft to treat an ICA pseudoaneurysm.

Case Report

A 77-year-old woman with hypertension presented to an outside hospital with vision loss and was found to have a $2.4 \times 1.9 \times 2$ cm nonsecreting sellar and suprasellar mass with right cavernous sinus invasion and bitemporal hemianopsia (► **Fig. 1A**). She was transferred to our institution after an aborted TSS for this lesion due to intraoperative ICA injury. Per the original operative note: “The thicker bone of the posterior wall of the sphenoid sinus (lateral and superior) was then removed using the Sonopet. As the superolateral bone was being removed, there was noted to be arterial bleeding. The bleeding was immediately tamponaded with 1 in x 3 in neuropatties.” Three Foley catheters were placed and inflated: one into each nare and one anterior to the right sphenoid sinus. Intraoperatively, the patient became hypotensive, was treated with vasopressors, and received four units of blood. She was transferred intubated for emergent angiography.

On admission, she was sedated but moving all four extremities spontaneously. Head computed tomography (CT) demonstrated postsurgical changes with metal artifact in the sinus cavities from the packing (► **Fig. 1B**). There was no intracranial hemorrhage. She underwent immediate cerebral angiography, demonstrating a 1.4×2 mm right medial cavernous segment pseudoaneurysm (► **Fig. 2A**). There was no evidence of stenosis or thrombosis. Due to increasing white blood cell (WBC) count on day of admission (DOA)2, sulfamethoxazole/trimethoprim was started. On DOA3, she underwent a right ICA balloon test occlusion (BTO). She was following commands with antigravity strength in both arms prior to balloon inflation. Angiography demonstrated a sizeable posterior communicating artery and small anterior communicating artery so runs of the posterior circulation through the left vertebral artery were obtained after inflating the balloon within the right cervical ICA. These runs demonstrated approximately 1 second of flow delay within the right ICA territory, with arterial phase opacification

during the parenchymal phase of the posterior circulation. She also failed the BTO clinically, losing the ability to raise her left arm antigravity after 9 minutes of occlusion. She was started on aspirin 325 mg and prasugrel 5 mg daily in anticipation for vessel-preserving flow diversion. Due to increasing WBC count, her antibiotics were broadened to vancomycin, cefepime, and metronidazole on DOA4.

Endovascular Management

Due to her failed BTO, on DOA5, the patient was taken to the interventional neuroradiology suite for Pipeline embolization under general anesthesia. The PEDs were deployed using a standard triaxial catheter setup and a drag-and-drop

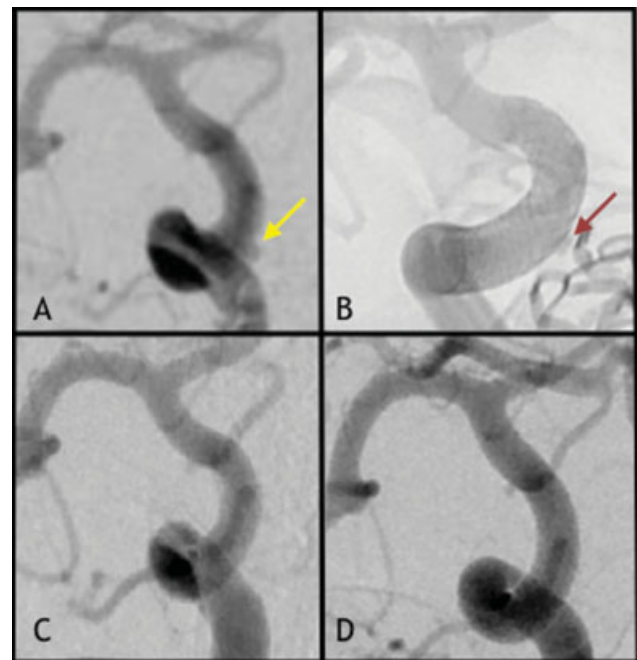


Fig. 2 (A) Right ICA pseudoaneurysm (yellow arrow) on DOA1. (B) PED placement with persistent filling (red arrow) on DOA5. (C) Complete obliteration of right ICA pseudoaneurysm after fascia lata/muscle graft repair on DOA19. (D) Angiogram 2.5 years after surgery demonstrates continued complete aneurysm obliteration with Pipeline endothelialization. DOA, day of admission; ICA, internal carotid artery; PED, Pipeline embolization device.

technique.⁹ Three telescoping PEDs were used: 4.75 × 14 mm Flex, 5 × 14 mm Flex, and 5 × 12 mm Flex (►Figs. 1C and 2B). After deployment of two devices, a region of incomplete parent vessel apposition at the proximal end of the construct was rectified using balloon angioplasty. At this point, there was only moderate (parenchymal phase) contrast stasis within the pseudoaneurysm, so a third device was deployed resulting in pronounced contrast stasis within the pseudoaneurysm.

Following the procedure, she remained intubated and sedated, but was able to follow commands in all extremities. Her packing and intranasal Foley catheters remained in place. Repeat angiogram on DOA12 showed good stent vessel wall apposition without evidence of in-stent stenosis but continued residual filling of the pseudoaneurysm. Due to fevers and increasing WBC, two Foley catheters were removed without complications. Due to prolonged intubation, she underwent tracheostomy and percutaneous G-tube (PEG) placement. Despite being on broad spectrum antibiotics, she required vasopressors for mild sepsis. Given the risk of worsening sepsis and the length of time that the nasal packing had remained in place, the patient was brought to the operating room on DOA17 for nasal packing removal with concomitant endoscopic endonasal repair of her pseudoaneurysm.

Operative Management

After general anesthesia and cardiovascular access, her head was fixed in a Mayfield holder. Neuronavigation was registered to the patient using her high-resolution CT and magnetic resonance imaging (MRI) scans. The remaining nasal Foley catheter was removed. The nasal cavities were irrigated with 1,200 mg of clindamycin in 1 L of normal saline. Her face, right neck (for carotid artery access and control), right groin, and right anterior thigh were prepped.

A 5 × 3 cm sheet of fascia lata and muscle was harvested from the proximal right thigh via a 7 cm incision. The defect was repaired in standard fashion.

The nasal cavities were examined with the 0-degree endoscope. Significant mucosal ulceration was noted. Superficial patties from the nasal cavity were removed. The prior sphenoidotomy was widely extended. An incision in the contralateral posterior nasal mucosa was widened to increase bilateral access. While the remaining patties were carefully dissected with significant irrigation, arterial bleeding was encountered in the region of the right anterior genu. Hemostasis was obtained by tamponading the bleeding with one of the remaining patties, which was amputated until there was a small piece of patty remaining over the aneurysmal site. The nasal cavities were irrigated with another liter of clindamycin irrigation. At this time, the fascia lata/muscle graft was placed in the sphenoid sinus. The remaining portion of the final patty was removed, and the muscle side of the graft was positioned over the ICA pseudoaneurysm by manipulating the fascia lata side of the graft. No more active bleeding was noted. The site was packed with Gelfoam wrapped in Surgicel. Two NasoPores were placed into the sphenoid sinus and a gloved Merocel was placed in each nasal

cavity. Intraoperative X-ray confirmed no retained radiopaque foreign bodies.

Postoperative Course and Follow-up

Angiography on DOA19 showed complete obliteration of the ICA pseudoaneurysm with no in-stent stenosis or thrombosis (►Fig. 2C). Her aspirin was decreased to 81 mg. She was weaned off of the ventilator and transferred to the floor on DOA24. On DOA26, she was discharged to rehabilitation. Her final antibiotic regimen of ciprofloxacin, metronidazole, and sulfamethoxazole/trimethoprim continued for an additional 3 weeks while her nasal packing remained in place. She continued to improve with PEG removal, tracheostomy decannulation, and subsequent discharge home on DOA40.

Follow-up cerebral angiograms at 6 months and 2.5 years (►Fig. 2D) confirmed complete obliteration of the ICA pseudoaneurysm with no in-stent stenosis. Her last pituitary MRI scan at 28 months postembolization showed mild increase in her tumor; however, the patient deferred treatment. At her last angiogram, she was doing well, living independently, and working 40 hours a week. She remained on aspirin 81 mg.

Discussion

ICA injury is a rare complication of TSS.^{1–6} ICA pseudoaneurysm is a frequent sequelae of iatrogenic ICA injury and can be difficult to treat. Definitive treatment modalities include vessel sacrifice, endovascular repair, and surgical bypass.^{7,8,10} Endovascular techniques include coiling, stent-assisted coiling, liquid embolization, and endoluminal reconstruction with stenting or flow diversion.⁸ Flow diversion offers the advantage of endoluminal treatment without accessing the aneurysm and avoidance of other complications of coiling alone such as coil compaction, migration, or extrusion.⁸

Parent vessel preservation through endovascular intervention has been increasingly reported through case reports and series. Sylvester et al identified 60 articles and 98 cases of endovascular treatments for iatrogenic ICA injury from endonasal surgery, and presented 7 cases from their own series.⁸ From these 105 cases, 46 (43.8%) underwent endovascular ICA sacrifice, 28 (26.7%) underwent ICA lesion embolization (stent-assisted coiling, coil embolization without stenting, balloon embolization without stenting, Onyx embolization), and 31 (29.5%) underwent endoluminal reconstruction with covered stent placement, multiple uncovered stents, or flow diversion. In this comprehensive literature review, five cases of flow diversion had been described for TSS-related ICA injury.⁸

The PED is a flow diversion device that was initially approved by the Food and Drug Administration in 2011 for treatment of large and giant aneurysms in the ICA extending from the petrous to the superior hypophyseal segments. It is a 48-strand device providing 30 to 35% metal coverage of the arterial wall surface area.¹¹ PED has gained popularity for its ability to reduce aneurysmal blood flow while providing a scaffold for endothelialization and vessel wall reconstruction.^{12,13}

Table 1 Literature review of the use of Pipeline embolization for treatment of iatrogenic carotid artery pseudoaneurysm after TSS

Article	Cases	Case series	Surgery	Pathology	Result	Angiographic follow-up	Last clinical follow-up, outcome
Amenta et al ¹⁴ (2012)	1	1 case PED (x2)	Endoscopic left ethmoidectomy, maxillary antrostomy, sphenoidostomy	Chronic sinusitis	CR	4 mo	6 mo, neurologically intact
Nerva et al ²⁰ (2015)	2	1 case PED (x2) 1 case PED, coils, BA	Endoscopic TSS Endoscopic TSS	Tumor, NOS Tumor, NOS	CR, mild ISS without flow limitation CR	4 mo 2 wk	9 mo, mRS=0 3 mo, died, unrelated causes (sepsis)
Zanaty et al ²² (2015)	1	1 case PED	Endoscopic TSS	Macroadenoma	CR	NR	NR, neurologically stable
Sylvester et al ⁸ (2016)	2	1 case PED 1 case PED (x3) ^a	TSS TSS 20 y prior with coiling of iatrogenic ICA PSA	PA PA	CR Contrast stasis in PSA	6 mo NR	16 mo, no neurological deficits 1 d, good
Griauzde et al ¹⁷ (2017)	3	1 case PED (immediate vessel sacrifice and delayed STA-MCA bypass) 1 case PED 1 case PED (x2)	Combined endoscopic/microscopic TSS TSS ^b	Recurrent macroadenoma Macroadenoma Recurrent chordoma	Sacrifice CR CR	NR 5 mo (MRA) 6 mo (CTA)	NR, mRS=1 NR, mRS=0 NR, mRS=0
Karadag et al ¹⁸ (2017)	1	1 case PED	Endoscopic TSS	PA	CR	3 mo (CTA)	3 mo, no neurologic deficit
Sami et al ²¹ (2018)	2	1 case PED (x3) ^a 1 case PED	TSS 20 y prior with coiling of iatrogenic ICA PSA TSS	NR Recurrent PA	Near CR CR	12 mo 6 mo	NR, mRS=0 NR, mRS=0
Giorgianni et al ¹⁶ (2019)	1	1 case PED	Endoscopic TSS	Macroadenoma	CR	6 mo	14 d, no neurologic deficit
Chen et al ¹⁵ (2019)	5	4 cases unspecified 1 case PED	Unspecified Endoscopic TSS	Unspecified tumor Macroadenoma	Unknown Persistent filling requiring sacrifice	NR 36 h	NR NR
Narrai et al ¹⁹ (2020)	1	1 case PED Flex	Endoscopic TSS	Rathke's cleft cyst	CR	12 mo	12 mo, mRS=0
Current case	1	1 case PED (x3), BA, followed by fascia lata/muscle graft	Endoscopic TSS	Macroadenoma	CR	2.5 y	2.5 y, neurologically stable

Abbreviations: BA, balloon angioplasty; CR, complete resolution at the time of last imaging; CTA, computed tomography angiography; d, days; h, hours; ICA, internal carotid artery; ISS, in-stent stenosis; MCA, middle cerebral artery; mo, months; MRA, magnetic resonance angiography; mRS, modified Rankin scale; NOS, not otherwise specified; NR, not reported; PA, pituitary adenoma; PED, Pipeline embolization device; PSA, pseudoaneurysm; STA, superficial temporal artery; TSS, transsphenoidal surgery; y, years.

^aSame case (M.R. Chicoine, MD, and C.J. Moran, MD, personal communication, 2020).

^bReported as transnasal in original report; confirmed transsphenoidal (J. Griauzde, MD, and A. Pandey, MD, personal communication, 2020).

Amenta et al were the first to describe the use of PED for iatrogenic ICA pseudoaneurysm after their patient underwent endoscopic sinus surgery for sinusitis.¹⁴ Initial CT angiography (CTA) performed due to concern for intraoperative ICA injury showed no pseudoaneurysm; however, repeat CTA 1 week later showed a 2×1.4 mm left ICA pseudoaneurysm, confirmed with angiogram. Two PEDs were placed across the pseudoaneurysm and 4 months later, follow-up angiogram demonstrated complete obliteration.¹⁴ Since then, several additional cases of PED alone or combined PED and coiling for iatrogenic ICA pseudoaneurysm have been described.^{8,14–22}

Most recently, Chen et al conducted a seven-institution retrospective study of PED for intracranial pseudoaneurysms of various etiologies. Average length of radiographic follow-up was 6 months, and 78% of patients achieved complete obliteration.¹⁵ Of the 19 total cases, 5 were due to iatrogenic injury from TSS for tumor, 1 of which was reported to ultimately require parent vessel sacrifice due to persistent filling.¹⁵ They also conducted a literature review of 11 case reports/series describing the use of PED (with or without coils) for pseudoaneurysms of various etiologies.¹⁵ Of the 30 cases, 10 were due to iatrogenic injury during TSS, which includes the 5 cases previously summarized by Sylvester et al.^{8,14,20} Currently, there are limited cases of PED used for iatrogenic pseudoaneurysm repair after TSS, with more than 10% ultimately requiring vessel sacrifice (**►Table 1**).^{8,14–22}

One major limitation of PED is the delay in obtaining complete occlusion. Close follow-up for persistent pseudoaneurysm filling is necessary, and additional treatment may be needed. As the false wall of the pseudoaneurysm remodels, fascia lata/muscle grafting can help reinforce the false wall and provide additional structural support rather than immediately opting for vessel sacrifice. While another limitation of PED is the preoperative and prolonged post-procedural antiplatelet therapy, our patient was able to undergo endoscopic repair without excessive bleeding on dual antiplatelets. Our patient's successful course may be related to her being a healthy, previously untreated patient as PED may be associated with increased complications in patients with other etiologies of ICA pseudoaneurysm (i.e., postradiation).²³

Our case demonstrates that concomitant fascia lata/muscle repair can supplement flow diversion in the treatment of iatrogenic ICA pseudoaneurysm. The use of a fascia lata graft has previously been described to supplement stenting of an iatrogenic cavernous ICA injury.²⁴ In our case, we chose to utilize muscle as part of our repair based on the effectiveness of muscle patching in hemostatic control of an intraoperative ICA injury.^{25,26} While our patient's sepsis necessitated an endoscopic approach to remove her packing, this technique may serve as a salvage option for patients who may not be able to undergo ICA sacrifice or bypass. Delayed or immediate neurological deficits after ICA sacrifice, even after passing a BTO, remain significant.^{27–30} Although PED has been shown to successfully obliterate pseudoaneurysms after TSS, our current case highlights a strategy to potentially avoid vessel sacrifice in patients treated with PED but who

require additional intervention for their pseudoaneurysm. Further investigation into the utility of directed endoscopic endonasal repair of iatrogenic pseudoaneurysms after PED is necessary, especially given the need for post-PED anticoagulation and the significant rate of neurological deficit after ICA sacrifice.

Conclusion

Iatrogenic ICA pseudoaneurysms are challenging lesions to treat. While reports of PED for treatment of iatrogenic ICA pseudoaneurysms have increased over the years, a combined PED and endoscopic endonasal approach may serve as a salvage technique to treat patients who are unable to undergo ICA sacrifice.

Disclosures

Dr. Alexander L. Coon is a proctor for the Woven Endobridge (WEB) device (Sequent Medical); a proctor for the Surpass device (Stryker Neurovascular), and a consultant for Stryker Neurovascular; a proctor for the PED (Medtronic Neurovascular) and a consultant for Medtronic; a proctor for the FRED device (MicroVention) and consultant for MicroVention; and a consultant for InNeuroCo. Dr. Niall R. London holds stock in Navigen Pharmaceuticals and was a consultant for Cooltech Inc., both of which are unrelated to the present manuscript. Dr. Cameron G. McDougall is a consultant for Microvention and Medtronic.

Source of Financial Support and Industry Affiliations

None.

Conflict of Interest

None declared.

References

- AlQahtani A, London NR Jr, Castelnuovo P, et al. Assessment of Factors Associated With Internal Carotid Injury in Expanded Endoscopic Endonasal Skull Base Surgery. *JAMA Otolaryngol Head Neck Surg* 2020;146(04):364–372
- Asemota AO, Ishii M, Brem H, Gallia GL. Comparison of complications, trends, and costs in endoscopic vs microscopic pituitary surgery: analysis from a US Health Claims Database. *Neurosurgery* 2017;81(03):458–472
- Kassam AB, Prevedello DM, Carrau RL, et al. Endoscopic endonasal skull base surgery: analysis of complications in the authors' initial 800 patients. *J Neurosurg* 2011;114(06):1544–1568
- Laws ER Jr. Vascular complications of transsphenoidal surgery. *Pituitary* 1999;2(02):163–170
- Perry A, Graffeo CS, Meyer J, et al. Beyond the learning curve: comparison of microscopic and endoscopic incidences of internal carotid injury in a series of highly experienced operators. *World Neurosurg* 2019;131:e128–e135
- Raymond J, Hardy J, Czepko R, Roy D. Arterial injuries in transsphenoidal surgery for pituitary adenoma; the role of angiography and endovascular treatment. *AJNR Am J Neuroradiol* 1997;18(04):655–665
- Gardner PA, Snyderman CH, Fernandez-Miranda JC, Jankowitz BT. Management of major vascular injury during endoscopic

- endonasal skull base surgery. *Otolaryngol Clin North Am* 2016;49(03):819–828
- 8 Sylvester PT, Moran CJ, Derdeyn CP, et al. Endovascular management of internal carotid artery injuries secondary to endonasal surgery: case series and review of the literature. *J Neurosurg* 2016;125(05):1256–1276
 - 9 Bender MT, Vo CD, Jiang B, et al. Pipeline embolization for salvage treatment of previously stented residual and recurrent cerebral aneurysms. *Intervent Neurol* 2018;7(06):359–369
 - 10 AlQahtani A, Castelnuovo P, Nicolai P, Prevedello DM, Locatelli D, Carrau RL. Injury of the internal carotid artery during endoscopic skull base surgery: prevention and management protocol. *Otolaryngol Clin North Am* 2016;49(01):237–252
 - 11 U.S. Food and Drug Administration Updated July 27, 2020. Accessed July 31, 2020 at: <https://www.accessdata.fda.gov/scripts/cdrh/cfdocs/cfpma/pma.cfm?ID=P100018>
 - 12 Kallmes DF, Ding YH, Dai D, Kadirvel R, Lewis DA, Cloft HJ. A second-generation, endoluminal, flow-disrupting device for treatment of saccular aneurysms. *AJNR Am J Neuroradiol* 2009;30(06):1153–1158
 - 13 Patel PD, Chalouhi N, Atallah E, et al. Off-label uses of the Pipeline embolization device: a review of the literature. *Neurosurg Focus* 2017;42(06):E4
 - 14 Amenta PS, Starke RM, Jabbour PM, et al. Successful treatment of a traumatic carotid pseudoaneurysm with the Pipeline stent: case report and review of the literature. *Surg Neurol Int* 2012;3:160
 - 15 Chen SH, McCarthy DJ, Sheinberg D, et al. Pipeline embolization device for the treatment of intracranial pseudoaneurysms. *World Neurosurg* 2019;127:e86–e93
 - 16 Giorgianni A, Pozzi F, Pellegrino C, et al. Emergency placement of a flow diverter stent for an iatrogenic internal carotid artery injury during endoscopic pituitary surgery. *World Neurosurg* 2019;122:376–379
 - 17 Griauzde J, Ravindra VM, Chaudhary N, et al. Use of the Pipeline embolization device in the treatment of iatrogenic intracranial vascular injuries: a bi-institutional experience. *Neurosurg Focus* 2017;42(06):E9
 - 18 Karadag A, Kinali B, Ugur O, Oran I, Middlebrooks EH, Senoglu M. A case of pseudoaneurysm of the internal carotid artery following endoscopic endonasal pituitary surgery: endovascular treatment with flow-diverting stent implantation. *Acta Med (Hradec Králove)* 2017;60(02):89–92
 - 19 Nariai Y, Kawamura Y, Takigawa T, Hyodo A, Suzuki K. Pipeline embolization for an iatrogenic intracranial internal carotid artery pseudoaneurysm after transsphenoidal pituitary tumor surgery: case report and review of the literature. *Interv Neuroradiol* 2020;26(01):74–82
 - 20 Nerva JD, Morton RP, Levitt MR, et al. Pipeline embolization device as primary treatment for blister aneurysms and iatrogenic pseudoaneurysms of the internal carotid artery. *J Neurointerv Surg* 2015;7(03):210–216
 - 21 Sami MT, Gattozzi DA, Soliman HM, et al. Use of Pipeline™ embolization device for the treatment of traumatic intracranial pseudoaneurysms: case series and review of cases from literature. *Clin Neurol Neurosurg* 2018;169:154–160
 - 22 Zanaty M, Chalouhi N, Jabbour P, Starke RM, Hasan D. The unusual angiographic course of intracranial pseudoaneurysms. *Asian J Neurosurg* 2015;10(04):327–330
 - 23 Tsang AC, Leung KM, Lee R, Lui WM, Leung GK. Primary endovascular treatment of post-irradiated carotid pseudoaneurysm at the skull base with the Pipeline embolization device. *J Neurointerv Surg* 2015;7(08):603–607
 - 24 Kan P, Stevens EA, Orlandi RR, Couldwell WT. Carotid artery-sparing repair of a cavernous carotid artery pseudoaneurysm. Case illustration. *J Neurosurg* 2006;104(06):978
 - 25 Valentine R, Boase S, Jervis-Bardy J, Dones Cabral JD, Robinson S, Wormald PJ. The efficacy of hemostatic techniques in the sheep model of carotid artery injury. *Int Forum Allergy Rhinol* 2011;1(02):118–122
 - 26 Valentine R, Padhye V, Wormald PJ. Management of arterial injury during endoscopic sinus and skull base surgery. *Curr Opin Otolaryngol Head Neck Surg* 2016;24(02):170–174
 - 27 Dare AO, Chaloupka JC, Putman CM, Fayad PB, Awad IA. Failure of the hypotensive provocative test during temporary balloon test occlusion of the internal carotid artery to predict delayed hemodynamic ischemia after therapeutic carotid occlusion. *Surg Neurol* 1998;50(02):147–155, discussion 155–156
 - 28 Linskey ME, Jungreis CA, Yonas H, et al. Stroke risk after abrupt internal carotid artery sacrifice: accuracy of preoperative assessment with balloon test occlusion and stable xenon-enhanced CT. *AJNR Am J Neuroradiol* 1994;15(05):829–843
 - 29 McIvor NP, Willinsky RA, TerBrugge KG, Rutka JA, Freeman JL. Validity of test occlusion studies prior to internal carotid artery sacrifice. *Head Neck* 1994;16(01):11–16
 - 30 Whisenant JT, Kadkhodayan Y, Cross DT III, Moran CJ, Derdeyn CP. Incidence and mechanisms of stroke after permanent carotid artery occlusion following temporary occlusion testing. *J Neurointerv Surg* 2015;7(06):395–401