

# Massive Enlargement of Bilateral Breast in a Pregnant Female

Lakshmi Agarwal<sup>1</sup> Manmohan Agarwal<sup>2</sup> Hemant Dadhich<sup>3</sup> Lokesh Rawat<sup>4</sup>

<sup>1</sup>Department of Pathology, Government Medical College, Kota, Rajasthan, India

<sup>2</sup>Pushpadi Cancer Care Centre, Kota, Rajasthan, India

<sup>3</sup>Cancer Research Centre, Kota, Rajasthan, India

<sup>4</sup>Balaji Sonography Centre, Kota, Rajasthan, India

**Address for correspondence** Lakshmi Agarwal, MBBS, MD (pathology), Department of Pathology, Government Medical College, Kota, Rajasthan, 324010, India (e-mail: drlaxmiagarwal@gmail.com).

Ind J Med Paediatr Oncol 2021;42:178–179.

A 26-year-old female at 28 weeks of gestation presented with massive enlargement of bilateral breast. She did not have any complaints of fever, pain (except heaviness), drenching night sweats, or weight loss. Her first pregnancy was unremarkable. Routine investigations such as complete blood count, liver function test, and renal function test were found to be within normal limits. Hemoglobin was 11.3 g/dL and total leukocyte count was 11,000/mm<sup>3</sup>, with neutrophils comprising 78%. Lactate dehydrogenase was 2000 IU/L. On clinical examination, both the breasts were diffusely enlarged, indurated, and tender. The overlying skin was red and hot (► **Fig. 1**). Multiple, bilateral, axillary lymphadenopathies were present. Ultrasonography of the breast showed diffuse edema, and no definite mass was identified.

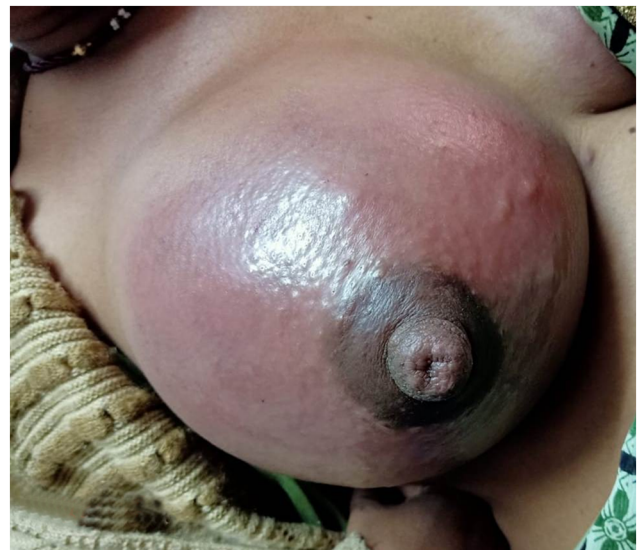Fine-needle aspiration cytology from the breast and axillary nodes showed singly scattered lymphoid cells. The cells were twice the size of small lymphocytes, having scant-to-moderate amount of cytoplasm. A few of them had prominent nucleoli. Mitosis was brisk. Atypical mitosis was also seen. Ductal cells were not evident (► **Fig. 2**).

The provisional diagnosis of non-Hodgkin lymphoma was rendered. Biopsy of the breast and immunohistochemistry (IHC) was advised for confirmation.

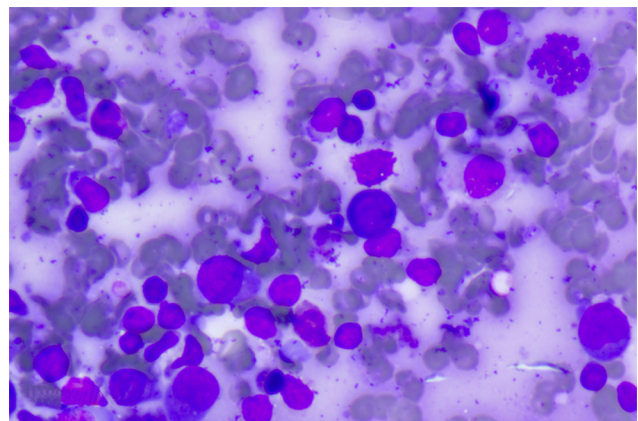
Trucut biopsy of the breast was done. Sections showed features of high-grade non-Hodgkin lymphoma (► **Fig. 3**). On IHC, the cells were positive for CD45, BCL2, CD10, and CD79A. Ki67 was 100%. The cells were negative for CK7, GATA3, E-cadherin, CD3, BCL6, and MUM1.

On the basis of the IHC report, the final diagnosis came out to be high-grade, diffuse large B cell lymphoma-germinal center type.

Chemotherapy was planned. Complete blood count and peripheral smear were repeated. The total leukocyte count was 1 lakh. The significant findings were presence of 80% blasts. Platelets had decreased in number. Hence, a clinical



**Fig. 1** Massive enlargement of the breast, with the overlying skin being red and hot.



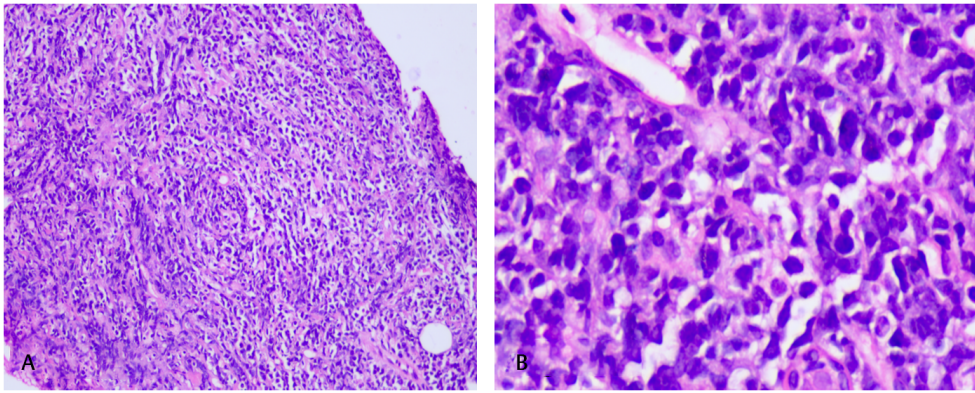
**Fig. 2** Giemsa-stained cytosmear slides showing singly scattered malignant lymphoid cells.

DOI <https://doi.org/10.1055/s-0041-1733821>  
ISSN 0971-5851

© 2021. Indian Society of Medical and Paediatric Oncology.

This is an open access article published by Thieme under the terms of the Creative Commons Attribution-NonDerivative-NonCommercial-License, permitting copying and reproduction so long as the original work is given appropriate credit. Contents may not be used for commercial purposes, or adapted, remixed, transformed or built upon. (<https://creativecommons.org/licenses/by-nc-nd/4.0/>).

Thieme Medical and Scientific Publishers Private Ltd. A-12, Second Floor, Sector -2, NOIDA -201301, India



**Fig. 3** (A and B) Hematoxylin and eosin-stained slides of trucut biopsy of breast showing features of non-Hodgkin lymphoma.

diagnosis of acute leukemia was made, and chemotherapy was planned, but she succumbed to the disease within a week.

Non-Hodgkin lymphoma involving the bilateral breast is uncommon in pregnancy. In the present case, the behavior of the tumor was very aggressive. It presented with acute leukemia within a short time. The diagnosis was delayed as breast enlargement is a common finding in pregnancy. Therefore, awareness about this can help in early diagnosis and treatment.

#### **Declaration of Patient Consent**

The authors certify that they have obtained all appropriate patient consent forms. In the form, the legal guardian has given his consent for images and other clinical information to be reported in the journal. The guardian understands that names and initials will not be published and due efforts will be made to conceal identity, but anonymity cannot be guaranteed.

#### **Funding**

Nil.

#### **Conflicts of Interest**

There are no conflicts of interest.