

## **Case Report: IV**

# Primitive Neuroectodermal Tumour Presenting as Cauda Equina Syndrome

JITENDRA K SAHU, RACHNA SETH, AK KARAK, V THAVARAJ & SK KABRA

### **ABSTRACT**

**Primary spinal presentation of Primitive neuroectodermal tumours (PNET) is an extreme rare occurrence and carries poor prognosis. An 11-year-old boy presented with pain in lumbar region, bilateral lower limb weakness, and bladder and bowel incontinence. Neurological examination showed paraparesis, hypotonia of lower limbs and absent deep tendon reflexes at both knees and ankles. MRI of spine revealed an intradural mass at the L2- L3 level. CT guided biopsy showed round cell tumour with strong positivity for MIC-2 antigen conclusive of PNET. A laminectomy of both L2 and L3 was performed, and near total removal of the cauda equina tumour was performed. Chemotherapy along with radiotherapy was started and good response was observed. The clinical, histopathologic, and radiologic findings of the patient are presented.**

### **INTRODUCTION**

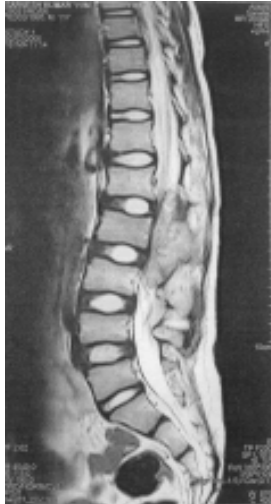
Primitive neuroectodermal tumours (PNET's) are malignant small round cell tumours of presumed neural crest origin belonging to the Ewing's sarcoma family. Cases of PNET have been increasingly reported in recent years but there is scarcity of reports of PNET originating primarily from the spinal cord. A review of the literature shows that only 30 cases of primary spinal PNET (PSPNET) have been reported till date.<sup>1,2</sup> The clinical, histopathologic, and radiologic findings of the patient are presented and discussed.

**CASE:** An 11-year-old boy admitted with a history of back pain, bilateral lower limb weakness, bladder and bowel incontinence for three months. Back pain was intermittent, severe and at the level of lumbar spine. Bilateral lower limb weakness was insidious in onset and gradual in progression. This was associated with bladder and bowel incontinence. There was no history of trauma, fever, antecedent infection or contact with tuberculosis. The patient had received a trial of antitubercular treatment before he presented to us.

On physical examination, the patient was alert and oriented with stable vital signs. He was found to have a blood pressure of 138/94 mmHg. There was no pallor, lymphadenopathy, clubbing or edema. There was no deformity on back and no tenderness on palpation. There was hypotonia of both lower limbs. Motor strength of the bilateral lower extremity was decreased to 3/5 in the quadriceps and ankle dorsiflexor muscles. There was areflexia of bilateral knee and ankle joints. Anal sphincter tone was reduced. Sensory examination was normal. Respiratory, cardiovascular and abdominal examinations were normal. Clinical possibilities of lymphoma, Ewing sarcoma and neuroblastoma were considered. Investigations: Hb 11.6gm/dl, total leukocyte count of 5100/mm<sup>3</sup>, DLC: polymorphs 36, lymphocytes 61, eosinophils 03, and platelets 336,000/mm<sup>3</sup> and an elevated ESR of 50mm/hr. Liver and renal function tests were normal. Serum LDH: was 301 IU/L. X-ray films of lumbosacral spine and chest were essentially unremarkable. MRI showed an intradural mass at the L2-L3 level (fig.1). The lesion was hypointense on T1W image and heterogeneously hyperintense on T2W image. No extension of the lesion in the surrounding soft tissues was seen. Computed tomogram of

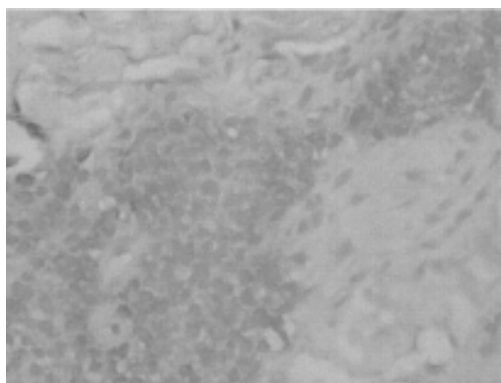
Department of Paediatrics and Pathology, (AK Karak) All India Institute of Medical Sciences, New Delhi, India  
Correspondence to: **RACHNA SETH**  
Email: drrachnaseth@yahoo.co.in

chest and brain were normal. <sup>131</sup>I-meta-iodobenzylguanidine (MIBG) scintiscan study was normal.



MRI of spine showing intradural mass at the L2 and L3 level and lesion is hypointense on T1W image and heterogeneously hyperintense on T2W image. No extension of the lesion in the surrounding soft tissues is seen.

CT guided biopsy showed round cell tumour. On immunohistochemical stain the tumour cells were negative for LCA, CD20, chromogranin and synaptophysin but strong positivity for MIC-2 antigen was observed; suggestive of PNET (fig.2). Bone marrow biopsy was normal. A laminectomy of both L2 and L3 was performed, and near total removal of the cauda equina tumour was performed. Chemotherapy along with radiotherapy was



Photomicrograph showing immunohistochemical staining of PNET cells with negative staining for LCA, CD20, chromogranin and synaptophysin but strong positivity for MIC-2 antigen.

started and good response was observed. His hypertension has subsided. He is now able to walk with calipers. Anal sphincter tone has improved. He is undergoing chemotherapy and under regular follow up.

## DISCUSSION

Hart and Earle<sup>3</sup> first introduced the term primitive neuroectodermal tumour in 1973 to describe predominantly undifferentiated tumours of the cerebrum that did not fulfill the diagnostic criteria for neuroblastoma, ependyoblastoma, polar spongioblastoma, medulloepithelioma or pineal parenchyma tumours. All neoplasm showing primitive poorly differentiated neuroepithelial cells can be called primitive neuroectodermal tumours, (PNET) regardless of location or cell type.

Cauda equina syndrome refers to the simultaneous compression of multiple lumbosacral nerve roots below the level of the conus medullaris, resulting in a characteristic pattern of neuromuscular and urogenital symptoms. In a report from Japan, the common causes of cauda equina tumour were schwannoma, ependymoma, neurofibroma, meningioma, and ganglioneuroblastoma.<sup>4</sup> Primary spinal PNET is an extreme rare cause of such presentation. Out of 30 cases of primary spinal PNET reported in literature 9 cases had cauda equina presentation (Table-1).

No single hematologic, biochemical or imaging method provides findings for a specific diagnosis of PNET. Therefore, obtaining a histologic specimen of the lesion in all patients is essential for diagnosis and planning therapy. Fine needle aspiration cytology/biopsy in conjunction with immunocytochemistry enables a rapid diagnosis of PNET.<sup>12,13</sup> Our case was diagnosed on the basis of histopathology and immunocytochemistry. Fluorescence in situ hybridization (FISH) and reverse transcriptase-polymerase chain reaction (RT-PCR) are newer modalities for molecular diagnosis of PNET.

Treatment of primary spinal PNET consists of surgical ablation, although results are poor. Radiotherapy and chemotherapy have been

tried. In view of scarcity of data in literature, the optimal management is yet to be defined. In our case postoperative spinal radiotherapy was given. The doses of radiation were 55 Gys in 30 fractions over 6 weeks. The chemotherapy used by us was Modified St Jude’s regimen<sup>14</sup> to control occult micrometastases. It included ifosfamide, etoposide, cyclophosphamide, doxorubicin, vincristine & actinomycin D.

Regarding the outcome, of the 9 cases of PSPNET with cauda equina reported until now, 3 were reported to be still alive at the last follow up. However, the time of observation was often

limited. The average survival time in the 5 patients listed in the table 1 was 44.2 months, (ranging from 10 to 42 months).

**CONCLUSION**

Our experience with this case emphasizes that in all cases of cauda equina tumours possibility of primary spinal PNET should be considered in pediatric age group. Early diagnosis, surgical removal and aggressive neuraxis radiation alongwith chemotherapy offers hope of long term and good quality survival.

**Table1. Primary Spinal PNET with Cauda Equina Presentation:**

SI No.	Authors	Age(years)/sex	Treatment	Metastases	Survival months
1	Smith et al. <sup>5</sup>	24/M	SX, RT	lung	10
2	Kepes et al. <sup>6</sup> case-1	24/M	SX, RT	leptomeningeal	18
	Kepes et al. <sup>6</sup> Case-2	56/M	SX, RT	None	36 Alive at last FU
	Case-3	39/M	SX, RT	none	42
3	Jaksche et al. <sup>7</sup>	26/M		NA	brain 36
4.	McDermott et al. <sup>8</sup>	47/M	CT/RT	none	16
5.	Hisaoka et al. <sup>9</sup>	14/M		NA	none 3 Alive last FU
6.	Isotal et al. <sup>10</sup>	52/M	SX, RT	none	12 Alive at last FU
7.	Kim et al. <sup>11</sup>	17/M	SX, RT,CT	none	NA

NA, not available; Sx-Surgery, CT, chemotherapy, RT-Radiotherapy, M-Male FU-Follow-up

## REFERENCES:

1. Kumar R, Reddy SJ, Wani AA, Pal L. Primary spinal primitive neuroectodermal tumour: case series and review of the literature. *Pediatr Neurosurg.* 2007;43:1-6.
2. Kampman WA, Kros JM, De Jong TH, Lequin MH. Primitive neuroectodermal tumours (PNETs) located in the spinal canal; the relevance of classification as central or peripheral PNET: case report of a primary spinal PNET occurrence with a critical literature review. *J Neurooncol* 2006;77:65-72.
3. Hart MN, Earle KM. Primitive neuroectodermal tumours of the brain in children. *Cancer* 1973; 32 : 890-897.
4. Shimada Y, Miyakoshi N, Kasukawa Y, Hongo M, Ando S, Itoi E. Clinical features of cauda equina tumours requiring surgical treatment. *Tohoku J Exp Med.* 2006;209: 1-6.
5. Smith DR, Hardman JM, Earle KM. Metastasizing neuroectodermal tumours of the central nervous system. *J Neurosurg.* 1969;31:50-8.
6. Kepes JJ, Belton K, Roessmann U et al. Primitive neuroectodermal tumours of the cauda equina in adults with no detectable primary intracranial neoplasm: Three case studies. *Clin Neuropathol* 1985;4:1-11.
7. Jakshe H, Wockel W, Wernert N. Primary spinal medulloblastomas? *Neurosurg Rev* 1988;11:259-265.
8. McDermott VG, El-Jabbour, Sellar RJ et al. Primitive neuroectodermal tumour of the cauda equina. *Neuroradiology* 1994;36:228-230.
9. Hisaoka M, Hashimoto H, Murao T. Peripheral primitive neuroectodermal tumour with ganglioneuroma-like areas arising in the cauda equina. *Virchows Arch.* 1997;431:365-9.
10. Isotalo PA, Agbi C, Davidson B, Girard A, Verma S, Robertson SJ. Primary primitive neuroectodermal tumour of the cauda equina. *Hum Pathol.* 2000;31:999-1001.
11. Kim YW, Jin BH, Kim TS, Cho YE. Primary intraspinal primitive neuroectodermal tumour at conus medullaris. *Yonsei Med J.* 2004;45:533-8.
12. Frostad B, Tani E, Brosjo O, Skoog L, Kogner P. Fine needle aspiration cytology in the diagnosis and management of children and adolescents with Ewing sarcoma and peripheral primitive neuroectodermal tumour. *Med Pediatr Oncol.* 2002;38:33-40.
13. Sahu K, Pai RR, Khadilkar UN. Fine needle aspiration cytology of the Ewing's sarcoma family of tumours. *Acta Cytol.* 2000;44:332-6.
14. Sridharan Gururangan, Neyssa M. Marina, Xiaolong Luo, David M. Parham, Chin-Yuan Tzen Carol A. Greenwald, Bhaskar N. Rao, Larry E. Kun, William H. Meyer. Treatment of Children with Peripheral Primitive Neuroectodermal Tumour or Extrasosseous Ewing's Tumour with Ewing's-Directed Therapy. *J. Ped. Hematol/Oncology.* 1998;20(1):55-61.

