

Original Article-I

Sentinel Node Biopsy in Cervical Cancer - A Pilot Study

MANOJ BABU R, ALTAF GAUHAR HAJI, D.K VIJAY KUMAR, K. CHITRATHARA, PADMA SUNDARAM, SHANMUGHA SUNDHARAM

ABSTRACT:

BACKGROUND: We conducted a pilot study to assess the feasibility of doing sentinel node biopsy in patients with early stage cervical cancer.

METHODS: Thirteen patients with early stage carcinoma cervix (Stage I A-2 and eleven cases of stage I B1) were planned for radical hysterectomy (PLND). Early on the day of surgery, patients had initial injection of 0.4 to 0.6 ml radio-isotope, 37 MBq of filtered ^{99m}Techneium sulphur colloid, either peritumourally or into the four quadrants of the cervix when the lesion was not visible. The injections were given using an insulin syringe taking precautions to avoid intra-tumoural injection and back-flow out of the injection tract. The patients were then screened under the gamma camera at regular intervals in the nuclear medicine department to determine the location of the sentinel node/nodes. Once the sentinel node was identified and marked, patients were taken to the operating room. During surgery the sentinel node was detected by means of a hand held gamma probe and sent separately for histopathological examination. This was followed by a radical hysterectomy with bilateral PLND in all cases.

Results: The sentinel lymph node was detected in all cases except one patient within thirty minutes after injection of the radioisotope. In this patient the node was

detected by ninety minutes. Two out of the thirteen patients had sentinel node positive for metastasis. These patients also had additional positive nodes. There were no false negatives. Bilateral nodes were seen in three patients. More than one node was identified in four patients. The sentinel node was found to be the "internal iliac node / nodes" in eight patients and the "obturator node / nodes" in seven patients.

Conclusion: Sentinel node biopsy is feasible in patents of stage I A2 to stage I B2 carcinoma cervix, using radiocolloid injection and lymphoscintigraphy techniques.

INTRODUCTION

Cervical cancer is a leading cause of cancer deaths worldwide and is common cancer among women in India. The current management for patients with cervical cancer stage I A2, stage I B1 and selected II A is a radical hysterectomy with a full pelvic node dissection. This may be associated with morbidities eg. bleeding, pelvic lymphocoele formation, neurogenic bladder, leg edema, nerve damage, etc.¹

The sentinel node is defined as the very first node or group of nodes that drain the anatomical region or primary tumour.^{2,3} Therefore, the absence of metastatic disease within the sentinel node should enable a reduction in extent of the lymphadenectomy and a possible morbidity sparing effect. The technique of sentinel node biopsy is now part of the standard surgical management for breast cancer and cutaneous malignant melanoma.

Department of Surgical Oncology, and Nuclear Medicine (Padma Sundaram, Shanmugha Sundaram) Amrita Institute of Medical Sciences and Research Centre, Kochi, Kerala.
Correspondence to: MANOJ BABU R,
Email: manojbabu4@rediffmail.com

Currently its application in various gynecological malignancies eg. vulval cancer, cervical cancer and endometrial cancer is being evaluated. Earlier studies in cervical cancer have suggested that the procedure is less reliable in advanced stages of disease, as the afferent lymphatics tend to get blocked by the tumour cells, leading to false negative study.⁴

The concept of sentinel node biopsy appears attractive for cervical cancer as the incidence of lymph node metastasis in stage I A2 cervical cancer is only 7 % and in stage I B1 it does not exceed 20 %, i.e. a significant percentage of patients are not benefited from lymphadenectomy.⁵ Cervix has a complex lymphatic drainage due to its midline position. Complications associated with lymph node dissection develop more frequently if postoperative radiotherapy is administered.^{6,7} Cervical cancer patients with negative pelvic nodes benefit from radical hysterectomy, while those with histologically proven lymph node metastasis may benefit more from primary chemo-radiation. Traditional imaging techniques including lymphangiography, CT and MRI may fail to identify lymph node metastasis with accuracy.^{8,9} Present study is to find out the feasibility of sentinel node biopsy in patients with early stages of cervical cancer.

METHODS

Patients:

Thirteen patients with histologically proven early cervical cancer with tumour size less than 4 cm were included in the study. The mean age of patients was 51.7 years (range= 37 to 71 years). Among the 13 cases, 11 had Stage IB 1 and the remaining two had stage I A2. 10 of 13 cases were squamous cell cancers on histology and cytology. All these cases were scheduled for radical hysterectomy with pelvic lymphadenectomy.

Pre-operative lymphoscintigraphy:

Preoperative lymphoscintigraphy was performed early during the day of surgery using

^{99m}Tc Technetium filtered sulphur colloid using a 0.22-micron Millipore filter, (Dose less than 37 MBq in a volume of 0.4 ml – 0.6 ml) in the nuclear medicine department. The total dose was divided into four injections and given into four quadrants of the cervix, at 12, 3, 6 and 9'O clock positions in cases where the lesion was not grossly visible (micro-invasive carcinoma). In patients with grossly visible tumour, the injections were given peritumourally. The injections were given by insulin syringe, taking precautions to avoid intra-tumoural injection and back flow out of the injection track.

Immediately after the injection the patient were shifted on to the gamma camera table and a high-resolution static image of the anterior abdomen and pelvis was acquired for five minutes. Subsequent static images of the abdomen and pelvis were acquired every 15 minutes to detect sentinel node / nodes. When the sentinel node was visualized as a hot spot, it was marked with a radioactive marker for confirmation and then the corresponding site was marked on the patient's skin with a marker pen.

Intra-operative localization

During laparotomy, before proceeding with lymphadenectomy, a hand held battery operated gamma detector probe [Energy range-140 keV to 360 keV, absolute sensitivity for ^{99m}Tc (140keV) -7500 cps/MBq and resolution (FWHM) of < 12mm] was moved along the lymph node regions to detect preoperatively marked sentinel lymph nodes. The nodes containing radioactivity counts more than ten times the background activity were removed and count checked ex-vivo using the same probe. The gamma probe needs to be angled laterally to avoid residual radioactivity emitted from the primary injection site (Figure I). Once the nodes were identified the position of each node in relation to the major pelvic vessels were noted and the count recorded. This was followed by a conventional lymphadenectomy in all cases.

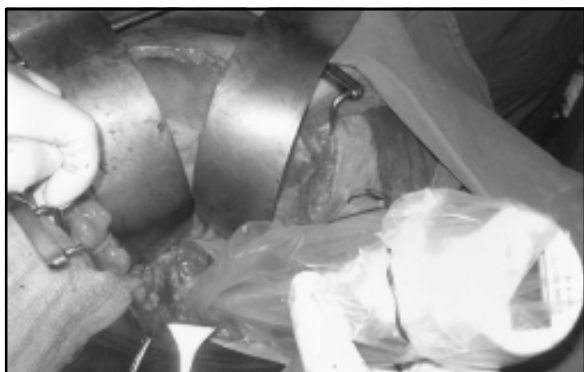


Figure 1- Intra-operative lymphatic mapping- the gamma probe being angled laterally to avoid residual radioactivity of primary site.

Histopathological Examination

The sentinel nodes as well as the lymphadenectomy specimen were then sent separately for histopathological examination. Histopathological examination was done using the standard technique with haematoxylin and eosin stain.

RESULTS

Patients characteristics are shown in table I. The sentinel nodes were detected in all the thirteen cases, i.e. detection rate was 100%. Only 3 cases had bilateral sentinel nodes. The average time taken for detection of sentinel nodes was 37 min (SD= 17.8) with a range of 20 to 90 minutes. The commonest site was the internal iliac node/nodes (61.53%) followed by obturator nodes (53.8%).

A total of 22 sentinel nodes were detected in thirteen cases. The lymph nodes were positive for metastasis in two cases (both stage IB 1). Both cases were squamous cell carcinomas. Among the node positive cases one was grade II and the other was grade III. In both these cases, other nodes were also positive. There were false negatives so far in our series, i.e., whenever sentinel nodes were negative other nodes were also negative.

DISCUSSION:

Sentinel node biopsy is a relatively new addition to the field of surgical oncology, which has got great potential to reduce surgical

morbidity. The two common methods for sentinel node detection are using vital dyes and radioactive tracers. The vital dyes commonly used are isosulfan blue, patent blue violet, and methylene blue. Any blue-dyed node is considered to be a sentinel node. Radioactive tracers contain the 99m technetium radioisotope. Three nanoparticles are used: 15-50 nm colloidal sulphur, 5-80 nm human albumin, and 2-3 nm human serum albumin. Several images are obtained from different projections, and the anatomical references are marked in order to facilitate location. An intraoperative gamma probe is used to trace the node chains under study systematically, considering the sentinel node as the one that shows, *ex vivo*, a 10-fold increase in the radiation count relative to the basal count.

Since Echt et al reported the initial case series in 1999 using blue dye alone; several authors have published their experience with sentinel node detection in cervical cancer¹⁰. More than forty three studies involving approximately 1600 patients have been reported so far using either blue dye alone, radio-colloid alone or with the combined method using blue dye along with radio-colloid for detecting sentinel nodes in patients with cervical cancer. The largest series, reported by Rob et al comprised of 183 cases, 100 cases using blue dye alone and 83 cases using the combined method. The detection rate was 80% with blue dye and 96.4% with the combined method. The negative predictive value (NPV) was 99% and 100% with blue dye and the combined method respectively.¹¹ Lin et al reported the largest series of 100 patients using lymphoscintigraphy followed by intraoperative lymphatic mapping.¹² There is a paucity of studies conducted and reported from India, even though it is the commonest malignancy in women.

In nine cases of Stage IB1 lesions peritumoural injection technique was practiced. In one case the lesion was mainly in the cervical canal and due to technical difficulties, four-quadrant injection technique was used. Similar procedure was adopted for the stage IA 2 cases. Most of the patients reported mild pain after injection, which did not persist. We felt that it was helpful to use a thin 25 G needle with constant gentle pressure to prevent spillage into

Table I - Patient and Tumour Characteristics.

Age (Mean)	51.7 years	Range: 37-71 years
Stage	IA2	No of Patients 02
	IB1	11
Histology	Squamous cell carcinoma	10
	Adenocarcinoma	03
Grade	Grade I	03
	Grade II	07
	Grade III	03
Internal iliac nodes	8	61.5%
External iliac nodes	2	15.48%
Obturator nodes	7	53.8%

*Standard deviation = 11.27

Table II -Characteristics of Sentinel Lymph Nodes

Characteristics	No. Of patients (N=13)	Percentage
Detection rate	13	100%
Bilateral nodes	3	23%
Lymph node metastases	2	15.38%
Sentinel node metastases	2	15.38%

the vagina. For the first 2 cases, we injected 0.6 ml of radio colloid. But in the subsequent cases we injected only 0.4 ml radio colloid with 0.1 ml for each site for convenience, even though the dose remained the same (25 MBq to 37 MBq). In 9 out of 13 cases the lymphoscintigraphic images were obtained within 30 minutes. In one case it took 90 minutes for localization of radioactivity. The markings were made on the anterior abdominal wall corresponding to the approximate site of the node. A lateral view was

not obtained because we felt that marking in a second plane did not add much to the easiness of detection of the node using the sensitive gamma probe. The only major use of lymphoscintigraphy as per our experience was to detect the side of sentinel node so that one can be more focussed while doing intra-operative gamma probe guided dissection. Other authors have reported similar experiences.¹¹ The minimum time taken was 20 min and the maximum time taken for sentinel node detection was 90 minutes.

The detection rate in our series was 100%. The detection-rate reported by Echt et al in 1999 was only 23%¹⁰ but the recent studies using intra-operative lymphatic mapping as well as the combined method using intraoperative lymphoscintigraphy (ILS) and blue dye together have reported detection rates around 100%.^{13, 14}

In the two patients who had sentinel nodes positive for metastasis, other nodes were also positive. This emphasizes the need for performing a complete lymphadenectomy, whenever sentinel nodes are positive for metastasis. The negative predictive value (NPV) was 100% i.e., whenever sentinel nodes were negative, other nodes were also negative. Others have also reported similar results.^{12, 15} The present study included only early cases up to stage I B1. This might have contributed to the high NPV. Barranger et al reported false negative rate of 20% in locally advanced cervical cancer and 0% in early stage disease.⁴

The commonest anatomical location of sentinel nodes was the internal iliac group (61.5%), followed by obturator group (53.8%). This was in contrast to many case series where the commonest site of sentinel nodes was the external iliac group.^{16, 17} This can be attributed to the limited number of cases in our series. Lymphatic anatomy of the cervix is complex. Cervix being a midline structure is likely to have bilateral lymphatic drainage, as noted by Leveuf and Godard¹⁸. But in our series only 3 out of 13 (23%) patients had bilateral sentinel nodes. Indeed the bilateral detection rate in literature varies from 24% and 83%.

One of the key issues of the SN concept is the histological assessment of the lymph node specimen(s). We have adopted standard sectioning with haematoxylin and eosin for evaluation of sentinel lymph nodes. We have not used intra-operative frozen section analysis, because it has low sensitivity for detecting metastases; and the false negative rate of identifying micrometastases can be as high as 70%.¹⁹ Standard sectioning with haematoxylin and eosin staining is not as sensitive as serial sectioning (variable intervals between 50 and 400 μ m) combined with immunohistochemistry (IHC) to detect micro metastases. In contrast, Hakam *et al.* found no additional benefit of

serial sectioning.²⁰ Molecular techniques such as real-time polymerase chain reaction (RT-PCR) are being evaluated for detecting micro metastasis. However, the clinical significance of PCR-detected micro metastasis remains controversial.

The major drawbacks of the present study include-the limited number of patients and the failure to use the combined method using blue dye and radioactive tracers rather than using radioactive tracers alone. The high cost of the equipments required and the lack of availability of qualified and experienced personnel are the major limiting factors for wider application of lymphoscintigraphy especially in countries like India.

In our view the major cause of morbidity after surgery for cervical cancer is due to the parametrial resection rather than the lymphadenectomy. An early cervical cancer i.e., ones which can be treated by surgery alone are those which are unlikely to have nodal metastasis. The morbidity of surgery is considerably increased when it is combined with radiotherapy. Hence sentinel node biopsy can be employed as a technique to detect nodal metastasis with minimum morbidity. Role of laproscopic surgery for cervical cancer is likely to increase in future. Once validated laparoscopic sentinel node biopsy would have potential to reduce surgical intervention time, avoid removal of normal nodes and helps the pathologist to concentrate on the limited number of nodes harvested by sentinel lymph node biopsy. Similarly detection of sentinel node status can help in planning treatment. For example in patients found to have SNB positive for nodal disease can be treated by primary chemo-radiation, thus avoiding additional morbidity of surgery.

CONCLUSION

Sentinel node biopsy is a feasible technique in early stage carcinoma cervix (I A2 to I B2) using radiocolloid injection and lymphoscintigraphy techniques. The results of this study are encouraging; however studies with larger number of patients are needed to confirm these observations.

ACKNOWLEDGEMENT

We would like to thank our colleagues in the department of pathology, Amrita Institute of Medical Sciences and Research Centre, Kochi, for their cooperation.

REFERENCES:

1. Soisson AP, Soper JT, Clarke-Pearson DL, et al. Adjuvant radiotherapy following radical hysterectomy for patients with stage IB and IIA cervical cancer. *Gynecol Oncol.* 1990;37(3):390-5.
2. Gould EA, Winship T, Philbin PH, et al. Observations on a "sentinel node" in cancer of the parotid. *Cancer.* 1960;13:77-8.
3. Cabanas RM. An approach for the treatment of penile carcinoma. *Cancer.* 1977;39:456-66.
4. Barranger E, Coutant C, Cortez A, et al. Sentinel node biopsy is reliable in early stage cervical cancer but not in locally advanced disease. *Ann Oncol.* 16(8):1237-42.
5. DiSaia PJ, Craesman TC. Invasive cervical cancer. In DiSaia PJ, Craesman TC (editors): *Clinical Gynecologic Oncology.* Pub Mosby, Philadelphia. 2001, 6th edition p 61-71.
6. Corn BW, Lanciano RM, Greven KM, et al. Impact of improved irradiation technique, age, and lymph node sampling on the severe complication rate of surgically staged endometrial cancer patients: a multivariate analysis. *Clin Oncol.* 1994;12(3): 510-5.
7. Magrina JF. Complications of irradiation and radical surgery for gynecologic malignancies. *Obstet Gynecol Surv.* 1993;48(8): 571-5.
8. Scheidler J, Hricak H, Yu KK, et al. Radiological evaluation of lymph node metastases in patients with cervical cancer. A meta-analysis. *JAMA.* 1997;278(13):1096-101.
9. Kokka F, Vorgias G, Tserkezoglou A, et al. Preoperative work-up of early cervical cancer (stages Ib-IIa). *Eur J Gynaecol Oncol.* 2003;24(2): 175-7.
10. Echt ML, Finan MA, Hoffman MS, Kline RC, Roberts WS, Fiorica JV. Detection of sentinel lymph nodes with lymphazurin in cervical, uterine, and vulvar malignancies. *South Med J.* 1999;92:204-8.
11. Rob L, Strnad P, Robova H, et al. Study of lymphatic mapping and sentinel node identification in early stage cervical cancer. *Gynecol Oncol.* 2005;98(2):281-8.
12. Lin YS, Tzeng CC, Huang KF, Kang CY, Chia CC, Hsieh JF. Sentinel node detection with radiocolloid lymphatic mapping in early invasive cervical cancer. *Int J Gynecol Cancer.* 2005;15:273-7.
13. Chung YA, Kim SH, Sohn HS, et al. Usefulness of lymphoscintigraphy and intraoperative gamma probe detection in the identification of sentinel nodes in cervical cancer. *Eur J Nucl Med Mol Imaging.* 2003;30:1014-7.
14. Merisio C, Berretta R, Gualdi M, et al. Radioguided sentinel lymph node detection in vulvar cancer. *Int J Gynecol Cancer.* 2005; 15:493-7.
15. Angioli R, Palaia I, Cipriani C, et al. Role of sentinel lymph node biopsy procedure in cervical cancer: a critical point of view. *Gynecol Oncol.* 2005;96:504-9.
16. Malur S, Krause N, Kohler C, et al. Sentinel lymph node detection in patients with cervical cancer. *Gynecol Oncol.* 2001;80(2): 254-7.
17. O'Boyle JD, Coleman RL, Bernstein SG, et al. Intraoperative lymphatic mapping in cervix cancer patients undergoing radical hysterectomy: A pilot study. *Gynecol Oncol.* 2000 Nov; 79(2): 238-43.
18. Grabau DA, Rank F, Friis E. Intraoperative frozen section examination of axillary sentinel lymph nodes in breast cancer. *APMIS.* 2005;113:7-12.21.
19. Leveuf J, Godard H. Les lymphatiques de l'uterus. *Rev Chir* 1923;3:219-4833.
20. Scholz HS, Lax SF, Benedicic C, et al. Accuracy of frozen section examination of pelvic lymph nodes in patients with FIGO stage IB1 to IIB cervical cancer. *Gynecol Oncol.* 2003;90:605-9.
21. Hakam A, Nasir A, Raghuvanshi R, et al. Value of multilevel sectioning for improved detection of micrometastases in sentinel lymph nodes in invasive squamous cell carcinoma of the vulva. *Anticancer Res.* 2004;24(2C):1281-6.

