

Case Report-IV

Multifocal Intracranial Hemangiopericytoma

AMIT BAHL, DN SHARMA, M EESA AND GK RATH

ABSTRACT

Hemangiopericytomas are uncommon central nervous system tumours of vascular origin. Surgery followed by radiotherapy is the mainstay of treatment. These tumours are known to recur locally and distant metastases are reported. However, multifocality either in the primary setting or recurrant setting is rarely reported. The 10 year survival rate varies from 27 – 40 %. We report here a rare case of multifocal central nervous system heman-giopericytoma occurring in a thirty two year female patient treated by surgery and radiotherapy.

CASE: A thirty two year old, female presented to 'Brain tumour clinic' in November 2005 with complaints of headache and progressive weakness in left side of body of 2 months duration. The patient had undergone gross total excision of right parietal parasagittal tumour in 1997 and was diagnosed to have hemangiopericytoma. The patient received post operative Gamma Knife radiation treatment to residual tumour to a dose of 15 Grays.

Current evaluation included MRI of brain which revealed multiple well defined extra axial homogeneously enhancing mass lesions in right high parietal, right posterior parietal region as

well as along the tentorial surface (Fig.1 & 2). Metastatic work up was negative. The patient underwent right quadrangular flap craniotomy and gross total excision of tumour in december 2005. Post operative histopathology showed the tumour to be hemangiopericytoma with a mitosis rate of approximately 5-6/10 high power field. The tumour was positive for vimentin and negative for CD34 and EMA. The histopathological picture showed a higher mitosis rate compared with the earlier post operative pathology reports.. She received whole brain post operative radiotherapy to a dose of 50 Gy in 25 fractions over 5 weeks. At six month follow up the disease was stable.

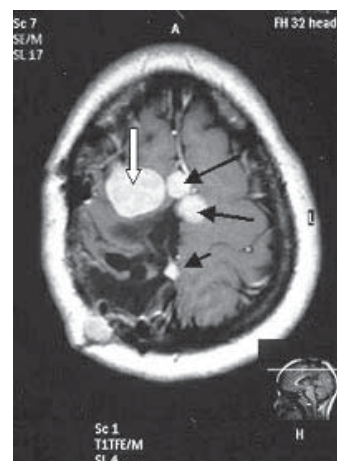


Fig-1 Sagittal gadolinium enhanced, T1 weighted image showing presence of multiple extra axial, homogeneously enhancing dural based mass lesions over the parietal location (solid arrow) as well as along the tentorial surface (open arrow). Some lesions also show presence of a dural tail (arrowhead)

Department of Radiation Oncology, (Amit Bhal, DN Sharma GK Rath) and Radiodiagnosis (M. Eesa)*, All India Institute of Medical Sciences, New Delhi (INDIA)
Correspondence to: **AMIT BAHL**
E-mail: dramitbahl@yahoo.com

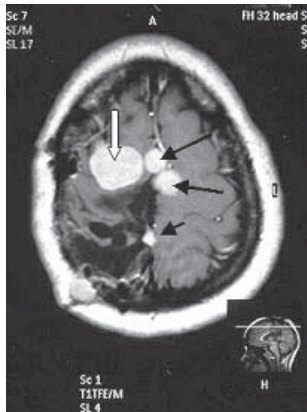


Fig-2 Axial ,gadolinium enhanced T1 weighted image reveals , multiple, lobular extra axial mass lesions showing homogenous enhancement in a parafalcine location (solid arrow) and along dura over right parietal location (open arrow).

DISCUSSION

Intracranial hemangiopericytomas are rare tumours arising from pericytes around capillaries or from mesenchymal cells. These tumours need to be differentiated from meningiomas. Intracranial multiple lesions either in primary or recurrent setting are rarely reported in CNS hemangiopericytomas.¹ These tumours are however known to recur and metastasize to bone, liver, lung and kidney.² Though surgery is the definitive modality of treatment, radiotherapy has been used to treat surgically inaccessible or recurrent tumours and to decrease local recurrence³ Pre operative radiotherapy has been used effectively in high risk surgical cases. Post operative radiotherapy has been associated with increased survival time. Response to radiotherapy has been seen as long as 7 months after treatment. The 5 year actuarial survival rate as high as 71 % has also been reported.⁴ Chemotherapy does not appear to have an established role in the primary management of these tumours.⁵ However in patients with disseminated distant metastasis palliative chemotherapy has been tried.

With current treatment modalities the patient can have a fairly long survival even in metastatic settings. Since our patient showed a recurrence with multiple intracranial lesions the patient was planned for post operative radiotherapy to a dose of 50 Gys over 35 fractions in conventional fractionation. The radiation dose was chosen keeping in mind the previous radiation treatment received and respecting the normal tissue tolerance of brain parenchyma. Our case is unusual because it presented with multiple intracranial lesions without showing any distant metastasis. Borg et al¹ reported a similar case where the patient developed multiple intracranial metastases after undergoing surgery. The patient failed to respond to radiotherapy and died. The response to external beam radiotherapy treatment in our patient at six month follow up was also suboptimal.

Patients presenting with multiple intracranial lesions carry a poor prognosis and are candidates for radiotherapy dose escalation trials using conformal radiotherapy techniques. Role of newer chemotherapy agents also need to be investigated further.

REFERENCES:

1. Borg MF, Benjamin CS. Hemangiopericytoma of the central nervous system. *Australas Radiol.* 1995;39(1):36-41
2. Mena H, Ribas JL, Pezeshkpour GH, Cowan DN, Parisi JE. Hemangiopericytoma of the central nervous system: a review of 94 cases. *Hum Pathol* 1991;22(1):84-91.
3. Uemura S, Kuratsu J, Hamada J, et al. Effect of radiation therapy against intracranial hemangiopericytoma. *Neurol Med Chir* 1992;32(6):328-332.
4. Spitz FR, Bouvet M, Pisters PW, Pollock RE, Feig BW. Hemangiopericytoma :a 20 year single institution experience. *Ann Surg Oncol* 1998;5(4):350-355.
5. Ecker RD, Marsh WR, Pollock BE, et al. hemangiopericytoma in the central nervous system: treatment, pathological features, and long term follow up in 38 patients. *J Neurosurg* 2003;98(6):1182-1187.

