

Case Report-III

Metastatic Choriocarcinoma Presenting as a Renal Mass:

JAYANTA CHAKRABARTI, P. K. MISHRA, PALASH MONDAL, DIBAKAR GHOSH, R. G. CHATERJEE & D. K. G. GHOSH

ABSTRACT

Choriocarcinoma is an aggressive tumour arising as a malignant transformation of the gestational trophoblastic disease or rarely from the germ cells in the ovary. Renal involvement due to choriocarcinoma is rare. We report here one such case.

A 32 year old married woman presented with abdominal pain and vomiting of 15 days duration. She gave history of abortion followed by bilateral oophorectomy 3 years back. Further details were not available. CT Scan of the abdomen showed a renal mass which was reported as a poorly differentiated carcinoma on fine needle aspiration cytology (FNAC). She underwent nephrectomy but patient succumbed within 2 weeks of surgery. Histopathology of the renal tumour revealed a choriocarcinoma, immuno-histochemistry for β -HCG and cytokeratin were positive. She also had elevated serum β -HCG done postoperatively.

Choriocarcinoma must be considered in the differential diagnosis of a renal mass in a young female patient.

INTRODUCTION

Choriocarcinoma is a rare tumour arising from gestational trophoblastic tissue. The disease spreads hematogenously to lungs, brain, liver and rarely to kidney.

CASE: A 32 year old female presented to surgery out patients department in March 2004 with complaints of pain in abdomen and vomiting since last 15 days. In past, she had undergone bilateral oophorectomy (without a hysterectomy) 3 years back following an abortion. Further details (including the histopathology report) were not available. She had a 5 year old male child and had regular menstrual cycles prior to bilateral oophorectomy. Clinical examination revealed pallor and a ballotable mass in the left lumbar region. Investigations: Hb-6.9g%, Ultrasound abdomen showed a large rounded mixed echogenic soft tissue mass inseparable from anterior abdominal wall and lower part of left kidney. IVP-a space occupying lesion in the left kidney with delayed contrast excretion and contralateral renal hypertrophy. She was admitted for evaluation. During hospitalization she also had haematuria. The microscopic examination of the urine revealed numerous RBC's seen at high power field with a few granular casts. CAT scan of abdomen showed large mixed attenuating soft tissue mass involving almost the whole of left kidney with irregular peripheral contrast enhancement. Fascia of gerota was thickened at places and the lesion was inseparable from spleen and left psoas muscle (Fig. 1). The F.N.A.C. showed a poorly differentiated malignant tumour with features suspicious of renal cell carcinoma. The patient was operated and on exploration the tumour was adherent to the surroundings, there were a few small intestinal metastatic sites, with one

Cancer Centre Welfare Home and Research Institute, M. G. Raod, Thakurpukur, Kolkata-700063

Correspondence : JAYANTA CHAKRABARTI
E-mail : chakrabortyj@rediffmail.com

causing intussusception which was resected. A few nodular metastases in the Liver were also seen. The kidney was removed as a palliative procedure. A provisional diagnosis of renal cell carcinoma was made. The patient's condition however deteriorated post operative and she finally succumbed on the second week of surgery, possibly due to internal hemorrhage. The specimen of kidney measured 3.5x8.5x6.5cms and on cut section displayed a hemorrhagic and necrotic tumour mass in the kidney with a thin rim of normal kidney in the lower pole (Fig. 2). Histopathological

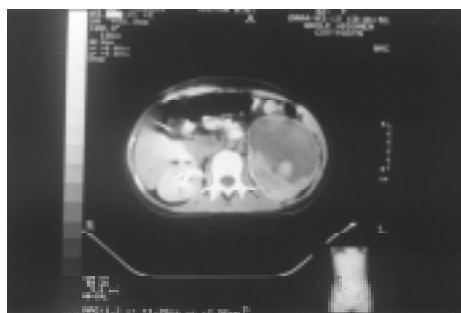


Fig - 1 : CT Scan abdomen. A huge space occupying lesion in the left Kidney, with mixed echogenicity.



Fig-2 : Cut Section of the specimen of left Kidney showing confluent haemorrhagic and necrotic areas, with a thin rim of normal kidney in the lower pole.

examination of the sections from the kidney mass showed bizarre cytotrophoblasts and syncytiotrophoblastic cells with extensive intervening hemorrhage and necrosis (Fig.3) immunohistochemical staining for beta HCG (Fig. 4) and cytokeratin were positive and

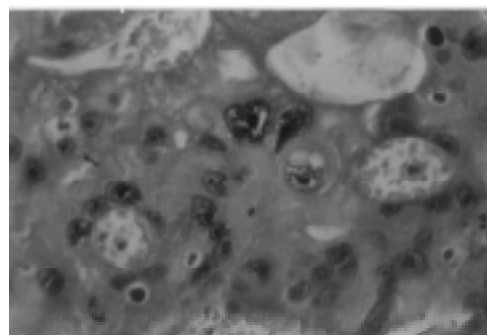


Fig-3 : Choriocarcinoma in kidney; Bizarre Cyto and Syncytiotrophoblastic structures with extensive intervening haemorrhage & necrosis (H&E Stain; 400 X).

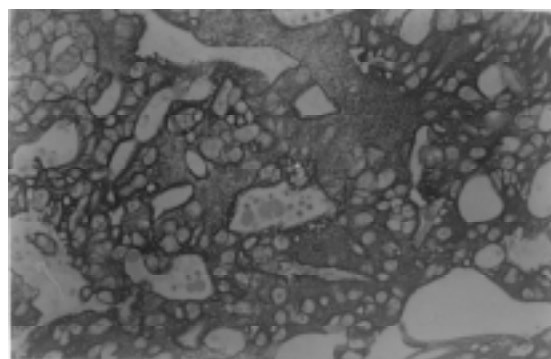


Fig-4 : Choriocarcinoma in kidney; Immunohistochemistry with β HCG; (200 X)

negative staining for desmin. A diagnosis of choriocarcinoma was made. Postoperative serum β -HCG was elevated (199.5u/l). Similar histological features were observed in the sections from small intestine and para-aortic lymph node.

COMMENTS

Choriocarcinoma of the Kidney, primary or metastatic is rare.^{1,2} In a relatively young woman with past history of abortion and clinical presentation of gross haematuria, menstrual irregularity and atypical renal tumour with other sites of metastasis such as lungs, liver, intestine, metastatic choriocarcinoma should be suspected.³

In female patients, majority of the reported case of choriocarcinoma of the kidneys are metastatic lesion from previous gestational choriocarcinoma,^{4,5} mostly associated with disseminated disease and may be detected at

early presentation. Occasionally a patient may present with renal and pulmonary metastatic choriocarcinoma.⁶ This malignancy is known to undergo spontaneous regression of the primary tumour, which in face of metastasis may obscure the primary tumour site.⁶ In one study, two patients presented with profound haematuria and renal enlargement secondary to metastatic choriocarcinoma in the absence of primary malignant foci.⁷

Histologically the choriocarcinoma is characterized by a dual cell population composed of cytotrophoblastic cells with uniform round nuclei, clear cytoplasm, and prominent nucleoli admixed with large, multinucleated syncytiotrophoblastic cells with bizarre nuclei, and abundant eosinophilic cytoplasm. Immunohistochemically, these tumours express strong keratin and β -HCG positivity.⁹ If the index of suspicion is high based on radiological and clinical features, immunocytochemical tests can be done on F.N.A smears. A core needle biopsy is another alternative before a radical surgery is contemplated. However a renal cell carcinoma of the Kidney may have a varied presentation and so a preoperative confirmatory diagnosis may not always be possible. Choriocarcinoma responds well to chemotherapy based on cisplatin, bleomycin with etoposide or vinblastin. Metastatic choriocarcinoma is also classified by the W.H.O as low, medium and high risk.⁹ This scoring system readily identifies those patients who fall in ultra high risk category and need to be treated with dose intensified poly-chemotherapy protocols for better results. The chemotherapeutic regimen (EMA-CO) based on etoposide, methotrexate, actinomycin-D, cyclophosphamide, vincristine has been the standard for high risk metastatic choriocarcinomas, but a dose intensified regimen (EMA-CE), in which cisplatin and etoposide are substituted for vincristine and

cyclophosphamide of the (EMA-CO) regimen, has shown to have some added benefits.¹⁰

CONCLUSION

Renal involvement in gestational choriocarcinoma is known, albeit rare. A high-index of suspicion is important to diagnose these cases early and preoperatively. Surgery may be associated with significant morbidity and mortality.

REFERENCES:

- (1) Washecka R.M, Mann .W, Zuna R. Spontaneous renal hemorrhage secondary to choriocarcinoma N.Y.State J Med.1990;90(8):418-9.
- (2) Newman L.B, Morgan.T.E, Bucy J.G. Choriocarcinoma and bilateral renal metastasis L.B.Urology.1975;5(5):658-61.
- (3) Ikeda. I, Miura.T, Kondo.I. Metastatic choriocarcinoma of the kidney discovered by refractory haematuria. Hinyokika kio-Acta urologica Japonica 1996;42(6):447-9.
- (4) A.U. Zettle Konrad M.A., Polzin. S.A. Urothelial carcinoma of the renal pelvis with choriocarcinomatous features genetic evidence of clonal evolution. Human Pathology 2002;33(12):1234-7.
- (5) Wang Y.E, Song .H.Z, Yang.X.Y. Renal metastasis of choriocarcinoma-A clinicopathological study of 31 cases. Chin Med Journal. 1991;104(9): 716-20.
- (6) Thanikasalam.K. Post hysterectomy choriocarcinoma with pulmonary and renal metastasis Med J Malasia1991;46(2):187-91.
- (7) Mark.R.B, Katz.S.M, Amenta.P.S. Choriocarcinoma of the kidney. Jn Am Osteopathic Asso 1992;92(6):799-802.
- (8) Ogunbiyi O.A,Enweren.E.O. Unusual renal manifestations of choriocarcinoma. Afr J Med 1986;15(3-4):93-7.
- (9) Moran C.A Suster. S. Primary mediastinal choriocarcinoma-a clinicopathological and immunohistochemical. study of 8 cases. Am J Surg Path.1997;21(9):1007-12.
- (10) World Health Organization Scientific Group: Gestational trophoblastic diseases. Geneva: World Health Organization, 1983.
- (11) Surwit EA, Childers JM: High-risk metastatic gestational trophoblastic disease: a new dose-intensive, multiagent chemotherapeutic regimen. J Reprod Med. 1991;36(1):45-48,
- (12) Hara S.Ito.K, Nagata.H. Choriocarcinoma the renal pelvis:Acase report. Hinyokika kio. 2000;46(2):117-21.

