

Images in Clinical Oncology-I

RADIATION PNEUMONITIS

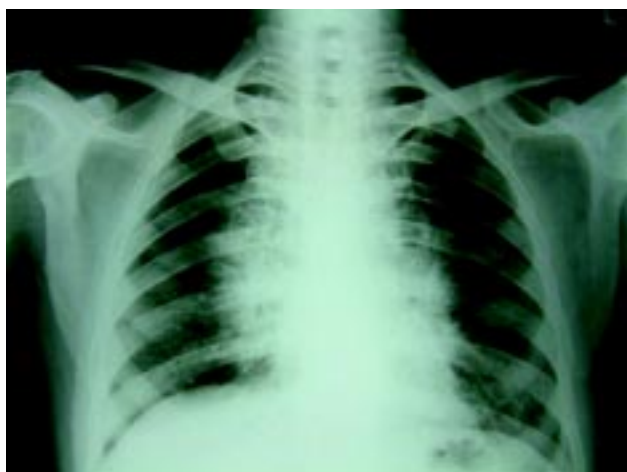

Fig-1 Chest X-ray showing bilateral perihilar infiltrates.

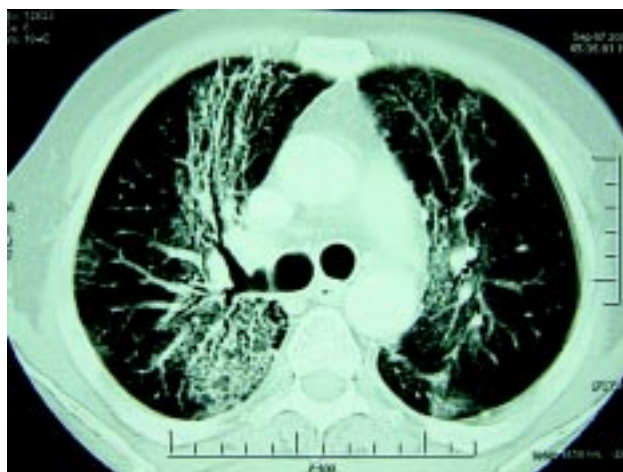


Fig-2 CAT Scan Chest Showing extensive interstitial and parenchymal fibrosis.

A 45 years old male was diagnosed to be a case of anaplastic large cell lymphoma-null cell type in another hospital and had received chemotherapy (cyclophosphamide, dexamethasone and liposomal doxorubicin) and external beam radiation to mediastinum in april 2006. He came to this Institute in view of persistent symptoms. Left supraclavicular lymph node biopsy slide review confirmed the diagnosis of true histiocytic lymphoma. He received 4 cycles of CHOP (Cyclophosphamide, vincristine, doxorubicin and Prednisolone). Evaluation after 4 cycles confirmed complete response. In August 2006, he presented with low grade fever and dyspnoea at rest. X-ray chest revealed bilateral perihilar infiltrates (Fig-1). High resolution CAT Scan revealed extensive interstitial and parenchymal fibrosis characteristically limited to the radiation field (Fig-2). A diagnosis of radiation pneumonitis was made.

Ajay Gupta, SP Kataria & V Kochupillai

Department of Medical Oncology
Institute Rotary Cancer Hospital,
All India Institute of Medical Sciences
New Delhi-110029