

## ***CASE REPORT (III)***

---

---

# Myeloid Sarcoma of Prostate with Urinary Obstruction: An Unusual Presentation of Acute Myelogenous Leukemia in a Child.

ABHISHEK JOSHI, APURVA PATEL, KIRTI PATEL, SANDEEP SHAH,  
PANKAJ SHAH, SHILIN N SHUKLA, BIRWA SHAH \*

---

### **ABSTRACT**

We describe here a case of myeloid sarcoma of prostate in an 8 year old child who presented with bladder outflow obstruction. Peripheral blood picture was normal and CECT of abdomen and pelvis showed a hypoechoic mass in prostate causing bilateral hydronephrosis. A diagnosis of rhabdomyosarcoma of prostate was considered. Bone marrow examination done as a part of metastatic workup revealed 38% blasts which were positive for Sudan Black and myeloperoxidase (MPO) indicating a diagnosis of acute myeloid leukemia (AML) – (FAB M2 subtype). An ultrasound guided biopsy of the prostate mass showed myeloblasts in a stroma of spindle cells which on immunohistochemistry (IHC) were positive for MPO. Flowcytometry was positive for CD 33 and CD 34. This mass completely disappeared after a week of induction chemotherapy using cytosine arabinoside (Ara-C), daunorubicin and etoposide with complete resolution of symptoms. Granulocytic sarcomas are rare in prostate; only 9 cases reported in adults. We could not find similar report in children. Granulocytic sarcoma should be considered in differential diagnosis of mass in anuric children.

### INTRODUCTION

Myeloid sarcoma, a form of leukemic infiltration is a tumour mass of myeloblasts or immature myeloid cells occurring in an extra medullary site. Only 9 cases of prostate myeloid sarcoma have been reported so far in adults (5 in association with AML, 2 as a site of relapse in AML, one preceding AML and another in association with myelodysplastic syndrome).<sup>1,2,3,5,7</sup>

We present here a case of acute myeloid leukemia (AML) in a child who presented with bladder outflow obstruction due to prostate myeloid sarcoma. To the best of our knowledge, this is the first paediatric case, earlier cases have been reported among adults<sup>3</sup>. More importantly symptoms due to the mass developed when there were no known symptoms or signs of AML. The clinical imaging and pathological findings at onset, after therapy and during follow up are described.

**CASE :** This 8 year old boy was referred to us for evaluation of pain in abdomen since 1 year, bladder outflow obstruction since 15 days and an abdominal pelvic ultra sound showing a hypoechoic mass in prostate. A detailed physical examination revealed a tender 30 X 30 mm, retroperitoneal mass in hypogastrium fixed to underlying structure.

An ultrasound scan of the pelvis showed a 44 X 40 X 40 mm hypoechoic lesion in prostate

---

Department of Medical Oncology, Department of Pathology,\*  
M.P Shah Cancer Hospital & I.J Kinariwala Paediatric  
Hemato-Oncology Centre, Gujarat Cancer & Research Institute  
Ahmedabad – 380016, Gujarat, INDIA.  
Correspondence to : **ABHISHEK JOSHI**  
E-mail: dr\_ajoshi@yahoo.com

involving left bladder (UB) wall, displacing the rectum posteriorly, with loss of fat planes surrounding the lesion and causing moderate hydronephrosis of left side. A subsequent CECT of abdomen & pelvis showed a large (45X45X42 mm) irregular, heterogeneously enhancing mass, not separable from prostate, displacing UB to the right side and encasing lower end of left ureter causing bilateral hydronephrosis more on the left side (Fig. 1). Routine hemogram and peripheral smear

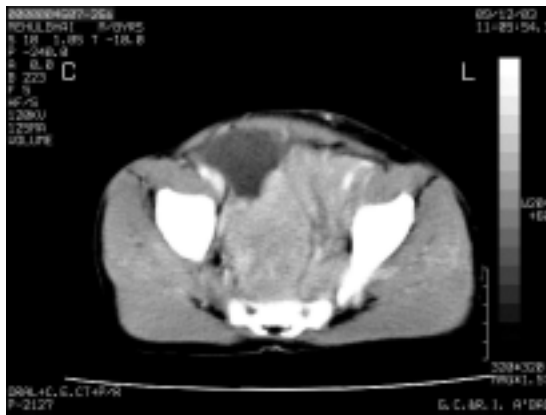

Fig 1. Prechemotherapy CECT of abdomen and pelvis showing heterogeneously enhancing prostate mass displacing UB to right and pushing rectum posteriorly

were normal. A diagnosis of rhabdomyosarcoma (RMS) of prostate was made. Bone marrow done as a part of metastatic work up of rhabdomyosarcoma (RMS) showed presence of 38% blasts which showed significant myeloperoxidase (MPO) positivity and sudan black positivity on cytochemistry. A diagnosis of AML- FAB M2 was interpreted.

An ultrasound guided biopsy of prostatic mass showed myeloblasts and spindle cells scattered among the stroma of muscles and was interpreted as prostatic myeloid sarcoma. Immunohistochemistry analysis showed myeloperoxidase positivity in prostate biopsy specimen (Fig 2) and flow cytology on bone marrow showed CD33, CD 34 and CD 45

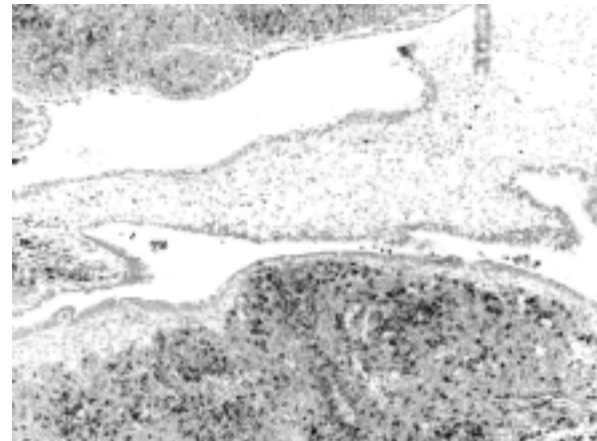


Fig 2. IHC of prostate mass tissue : showing strong MPO positivity characterized by greenish black colour of immunostain.

expression. Cytogenetic analysis showed a normal karyotype 46 XY.

The symptoms of bladder outflow obstruction completely resolved within a week of induction chemotherapy with AML- BFM 87 protocol (Ara C with daunorubicin and etoposide) A repeat CECT scan of abdomen and pelvis after induction chemotherapy showed complete disappearance of mass with restoration of normal

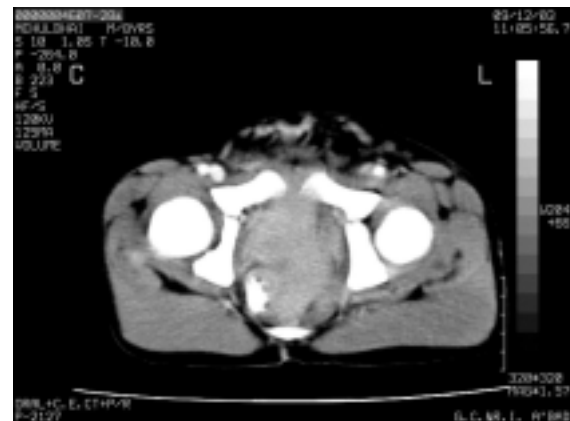

Fig 3. Post induction chemotherapy CECT of abdomen showing complete disappearance of mass with restored architecture of rectal fat planes.

fat planes between prostate and rectum and reversion of hydronephrosis (Fig. 3).

**DISCUSSION**

Myeloid sarcoma is also known as granulocytic

sarcoma, extramedullary myeloid tumour or chloroma (green tumour). The green appearance is a result of the presence of myeloperoxidase enzymes in the immature myeloid cells.<sup>4</sup> This favoured name was later changed to granulocytic sarcoma following description of lesions that were not green (disappearance of colour due to exposure to air or fixation in formalin). Now we are aware that not all myeloid leukemias are derived from granulocytes, the preferred term is myeloid sarcoma.

In association with AML, myeloid sarcomas may be found in the active phase of the disease, as the first manifestation of relapse or de novo in healthy subjects who may later develop AML.<sup>4,5</sup>

The clinical presentation varies and depends upon the site of involvement. Commonly involved sites of occurrence include - subperiosteal bone structures of the skull, para nasal sinuses, sternum, ribs, vertebrae and pelvis; lymph nodes and skin.<sup>4</sup> Rare sites reported in the literature include - pancreas, heart, brain, mouth, breast, GI tract, urinary bladder, gynaecological tract and prostate.<sup>6</sup>

The mean age of presentation of prostate myeloid sarcoma is 67 years<sup>7</sup>. Differential diagnosis of prostate myeloid sarcoma includes small round cell tumours (rhabdomyosarcoma, neuroblastoma, Ewings sarcoma, and peripheral neuroectodermal tumour), lymphoma and prostate neoplasms. The use of immunohistochemical stains has aided us in the diagnosis of prostate myeloid sarcoma.

The use of only four antibodies (MPO, CD68, Lysozyme and CD34) has been proposed to distinguish the more common variants of myeloid sarcomas<sup>8</sup>. Treatment is similar to that for AML,

even in cases with isolated tumours with no blood or bone marrow involvement.<sup>9</sup>

Prostate myeloid sarcoma, a rare manifestation of AML in adults, also does occur in children and can present with sign, and symptoms related to the mass during the active phase of the disease.

#### REFERENCES:

1. Spethmann S, Heuer R et al. Myeloid Sarcoma of the prostate as first clinical manifestation of acute myeloid leukemia. *Lancet Oncol.* 2004;5(1):62-3
2. Chan YF. Granulocytic sarcoma (Chloroma) of the kidney and prostate. *Br J Urol.* 1990;65(6):655-6
3. Frame R, Head D, Lee R, Craven C et al. Granulocytic Sarcoma of the prostate. Two cases causing urinary obstruction. *Cancer.* 1987;59(1):142-6.
4. Brunning RD, Bennet J, Matutes E, et al. Acute Myeloid Leukemia not otherwise categorized. In: Jaffe ES, Harris NL, Stein H and Vardiman JW (eds). *WHO Classification of Tumours; Pathology and Genetics of Tumours of Haematopoietic and Lymphoid Tissues.* IARC Press, Lyon 2001:104-105.
5. Thalhammer F, Gisslinger H, Chott A, et al. Granulocytic sarcoma of the prostate as the first manifestation of late relapse of acute myelogenous leukemia. *Ann Hematol.* 1994;68(2):97-99.
6. Audouin J, Comperat E, Le Tourneau A, et al. Myeloid sarcoma: clinical and morphologic criteria useful for diagnosis. *Int J Surg Pathol.* 2003;1:1272-82.
7. Quein ET, Wallach B, Sandhaus L, et al. Primary extramedullary leukemia of the prostate : Case report and review of literature. *Am J Hematol.* 1996;53(4):267-71.
8. Chang CC, Eshoa C, Kampalath B, et al. Immunophenotypic profile of myeloid cells in granulocytic sarcoma by immunohistochemistry. Correlation with blast differentiation in bone marrow. *Am J Clin Pathol* 2000;114:807-811.
9. Byrd JC, Edenfield WJ, Shields DJ, et al. Extramedullary myeloid cell tumours in acute non lymphocytic leukemia: a clinical review. *J Clin Oncol.* 1995;13:1800-1816.

