Article published online: 2022-03-28



## *Case Report (I)*

# Melanotic Progonoma-A Case Report and Review of Literature

SENTHIL RAJAPPA, I. SATISH RAO, D. RAGHUNADHA RAO, C. SUNDARAM, ANJNA SURATH, M. UMA DEVI

**ABSTRACT**

**A 6-month-old baby girl presented with a swelling arising from the oral cavity. On examination there was a hard bluish mass arising from the maxilla. An FNABC (Fine needle aspiration biopsy cytology) was suggestive of a melanotic progonoma. The tumour was resected and the histopathology examination confirmed the same. The case is being reported for its rarity and the classical clinical and pathological findings.**

## INTRODUCTION

Melanotic progonoma or Melanotic neuroectodermal tumour of infancy (MNTI) is a rare tumour. Only about 200 cases have been reported. The tumour characteristically occurs in the maxilla and has a typical bluish colour due to the presence of melanin. It is usually asymptomatic. As the tumour can have a very rapid growth it can lead to a misdiagnosis of malignancy. It is a locally aggressive tumour. The incidence of malignancy is rare. Wide local excision is the treatment of choice. Local recurrences are well known. Hence, patients need to be on regular follow-up.

## CASE REPORT

A 6-month-old baby girl presented to the outpatient department with complaints of a swelling arising from the mouth of 6 weeks duration. She was apparently normal 6 weeks ago when the mother noticed a small swelling arising from the upper alveolus. The swelling was progressively increasing in size. It was initially not associated with pain, fever and difficulty in swallowing. The baby had no difficulty in breast-feeding. However, with increasing size, the baby started having difficulty in feeding. She was born of a non-consanguineous parentage and a full term normal delivery. There was no history of any drug intake by the mother during pregnancy except hematinics. The milestones were normal. She was adequately vaccinated for her age.

On examination, the baby was cheerful and cooperative. The weight, head circumference and body length were normal for her age. There was a bluish, hard, fixed 7x5 cm swelling arising out of the mouth, predominantly to the right side and extending to the opposite side (Fig 1). The

Fig 1-Photograph showing mass arising from the oral cavity

Department of Medical Oncology
E Block, VI Floor, Nizam's Institute of Medical Sciences
Panjagutta, Hyderabad
Correspondence to : **SENTHIL RAJAPPA**
E mail: siddharth142@sify.com

posterior and lateral margins of the swelling were not well made out. It was non-tender, not warm, non-pulsatile and there was no bruit or bleeding. There were no palpable nodes in the neck. There was no fever, pallor, ear discharge, cyanosis, lymphadenopathy, bony tenderness, petechiae, purpura or skin lesions. The examination of the cardiovascular, respiratory, abdomen and central nervous systems were normal. In view of the short history, a clinical diagnosis of a malignant tumour, probably a rhabdomyosarcoma or a Langerhans cell histiocytosis was made.

A plain radiograph showed an ill-defined soft tissue lesion in the region of the maxilla. The bony defects were not clearly made out. A contrast enhanced axial section computed tomography (CT) scan of the paranasal sinuses showed a heterogeneously enhancing osteolytic mass lesion arising from the alveolar process of the right maxilla (Fig 2). There was an

Fig 2-Coronal section CT scan showing an expansile mass lesion from the maxilla

expansion of the involved bone with trabeculation associated with loosening of the teeth. The axial section bone windows showed a break in the cortex with extension into the subcutaneous planes and extension to the contra lateral side (Fig 3). Her complete blood picture,

Fig 3-Axial CT (bone window) showing osteolytic lesion involving the maxilla with soft tissue component

liver and renal function tests were normal for her age. A chest radiograph and ultrasound of the abdomen were normal. A FNABC (Fine needle aspiration biopsy cytology) revealed a possibility of a melanotic neuroectodermal tumour of infancy.

The baby underwent resection of the tumour. At surgery, there was a mass arising from the alveolar process of the maxilla with a soft-tissue component and bone destruction. A wide excision of the mass was done and the tumour was submitted for histopathology examination (HPE).

The HPE sections showed biphasic population consisting of small round cells in the center with scant cytoplasm surrounded by large cells containing melanin pigment (Fig 4). Further sections showed infiltration into

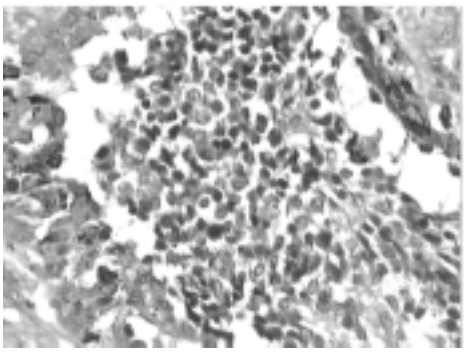

Fig 4-HPE sections showing biphasic pattern with melanin in the large cells

bone. This was consistent with diagnosis of melanotic neuroectodermal tumour of infancy or melanotic progonoma. There were no features of malignancy. The margins were negative. The child made an uneventful postoperative recovery. The child was advised a 3-monthly follow up.

## DISCUSSION

Melanotic progonoma or melanotic neuroectodermal tumour of infancy (MNTI) is a relatively uncommon, osteolytic, pigmented lesion that affects the jaws of newborn infants. Krompecker described it first in 1918 as a melanocarcinoma.[1] As the cell of origin was unclear, many terms were used to describe this tumour. These include, pigmented ameloblastoma, retinal analge tumour, melanotic adamantinoma, retinal choristoma etc. This reflects the suspected origin from odontogenic apparatus, the pigmented anlage of the retina and the sensory neuroectodermal tissues. In 1966, high urinary vanillylmandelic acid (VMA) was found to be excreted in the urine of patients with this tumour.[2] This suggested a neural crest origin .[1,3,4] It was later confirmed by immunohistochemical, electronmicroscopic and tissue culture studies. However, the presence of VMA in the urine is not diagnostic of a melanotic progonoma.

Most patients present with a tumour in the first year of life. The median age of occurrence is 4.3 months. Our patient presented at 6 months of age. There is no sexual predilection. The patient is usually asymptomatic except for swelling in the region of the oral cavity.[4,6] Often, feeding and sucking are impaired.

More than 90% of melanotic progonomas occur in the head-and-neck region. The most common site is the anterior part of the maxilla. Other sites include skull, mandible and brain[4,5,6,7,8] It begins as a non-ulcerated pigmented blue or black lesion arising from the maxilla. The lesion is solitary and multiple lesions are extremely rare.[9] Although this tumour is classified as a benign tumour the rate of growth can be alarming, leading to misdiagnosis of a malignancy clinically.

Our patient had all the above characteristics including the rapid growth rate described in the literature. Our clinical diagnosis was that of a malignant tumour. As the diagnosis of a melanotic progonoma or a metastatic neuroblastoma was not considered a urinary VMA was not requested.

The location of the tumour in the anterior aspect of the maxilla is consistent with a number of differential diagnoses, which includes benign and malignant tumours.[10] This includes benign lesions like ameloblastoma, odontoma, odontogenic myxoma and fibroma and malignant tumours like Ewings tumour, rhabdomyosarcoma, Langerhans cell histiocytosis and non-Hodgkin's lymphoma. Although the clinical features are typical, there are no characteristic radiological findings and hence pathology remains the cornerstone of diagnosis.

Plain dental radiographs, Computed tomography scan (CT) and Magnetic resonance imaging (MRI) are used to evaluate the content and extent of the lesion. Radiographic appearance of a well-circumscribed, low-density unilocular lesion without calcification typically arising from the maxilla is suggestive but not confirmatory of melanotic progonoma. As the tumour grows, the bone is destroyed suggesting a malignant process. These radiological characteristics are best observed in maxillary occlusion views.[5,6] CT scan and MRI with contrast are used to define the extent of lesion before surgery.

The histologic pattern is characteristic, with a biphasic pattern and a moderately fibrovascular background. The tumour shows infiltration into the adjacent bone.[11] The tumour contains large polygonal and cuboidal cells arranged in sheets and alveolar patterns that often contain melanin. Fontana stain can be used to highlight the melanin. Biphasic pattern and bone infiltration with presence of melanin was demonstrated in our case. Immunohistochemistry and electron micro-scopy help in confirming the diagnosis in doubtful cases lacking the typical histologic features. The tumour cells are positive for cytokeratin, HMB 45, synaptophysin, and neuron specific enolase.[12] They are negative for S 100 electron

microscopy demonstrates ultrastructural evidence of neural, epithelial and melanocytic features. As the morphology was characteristic immunohis tochemical stains were not done to confirm the diagnosis.

The incidence of malignancy is very rare and accounts for 2% of all cases. Few reported malignant cases had more mitoses, increased vascularity and focal necrosis. Diagnosis of malignancy is based on increased growth rate, infiltration and metastasis. Metastasis has been described to lymph nodes, liver and adrenal.

The treatment of choice is complete surgical excision.[13] This could be achieved successfully in our patient. Developing teeth and surrounding tissues may need to be sacrificed to attain an adequate surgical margin of 5 mm. The recurrence rates range from 10-60% in various reports.[10] In case of inoperable recurrence or margin positive resection radio and chemotherapy have been used. Metastases occur in 2% of cases.[10]

Patients have to be under close follow-up to detect recurrences. Permanent reconstruction can be done after growth is completed. The rapid growth can lead to a misdiagnosis of malignancy clinically. Hence a high index of suspicion is necessary to diagnose this tumour.

**REFERENCES:**


1) *Dehner LP, Sibley RK, Sauk JJ Jr, et al. Malignant melanotic neuroectodermal tumour of infancy: a clinical, pathologic, ultra structural and tissue culture study. Cancer 1979;43:1389-1410*

2) *Borello ED, Gorlin RJ. Melanotic neuroectodermal tumour of infancy-a neoplasm of neural crest origin. Report of a case associated with high urinary excretion of vanilmandelic acid. Cancer 1966 ;19(2):196-206.*

3) *Navas Palacios JJ. Malignant melanotic neuroectodermal tumour: light and electron microscopic study. Cancer 1980;46:529-536*

4) *Hoffman S, Jacoway JR, Krolls SO. Intraosseous and parosteal tumours of the jaws. Atlas of tumour pathology. 2nd series. Fascicle 24. Washington, D.C.: Armed Forces Institute of Pathology, 1987:165-9.*

5) *Mosby EL, Lowe MW, Cobb CM, et al. Melanotic neuroectodermal tumour of infancy: review of the literature and report of a case. J Oral Maxillofac Surg 1992;50:886-894*

6) *Cutler LS, Chaudhry AP, Topazian R. Melanotic neuroectodermal tumour of infancy: an ultra structural study, literature review, and reevaluation. Cancer 1981;48:257-270*

7) *Pettinato G, Manivel JC, d'Amore ES, et al. Melanotic neuroectodermal tumour of infancy: a reexamination of a histogenetic problem based on immunohistochemical, flow cytometric, and ultra structural study of 10 cases. Am J Surg Pathol 1991;15:233-245.*

8) *Kapadia SB, Frisman DM, Hitchcock CL, et al. Melanotic neuroectodermal tumour of infancy: clinicopathological, immunohistochemical, and flow cytometric study. Am J Surg Pathol 1993;17:566-573.*

9) *Young S, Gonzalez-Crussi F. Melanocytic neuroectodermal tumour of the foot: report of a case with multicentric origin. Am J Clin Pathol 1985;84:371-378*

10) *Volk MS, Neilson P. Case records of the Massachusetts General Hospital. Weekly clinicopathological exercises. Case 7-2001. A male infant with a right maxillary mass. N Engl J Med 2001;344(10):750-7.*

11) *Fletcher C. Melanotic neuroectodermal tumour of infancy. Clinicopathological, immunohistochemical and flow cytometry study. Am J Surg Pathol 1995;17:566-573.*

12) *Stirling RW, Powell G, Fletcher CD. Pigmented neuroectodermal tumour of infancy: an immunohistochemical study. Histopathology 1988;12:425-435*

13) *Kaya S, Unal OF, Sarac S, et al. Melanotic neuroectodermal tumour of infancy: report of two cases and review of literature. Int J Pediatr Otorhinolaryngol 2000;52(2):169-72.*