Article published online: 2022-03-28

Bilateral Proptosis in a Child with AML

a

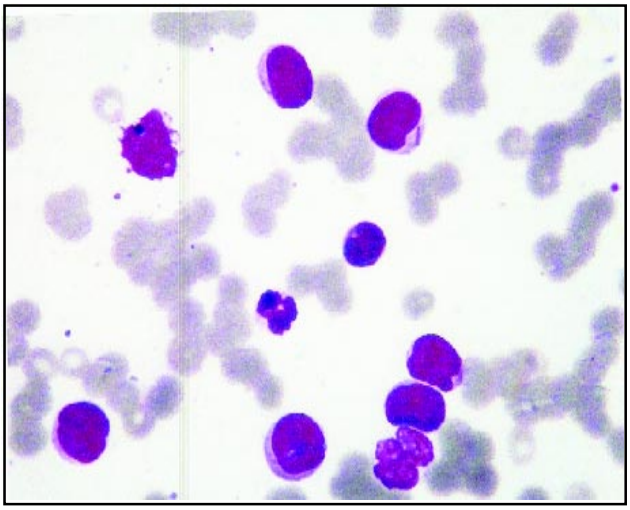

b

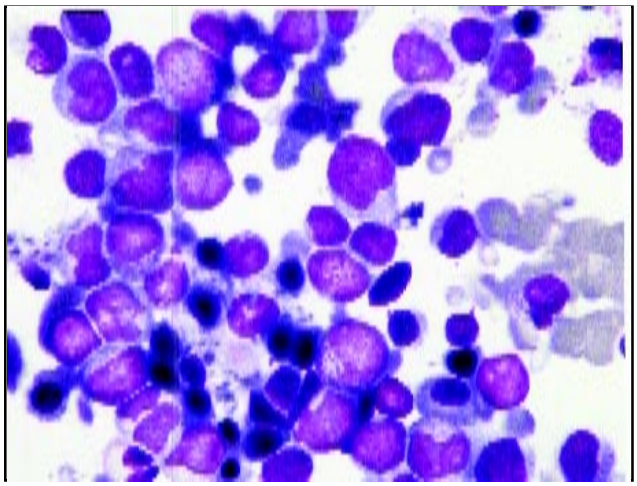

c

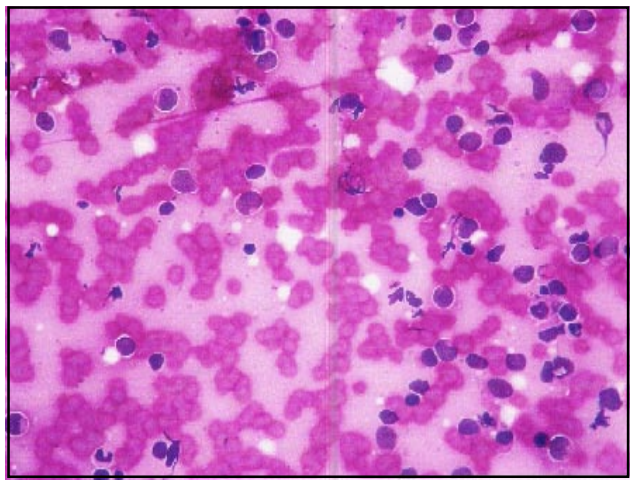

d

A 3.5 year old male child was brought to the emergency . He was febrile, pale and had bilateral proptosis (Fig. a) and cervical adenopathy. Investigations. Blood Hb 3.5G%, WBC-70,000/cmm, DLC- 80% blasts with auer rods (Fig. b) Bone marrow examination confirmed the diagnosis of AML –M2 (Fig . c). Cytogenetics was not done. Lymph node aspiration revealed presence of blasts (Fig. d).

Proptosis is an uncommon presentation in children. Common causes of bilateral proptosis include – granulocytic sarcoma due to AML/MDS, and metastatic neuroblastoma. Rhabdomyosarcoma is the most frequent cause of unilateral proptosis followed by retinoblastoma (frequent in India) , granulocytic sarcoma and neuroblastoma .

AK Kalwar, V Kumar, V Yadav, SK Bishnoi, HS Kumar & DP Punia
Acharya Tulsi Regional Cancer Treatment & Research Institute, Bikaner