



# Reconstruction of a Composite Defect of the Distal Index Finger Using a Chimeric Reverse Flow Second Dorsal Metacarpal Artery Flap: A Case Report

Koichi Yano<sup>1</sup> Yasunori Kaneshiro<sup>1</sup> Megumi Ishiko<sup>1</sup> Seungho Hyun<sup>1</sup> Hideki Sakanaka<sup>1</sup>

<sup>1</sup>Department of Orthopaedic Surgery, Seikeikai Hospital, Sakai-ku, Sakai City, Osaka, Japan

Address for correspondence Koichi Yano, MD, PhD, Department of Orthopaedic Surgery, Seikeikai Hospital, 1-1-1 Minamiyasuicho, Sakai-ku, Sakai City, Osaka 590-0064, Japan (e-mail: koichiyano@hotmail.com).

J Hand Microsurg 2023;15:148–151.

## Abstract

The reconstruction for mild tissue loss at the distal part of a finger is challenging. We report about a 29-year-old man presenting with traumatic tissue loss at the distal interphalangeal (DIP) joint of the index finger, including skin, bone, and nerve. Reconstruction using two types of flaps was performed. The dorsal skin flap, nourished by the second dorsal metacarpal artery (SDMA) perforator, was elevated. The vascularized second metacarpal bone, nourished by the SDMA, was also elevated. Using the vascular connection between the DMA and the palmar digital artery (PDA), both flaps were raised to the distal part of the finger, and the pivot point was set at the dorsal proximal phalanx. After arthrodesis of the DIP joint with the vascularized second metacarpal bone, the digital nerve was repaired using the cutaneous nerve in the skin flap, and the skin defect was covered using the perforator flap. The postoperative course, including flap survival and bone union, was uneventful. A good indication for the reconstruction of the distal part of a finger with this technique is when the defect sizes of the skin and bone differ and the vascular connection between the SDMA and dorsal branch of PDA is not injured.

## Keywords

- ▶ dorsal metacarpal artery
- ▶ perforator
- ▶ bone graft
- ▶ chimeric flap

## Introduction

The treatment options for the soft tissue reconstruction of mild defects, 1.5 to 2.0 cm in length, at the distal part of a finger are a cross-finger flap, an advancement island flap, or a reverse digital artery flap. However, each has disadvantages, and there are limited indications for each flap.<sup>1–5</sup>

Dorsal metacarpal artery (DMA) perforator flap is useful for reconstructing finger and palmar soft tissue defects.<sup>6</sup> However, this flap cannot cover the distal to proximal interphalangeal (PIP) joint because of its pedicle length. Conversely, extended DMA perforator flap can cover the distal phalanx of the finger depending on the distal pivot

point using the connection between the DMA and dorsal branch of the palmar digital artery (PDA).<sup>7–10</sup>

There is one report on the reconstruction of both skin and bone at the PIP joint using the compound flap (bone, fascia, and skin) pedicled by the DMA perforator.<sup>11</sup> For reconstruction of both skin and bone at the distal interphalangeal (DIP) joint level, there is no report of reconstruction in such cases with the pedicled compound flap using DMA.<sup>12–14</sup>

Herein, we report the surgical procedure and clinical outcomes of a patient with skin, nerve, and joint defects at the DIP joint who underwent a pedicled chimeric flap reconstruction.

article published online  
July 15, 2021

DOI <https://doi.org/10.1055/s-0041-1731938>.  
ISSN 0974-3227.

© 2021. The Author(s).

This is an open access article published by Thieme under the terms of the Creative Commons Attribution-NonDerivative-NonCommercial-License, permitting copying and reproduction so long as the original work is given appropriate credit. Contents may not be used for commercial purposes, or adapted, remixed, transformed or built upon. (<https://creativecommons.org/licenses/by-nc-nd/4.0/>).

Thieme Medical and Scientific Publishers Pvt. Ltd. A-12, 2nd Floor, Sector 2, Noida-201301 UP, India

## Case Report

A 29-year-old right-handed male timber worker suffered his right index finger that had been hit by wood while working. He did not have a previous medical history.

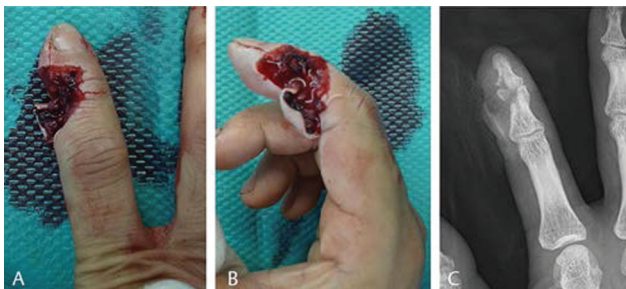Initial examination showed a contaminated, punched out, tissue defect on the radial side of the index finger with maintaining circulation (►Fig. 1A, B). Plain radiography revealed a comminuted intra-articular fracture and a defect of the DIP joint of the index finger (►Fig. 1C).

On the following day, surgery was performed under general anesthesia. Because the patient requested to preserve the finger length, we decided to perform soft tissue reconstruction and arthrodesis of the DIP joint. Before surgery, the second DMA (SDMA) perforator and dorsal branch of the ulnar PDA at the proximal phalanx were marked using color Doppler ultrasonography (►Fig. 2A).

After debridement, the skin defect (32 mm × 20 mm) and radial digital artery and nerve defects were observed. The radial two-thirds of the articular surface of the DIP joint was lost. The DIP joint was fused using wires after resection of remaining articular cartilage.

The skin flap (38 mm × 22 mm) was designed between the second and third metacarpal bones on the dorsal side of the hand. The flap was elevated over the paratenon of the extensor tendon from the proximal to SDMA perforator, and the dorsal cutaneous nerve to the index finger was included (►Fig. 2B). The base of the second metacarpal bone (15-mm long and 7-mm wide) was harvested using a bone chisel and raised with the SDMA at the subfascial and intramuscular layer. The vascular pedicle was elevated with the surrounding fat tissue to maintain microcirculation and to preserve venous return. The SDMA was released to the location of dorsal interosseous muscle penetration where a connection between the DMA and palmar metacarpal artery (PMA) was present. The vessel connection between SDMA and PMA was then cut at this point. The pedicle of both the skin and bone flaps was raised over the paratenon of the extensor expansion hood and the extensor of the index finger to the ulna-dorsal proximal phalanx which was marked as the dorsal branch of the PDA using ultrasonography. The circulation of both flaps was excellent after deflating the tourniquet (►Fig. 2C).

The vascularized bone was fixed to the bony defect using two wires and one external fixator (JuNction, Arata Co., Ltd. Tokyo,

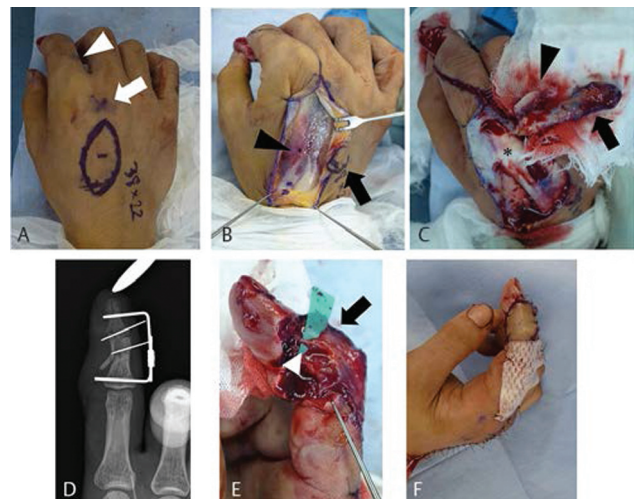


**Fig. 1** Macroscopic photographs and plain radiographs before the operation. (A) Dorsal and (B) radial views. (C) Plain radiograph of the index finger.

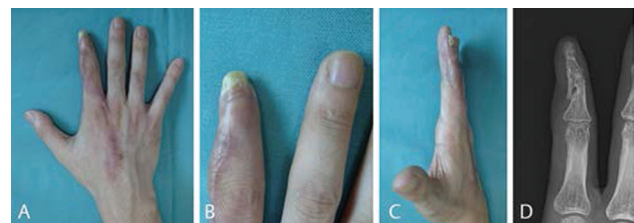
Japan, ►Fig. 2D). The defect of the radial digital nerve was 25-mm long and was repaired using the nerve in the flap as a vascularized cable graft (►Fig. 2E). The skin defect was covered using the flap (►Fig. 2F). The donor site was closed primarily.

Although flap congestion was noted postoperatively, it disappeared on elevating the upper extremity for a week. The PIP and metacarpophalangeal (MP) joint of the finger was mobilized 1 week postoperatively. Bone union was achieved 7 weeks postoperatively, and the wires were removed. The patient returned to work 3 months postoperatively.

At the final follow-up at 1 year postoperatively, the patient was asymptomatic in daily life and work. Slight numbness on the dorsal surface of the proximal phalanx of the index finger was noted, and a nail deformity with the nail being slightly shorter and narrower than normal was observed (►Fig. 3A–C). Plain radiography at the final follow-up showed bony union (►Fig. 3D). There was no neuroma formation. The grip strength of the right and left hands



**Fig. 2** Intraoperative photographs. (A) Design of the skin flap. The dorsal branch of the ulnar palmar digital artery (arrowhead) and second dorsal metacarpal artery perforator (arrow) are marked using color Doppler ultrasonography. (B) The elevated skin flap (arrow) and extensors were retracted to the ulnar side. Arrowhead indicates second dorsal metacarpal artery. (C) The elevated skin flap (arrow) and vascularized bone (arrowhead) showed good circulation after deflating the tourniquet. The metacarpophalangeal joint is indicated by the asterisk. (D) Plain radiography immediately post-surgery. (E) Nerve grafting performed after bone fixation. The dorsal cutaneous nerve is indicated by the arrowhead. The skin flap is indicated by the arrow. (F) After the operation.



**Fig. 3** Macroscopic photograph at 1 year after operation. (A) Dorsal, (B) enlarged dorsal, and (C) radial views. Scar formation on the dorsal side of the hand was noted. (D) Plain radiography at the final follow-up.

was 29.6 and 34.2 kg, respectively, and pulp pinch was 1.8 and 7.0 kg, respectively. The active extension/flexion range of motion of the index finger was as follows: MP joint, 10/90 degrees; PIP joint, 0/90 degrees; and DIP joint, 0/0 degrees. Evaluation of the sensory function of the distal index finger (radial side/ulnar side) was observed to be 9/3 mm using static two-point discrimination (2PD) and 7/2 mm using the moving 2PD. The Disabilities of Arm, Shoulder, and Hand score was 6.7 for disability/symptom and 6.3 for work.

The patient was informed that the data from the case would be submitted for publication, and he gave his consent for publication.

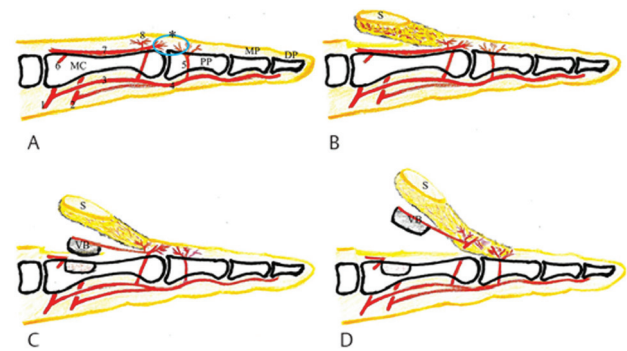
## Discussion

The distally based flaps on the dorsal side of the hand, including the DMA perforator flap, DMA flap, and the extended DMA flap, are ideal flaps for reconstructing the dorsal soft tissue.<sup>6–10,15</sup> In this report, we used a reverse flow extended DMA skin flap and were able to cover the soft tissue defect at the DIP joint by setting a pivot point more distally than the DMA flap.

For bony reconstruction, the use of a vascularized bone graft has several advantages: maintaining vascularity to prevent infection by increasing local phagocytosis and antibiotic delivery and decreasing bacterial counts, structural support, and a high rate of union by viable cells.<sup>16,17</sup>

There are arterial networks between the dorsal and palmar arteries in the hand and fingers (►Fig. 4A).<sup>10,18</sup> The SDMA arises from the dorsal carpal arch and anastomoses with the PMA, the dorsal perforating branches of the deep palmar arch, near the metacarpal neck. Furthermore, there is a vascular connection between the proximal dorsal cutaneous branches of the PDA and the dorsal digital branches of the DMA at the level of the proximal phalanx. We utilized the vascular connection between the dorsal branch of the PDA and the distal DMA as a pedicle, and thus the chimeric flap could reach the DIP joint and distal phalanx (►Fig. 4A). A challenging issue in this case was that the sizes and longitudinal axes of the bone and skin defects differed. To elevate the DMA perforator flap, the flap needed to be over the paratenon of the extensors (►Fig. 4B). To harvest the vascularized metacarpal bone, the flap needed to be under the extensors, and the DMA needed to be under the fascia of the interosseous muscle (►Fig. 4C). Therefore, we could harvest the skin flap and bone graft using two types of pedicle separately, and we could also adjust the size of the bone and skin to that of the defect (►Fig. 4D).

For the reconstruction of both skin and bone at the level of the DIP joint, there have been two previous case reports, an iliac crest bone graft and extended DMA flap in one patient and a free metacarpal bone graft and extended DMA flap in another.<sup>12,13</sup> Because bony reconstructions were performed using a nonviable bone graft in the former report, there were concerns with the risk of infection and nonunion.<sup>13</sup> For the latter report, the procedure of a free metacarpal bone graft seemed to be a complicated one,<sup>12</sup> and plain radiography was



**Fig. 4** Schema of the surgical procedures. (A) Normal anatomy of the arteries. DP, distal phalanx; MC, metacarpal bone; MP, middle phalanx; PP, proximal phalanx; 1, deep palmar arch; 2, superficial palmar arch; 3, palmar metacarpal artery; 4, common digital artery; 5, dorsal branch of palmar digital artery (PDA); 6, dorsal carpal arch; 7, second dorsal metacarpal artery (SDMA); 8, DMA perforator; asterisk (\*), anastomosis between the SDMA and the dorsal branch of the PDA. (B) Elevation of the skin flap (S, SDMA perforator flap). (C) Elevation of the vascularized second metacarpal bone pedicled by the second DMA (VB). (D) Release up to the pivot point of the dorsal branch of PDA.

not presented initially after the surgery. Our procedure could be performed under the same operating field, does not require vascular anastomosis, and achieved bone union without extensive bone resorption and infection.

To our knowledge, this is the first report regarding reconstruction using one pedicle containing two types of flaps nourished by different vascular pedicles using SDMA. When the vascular connection between the SDMA and dorsal branch of the PDA is not injured, this technique can be a useful method for reconstructing the distal part of a finger.

## Conflict of Interest

None declared.

## References

- Evans DM, Martin DL. Step-advancement island flap for fingertip reconstruction. *Br J Plast Surg* 1988;41(02):105–111
- Gurdin M, Pangman WJ. The repair of surface defects of fingers by trans-digital flaps. *Plast Reconstr Surg* (1946) 1950;5(04):368–371
- Lai CS, Lin SD, Yang CC. The reverse digital artery flap for fingertip reconstruction. *Ann Plast Surg* 1989;22(06):495–500
- Snow JW. The use of a volar flap for repair of fingertip amputations: a preliminary report. *Plast Reconstr Surg* 1967;40(02):163–168
- Lemmon JA, Janis JE, Rohrich RJ. Soft-tissue injuries of the fingertip: methods of evaluation and treatment. An algorithmic approach. *Plast Reconstr Surg* 2008;122(03):105e–117e
- Quaba AA, Davison PM. The distally-based dorsal hand flap. *Br J Plast Surg* 1990;43(01):28–39
- Gajisin S, Zbrodowski A, Grodecki J. Vascularization of the extensor apparatus of the fingers. *J Anat* 1983;137(pt 2):315–322
- Karacalar A, Ozcan M. A new approach to the reverse dorsal metacarpal artery flap. *J Hand Surg Am* 1997;22(02):307–310
- Vuppalapati G, Oberlin C, Balakrishnan G. “Distally based dorsal hand flaps”: clinical experience, cadaveric studies and an update. *Br J Plast Surg* 2004;57(07):653–667
- Yang D, Morris SF. Vascular basis of dorsal digital and metacarpal skin flaps. *J Hand Surg Am* 2001;26(01):142–146

- 11 Santa-Comba A, Amarante J, Silva A, Rodrigues J. Reverse dorsal metacarpal osteocutaneous flap. *Br J Plast Surg* 1997;50(07):555–558
- 12 Saalabian AA, Unglaub F, Horch RE, Kneser U. Free vascularized metacarpal bone graft combined with extended dorsal metacarpal artery flap for phalangeal bone and soft tissue loss: case report. *Arch Orthop Trauma Surg* 2012;132(01):137–140
- 13 Stahl S, Lotter O, Stahl AS, Schaller HE, Sinis N. Immediate reconstruction of complex hand trauma with iliac crest bone graft and 2 pedicled fasciocutaneous skin flaps: a case report. *Eplasty* 2010;10:e21
- 14 Katz TL, Hunter-Smith DJ, Matthew Rozen W. Reverse second dorsal metacarpal artery vascularized bone flap for index distal bone loss: a case report. *Microsurgery* 2016;36(03):250–253
- 15 Maruyama Y. The reverse dorsal metacarpal flap. *Br J Plast Surg* 1990;43(01):24–27
- 16 Sunagawa T, Bishop AT, Muramatsu K. Role of conventional and vascularized bone grafts in scaphoid nonunion with avascular necrosis: a canine experimental study. *J Hand Surg Am* 2000;25(05):849–859
- 17 Gosain A, Chang N, Mathes S, Hunt TK, Vasconez L. A study of the relationship between blood flow and bacterial inoculation in musculocutaneous and fasciocutaneous flaps. *Plast Reconstr Surg* 1990;86(06):1152–1162
- 18 Pelissier P, Casoli V, Bakhach J, Martin D, Baudet J. Reverse dorsal digital and metacarpal flaps: a review of 27 cases. *Plast Reconstr Surg* 1999;103(01):159–165