

# A Word of Caution for Gossypiboma

Bihter Sayan<sup>1</sup>  Esra Yamansavci Sirzai<sup>1</sup> Bedrettin Yildizeli<sup>1</sup>

<sup>1</sup>Department of Thoracic Surgery, Marmara University School of Medicine, Istanbul, Turkey

Thorac Cardiovasc Surg 2022;70:579–582.

Address for correspondence: Bihter Sayan, MD, Department of Thoracic Surgery, Marmara University School of Medicine, Fevzi Cakmak Mah. Muhsin Yazicioglu Cad. No:10 Üst Kaynarca-Pendik Istanbul, Istanbul 34662, Turkey (e-mail: sayan\_b@live.com).

## Abstract

### Keywords

- ▶ gossypiboma
- ▶ foreign body
- ▶ surgery
- ▶ complications

Gossypiboma, a retained nonabsorbable surgical sponge, is a major safety issue despite being infrequent, causing serious malpractice debates. In addition to this, it may mimic a range of different diseases within the thorax and even have unpleasant clinical presentations even after years.

In this article, we report four gossypiboma cases with nonspecific clinical presentations to emphasize the importance of keeping this diagnosis in mind with all patients who have had a previous operation.

## Introduction

“Gossypiboma” is a term used to refer to a nonabsorbable material, such as gauze sponges or swabs, accidentally left inside a patient’s body cavity during an operation.<sup>1</sup> It is a combination of two words: the Latin word “Gossypium,” meaning cotton, and the Swahili word “boma,” meaning a place of concealment.<sup>1</sup> In the literature, gossypiboma, a retained surgical gauze or sponge, may also be referred to as “textiloma.” Although gossypiboma is preventable and should never happen, its incidence is estimated to be as high as between one in 1,000 and one in 10,000 surgeries.<sup>2</sup>

Gossypiboma is a major safety violation. It is reported that it accounts for 50% of malpractice claims<sup>2</sup> and is generally associated with medicolegal consequences. Because of its nonspecific manifestation, the diagnosis of gossypiboma may easily be overlooked.<sup>3</sup> However, it may cause serious morbidities or may become symptomatic. It may mimic a hematoma, an abscess, a cyst, a loculated empyema, infectious diseases, or even malignant tumors in radiological examination. In this article, we report four retained surgical sponge cases. The first case presented mild symptoms and caused suspicion of malignancy. In the second case, a probable abscess was thought of as a differential diagnosis, while the third and fourth cases suffered from wound discharges for 15 years and 6 months, respectively.

## Case 1

A 64-year-old female was referred to the outpatient clinic with the chief complaint of hemoptysis once a week with vague chest pain for 2 years. According to the medical history received from the patient, she had had an urgent thoracotomy due to a hematoma following a thyroidectomy operation 9 years before. She was a former smoker, with a 20 pack-year history, but had ceased 9 years prior. After a chest computed tomography (CT), a 50\*31 mm mass located in the right upper lobe was noticed (▶ Fig. 1). There were no signs of calcification, mediastinal lymphadenopathy, or pleural effusion. In positron emission tomography (PET), the standard uptake value was measured at 9.5 with no other distant uptake. Her forced expiratory volume in the first second was 2.57 (%103,5). Flexible bronchoscopy was unremarkable. Wedge resection of the mass in the upper lobe was performed in a redo thoracotomy. On the back table, a 3 cm incision was made, and a gauze was seen inside the specimen. The histopathological examination reported a foreign body granulation tissue and fibrous capsule formation. Cellulose fibers were detected inside the cells. Therefore, the case was diagnosed as a gossypiboma/textiloma. Postoperative course was uneventful, and the patient was discharged on the fourth postoperative day.

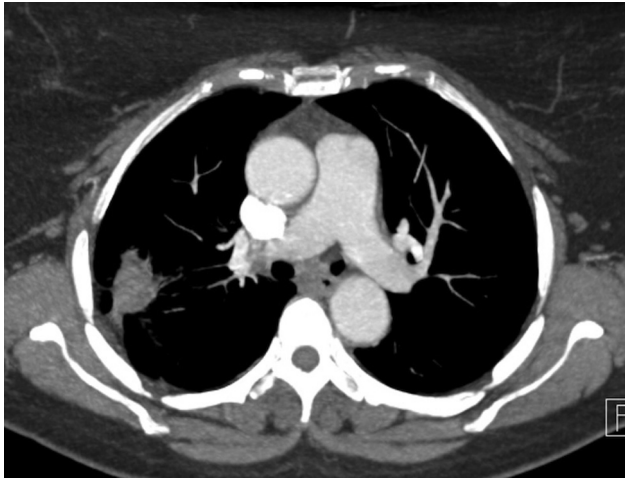
## Case 2

A 75-year-old male was referred to our outpatient clinic with dyspnea on exertion for 2 months. In chest CT, an

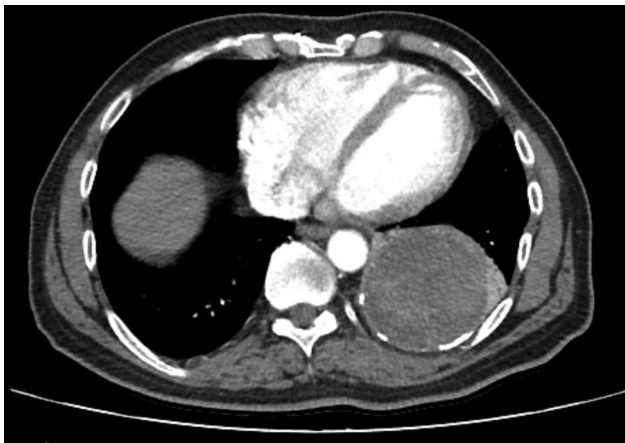
received  
March 23, 2021  
accepted  
April 26, 2021  
published online  
August 10, 2021

© 2021, Thieme. All rights reserved.  
Georg Thieme Verlag KG,  
Rüdigerstraße 14,  
70469 Stuttgart, Germany

DOI <https://doi.org/10.1055/s-0041-1731779>  
ISSN 0171-6425.



**Fig. 1** Fluorodeoxyglucose-avid right upper lobe solid mass.

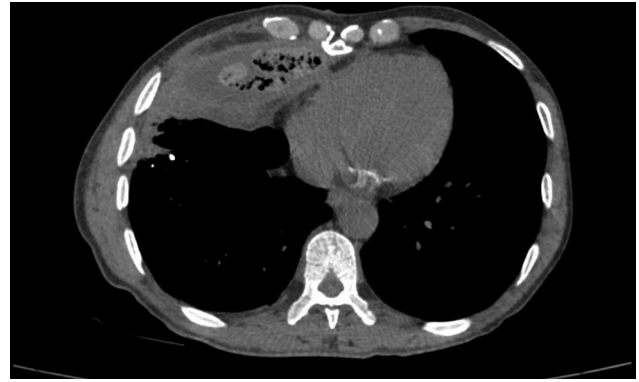

**Fig. 2** A giant, heterogenous, encapsulated, focally calcified, cystic mass was seen in the left lower lobe area.

83 × 78 × 73 mm, heterogenous, encapsulated, and partially calcified mass was observed in left lower lobe (►Fig. 2). His medical history included a coronary bypass graft 20 years ago. His pulmonary function tests were within normal range. Surgery was recommended with a preliminary diagnosis of a limited abscess with calcific margins formed after the bypass procedure. In surgery, there were dense adhesions to vertebral bodies, diaphragm, and the aorta. An extrapulmonary and extrapericardial mass was removed. Pathological examination reported hyaline fibrosis with foreign body reaction. The wall thickness was measured at 1.5 cm with some calcified areas. After an uneventful postoperative course, the patient was discharged on the fifth day.

### Case 3

A 65-year-old male consulted our clinic for purulent wound discharges from two cutaneous fistulas on the xyphoid and right lateral chest wall. The patient had suffered from continuous wound discharges for 15 years, after a mitral valve replacement surgery that had taken place at that time. Gossypiboma was the preliminary diagnosis, and a chest CT

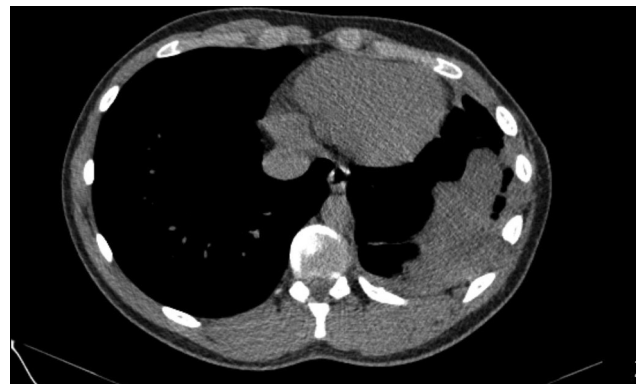

**Fig. 3** A paracardiac gossypiboma in its characteristic spongiform appearance.

was implemented to confirm (►Fig. 3). A retained gauze sponge without radiopaque lines was removed near the pericardium. Wound debridement tissues were sent for pathological examination, which reported them to be abscess formation and fibrosis. Methicillin-sensitive *Staphylococcus aureus* was isolated, and the patient received antibiotics and negative-pressure wound therapy to induce granulation. The postoperative period was otherwise uneventful, and he was discharged on the eighth day.

### Case 4

A 19-year-old male reached out to our outpatient clinic with wound discharge. Following a stab wound 6 months prior, he had had an emergency thoracotomy and a laparotomy simultaneously. The complaint was a purulent discharge from the chest drain's incision scar. The otherwise healthy patient had a diagnostic CT (►Fig. 4), which showed no visible radiopaque marking in the foreign body, but considering the patient's operation history and wound discharge, the preliminary diagnosis included gossypiboma and empyema. Surgery for sponge excision and decortication for empyema was performed and pathological examination confirmed the diagnosis. He was discharged on the fifth day after an uneventful postoperative course.



**Fig. 4** An intrathoracic heterogeneous solid mass with undulant borders.

## Discussion

The diagnosis of gossypiboma may be overlooked because of its rare occurrence and low frequency of suspicion. It is important to remember that gossypiboma can be a complication of any surgical procedure. In a review article with a total of 254 cases, the risk factors were reported as emergency procedures, lengthy procedures, unexpected changes in the procedures, cases involving more than one body cavity or surgical field, patients with a high body mass index, staffs' shift changes, staffs' inadequate communication, incomplete count of surgical gauze sponges, absence of a brief standardized sponge counting policy, and usage of nonradiopaque sponges.<sup>4</sup> The cases presented earlier are exemplary of these circumstances. In the first case, the patient had had an urgent thoracotomy for a hematoma. The second and third cases presented lengthy operations during which the medical staff's attention levels may diminish. Case 4 presented a case of emergent trauma resulting from a stab wound and involving multicavities in the procedure. All patients in this group of cases seem to comply with the risk factors described above.

Another important aspect of gossypibomas is that their symptoms' onset may take place early or significantly late, that is, after several years. In our report, there were long periods between the operation where the gossypiboma was left and its eventual removal. In our first case, there were 9 years in between these two points, including 2 years of mild hemoptysis. In our second case, the patient spent two clinically silent decades with an intrathoracic gossypiboma. The third case presented continuous wound discharge for 15 years without the patient seeking any further advice. In the fourth case, a young male complained of wound discharge for 6 months before a gossypiboma was suspected. Most of the literature on intrathoracic gossypibomas consists of case reports, where we encountered widely varying for the period between the initial procedure and retrieval. In one of the largest series, it ranged from 1 to 120 months, with a mean of 30.6 months.<sup>5</sup> One review article reported that the average time of gossypiboma discovery was 6.9 years, with 38% of the cases being discovered within the first year.<sup>4</sup> However, in one case report, authors reported that gauze sponge was hidden for 52 years without any symptoms.<sup>6</sup> The numerous examples found in the literature, and particularly the inconsistency these show in relation to the symptoms presented and their onset, provide evidence that there is no single clinical pattern for gossypibomas. For this reason, regardless of the number of years passed, a patient's history of surgical procedure should, on its own, be enough for a doctor to include gossypibomas in the list of differential diagnoses.

In addition to the symptoms' onset likelihood of being postponed for several years, clinical presentation and patients' reason for admission may be unclear. Clinical presentation of intrathoracic gossypiboma is vague, as patients with this condition may present with fever, cough, hemoptysis, weight loss, dyspnea, shoulder pain, wound discharge, or, even, they may be entirely asymptomatic. A

further complication lies in the fact that these signs are frequently attributed to a range of lung diseases. In these series, the first patient's main complaint was hemoptysis, which could be seen as the clinical presentation of a lung tumor. Added the opacity's fluorodeoxyglucose (FDG) avidity, it would be natural to include primary lung malignancies in differential diagnoses. It is also reported that gossypibomas may show low, moderate, or high affinity to FDG in PET.<sup>7,8</sup> Our first case showed moderate amount of FDG affinity, contributing to the uncertainty of the diagnosis and suggesting neoplasm.

On the other hand, this patient's refusal to a new operation for 2 years highlighted the fact that, over this period, the radiological opacity (→ **Fig. 1**) did not present any progress in size, pointing to the probability of a benign disease. This, along with the history of her previous urgent thoracotomy, led us to the presumptive diagnosis of gossypiboma, later confirmed by the back table examination. The second case's radiological image displayed the characteristics of a cyst with a smooth circular shape as well as dense structures inside the lesion, which could suggest the presence of an abscess when considering the lesion's calcific borders. Due to the proximity to the pulmonary arteries, the possibility of an aneurysm should be considered, but the lesion's lack of any contrast medium inside makes this diagnosis highly unlikely. Low incidence, low rate of suspicion, and nonspecific findings on chest CT could be the main causes of unnoticed or undiagnosed thoracic gossypibomas.<sup>9</sup> In late recognition, it may mimic hematoma,<sup>10</sup> abscess, aspergilloma,<sup>11,12</sup> echinococcal cyst,<sup>13,14</sup> loculated empyema, bronchiectasis,<sup>15</sup> granulomatous diseases, or even malignancies.<sup>9</sup>

Even though chest CT does not provide a precise and reliable diagnosis of intrathoracic gossypiboma, it remains the most effective tool when trying to identify it. It would be likely to find the spongiform appearance characteristic of gossypiboma/textiloma (→ **Fig. 3**). However, thoracic textilomas may lose their spongiform appearance, as air bubbles could disappear due to the pleura's absorption capacity.<sup>16</sup> This also means that the radiological image may simply show a nonspecific solid mass. As a matter of fact, three of the cases presented here lost the air entrapment inside the foreign gauze (→ **Figs. 1, 2, and 4**). This could be the reason why, in literature, the main consensus regarding radiological findings is their heterogeneity. Even with modern investigational tools, it remains difficult to accurately diagnose all gossypibomas. Nevertheless, they should be included in the differential diagnosis of all atypical chest lesions in any patient who has had an operative procedure previously. In the reviewed reports, however, physicians included gossypiboma as a differential diagnosis in only 39% of the cases.<sup>4</sup>

Gossypiboma is undoubtedly a major safety violation and can cause considerable medicolegal problems. At the same time, it is a preventable complication. Rules exist requiring the exclusive usage of sponges with radiopaque markers. Although it is known that the radiopaque marked sponges were widely used in our country for many years, in all four of the patients, who had their previous surgeries in other hospitals, the retained gauze sponges had no radiopaque

marker, further diminishing the probability of finding accurate preoperative diagnosis as a consequence. Over and above, there should be strict, clear, and standardized policies to count the sponges. If the counting does not match, Raytec sponges can easily be recognized with C-armed scopes, and immediately be removed. Thus, the patients would not suffer from further complications, additional costs, and possible morbidities of redo surgeries. What is more, the surgery team would avoid the burden of medicolegal consequences.

## Conclusion

Patients suffering from retained surgical sponges may have serious complications in the early postoperative period, or these may remain silent in the body cavity for many years without any symptoms. Undoubtedly, there is major safety violation in both situations. It must be noted that they may cause serious medicolegal consequences. These case series emphasize that intrathoracic gossypiboma can cause non-specific symptoms and may emerge even after 20 years. Despite its rarity, clinicians must include gossypiboma in differential diagnoses for patients who had a previous surgery. Lastly, we recommend using the radiopaque gauzes routinely, along with the careful counting of the gauzes before finishing each operation. Albeit surgery itself is diagnostic and curative, prevention is always easier and better.

### Conflict of Interest

None.

## References

- Hameed A, Naeem A, Azhar M, Fatimi SH. Intrathoracic gossypiboma. *BMJ Case Rep* 2014;2014:bcr2013201814
- Manzella A, Filho PB, Albuquerque E, Farias F, Kaercher J. Imaging of gossypibomas: pictorial review. *AJR Am J Roentgenol* 2009;193(06):S94–S101
- Marchiori E, Nobre LF, Zanetti G. Textiloma: a forgotten diagnosis. *Rev Port Pneumol* (2006) 2016;22(06):366–367
- Wan W, Le T, Riskin L, Macario A. Improving safety in the operating room: a systematic literature review of retained surgical sponges. *Curr Opin Anaesthesiol* 2009;22(02):207–214
- Machado DM, Zanetti G, Araujo Neto CA, et al. Thoracic textilomas: CT findings. *J Bras Pneumol* 2014;40(05):535–542
- Parra M, Oppliger F, Berríos R, Schiappacasse G. Intrathoracic gossypiboma presenting 52 years later as a chest mass. *Asian Cardiovasc Thorac Ann* 2015;23(05):596–598
- Dubois RL, Raisig E, Stanifer BP. Gossypiboma mimicking FDG-avid lung nodule. *Ann Thorac Surg* 2020;109(06):e403–e405
- Petermann D, Christodoulou M, Letovanec I, et al. Textiloma on 18F-fluorodeoxyglucose positron emission tomography/computed tomography: a wolf in a sheep's clothing? *J Thorac Oncol* 2010;5(02):280–281
- Nemati MH. Mediastinal gossypiboma simulating a malignant tumour. *Interact Cardiovasc Thorac Surg* 2012;15(04):783–785
- Nobre LF, Marchiori E, May F, Carrão AD Jr, Zanetti G, Machado DM. Thoracic textilomas after myocardial revascularisation: typical CT findings. *Br J Radiol* 2010;83(985):4–7
- Rijken MJ, van Overbeeke AJ, Staaks G. Gossypiboma in a man with persistent cough. *Thorax* 2005;60(08):708. Doi: 10.1136/thx.2004.035659
- Park HJ, Im SA, Chun HJ, Park SH, O JH, Lee KY. Changes in CT appearance of intrathoracic gossypiboma over 10 years. *Br J Radiol* 2008;81(962):e61–e63
- Patel AM, Trastek VF, Coles DT. Gossypibomas mimicking echinococcal cyst disease of the lung. *Chest* 1994;105(01):284–285
- Solaini L, Prusciano F, Bagioni P. Intrathoracic gossypiboma: a movable body within a pseudocystic mass. *Eur J Cardiothorac Surg* 2003;24(02):300. Doi: 10.1016/S1010-7940(03)00248-3
- Suwatanapongched T, Boonkasem S, Sathianpitayakul E, Leela-chaikul P. Intrathoracic gossypiboma: radiographic and CT findings. *Br J Radiol* 2005;78(933):851–853
- Ridene I, Hantous-Zannad S, Zidi A, et al. Imaging of thoracic textiloma. *Eur J Cardiothorac Surg* 2011;39(03):e22–e26