Article published online: 2021-06-14

Percutaneous Transhepatic Biopsy for Extrahepatic Lesions

Yasuyuki Onishi[1] Yasuaki Arai[1] Miyuki Sone[1] Shunsuke Sugawara[1] Chihiro Itou[1] Shintaro Kimura[1]

[1]Department of Diagnostic Radiology, National Cancer Center Hospital, Chuo-ku, Tokyo, Japan

Address for correspondence Yasuyuki Onishi, MD, Department of Diagnostic Radiology, National Cancer Center Hospital, 5-1-1 Tsukiji, Chuo-ku, Tokyo 104-0045, Japan (e-mail: goforawalktoday@yahoo.co.jp).

Arab J Intervent Radiol 2021;5:41–44.

Abstract

Purpose The purpose was to assess the diagnostic accuracy and safety of percutaneous transhepatic biopsy for extrahepatic lesions.

Materials and Methods Between January 2008 and December 2019, 26 patients (17 men and 9 women; median age, 60 years) underwent percutaneous transhepatic needle biopsy for extrahepatic lesions at our institution. Transhepatic biopsy was deemed appropriate compared with other biopsy routes or methods (i.e., endoscopic or surgical). The lesions were in the porta hepatis (*n* = 9), retroperitoneum (*n* = 6), right adrenal gland (*n* = 4), right kidney (*n* = 3), lesser omentum (*n* = 2), duodenum (*n* = 1), pleura (*n* = 1), and inferior vena cava (*n* = 1). The median maximal diameter of the lesions was 45.5 mm (range, 18–148 mm). Core-needle biopsy was performed in all patients. Eighteen-gauge and 21-G needles were used in 25 and one patient, respectively. Ultrasound was used for biopsy in 21 patients, and CT fluoroscopy was used in five patients. Postbiopsy tract embolization was performed in three patients. Technical success and diagnostic accuracy of the biopsy were evaluated. Complications were recorded using the systemic inflammation response (SIR) criteria.

Results The pathological results of biopsy were carcinoma (*n* = 10), lymphoma (*n* = 9), and other diagnoses (*n* = 7). Technical success was obtained in all patients. The accurate diagnosis was achieved in 24 of the 26 patients (92.3%). A major complication, a bladder tamponade, was observed in one patient (3.8%) after biopsy of a right kidney lesion. A hematoma caused by iatrogenic renal injury likely obstructed the bladder outlet. Minor complications were observed in three patients (11.5%).

Conclusions Percutaneous transhepatic biopsy for extrahepatic lesions is feasible with acceptable safety.

Keywords
- nonvascular intervention
- percutaneous needle biopsy
- transhepatic biopsy

Introduction

Image-guided percutaneous needle biopsy is accepted as a minimally invasive diagnostic procedure.[1,2] In the abdomen, however, it can be technically challenging to perform a biopsy without injuring other organs surrounding the target lesion.[3-5] To overcome such difficulty, many techniques have been reported, such as the administration of contrast material, the change of patient positioning, tilting of CT gantry on CT-guided biopsy, breath-hold, and hydrodissection.[3,4] An alternative approach for a difficult biopsy is accessed through organs such as the stomach, liver, and pleura.[3-5] The liver occupies a large volume in the right upper abdomen and can

published online
June 14, 2021

DOI https://doi.org/10.1055/s-0041-1731127
ISSN 2542-7075

be regarded as a useful access route for abdominal lesions. Only a few studies with a small number of patients have evaluated the feasibility and safety of percutaneous transhepatic biopsy for extrahepatic lesions.[6,7] The usefulness of the transhepatic approach has been evaluated in other procedures, namely, abdominal abscess drainage and radiofrequency ablation for renal or adrenal tumors.[8-12] However, a biopsy differs from drainage and ablation in terms of device and duration; in a biopsy, the needle is placed just long enough in the liver to get a specimen, whereas in drainage, the catheter is left in place for days. Therefore, the procedural complications also differ. Thus, studies focusing on transhepatic biopsy should be conducted. The purpose of this study was to evaluate the diagnostic accuracy and safety of percutaneous transhepatic biopsy for extrahepatic lesions.

Materials and Methods

Patients and Lesions

This retrospective study was approved by our institutional review board. Between January 2008 and December 2019, 6,288 percutaneous biopsy procedures were performed at our department. Among them, 26 percutaneous transhepatic biopsy procedures were performed on 26 patients. Patients with a target lesion which had deeply invaded the liver or was located in the gallbladder or bile duct were not included. The appropriate route and biopsy method were discussed by interventional radiologists in a conference held 1 day before the procedure. They concluded that for all patients, a transhepatic core needle biopsy was appropriate, compared with other biopsy routes or methods (i.e., endoscopic or surgical). The 26 patients consisted of 17 men and nine women with a median age of 60 years (range, 32–87 years). Written informed consent was obtained from all patients before the procedure. Before biopsy, prothrombin time-international normalized ratio (PT-INR) ≤1.6 and platelet count >50,000/μL were confirmed in all patients. When patients used antithrombotic drugs, the biopsy was performed after the drug was suspended for an appropriate period, based on the systemic inflammation response (SIR) guideline.[13] CT was performed in all patients before biopsy. The location of the target lesions is shown in ►**Table 1**. The porta hepatis and retroperitoneum are the two most common locations of the target lesion. In 25 patients, the target lesions were located in the abdomen, whereas in one patient, the target lesion was located in the pleura. Three patients had target lesions similarly located in the anterior part of the right kidney, necessitating traversal of the renal or liver parenchyma for biopsy. We selected the transhepatic approach because renal biopsy is considered to have a higher risk of bleeding than liver biopsy.[2] The pleural lesion was abutting the diaphragm and far from the intercostal space. In this patient, we chose the transhepatic approach over the transpulmonary approach, because it was suspected that pneumothorax, a common complication of transpulmonary biopsy, can lead to migration of the pleural nodule.

Table 1 Location of the target lesions

Location	Value (%)
Porta hepatis	8 (30.8)
Retroperitoneum	6 (23.1)
Right adrenal gland	4 (15.4)
Right kidney	3 (11.5)
Lesser omentum	2 (7.7)
Duodenum	1 (3.8)
Pleura	1 (3.8)
Inferior vena cava	1 (3.8)

Biopsy Procedures

Biopsy procedures were performed on an angio-CT system (INFX-8000C/Aquilion 16: Canon Medical Systems, Ohtawara, Japan), with the patients in the supine or supine oblique position. Conscious sedation and local anesthesia were used. The puncture route was carefully selected, based on the location of the target lesion. Extreme care was taken not to puncture the liver hilum or large blood vessels or bile ducts. The biopsy was performed using ultrasound in 21 patients (►**Fig. 1**), and in five among them, CT was used to confirm the position of the needle during the procedure. In the remaining five patients, biopsy was performed using CT fluoroscopy (►**Fig. 2**). In three among all patients, X-ray fluoroscopy was also used. In all patients, the coaxial technique with a guide needle or vascular sheath was used to decrease the risk of hemorrhage and needle tract dissemination. A metallic guide needle and a vascular sheath were used in 24 and 2 patients, respectively. To obtain the biopsy sample, 18-G cutting needles (MISSION, MAGNUM; BARD, Murray Hill, NJ, USA; or Temno Evolution, Achieve; Merit Medical Systems, South Jordan, UT, USA) were used in 25 patients, and 21-G core biopsy needle (Sonopsy; Hakko, Nagano, Japan) was used in one patient. The mean number of needle passes was 2.7 (range, 1–5). After the

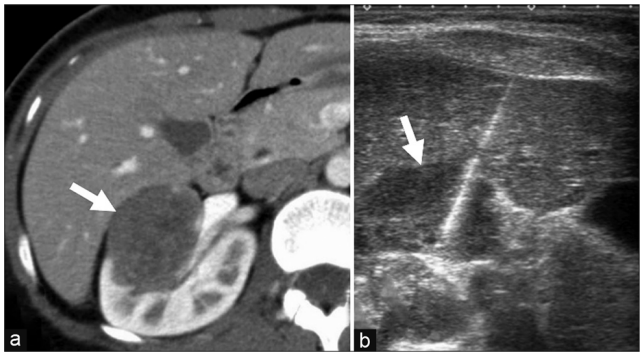

Fig. 1 Ultrasound-guided transhepatic biopsy for a right renal mass in a 32-year-old woman. (**a**) Contrast-enhanced computed tomography image shows a right renal mass (arrow). (**b**) Ultrasound image acquired from the right intercostal space during transhepatic biopsy shows a biopsy needle advanced into a hypoechoic mass (arrow). Pathological diagnosis was lymphoma.

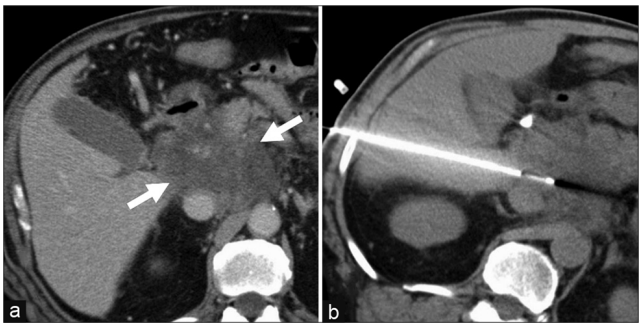

Fig. 2 CT-guided transhepatic biopsy for a retroperitoneal mass in a 64-year-old man. (**a**) Contrast-enhanced CT image shows a retroperitoneal mass (arrows) anterior to the inferior vena cava. (**b**) CT fluoroscopy image during transhepatic biopsy shows an 18-G needle advanced from the tip of the guide needle. Pathological diagnosis was lymphoma.

biopsy, if no blood came out of the guide needle, the needle was withdrawn. When blood came out, an autologous blood clot was pushed into the guide needle for hemostasis. In 23 patients, the guide needle was withdrawn with or without autologous blood clot. In three patients, hemostasis was not achieved with autologous blood clot, and tract embolization was performed using different embolic agents: coils in one patient, gelatin sponge in another, and n-butyl cyanoacrylate (Histoacryl; B. Braun, Melsungen, Germany) in the last.

Evaluation of Procedure

Technical success was defined as successful needle advancement within the target lesion. When surgical resection of the target lesion was performed after needle biopsy, the pathological diagnosis of the resected lesion was used as the final diagnosis. The result of percutaneous needle biopsy was compared with the final diagnosis to test the accuracy of the biopsy. When the pathological diagnosis was not available, clinical and imaging findings, such as patient symptoms and temporal change of the lesion, were evaluated. If clinical and imaging findings were compatible with the diagnosis of percutaneous needle biopsy, the result of percutaneous needle biopsy was considered accurate.

Complications were determined by reviewing interventional radiology records, medical records, and findings of postbiopsy images. Complications were classified into minor and major based on the SIR guideline.[13]

Results

Technical success was obtained in all patients. ►**Table 2** shows the pathological results from the percutaneous transhepatic biopsy. Surgical resection of the target lesion was performed in one patient, leading to the pathological diagnosis of gastrointestinal stromal tumor, which was consistent with the result of the percutaneous transhepatic biopsy. In 23 patients of the remaining 25 patients, the result of the transhepatic biopsy was compatible with clinical and imaging findings. The result of the transhepatic biopsy was inconsistent with the clinical and imaging findings in two patients. One patient received a biopsy of a pleural lesion, which showed normal liver tissue. However, the clinical diagnosis was pleural dissemination of lung carcinoma, based on follow-up imaging findings. The other patient received a biopsy of a retroperitoneal tumor, which showed benign mesenchymal tissue. However, imaging findings strongly suggested that the lesion was a fat-containing tumor, such as well-differentiated liposarcoma. The patient is currently followed with CT studies at an outside hospital. Thus, the diagnostic accuracy of the biopsy procedure was 24/26 (92.3%).

Table 2 Pathological diagnosis of percutaneous transhepatic biopsy

Diagnosis	Value (%)
Carcinoma	10 (38.5)
Lymphoma	9 (34.6)
Benign mesenchymal tissue	1 (3.8)
Chondrosarcoma	1 (3.8)
Ganglioneuroma	1 (3.8)
Gastrointestinal stromal tumor	1 (3.8)
Leiomyosarcoma	1 (3.8)
Normal liver tissue	1 (3.8)
Reactive lymph node	1 (3.8)

Complications were observed in four patients (15.4%). One of the complications was major and three were minor. Bladder tamponade was observed in one patient after biopsy of a right kidney lesion. It was suspected that a hematoma in the urinary tract, caused by iatrogenic renal injury, obstructed the bladder outlet. Cystoscopic bladder irrigation was performed, and no additional treatment was needed. This was regarded as a major complication (Class C). The following three cases were regarded as minor complications (Class A). Dyspnea was observed in a patient who had biopsy of a pleural lesion, and the symptom improved spontaneously. Imaging study did not show any additional complications such as pneumothorax or hemothorax. Hypotension was observed in a patient who had biopsy of an inferior vena cava lesion, and the symptom resolved spontaneously. Imaging study did not show any complications including hematoma. Intraperitoneal hemorrhage was observed on CT during the procedure in a patient with the target lesion at the porta hepatis. The patient was asymptomatic and successfully managed conservatively. CT scans were performed in 21 patients for follow-up of lesions, and the median period of follow-up was 326 days (range, 43–3,947 days). These postbiopsy images were reviewed to evaluate needle tract dissemination, and no dissemination was observed.

Discussion

In the study period, 6,288 percutaneous biopsy procedures were performed. Among them, only 26 (0.41%) were performed using the transhepatic approach, indicating it was only performed on carefully selected patients.

The present study showed that the diagnostic accuracy of percutaneous transhepatic biopsy for extrahepatic lesions was 92.3%. The diagnostic accuracy of percutaneous

needle biopsy in general was reported to range from 70% to 96% and considered to be equivalent to that of transhepatic biopsy.[1] In this study, ten of the 26 patients underwent biopsies for lesions of the porta hepatis or the lesser omentum. Laparoscopic biopsy and endoscopic ultrasound-guided biopsy can also be performed for lesions at these locations, but these methods have disadvantages. Laparoscopic biopsy requires general anesthesia and is an invasive procedure. Fine-needle aspiration (FNA) is often used in an endoscopic ultrasound-guided biopsy. However, core-needle biopsy is more suitable than FNA for the diagnosis of lymphoma, which frequently develops in these locations.[14] Thus, percutaneous transhepatic biopsy is a useful technique in the diagnosis of lesions at the porta hepatis and lesser omentum. Seven of the 26 patients underwent biopsy for lesions of the right adrenal gland or right kidney. The usefulness of transhepatic biopsy for lesions in these areas was reported in a previous study and is consistent with our results.[7]

In the present study, the major complication rate was 3.8% and the minor complication rate was 11.5%. The major complication rate of percutaneous liver biopsy was reported to range from 1 to 3% and considered to be equivalent to that of the transhepatic biopsy.[15] In a previous study evaluating transhepatic biopsy of right renal and adrenal masses, no major complication and one minor complication (10%) were reported in 10 patients.[7] Both the present study and previous research have shown that transhepatic biopsy for extrahepatic lesions is a safe procedure. Needle tract dissemination, although not evaluated in all patients, was not observed. Coaxial technique was used in this study, which might be useful in decreasing the rate of hemorrhage and needle tract dissemination.[16,17]

A percutaneous biopsy not using a transhepatic approach for lesions of the right adrenal gland, right kidney, or retroperitoneum usually requires the patient to lie prone, which is sometimes painful and difficult to maintain. An advantage of the transhepatic approach is that it allows the patient to lie supine during the procedure, which is more comfortable for the patient.[9]

This study has some limitations. The first is that the number of patients is small. The second is that, in all but one patient, we did not receive final pathology from a surgical resection sample. The third is that all biopsy procedures were performed with angio-CT system where X-ray fluoroscopy, CT fluoroscopy, CT scanning, and ultrasound were freely used. Hence, it is uncertain whether the results can be reproduced without angio-CT system.

Conclusions

Percutaneous transhepatic biopsy for extrahepatic lesions enables us to make pathological diagnosis with an acceptable rate of complications. It is important to consider the transhepatic approach in difficult cases.

Financial Support and Sponsorship

Nil.

Conflicts of Interest

There are no conflicts of interest.

References

1 Gupta S, Wallace MJ, Cardella JF, Kundu S, Miller DL, Rose SC; Society of Interventional Radiology Standards of Practice Committee. Quality improvement guidelines for percutaneous needle biopsy. J Vasc Interv Radiol 2010;21(7):969–975

2 Veltri A, Bargellini I, Giorgi L, Almeida PAMS, Akhan O. CIRSE guidelines on percutaneous needle biopsy (PNB) Cardiovasc Intervent Radiol 2017;40(10):1501–1513

3 McDermott S, Levis DA, Arellano RS. Approaches to the difficult drainage and biopsy. Semin Intervent Radiol 2012;29(4):256–263

4 Sainani NI, Arellano RS, Shyn PB, Gervais DA, Mueller PR, Silverman SG. The challenging image-guided abdominal mass biopsy: established and emerging techniques 'if you can see it, you can biopsy it' Abdom Imaging 2013;38(4):672–696

5 Arellano RS, Maher M, Gervais DA, Hahn PF, Mueller PR. The difficult biopsy: let's make it easier. Curr Probl Diagn Radiol 2003;32(5):218–226

6 Price RB, Bernardino ME, Berkman WA, Sones PJ Jr, Torres WE. Biopsy of the right adrenal gland by the transhepatic approach. Radiology 1983;148(2):566

7 Park SY, Park BK, Kim CK. Sonographically guided transhepatic core biopsies of right renal and adrenal masses: safety and short-term follow-up. J Ultrasound Med 2013;32(11):2013–2021

8 Yamakado K, Takaki H, Nakatsuka A, et al. Percutaneous transhepatic drainage of inaccessible abdominal abscesses following abdominal surgery under real-time CT-fluoroscopic guidance. Cardiovasc Intervent Radiol 2010;33(1):161–163

9 Hegg RM, Schmit GD, Kurup AN, Weisbrod AJ, Boorjian SA, Atwell TD. Ultrasound-guided transhepatic radiofrequency ablation of renal tumors: a safe and effective approach. Cardiovasc Intervent Radiol 2014;37(2):508–512

10 Kuehl H, Stattaus J, Forsting M, Antoch G. Transhepatic CT-guided radiofrequency ablation of adrenal metastases from hepatocellular carcinoma. Cardiovasc Intervent Radiol 2008;31(6):1210–1214

11 Zhao N, Li Q, Cui J, Yang Z, Peng T. CT-guided special approaches of drainage for intraabdominal and pelvic abscesses: One single center's experience and review of literature. Medicine (Baltimore) 2018;97(42):e12905

12 Ciftci TT, Akinci D, Akhan O. Percutaneous transhepatic drainage of inaccessible postoperative abdominal abscesses. AJR Am J Roentgenol 2012;198(2):477–481

13 Khalilzadeh O, Baerlocher MO, Shyn PB, et al. Proposal of a new adverse event classification by the society of interventional radiology standards of practice committee. J Vasc Interv Radiol 2017;28(10):1432–1437.e3

14 Rana A, Rana SS. Endoscopic ultrasound-guided tissue acquisition: techniques and challenges. J Cytol 2019;36(1):1–7

15 Bravo AA, Sheth SG, Chopra S. Liver biopsy. N Engl J Med 2001;344(7):495–500

16 Amaral JG, Schwartz J, Chait P, et al. Sonographically guided percutaneous liver biopsy in infants: a retrospective review. AJR Am J Roentgenol 2006;187(6):W644–9

17 Maturen KE, Nghiem HV, Marrero JA, et al. Lack of tumor seeding of hepatocellular carcinoma after percutaneous needle biopsy using coaxial cutting needle technique. AJR Am J Roentgenol 2006;187(5):1184–1187

