Article published online: 2021-07-02

Alagille Syndrome: A Focused Review on Clinical Features, Genetics, and Treatment

Taisa J. Kohut, MD[1] Melissa A. Gilbert, PhD[2] Kathleen M. Loomes, MD[1,3]

[1] Division of Gastroenterology, Hepatology, and Nutrition, Children's Hospital of Philadelphia, Philadelphia, Pennsylvania
[2] Division of Genomic Diagnostics, Department of Pathology and Laboratory Medicine, Children's Hospital of Philadelphia, Philadelphia, Pennsylvania
[3] Department of Pediatrics, Perelman School of Medicine, University of Pennsylvania, Philadelphia, Pennsylvania

Address for correspondence Kathleen M. Loomes, MD, 3401 Civic Center Boulevard, Philadelphia, PA, 19104 (e-mail: loomes@email.chop.edu).

Semin Liver Dis 2021;41:525–537.

Abstract

Alagille syndrome (ALGS) is an autosomal dominant disorder caused by pathogenic variants in *JAG1* or *NOTCH2*, which encode fundamental components of the Notch signaling pathway. Clinical features span multiple organ systems including hepatic, cardiac, vascular, renal, skeletal, craniofacial, and ocular, and occur with variable phenotypic penetrance. Genotype–phenotype correlation studies have not yet shown associations between mutation type and clinical manifestations or severity, and it has been hypothesized that modifier genes may modulate the effects of *JAG1* and *NOTCH2* pathogenic variants. Medical management is supportive, focusing on clinical manifestations of disease, with liver transplant indicated for severe pruritus, liver synthetic dysfunction, portal hypertension, bone fractures, and/or growth failure. New therapeutic approaches are under investigation, including ileal bile acid transporter (IBAT) inhibitors and other approaches that may involve targeted interventions to augment the Notch signaling pathway in involved tissues.

Keywords
- *JAG1*
- *NOTCH2*
- cholestasis
- liver transplant

Alagille syndrome (ALGS) is a multisystem autosomal dominant disorder with highly variable expression that was first described in 1969 by Alagille et al.[1] ALGS was initially called arteriohepatic dysplasia due to having the identifiable features of congenital hypoplasia and stenosis of the pulmonary arteries, neonatal cholestatic liver disease, and various other congenital anomalies, including characteristic facies.[2,3] Since its initial description, additional disease features have emerged, including vertebral, cardiac, vascular, renal, and ocular phenotypes.

The reported incidence rates of ALGS are 1:70,000 to 100,000 live births but with the advent of molecular diagnosis, the true incidence is probably closer to 1 in 30,000.[4] Mutations in *JAGGED1* (*JAG1*), a gene encoding a ligand in the Notch signaling pathway, were first identified in 1997. It is estimated that nearly 95% of individuals with ALGS have a pathogenic variant in *JAG1*.[5–7] More recently, a smaller subset of patients with ALGS have been found to have a variant in *NOTCH2* (~2.5%) which encodes a Notch signaling receptor.[7–10] JAG1 and NOTCH2 are both transmembrane proteins, and their direct interaction results in the cleavage and nuclear translocation of an intracellular region of NOTCH2 which then interacts with transcription factors to influence gene expression. As the number of identified variants in *JAG1* has increased over the years (now amounting to over 600 published variants), it has been well established that loss-of-function variants are the most frequent variant type, and a disease pathomechanism of haploinsufficiency has been proposed.[6,10–12] Despite our strong understanding of disease-causing variants for ALGS, it is not understood why different phenotypic characteristics and severity occur, even among family members who have the same pathogenic variants.[9,10,12,13] One hypothesis has been that a second genetic change may exist outside of *JAG1* and

published online
July 2, 2021

© 2021. Thieme. All rights reserved.
Thieme Medical Publishers, Inc., 333 Seventh Avenue, 18th Floor, New York, NY 10001, USA

DOI https://doi.org/10.1055/s-0041-1730951.
ISSN 0272-8087.

This document was downloaded for personal use only. Unauthorized distribution is strictly prohibited.

NOTCH2 that modifies the disease phenotype, and this remains an active area of research.[14–17]

In this review, we will provide a comprehensive background of the clinical features of ALGS, followed by an overview on the genetics of this disease. We will conclude with an in-depth discussion on treatments for ALGS, both those that are currently available and active areas of research. Current treatment for ALGS is focused on alleviation of clinical symptoms while ongoing and future research include the development of therapeutics that directly affect *JAG1* and *NOTCH2* gene expression and protein interaction.

Clinical Features

There is a wide spectrum of clinical variability in ALGS ranging from life-threatening liver or cardiac disease to only subclinical manifestations. Such highly variable expressivity is seen even among individuals from the same family with the same pathogenic variant. Those with severe liver or cardiac manifestations are most often diagnosed with ALGS in infancy versus those with subclinical or mild hepatic involvement who may not have an established diagnosis until later in life, even as adults. In a study of 53 *JAG1* mutation-positive relatives of 34 ALGS probands, only 21% of mutation-positive relatives had clinical features that would have led to a diagnosis of ALGS.[4] The frequency of cardiac and liver disease was notably lower in the relatives than in the probands. The clinical feature with the highest penetrance was the characteristic facies of ALGS, occurring almost universally in mutation-positive probands and relatives.[4] ►**Table 1** summarizes the clinical features and overall frequency associated with ALGS.[11,18,19]

Hepatic

Liver disease typically presents in the neonatal period with direct hyperbilirubinemia, and varies in severity. Mild liver disease often improves during early childhood, and progressive liver disease does not develop outside of early childhood.[18,20] Reports indicate cholestasis varying from mild to severe in 89% of patients, making it one of the most common phenotypes seen in ALGS.[19]

It is difficult to predict who will improve versus progress, but in children under 5 years of age, total bilirubin > 6.5 mg/dL, conjugated bilirubin > 4.5 mg/dL, and cholesterol > 520 mg/dL are predictors of sustained and more severe liver disease.[21] A recent large, multicenter natural history study of cholestasis in ALGS demonstrated a previously underappreciated burden of liver disease.[22] This study found early profound cholestasis, progression of portal hypertension later in childhood, and < 25% of patients reaching young adulthood with their native liver.[22] Chronic cholestasis is associated with many complications with some of the most bothersome being pruritus and xanthomas. Pruritus develops early, is associated with serum bile salt level elevation occurring independently of bilirubin level, and can often become the most debilitating symptom of ALGS. However, pruritus is not always associated with an

Table 1 Multisystem involvement, clinical features, and frequency in Alagille syndrome, based on reports by references[18–20]

Involved system	Clinical features	Overall frequency[a] (%)
Hepatic	• Bile duct paucity • Conjugated hyperbilirubinemia • Chronic cholestasis Pruritus, xanthomas, and/or fat-soluble vitamin deficiencies • End-stage liver disease	Up to 100
Cardiac	• Structural abnormalities, most common: Pulmonary artery stenosis/hypoplasia The Tetralogy of Fallot	90–97[b]
Skeletal	• Vertebral anomalies Hemivertebra Butterfly vertebra	33–93
Facial	• Prominent forehead • Deep-set eyes with moderate hypertelorism • Pointed chin • Saddle or straight nose with bulbous tip	20–97
Ocular	• Posterior embryotoxon	78–89
Vascular	• Intracranial bleeds, including: Epidural, subdural, subarachnoid, and intraparenchymal • Systemic vascular anomalies, including: Aorta, renal, celiac, superior mesenteric, and subclavian arteries • Other: Moyamoya syndrome	15–30
Renal	• Renal abnormalities, most common: Renal dysplasia Renal tubular acidosis • Ureteropelvic obstruction	39

[a]Percentages based on probands either with documented *JAG1* or *NOTCH2* variants or meeting clinical criteria for Alagille syndrome.
[b]Includes those with cardiac murmur only.

 © 2021. Thieme. All rights reserved.

This document was downloaded for personal use only. Unauthorized distribution is strictly prohibited.

elevated bile salt level. Impaired bile secretion is also associated with reduced secretion of cholesterol and can lead to significantly elevated cholesterol levels often resulting in the formation of xanthomas which are skin lesions that typically develop early on and resolve as cholestasis improves.[23]

Histopathology

The most consistently reported feature of ALGS syndrome is bile duct paucity (►**Fig. 1A**) which is defined as having a bile duct to portal tract ratio < 0.5 (compared with normal ratio ranges from 0.9 to 1.8).[24] Bile duct paucity may not be detectable prior to 6 months of age (►**Fig. 1B**), with one ALGS study showing bile duct paucity in 60 versus 95% of liver biopsies completed prior to 6 months compared with after 6 months of age, respectively.[18] The progression of bile duct paucity over the first months of life could be related to continued bile duct development postnatally, or alternatively to an inability of compromised bile ducts to keep up with rapid hepatic growth that occurs after birth, but the exact mechanisms are unknown. Additional insights have been provided from animal studies. Mouse models have shown that *JAG1* expression in hepatoblasts is dispensable for bile duct development, while conditional deletion of *Jag1* in the portal vein mesenchyme results in failure of ductal plate remodeling into tubular structures in early mouse liver development.[25,26] These results indicate that *JAG1* expression in specific cell types and at specific times during development is necessary to activate the Notch signaling for normal biliary tract remodeling.

In addition to undetectable bile duct paucity prior to 6 months of age, other histologic features, including ductular proliferation and giant cell hepatitis, can be present in infancy, further complicating the diagnosis with biliary atresia. ALGS patients who undergo Kasai's hepatoportoenterostomy have no added benefit after surgery and rather may have worsened outcomes (early transplantation or mortality); therefore, the Kasai procedure should be avoided for patients with ALGS.[18,27] In circumstances in which a liver

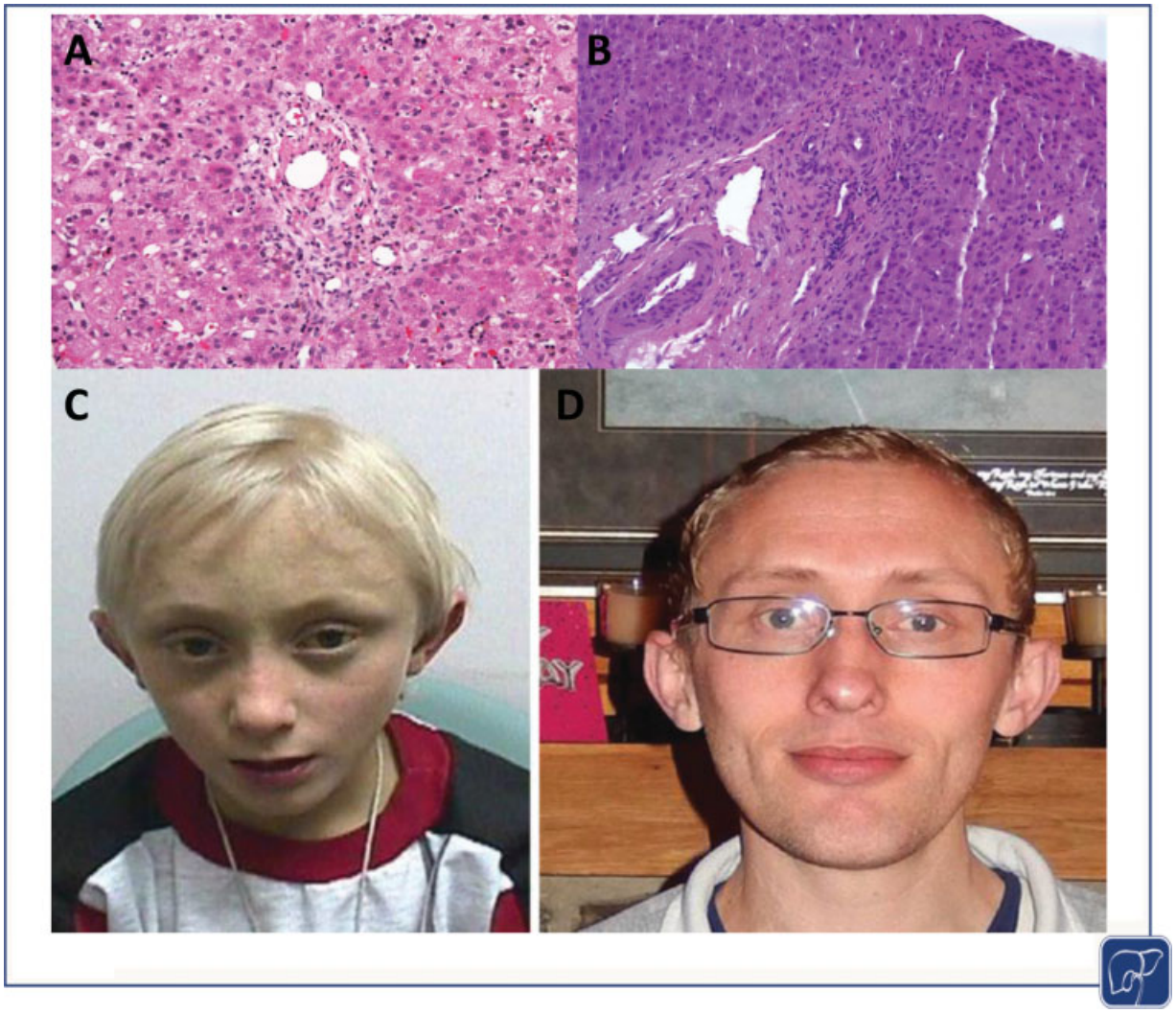

Fig. 1 Variability in the clinical features of Alagille syndrome (ALGS). (**A**) Hematoxylin & eosin staining of a liver biopsy from a 7-week-old infant with ALGS shows a portal tract with a branch of the portal vein and hepatic artery but no bile duct, indicative of bile duct paucity. (**B**) Liver biopsy from an infant (< 6 months of age) with ALGS shows presence of bile ducts. (**C**) Facial features in children with ALGS include a triangular face, deeply set eyes, and straight nose with a bulbous nasal tip. (**D**) ALGS facies evolve from childhood to adulthood with characteristic facial features in adults being a square jaw and prominent chin. Facies pictures used from Kamath et al,[59] with permission.

 © 2021. Thieme. All rights reserved.

This document was downloaded for personal use only. Unauthorized distribution is strictly prohibited.

biopsy cannot distinguish infantile ALGS from biliary atresia, it is of paramount importance to identify extrahepatic syndromic features or a family history to help guide additional evaluations (see Diagnostic Testing in Management).

Hepatic Lesions

Hepatic lesions are a reportedly rare complication of ALGS, although their true incidence is unknown.[28] Lesions typically manifest as either regenerative nodules which are benign, homogeneous masses with relative preservation of interlobular bile ducts that usually do not necessitate intervention, or as hepatocellular carcinoma (HCC) which are malignant, single, or multifocal heterogeneous tumors prone to necrosis, hemorrhage, and metastasis that are largely resistant to chemotherapy but also often not appropriate for resection or liver transplantation due to extensive invasion of healthy liver tissue.[29–35] HCC has been documented in children and adults with ALGS phenotypes ranging from mild to severe with differing degrees of liver involvement, though little is known about its incidence, etiology, or typical manifestation age among affected individuals.[36] Case reports of adults with mild ALGS presenting with HCC and no overt ALGS liver phenotype have caused some to argue that ALGS-causing variants could predispose affected individuals to HCC by interfering with the Notch signaling.[30,36–38] Dysfunctional Notch signaling has been implicated in HCC and intrahepatic cholangiocarcioma.[39] Somatic variants in *JAG1* and *NOTCH2* have been identified in a variety of human tumor tissues; however, the exact role of the Notch signaling in HCC remains unclear.[39–41] The risk for developing HCC in ALGS regardless of phenotypic severity highlights the need for a cancer screening protocol that would enable early detection and treatment in this at-risk population.[36]

Cardiovascular

Congenital cardiac disease is common in ALGS. Structural abnormalities are seen in up to 94% of patients with the most common being stenosis/hypoplasia of the branch pulmonary arteries followed by the tetralogy of Fallot.[42] Pulmonary artery disease in ALGS is likely underestimated because invasive cardiac imaging is not routinely performed. Survival is significantly impacted by structural congenital heart disease with 6-year survival decreased to 40% compared with 95% in those with versus without intracardiac disease, respectively.[18] The presence and type of cardiac involvement does not seem to be correlated with *JAG1* mutation type.[42,43] *JAG1* is known to play a crucial role in cardiac and vascular development. While the exact mechanisms behind disrupted development are not known, genetic mouse models offer some insights. Endothelial expression of *Jag1* is essential for vascular smooth muscle development, and disruption of *Jag1* expression in endothelium in a conditional knockout mouse model leads to vascular and congenital heart defects similar to those seen in ALGS.[44,45]

Vascular

Vascular anomalies are highly prevalent in ALGS and can lead to significant morbidity and mortality with noncardiac vascular anomalies responsible for 34% of mortality in patients.[46] Up to 25% of ALGS patients have intracranial bleeds with the vast majority having no other risk factors.[18,47] Vascular anomalies are frequently (> 30%) identified on screening brain magnetic resonance imaging (MRI) in asymptomatic patients with both arterial and venous anomalies reported, with many detected within the first decade of life.[48,49] Screening brain MRI/magnetic resonance angiography (MRA) is recommended in all ALGS patients when they reach an age where they do not require sedation for the examination. In the case of trauma or neurological symptoms, there must be a low threshold to repeat imaging. As with cardiovascular anomalies, there is no correlation between vascular abnormality phenotype and ALGS genotype.[50]

Renal

Renal abnormalities can be a disease-defining criterion in ALGS. Renal involvement has been reported in 39% of ALGS patients with the most common being renal dysplasia (58.9%) followed by renal tubular acidosis (9.5%).[51] Renal insufficiency is rare but patients should have a full renal functional and structural evaluation at the time of ALGS diagnosis. A renal evaluation should be repeated if a patient is under consideration for liver transplantation. Evidence of renal disease is not a contraindication for liver transplantation. Knowledge of underlying renal disease is important to help the transplant team manage medications and limit nephrotoxic therapies.

Skeletal

The most common skeletal abnormality in ALGS is butterfly vertebrae with a wide range in frequency of 33 to 66% of patients.[52] There is no structural significance to this finding and patients are asymptomatic, but it can aid in diagnosis, although its presence does not confirm ALGS. Various other skeletal abnormalities can occur, including temporal bone abnormalities and middle ear bone defects, which increase the risk for chronic otitis media and hearing loss.[53,54] There is an increased risk of fragility fracture in ALGS, causing significant morbidity and this can be an indication for liver transplantation.[55,56] The etiology of increased fracture risk is unknown but likely multifactorial, relating to both clinical factors including chronic cholestasis, malabsorption, and fat-soluble vitamin deficiencies, as well as the underlying genetics of the disease, given the known role of *JAG1* and the Notch signaling pathway in skeletal development.[57] In a recent cross-sectional study, deficits in cortical bone size and trabecular bone microarchitecture were evident in ALGS children compared with healthy controls.[58] Further investigation is needed to determine how these deficits contribute to increased fracture risk.[58]

Facial Features

The typical ALGS facies are often described as triangular and can include a prominent forehead, deeply set eyes, moderate hypertelorism, pointed chin, and bulbous tip of the nose (►**Fig. 1C**).[59,60] These features change over time to a predominant lower face and mandible and less prominent upper

 © 2021. Thieme. All rights reserved.

This document was downloaded for personal use only. Unauthorized distribution is strictly prohibited.

face and forehead (►**Fig. 1D**).[59,60] Notably, the characteristic facies of ALGS has been shown to be the clinical feature with the highest penetrance, with almost universal occurrence in *JAG1* mutation-positive probands and relatives.[4] *JAG1* has been implicated in the Notch signaling pathway of cranial neural crest cells which perhaps play a role in the formation of these characteristic facial features.[61]

Ocular

Ocular abnormalities in ALGS can be helpful for diagnosis but do not typically affect vision. Posterior embryotoxon is the most common ocular feature found in 56 to 95% of patients with ALGS, although it is also commonly detected in non-affected children with a reported prevalence of 22.5% in children (18 months–20 years) seen in a general ophthalmic clinic.[62] This term describes a prominent, centrally positioned ring or line at the Schwalbe ring which is the point when the corneal endothelium and the uveal trabecular meshwork join.[62] Ophthalmic evaluation for optic disc drusen may be more specific for diagnosis reported in up to 95% of ALGS children versus only 0.3 to 2% of the general population.[63] There is no clear association between ocular abnormalities and fat-soluble vitamin A and E levels, nor are there genotype–phenotype correlations.[64]

Growth

Growth failure is well established in ALGS, with more than half of patients falling below the 5th percentile for height and/or weight.[65] The underlying etiology is likely multifactorial including inadequate caloric intake, contribution from chronic disease and fat malabsorption from cholestasis, and a possible role of *JAG1* in growth deficiency.[66,67] Another proposed mechanism is growth hormone (GH) insensitivity by which growth-retarded children with ALGS fail to increase insulin-like growth factor-1 (IGF-1) concentrations in response to GH.[68] This has been supported by a mouse model of ALGS showing reduced expression of IGF-1.[69] These studies imply that children with ALGS and growth failure may benefit from IGF-1 treatment rather than GH.[68] In a recent ALGS cohort study, total bilirubin showed modest negative correlation with height and weight *z*-scores, while the potential contribution of cardiac defect status was not significant, suggesting that growth impairments in ALGS may be intrinsic and related to the underlying genetic defects rather than secondary to the clinical manifestations of the disease.[22] There is a need for an ALGS-specific growth chart to help better understand the growth patterns and interpret the impact of liver transplantation and/or new therapies.

Neurodevelopment

Neurocognitive deficits and the need for special education are seen in almost half of patients with ALGS.[70] While improvements in nutritional status and cholestasis may help combat this, it has shown that patients with ALGS, particularly those with evidence of progression of liver disease, appear to be at higher risk of intelligence quotient (IQ) impairment compared with other cholestatic diseases, possibly implicating a role for *JAG1* in neurodevelopment.[71] Mental health issues can also occur due not only to the challenges of dealing with a chronic disease, but also because of ALGS-specific issues, such as intractable pruritus and xanthomas, that may affect quality of life.[70] One study showed that health-related quality of life (HRQOL) is impaired in children with ALGS similar to children with other causes of chronic intrahepatic cholestasis, and that it is associated with growth failure, a potentially treatable determinant of HRQOL.[72] Therefore, psychological support should be incorporated into all stages of ALGS management, from infancy to adulthood.

Genetics

As mentioned above, ALGS is an autosomal dominant disorder with pathogenic variants predominantly occurring in *JAG1* (almost 95% of affected individuals). Variant type is variable and includes primarily protein-truncating variants (insertion-deletions, nonsense, splice, full gene deletions, and partial gene deletions; ►**Table 2**), suggesting a disease mechanism of reduced gene dosage resulting in *JAG1* haploinsufficiency.[6,7,10–12] Biallelic variants in *JAG1* have not been described and are likely lethal. Functional studies performed on a handful of *JAG1* missense variants have corroborated the proposed mechanism of haploinsufficiency, with evidence showing that mutant proteins are retained intracellularly where they are unable to interact with the NOTCH2 receptor and/or are defective in their physical ability to interact with NOTCH2 and propagate a signal.[10,73–77] Pathogenic *NOTCH2* variants, which are far less common than *JAG1* variants (~2.5% of affected individuals), tend to be predominantly missense (►**Table 1**), and the mechanism for pathogenicity has not been confirmed through functional studies.[7,8,10,78] To date, 696 pathogenic *JAG1* variants and 20 pathogenic *NOTCH2* variants have been reported for ALGS.[10,79]

The overall diagnostic yield of ALGS in patients who meet diagnostic criteria has been reported to be 96.6% following

Table 2 Distribution and frequency of mutation type for *JAG1* and *NOTCH2* variants in Alagille syndrome

	Gene			
	JAG1		*NOTCH2*	
	$n = 696$		$n = 20$	
	%	n	%	n
Frameshift	43.5	303	10.0	2
Nonsense	16.2	113	15.0	3
Missense	15.0	104	65.0	13
Splice site	12.8	89	5.0	1
Structural variants[a]	11.1	77	5.0	1
In frame deletion	1.3	9	0	0
Promoter variant	0.1	1	0	0

[a]including multi–exon deletions/duplications, full gene deletions/duplications, translocations, and inversions.[7,10]

 © 2021. Thieme. All rights reserved.

This document was downloaded for personal use only. Unauthorized distribution is strictly prohibited.

standard genetic testing.[7] Genetic testing for ALGS typically follows a sequential testing strategy that involves *JAG1* sequencing and deletion/duplication analysis (which identifies up to ~94% of pathogenic variants) followed by *NOTCH2* sequencing analysis, although depending on the clinical testing laboratory, these tests may be offered as panels that include both sequencing and deletion/duplication analysis for both *JAG1* and *NOTCH2*.[80] Until recently, deletion/duplication variants in *NOTCH2* have not been reported, and therefore copy number analysis of *NOTCH2* is not always included; however, a recent report identifying a multi–exon deletion of *NOTCH2* in an individual with ALGS suggests that copy number analysis of *NOTCH2* should not be overlooked.[7]

Despite the high diagnostic yield obtained by standard genetic testing of *JAG1* and *NOTCH2* for ALGS, there remains a very small percentage (3.4%) of individuals in whom a molecular diagnosis is not identified despite a confident clinical diagnosis.[7] In a recent publication, genome sequencing (GS) was performed in a cohort of 14 individuals without a molecular diagnosis for their ALGS, and it resulted in the identification of four novel variants, three involving *JAG1* and one involving *NOTCH2*.[7] The *JAG1* pathogenic variants included a promoter single nucleotide variant (SNV), a balanced inversion with breakpoints located within intron 3 of *JAG1* and within an upstream gene desert, and a four-exon deletion that was missed by a prior multiplex ligation-dependent probe amplification (MLPA) assay due to limitations of the MLPA probe design.[7] The report also identified a multi–exon deletion within the *NOTCH2* gene which was previously missed since copy number analysis of *NOTCH2* was not performed for that individual.[7] This study showed that utilization of GS increases the diagnostic yield in ALGS by 0.9%, bringing it to 97.5%, and reducing the percentage of individuals in whom a molecular diagnosis is not identified to 2.5%.[7] Although prior reports have revealed cases where additional genetic testing has yielded alternative diagnoses in individuals thought to have ALGS,[81–83] it is also possible, particularly for individuals with a strong clinical indication of ALGS, that variants in as-of-yet unidentified regulatory regions for *JAG1* or *NOTCH2* may exist, and additional testing strategies, such as RNA sequencing, or improved understanding of GS data analysis may further increase the diagnostic yield for this disease.

As mentioned throughout that the overview on clinical disease features, there have been no observed genotype–phenotype correlations in ALGS; conversely, there have been multiple reports of individuals with the same pathogenic variant and divergent clinical presentations.[4,12,13,18,84–89] This has led to the hypothesis that a variant in a separate gene may influence or modify the effects of the *JAG1* pathogenic variants, further defining patient phenotype, and whether the clinical course is likely to be mild or severe. Multiple groups have provided evidence for various genes to function as genetic modifiers in ALGS. Putative modifiers have been identified in proteins that are responsible for posttranslational glycosylation of *JAG1*,[15,16] Thrombospondin 2 (THBS2), a protein that is capable of interacting with NOTCH2 and interfering with the downstream Notch signaling,[14] and more recently the transcription factor SOX9, with a study that showed reduced expression led to a worsened liver phenotype in a mouse model of ALGS.[17]

Management

Diagnostic Testing

If a diagnosis of ALGS is suspected, initial clinical evaluation should include routine laboratories (liver function tests including gamma-glutamyl transferase, serum cholesterol and triglycerides, serum bile acids, complete blood cell count, and coagulation studies) and imaging (liver ultrasound). Depending on the clinical scenario, a liver biopsy may or may not be performed. For example, it is immediately necessary to perform a liver biopsy in a cholestatic infant in whom a diagnosis of biliary atresia must be excluded in a timely manner and where awaiting the results of genetic testing is not an option. In this clinical scenario, the range of findings in infantile ALGS need to be considered to avoid misdiagnosis with biliary atresia and unnecessary hepatic surgery. There must be a high level of suspicion for ALGS in cholestatic infants as the initial di-isopropyl iminodiacetic acid (DISIDA) scan (hepatobiliary scan), cholangiogram, and liver biopsy results may mimic those of biliary atresia. Further, even with a nonexcreting DISIDA, histological bile duct proliferation, and an operative cholangiogram that fails to show the intrahepatic biliary tree, ALGS is still a possibility. Therefore, it is important to identify syndromic features or a family history of ALGS to help guide additional evaluations such as cardiology (echocardiogram), renal (renal ultrasound and renal function tests), skeletal (anteroposterior spine radiograph), ocular (ophthalmic exam), nutritional assessment (including fat-soluble vitamins), and genetic testing (previously discussed).

Outside of the clinical scenario of cholestatic infants, a liver biopsy may not be necessary at all, especially given advancements in genomic diagnostics that have shown ALGS diagnosis may occur even in those not meeting all of the classic clinical criteria. Cholestatic liver disease next generation sequencing panels, which include testing for *JAG1* and *NOTCH2*, may identify a pathogenic variant in one of these two ALGS disease genes in the absence of or before a clinical presentation of ALGS fully emerges. This scenario may be more common in *NOTCH2*-related disease; however, studies have also shown that a *JAG1* mutation does not always lead to the classical presentation of ALGS either.[4,8,78] Genomic diagnostics typically includes sequence and deletion/duplication testing of *JAG1* and *NOTCH2*.

Liver disease assessment: Use of transient elastography (FibroScan) for measurement of liver stiffness is of growing importance in the assessment of liver disease, and although pediatric experiences with this technique are limited, this is a growing area of research. Shneider et al recently published a prospective investigation of FibroScan in pediatric cholestatic liver disease showing that nonfasted liver stiffness correlates with liver disease parameters and portal hypertension, although to a lesser degree in children with ALGS compared with biliary atresia, suggesting a disease-specific

 © 2021. Thieme. All rights reserved.

This document was downloaded for personal use only. Unauthorized distribution is strictly prohibited.

pattern exists. Use of FibroScan for this purpose in children with ALGS remains investigational and is not yet part of routine clinical care.[90]

Medical Management

Management of ALGS requires a multidisciplinary approach depending on the organ system involvement as described below.

Pruritus: Initial measures to help minimize itching and excoriations include skin emollients, cutting nails short, and avoiding bathing in hot water. Ursodeoxycholic acid (UDCA), a choleretic which stimulates bile flow, is commonly used as a treatment for cholestasis, but there are no definitive studies of efficacy.[91] Other medications include cholestyramine or colesevelam, bile acid-binding resins; naltrexone, an opioid-antagonist which has been effective in other pediatric cholestatic diseases; rifampin, an antibiotic whose mechanism to treat refractory pruritus may involve modulation of pruritogen modulating factors being targeted by the Pregnane X Receptor (PXR, present in both hepatocytes and enterocytes); and antihistamines which are helpful when dosed at night when pruritus interferes with sleep.[92,93] More recently, a prospective, multicenter study tested the safety and efficacy of a serotonin reuptake inhibitor, sertraline, in treating children with refractory cholestatic pruritus, including in those related to ALGS. After 3 months of sertraline therapy, pruritus, median itching score, skin scratch marks, and sleep quality improved with a tolerable side-effect profile.[94] Combinations of these medications are often required and should be added in a step-wise fashion (►**Table 3**).[60,95] When medical therapy fails, surgical biliary diversion or ileal resection can be considered prior to liver transplantation.[96,97]

A new class of drugs under investigation for the treatment of refractory pruritus in ALGS and other cholestatic liver disorders are the ileal bile acid transporter (IBAT) inhibitors. These drugs work by interrupting the enterohepatic circulation of bile acids, in effect acting as a medical biliary diversion. The evaluation of LUM001 (maralixibat) in the Reduction of Pruritus in Alagille Syndrome (ITCH; NCT02057692) multicenter, randomized, placebo-controlled trial was recently completed for the IBAT inhibitor, maralixibat, for the treatment of refractory pruritus in ALGS.[98] The data suggest that maralixibat is safe and may reduce pruritus in ALGS.[98] The Safety and Efficacy Study of LUM001 With a Drug Withdrawal Period in Participants with Alagille Syndrome (ICONIC; NCT02160782) phase-2 randomized withdrawal trial showed that 4 years of maralixibat treatment in patients with ALGS was associated with significant and durable improvement in pruritus, serum bile acids, quality of life, cholesterol, xanthoma, and height growth.[99] Results of a phase-2 study of the IBAT inhibitor odevixibat also showed reduction in serum bile acids and pruritus in patients with ALGS and other cholestatic liver disorders.[100] Other long-term follow-up studies of maralixibat and odevixibat are ongoing (NCT04530994 and NCT04674761).

Xanthomas: These lesions can form on areas with high friction when cholesterol levels are > 500 mg/dL and can be cosmetically disfiguring for patients. No specific treatment is required as they typically resolve as cholestasis improves; however, as per personal communication, statins have reportedly been used in severe, debilitating cases with beneficial effect.[95] Importantly, the hypercholesterolemia of ALGS is mainly due to lipoprotein X (LpX), which is rich in phospholipids, albumin, and free cholesterol, having a density similar to low-density lipoprotein (LDL), however, unlike LDL, LpX has no apoB-100 and is not removed from circulation via the LDL receptor and is not thought to be atherogenic. As such, treatment of LpX-dependent hypercholesterolemia with conventional hypolipidemic drugs is frequently ineffective, and definitive treatment relies on correction of the underlying cause of cholestasis.[101]

Fat-soluble vitamin deficiency: Vitamin levels should be checked routinely and replaced as needed. Fixed ratio multivitamins, such as ADEKs or DEKAs, are frequently used but may result in excessive intake of some vitamins to treat insufficiency of others. In that case, vitamins may need to be dosed individually.

Malnutrition and growth failure: High-calorie supplements should be used as needed to optimize oral nutrition. Nasogastric feeds or gastrostomy tube placement may be required to reach calorie intake goals.

Liver Transplantation

In a recent ALGS cohort study of children presenting with cholestasis, survival to early adulthood with native liver occurred in only 24% of children at 18.5 years.[22] This study further showed that despite improvement of cholestasis, progression of hepatic disease occurred in later childhood in ALGS. This phase was associated with clinically significant portal hypertension, and ultimate need for liver transplantation later in childhood.[22] Typical indications for liver transplant in ALGS include severe pruritus, synthetic dysfunction, portal hypertension, bone fractures, and growth failure. Pretransplant evaluation must include cardiac and renal function assessments. ALGS patients rarely require a cardiac or renal transplant at the time of liver transplant. Cardiac disease should be repaired prior to liver transplant when possible. The extent of renal disease involvement may impact choice of immunosuppression regimen. Other considerations include head and abdominal imaging to identify vascular anomalies which could impact bleeding risk and technical aspects of the transplant procedure.

Patients do well after liver transplant with improved nutritional and growth status.[102] Patient survival 1-year after liver transplant is 80% with similar survival rates seen in those receiving a living related donor graft.[103,104] All potential living related donors should undergo genetic testing. Any potential donor with a *JAG1* mutation should be eliminated from consideration, even if no overt liver disease is present.[104]

Prognosis

A retrospective study of 92 individuals with ALGS determined the factors that contributed significantly to mortality were complex congenital heart disease, intracranial bleeding, and hepatic disease or hepatic transplantation. A

 © 2021. Thieme. All rights reserved.

This document was downloaded for personal use only. Unauthorized distribution is strictly prohibited.

Table 3 Medication management of cholestatic pruritus in Alagille syndrome (ALGS)

Medication	Dose	Adverse effects
Choleretics		
Ursodeoxycholic acid	10–20 mg/kg/day, divided in 2 doses	Diarrhea, abdominal pain, worsening pruritus, or cholestasis at high dose
Antibiotics		
Rifampin	10 mg/kg/day, divided in 2 doses (max 600 mg/day)	Red discoloration of body fluids, hypersensitivity reactions, hepatitis, and altered metabolism of other drugs via induction of cytochrome P450 3A
Bile-salt binding agents		
Cholestyramine	240 mg/kg/day divided in 3 doses (max 8 g/day)	Constipation, abdominal pain, and hyperchloremic metabolic acidosis, malabsorption (including fat-soluble vitamins)
Colesevelam	Limited pediatric data (adult dose 625 mg daily)	
Antihistamines		
Diphenhydramine	5 mg/kg/day, divided in 3–4 doses	Drowsiness
Hydroxyzine	2 mg/kg/day, divided in 3–4 doses	
Opioid antagonists		
Naltrexone	0.25–0.5 mg/kg once daily, max 50 mg (adult dose)	Symptoms of opioid withdrawal
Serotonin reuptake inhibitor		
Sertraline	1–4 mg/kg/day (maximum: 200 mg/day)	Behavior disorders, skin reactions, vomiting, and transient arterial hypertension
Lipid-lowering agents		
Atorvastatin	Limited pediatric data, 10 mg once daily (for children ages 10–17 years)	Headache, increased transaminases
Drugs under investigation: apical sodium-dependent bile acid transporter inhibitors [98–100]		
Maralixibat (Expanded Access Program for patients with cholestatic pruritus associated with ALGS —NCT04530994)	As per study protocol	Gastrointestinal symptoms
Odevixibat (Efficacy and Safety in patients with ALGS—NCT04674761)	As per study protocol	Gastrointestinal symptoms

Notes: These agents are used empirically and generally have not been tested.
Adapted from references.[60,95]

mortality of 17% was reported with major causes of death being hepatic death (average age, 7.5 years), intracranial bleed (average age, 2.9 years), and multisystem/cardiac failure (average age, 1.6 years).[18] The 20-year predicted life expectancy was 75% for all patients, 80% for those not requiring liver transplant, and 60% for those requiring liver transplant.[18] In a more recent longitudinal study of 293 individuals with ALGS with native liver, 11 (4%) died with native liver during the study follow-up (median = 2.7 years, range: 0–10 years).[22] Only three deaths were directly related to liver disease with the remainder due to cardiac involvement, pulmonary hemorrhage, and "other."[22]

Future Directions/Novel Therapeutics/Research

To date, therapeutic interventions in ALGS have been supportive and directed to address specific clinical manifestations, rather than the underlying pathophysiology of disordered Notch signaling pathway. Theoretically, it should be possible to develop novel therapeutics to augment the Notch signaling in ALGS, thereby ameliorating the signs and symptoms of the disease. Notch signaling pathway activation would need to be limited to specific cell types and most likely for a defined period of time, since unregulated Notch

 © 2021. Thieme. All rights reserved.

This document was downloaded for personal use only. Unauthorized distribution is strictly prohibited.

signaling can lead to development of cancer. Both bile duct and vascular development continue postnatally and could be amenable to such an approach.

Depending on the individual patient, clinical scenario, and specific pathogenic variant in *JAG1* or *NOTCH2*, several different therapeutic approaches may be appropriate. One approach would be to increase expression of the normal *JAG1* or *NOTCH2* allele by delivering mRNA or by altering transcriptional regulation. Direct delivery of the Jag1 ligand has been shown to effectively improve fracture healing in a mouse model and may be possible in some circumstances.[105] Depending on the individual pathogenic variant in a particular patient, another approach might be to promote readthrough of a nonsense variant or to correct a missense variant either in vitro or in vivo.

Genetic modifiers of the Notch signaling also represent potential therapeutic targets. For example, glycosylation status of the Notch receptor affects binding affinity for the ligands. Deletion of the O-glucosyltransferase, *Poglut1*, rescues the phenotype of bile duct paucity in a *Jag1* mouse model, while loss of the Fringe glycosyltransferases has the opposite effect.[15,16] Altering the Notch receptor glycosylation to increase affinity of JAG1 ligand binding could result in a subtle increase in the Notch signaling pathway in the setting of *JAG1* haploinsufficiency. Another recently identified genetic modifier of liver disease severity in ALGS is the extracellular matrix protein THBS2.[14] THBS2 has been shown to directly inhibit JAG1–NOTCH2 interactions in vitro, and a polymorphism leading to increased expression of *THBS2* was associated with severe liver disease in a well-characterized ALGS cohort. Targeting THBS2 expression could therefore lead to more efficient Notch signaling pathway.

While still largely theoretical, these approaches to augment the Notch signaling pathway (►**Fig. 2**) are under investigation in both in vitro and animal models and could lead to viable therapeutic interventions in the not too distant future.

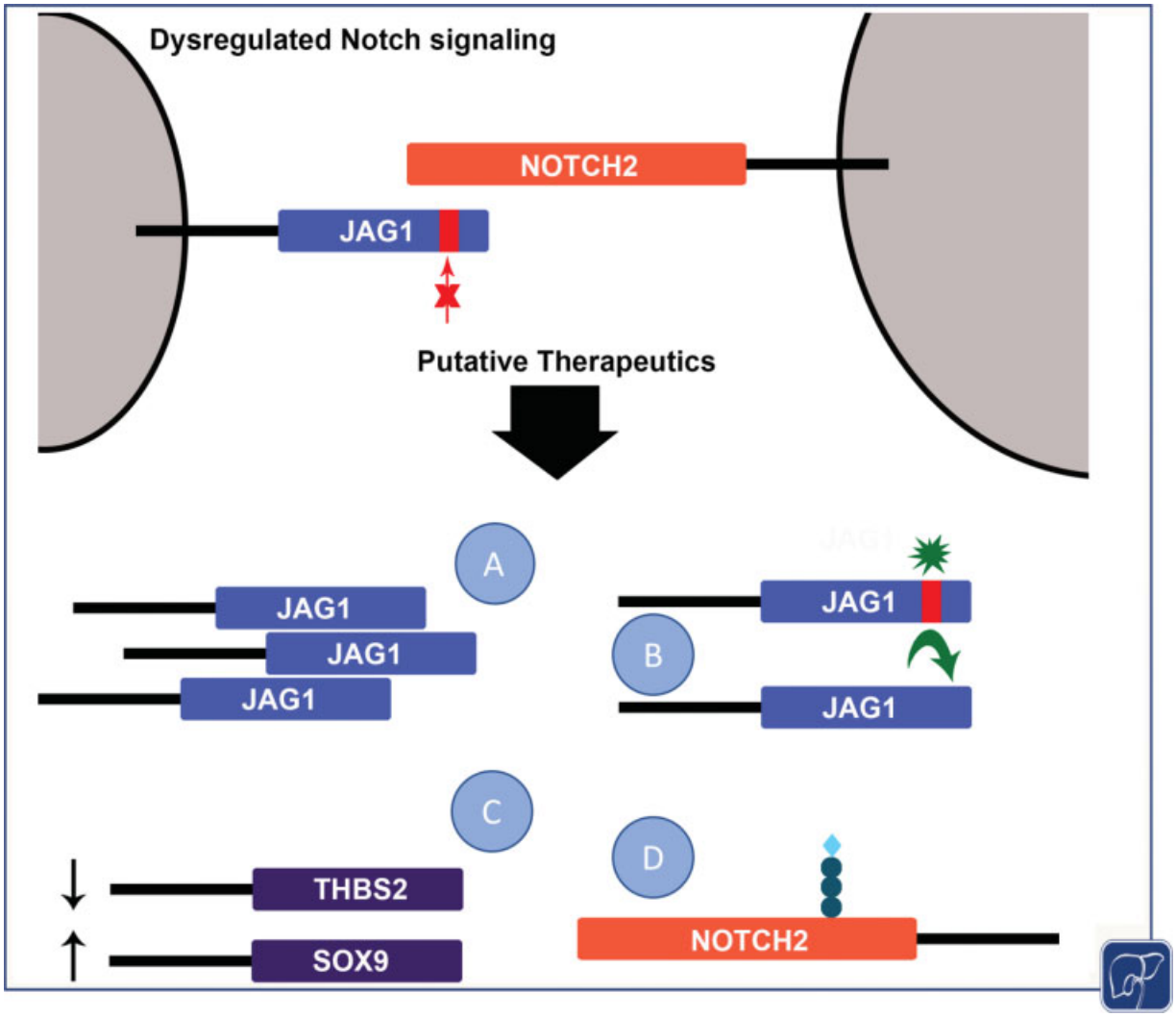

Fig. 2 Schematic of putative Notch signaling therapeutics for Alagille syndrome (ALGS). Dysregulated Notch signaling is depicted at the top with a pathogenic *JAG1* variant shown in red. Putative therapeutics include (a) increasing expression of the wild type *JAG1* allele, (b) correcting the pathogenic variant in the mutant *JAG1* allele, (c) augmenting expression of putative genetic modifiers (reducing *THBS2* or increasing *SOX9*), and (d) altering NOTCH2 glycosylation.

 © 2021. Thieme. All rights reserved.

This document was downloaded for personal use only. Unauthorized distribution is strictly prohibited.

Conclusion

ALGS is a complex, multisystem, autosomal dominant disease with variable penetrance caused predominantly by pathogenic variants in *JAG1* but also by pathogenic variants in *NOTCH2*. Although cardiac and vascular involvements are a major cause of mortality, liver disease accounts for significant morbidity in the ALGS population, and despite a clear genetic etiology, no genotype–phenotype correlations have been elucidated for any organ system. Clinical management remains largely supportive; however, multiple avenues of active research have identified promising drugs for refractory pruritus. Research is ongoing to discover targeted interventions to augment the Notch signaling in involved tissues.

Major Concepts and Learning Points

- Alagille syndrome (ALGS) is a rare, debilitating, autosomal dominant disorder caused by pathogenic variants in one of two disease-causing genes, *JAGGED1* (*JAG1*) or *NOTCH2*, leading to disruption of the Notch signaling pathway.
- The syndrome is primarily characterized by intrahepatic bile duct paucity and cholestasis, but has multiple clinical features.
- Typical indications for liver transplant in ALGS include severe pruritus, synthetic dysfunction, portal hypertension, bone fractures, and growth failure.
- There are no observed genotype–phenotype correlations in ALGS, leading to the hypothesis that a variant in a separate gene may modify the effects of *JAG1* or *NOTCH2* pathogenic variants.
- Management of ALGS aims to support nutrition and alleviate pruritus, and while there are currently no approved treatments, ileal bile acid transporter (IBAT)/apical sodium-dependent bile acid transporter (ASBT) inhibition has demonstrated promising clinical results.

Conflicts of Interest

K.M.L. declares the following conflicts—research grants for clinical trials: Mirum Pharmaceuticals (maralixibat) and Albireo Pharma (odevixibat); consulting for Mirum Pharmaceuticals, Albireo Pharma, and Travere Therapeutics (formerly known as Retrophin). M.A.G. declares the following conflicts—consulting for Travere Therapeutics (formerly known as Retrophin).

Acknowledgments

The authors are grateful to Pierre Russo for providing histologic images.

References

1 Alagille D, Habib EC, Thomassin N. L'atresie des voies biliaires intrahepatiques avec voies biliaires extrahepatiques permeables chez l'enfant. J Par Pediatr 1969:301–318
2 Alagille D, Estrada A, Hadchouel M, Gautier M, Odièvre M, Dommergues JP. Syndromic paucity of interlobular bile ducts (Alagille syndrome or arteriohepatic dysplasia): review of 80 cases. J Pediatr 1987;110(02):195–200
3 Watson GH, Miller V. Arteriohepatic dysplasia: familial pulmonary arterial stenosis with neonatal liver disease. Arch Dis Child 1973;48(06):459–466
4 Kamath BM, Bason L, Piccoli DA, Krantz ID, Spinner NB. Consequences of JAG1 mutations. J Med Genet 2003;40(12): 891–895
5 Li L, Krantz ID, Deng Y, et al. Alagille syndrome is caused by mutations in human Jagged1, which encodes a ligand for Notch1. Nat Genet 1997;16(03):243–251
6 Oda T, Elkahloun AG, Pike BL, et al. Mutations in the human *Jagged1* gene are responsible for Alagille syndrome. Nat Genet 1997;16(03):235–242
7 Rajagopalan R, Gilbert MA, McEldrew DA, et al. Genome sequencing increases diagnostic yield in clinically diagnosed Alagille syndrome patients with previously negative test results. Genet Med 2021;23(02):323–330
8 Kamath BM, Bauer RC, Loomes KM, et al. NOTCH2 mutations in Alagille syndrome. J Med Genet 2012;49(02):138–144
9 McDaniell R, Warthen DM, Sanchez-Lara PA, et al. NOTCH2 mutations cause Alagille syndrome, a heterogeneous disorder of the notch signaling pathway. Am J Hum Genet 2006;79(01): 169–173
10 Gilbert MA, Bauer RC, Rajagopalan R, et al. Alagille syndrome mutation update: Comprehensive overview of JAG1 and NOTCH2 mutation frequencies and insight into missense variant classification. Hum Mutat 2019;40(12):2197–2220
11 Saleh M, Kamath BM, Chitayat D. Alagille syndrome: clinical perspectives. Appl Clin Genet 2016;9:75–82
12 Spinner NB, Colliton RP, Crosnier C, Krantz ID, Hadchouel M, Meunier-Rotival M. Jagged1 mutations in Alagille syndrome. Hum Mutat 2001;17(01):18–33
13 Crosnier C, Driancourt C, Raynaud N, et al. Mutations in *JAGGED1* gene are predominantly sporadic in Alagille syndrome. Gastroenterology 1999;116(05):1141–1148
14 Tsai EA, Gilbert MA, Grochowski CM, et al. *THBS2* is a candidate modifier of liver disease severity in Alagille syndrome. Cell Mol Gastroenterol Hepatol 2016;2(05):663–675.e2
15 Ryan MJ, Bales C, Nelson A, et al. Bile duct proliferation in Jag1/fringe heterozygous mice identifies candidate modifiers of the Alagille syndrome hepatic phenotype. Hepatology 2008;48(06): 1989–1997
16 Thakurdas SM, Lopez MF, Kakuda S, et al. Jagged1 heterozygosity in mice results in a congenital cholangiopathy which is reversed by concomitant deletion of one copy of Poglut1 (Rumi). Hepatology 2016;63(02):550–565
17 Adams JM, Huppert KA, Castro EC, et al. Sox9 is a modifier of the liver disease severity in a mouse model of Alagille syndrome. Hepatology 2020;71(04):1331–1349
18 Emerick KM, Rand EB, Goldmuntz E, Krantz ID, Spinner NB, Piccoli DA. Features of Alagille syndrome in 92 patients: frequency and relation to prognosis. Hepatology 1999;29(03):822–829
19 Subramaniam P, Knisely A, Portmann B, et al. Diagnosis of Alagille syndrome-25 years of experience at King's College Hospital. J Pediatr Gastroenterol Nutr 2011;52(01):84–89
20 Lykavieris P, Hadchouel M, Chardot C, Bernard O. Outcome of liver disease in children with Alagille syndrome: a study of 163 patients. Gut 2001;49(03):431–435
21 Kamath BM, Munoz PS, Bab N, et al. A longitudinal study to identify laboratory predictors of liver disease outcome in Alagille syndrome. J Pediatr Gastroenterol Nutr 2010;50(05): 526–530
22 Kamath BM, Ye W, Goodrich NP, et al; Childhood Liver Disease Research Network (ChiLDReN) Outcomes of childhood cholestasis in Alagille syndrome: results of a multicenter observational study. Hepatol Commun 2020;4(03):387–398

 © 2021. Thieme. All rights reserved.

This document was downloaded for personal use only. Unauthorized distribution is strictly prohibited.

23 Mitchell E, Gilbert M, Loomes KM. Alagille syndrome. Clin Liver Dis 2018;22(04):625–641
24 Kahn E. Paucity of interlobular bile ducts. Arteriohepatic dysplasia and nonsyndromic duct paucity. Perspect Pediatr Pathol 1991;14:168–215
25 Loomes KM, Russo P, Ryan M, et al. Bile duct proliferation in liver-specific Jag1 conditional knockout mice: effects of gene dosage. Hepatology 2007;45(02):323–330
26 Hofmann JJ, Zovein AC, Koh H, Radtke F, Weinmaster G, Iruela-Arispe ML. Jagged1 in the portal vein mesenchyme regulates intrahepatic bile duct development: insights into Alagille syndrome. Development 2010;137(23):4061–4072
27 Markowitz J, Daum F, Kahn EI, et al. Arteriohepatic dysplasia. I. Pitfalls in diagnosis and management. Hepatology 1983;3(01): 74–76
28 Rapp JB, Bellah RD, Maya C, Pawel BR, Anupindi SA. Giant hepatic regenerative nodules in Alagille syndrome. Pediatr Radiol 2017; 47(02):197–204
29 Alhammad A, Kamath BM, Chami R, Ng VL, Chavhan GB. Solitary hepatic nodule adjacent to the right portal vein: a common finding of Alagille syndrome? J Pediatr Gastroenterol Nutr 2016; 62(02):226–232
30 Bhadri VA, Stormon MO, Arbuckle S, Lam AH, Gaskin KJ, Shun A. Hepatocellular carcinoma in children with Alagille syndrome. J Pediatr Gastroenterol Nutr 2005;41(05):676–678
31 Ennaifer R, Ben Farhat L, Cheikh M, Romdhane H, Marzouk I, Belhadj N. Focal liver hyperplasia in a patient with Alagille syndrome: diagnostic difficulties. A case report. Int J Surg Case Rep 2016;25:55–61
32 Syed MA, Khalili K, Guindi M. Regenerating nodules in arteriohepatic syndrome: a case report. Br J Radiol 2008;81(963): e79–e83
33 Wetli SC, Gralla ES, Schibli S, Stranzinger E. Hepatocellular carcinoma and regenerating nodule in a 3-year-old child with Alagille syndrome. Pediatr Radiol 2010;40(10):1696–1698
34 Kim B, Park S-H, Yang HR, Seo JK, Kim WS, Chi JG. Hepatocellular carcinoma occurring in Alagille syndrome. Pathol Res Pract 2005;201(01):55–60
35 Andrews AR, Putra J. Central hepatic regenerative nodules in Alagille syndrome: a clinicopathological review. Fetal Pediatr Pathol 2021;40(01):69–79
36 Schindler EA, Gilbert MA, Piccoli DA, Spinner NB, Krantz ID, Loomes KM. Alagille syndrome and risk for hepatocellular carcinoma: Need for increased surveillance in adults with mild liver phenotypes. Am J Med Genet A 2021;185(03): 719–731
37 Keeffe EB, Pinson CW, Ragsdale J, Zonana J. Hepatocellular carcinoma in arteriohepatic dysplasia. Am J Gastroenterol 1993;88(09):1446–1449
38 Tsai S, Gurakar A, Anders R, Lam-Himlin D, Boitnott J, Pawlik TM. Management of large hepatocellular carcinoma in adult patients with Alagille syndrome: a case report and review of literature. Dig Dis Sci 2010;55(11):3052–3058
39 Lu J, Xia Y, Chen K, et al. Oncogenic role of the Notch pathway in primary liver cancer. Oncol Lett 2016;12(01):3–10
40 Tate JG, Bamford S, Jubb HC, et al. COSMIC: the catalogue of somatic mutations in cancer. Nucleic Acids Res 2019;47(D1): D941–D947
41 Morell CM, Fiorotto R, Fabris L, Strazzabosco M. Notch signalling beyond liver development: emerging concepts in liver repair and oncogenesis. Clin Res Hepatol Gastroenterol 2013;37(05): 447–454
42 McElhinney DB, Krantz ID, Bason L, et al. Analysis of cardiovascular phenotype and genotype-phenotype correlation in individuals with a JAG1 mutation and/or Alagille syndrome. Circulation 2002;106(20):2567–2574
43 Loomes KM, Underkoffler LA, Morabito J, et al. The expression of Jagged1 in the developing mammalian heart correlates with cardiovascular disease in Alagille syndrome. Hum Mol Genet 1999;8(13):2443–2449
44 High FA, Lu MM, Pear WS, Loomes KM, Kaestner KH, Epstein JA. Endothelial expression of the Notch ligand Jagged1 is required for vascular smooth muscle development. Proc Natl Acad Sci U S A 2008;105(06):1955–1959
45 Hofmann JJ, Briot A, Enciso J, et al. Endothelial deletion of murine Jag1 leads to valve calcification and congenital heart defects associated with Alagille syndrome. Development 2012;139(23): 4449–4460
46 Kamath BM, Spinner NB, Emerick KM, et al. Vascular anomalies in Alagille syndrome: a significant cause of morbidity and mortality. Circulation 2004;109(11):1354–1358
47 Lykavieris P, Crosnier C, Trichet C, Meunier-Rotival M, Hadchouel M. Bleeding tendency in children with Alagille syndrome. Pediatrics 2003;111(01):167–170
48 Emerick KM, Krantz ID, Kamath BM, et al. Intracranial vascular abnormalities in patients with Alagille syndrome. J Pediatr Gastroenterol Nutr 2005;41(01):99–107
49 Carpenter CD, Linscott LL, Leach JL, Vadivelu S, Abruzzo T. Spectrum of cerebral arterial and venous abnormalities in Alagille syndrome. Pediatr Radiol 2018;48(04):602–608
50 Jones EA, Clement-Jones M, Wilson DI. JAGGED1 expression in human embryos: correlation with the Alagille syndrome phenotype. J Med Genet 2000;37(09):658–662
51 Kamath BM, Podkameni G, Hutchinson AL, et al. Renal anomalies in Alagille syndrome: a disease-defining feature. Am J Med Genet A 2012;158A(01):85–89
52 Sanderson E, Newman V, Haigh SF, Baker A, Sidhu PS. Vertebral anomalies in children with Alagille syndrome: an analysis of 50 consecutive patients. Pediatr Radiol 2002;32(02): 114–119
53 Okuno T, Takahashi H, Shibahara Y, Hashida Y, Sando I. Temporal bone histopathologic findings in Alagille syndrome. Arch Otolaryngol Head Neck Surg 1990;116(02):217–220
54 Teng CS, Yen H-Y, Barske L, et al. Requirement for Jagged1-Notch2 signaling in patterning the bones of the mouse and human middle ear. Sci Rep 2017;7(01):2497
55 Olsen IE, Ittenbach RF, Rovner AJ, et al. Deficits in size-adjusted bone mass in children with Alagille syndrome. J Pediatr Gastroenterol Nutr 2005;40(01):76–82
56 Bales CB, Kamath BM, Munoz PS, et al. Pathologic lower extremity fractures in children with Alagille syndrome. J Pediatr Gastroenterol Nutr 2010;51(01):66–70
57 Youngstrom DW, Dishowitz MI, Bales CB, et al. Jagged1 expression by osteoblast-lineage cells regulates trabecular bone mass and periosteal expansion in mice. Bone 2016; 91:64–74
58 Kindler JM, Mitchell EL, Piccoli DA, et al. Bone geometry and microarchitecture deficits in children with Alagille syndrome. Bone 2020;141:115576
59 Kamath BM, Loomes KM, Oakey RJ, et al. Facial features in Alagille syndrome: specific or cholestasis facies? Am J Med Genet 2002; 112(02):163–170
60 Mouzami M, Kamath BM. Alagille syndrome. In: Dhawan A, ed. Concise Pediatric and Adolescent Hepatology. Basel, Switzerland: Springer International Publishing; 2018
61 Humphreys R, Zheng W, Prince LS, et al. Cranial neural crest ablation of Jagged1 recapitulates the craniofacial phenotype of Alagille syndrome patients. Hum Mol Genet 2012;21(06):1374–1383
62 Rennie CA, Chowdhury S, Khan J, et al. The prevalence and associated features of posterior embryotoxon in the general ophthalmic clinic. Eye (Lond) 2005;19(04):396–399
63 Nischal KK, Hingorani M, Bentley CR, et al. Ocular ultrasound in Alagille syndrome: a new sign. Ophthalmology 1997;104(01): 79–85
64 Hingorani M, Nischal KK, Davies A, et al. Ocular abnormalities in Alagille syndrome. Ophthalmology 1999;106(02):330–337

This document was downloaded for personal use only. Unauthorized distribution is strictly prohibited.

 © 2021. Thieme. All rights reserved.

65 Rovner AJ, Schall JI, Jawad AF, et al. Rethinking growth failure in Alagille syndrome: the role of dietary intake and steatorrhea. J Pediatr Gastroenterol Nutr 2002;35(04):495–502
66 Sokol RJ, Stall C. Anthropometric evaluation of children with chronic liver disease. Am J Clin Nutr 1990;52(02):203–208
67 Wasserman D, Zemel BS, Mulberg AE, et al. Growth, nutritional status, body composition, and energy expenditure in prepubertal children with Alagille syndrome. J Pediatr 1999;134(02): 172–177
68 Bucuvalas JC, Horn JA, Carlsson L, Balistreri WF, Chernausek SD. Growth hormone insensitivity associated with elevated circulating growth hormone-binding protein in children with Alagille syndrome and short stature. J Clin Endocrinol Metab 1993;76 (06):1477–1482
69 Andersson ER, Chivukula IV, Hankeova S, et al. Mouse model of Alagille syndrome and mechanisms of Jagged1 missense mutations. Gastroenterology 2018;154(04):1080–1095
70 Elisofon SA, Emerick KM, Sinacore JM, Alonso EM. Health status of patients with Alagille syndrome. J Pediatr Gastroenterol Nutr 2010;51(06):759–765
71 Leung DH, Sorensen LG, Ye W, et al. Neurocognitive status in alagille syndrome: Results of a multi-center prospective observational study. Hepatology 2017;66(01):647A
72 Kamath BM, Chen Z, Romero R, et al; Childhood Liver Disease Research Network (ChiLDReN) Quality of life and its determinants in a multicenter cohort of children with Alagille syndrome. J Pediatr 2015;167(02):390–6.e3
73 Morrissette JD, Colliton RP, Spinner NB. Defective intracellular transport and processing of JAG1 missense mutations in Alagille syndrome. Hum Mol Genet 2001;10(04):405–413
74 Lu F, Morrissette JJ, Spinner NB. Conditional JAG1 mutation shows the developing heart is more sensitive than developing liver to JAG1 dosage. Am J Hum Genet 2003;72(04): 1065–1070
75 Guarnaccia C, Dhir S, Pintar A, Pongor S. The tetralogy of Fallot-associated G274D mutation impairs folding of the second epidermal growth factor repeat in Jagged-1. FEBS J 2009;276(21): 6247–6257
76 Bauer RC, Laney AO, Smith R, et al. Jagged1 (JAG1) mutations in patients with tetralogy of Fallot or pulmonic stenosis. Hum Mutat 2010;31(05):594–601
77 Tada M, Itoh S, Ishii-Watabe A, Suzuki T, Kawasaki N. Functional analysis of the Notch ligand Jagged1 missense mutant proteins underlying Alagille syndrome. FEBS J 2012;279(12):2096–2107
78 Vandriel SM, Li L, She H, et al. Phenotypic divergence of JAGGED1 and NOTCH2-associated Alagille syndrome: results from the International Multicenter GALA Study Group. Hepatology 2020;72(Suppl 1):882A–884A
79 Stenson PD, Mort M, Ball EV, et al. The Human Gene Mutation Database: towards a comprehensive repository of inherited mutation data for medical research, genetic diagnosis and next-generation sequencing studies. Hum Genet 2017;136 (06):665–677
80 Gilbert MA, Spinner NB. Genetics of Alagille syndrome. In: Alagille Syndrome. Springer International Publishing; 2018: 33–48. Doi: 10.1007/978-3-319-94571-2_3
81 Grochowski CM, Rajagopalan R, Falsey AM, et al. Exome sequencing reveals compound heterozygous mutations in ATP8B1 in a JAG1/NOTCH2 mutation-negative patient with clinically diagnosed Alagille syndrome. Am J Med Genet A 2015;167A(04): 891–893
82 Rajagopalan R, Grochowski CM, Gilbert MA, et al. Compound heterozygous mutations in NEK8 in siblings with end-stage renal disease with hepatic and cardiac anomalies. Am J Med Genet A 2016;170(03):750–753
83 Schatz SB, Jüngst C, Keitel-Anselmo V, et al. Phenotypic spectrum and diagnostic pitfalls of ABCB4 deficiency depending on age of onset. Hepatol Commun 2018;2(05):504–514
84 Dhorne-Pollet S, Deleuze JF, Hadchouel M, Bonaïti-Pellié C Segregation analysis of Alagille syndrome. J Med Genet 1994; 31(06):453–457
85 Elmslie FV, Vivian AJ, Gardiner H, Hall C, Mowat AP, Winter RM. Alagille syndrome: family studies. J Med Genet 1995;32(04): 264–268
86 Izumi K, Hayashi D, Grochowski CM, et al. Discordant clinical phenotype in monozygotic twins with Alagille syndrome: possible influence of non-genetic factors. Am J Med Genet A 2016; 170A(02):471–475
87 Kamath BM, Krantz ID, Spinner NB, Heubi JE, Piccoli DA. Monozygotic twins with a severe form of Alagille syndrome and phenotypic discordance. Am J Med Genet 2002;112(02): 194–197
88 Krantz ID, Colliton RP, Genin A, et al. Spectrum and frequency of jagged1 (JAG1) mutations in Alagille syndrome patients and their families. Am J Hum Genet 1998;62(06):1361–1369
89 Shulman SA, Hyams JS, Gunta R, Greenstein RM, Cassidy SB. Arteriohepatic dysplasia (Alagille syndrome): extreme variability among affected family members. Am J Med Genet 1984;19 (02):325–332
90 Shneider BL, Goodrich NP, Ye W, et al; Childhood Liver Disease Research Network (ChiLDReN) Nonfasted liver stiffness correlates with liver disease parameters and portal hypertension in pediatric cholestatic liver disease. Hepatol Commun 2020;4(11): 1694–1707
91 Narkewicz MR, Smith D, Gregory C, Lear JL, Osberg I, Sokol RJ. Effect of ursodeoxycholic acid therapy on hepatic function in children with intrahepatic cholestatic liver disease. J Pediatr Gastroenterol Nutr 1998;26(01):49–55
92 Zellos A, Roy A, Schwarz KB. Use of oral naltrexone for severe pruritus due to cholestatic liver disease in children. J Pediatr Gastroenterol Nutr 2010;51(06):787–789
93 Bolier AR, Peri S, Oude Elferink RPJ, Beuers U. The challenge of cholestatic pruritus. Acta Gastroenterol Belg 2012;75(04): 399–404
94 Thébaut A, Habes D, Gottrand F, et al. Sertraline as an additional treatment for cholestatic pruritus in children. J Pediatr Gastroenterol Nutr 2017;64(03):431–435
95 Kamath BM, Loomes KM, Piccoli DA. Medical management of Alagille syndrome. J Pediatr Gastroenterol Nutr 2010;50(06): 580–586
96 Mattei P, von Allmen D, Piccoli D, Rand E. Relief of intractable pruritus in Alagille syndrome by partial external biliary diversion. J Pediatr Surg 2006;41(01):104–107, discussion 104–107
97 Modi BP, Suh MY, Jonas MM, Lillehei C, Kim HB. Ileal exclusion for refractory symptomatic cholestasis in Alagille syndrome. J Pediatr Surg 2007;42(05):800–805
98 Shneider BL, Spino C, Kamath BM, et al; Childhood Liver Disease Research Network. Placebo-controlled randomized trial of an intestinal bile salt transport inhibitor for pruritus in Alagille syndrome. Hepatol Commun 2018;2(10):1184–1198
99 Gonzalez E. Durability of treatment effect with long-term maralixibat use in children with Alagille syndrome: 4-year safety and efficacy results from the ICONIC study [abstract 243]. Paper presented at: North Am Soc Pediatr Gastroenterol Hepatol Nutr Annu Meet; 2020. Last accessed on 31 May 2021 at: https://members.naspghan.org/Annualmeeting/Program/Scientific_Abstracts_2020/Annualmeeting/2020_Annual_Meeting/2020_Annual_Meeting_Program/Scientifc_Abstracts.aspx
100 Gonzales E, Sturm E, Baumann U, et al. Correlation of autotaxin levels, serum bile acids, and pruritus in a multiple-dose, open-label, multinational study of the ileal bile acid transport inhibitor A4250 [abstract SAT-059]. Paper presented at: 53rd Annu Int Liver Congr; 2018. Last accessed on 31 May 2021 at: https://www.clinicalkey.com/service/content/pdf/watermarked/1-s2.0-S0168827818315216.pdf?locale=en_US&searchIndex=

This document was downloaded for personal use only. Unauthorized distribution is strictly prohibited.

101 Kattah L, Gómez A, Gutiérrez S, et al. Hypercholesterolemia due to lipoprotein X: case report and thematic review. Clin Med Insights Endocrinol Diabetes 2019;12:1179551419878687
102 Kamath BM, Yin W, Miller H, et al; Studies of Pediatric Liver Transplantation. Outcomes of liver transplantation for patients with Alagille syndrome: the studies of pediatric liver transplantation experience. Liver Transpl 2012;18(08): 940–948
103 Kamath BM, Schwarz KB, Hadzić N Alagille syndrome and liver transplantation. J Pediatr Gastroenterol Nutr 2010;50(01):11–15
104 Kasahara M, Kiuchi T, Inomata Y, et al. Living-related liver transplantation for Alagille syndrome. Transplantation 2003; 75(12):2147–2150
105 Youngstrom DW, Senos R, Zondervan RL, et al. Intraoperative delivery of the Notch ligand Jagged-1 regenerates appendicular and craniofacial bone defects. NPJ Regen Med 2017;2(01):32

This document was downloaded for personal use only. Unauthorized distribution is strictly prohibited.