Article published online: 2021-05-18

Revascularization of Chronic Iliac Vein Occlusion Using Balloon-Assisted Transseptal Needle Puncture Technique

Simon Long[1] Patrick D. Sutphin[2] Sanjeeva P. Kalva[2]

[1]Department of Vascular and Interventional Radiology, University of California Irvine, Orange, California, United States
[2]Department of Vascular and Interventional Radiology, GRB-290 Massachusetts General Hospital, Boston, Massachusetts, United States

Address for correspondence Simon Long, MD, Department of Vascular and Interventional Radiology, University of California Irvine, 101 The City Drive South, Route 140, Orange, CA 92868, United States (e-mail: Slong9@hs.uci.edu).

J Clin Interv Radiol ISVIR 2021;5:119–122.

Abstract

Objectives To evaluate the utility of a transseptal needle for balloon-assisted sharp recanalization of chronically occluded central venous structures.

Background Chronically occluded central veins are not an uncommon problem, which may arise due to a plethora of reasons. Traditionally, wire and catheter techniques are often used first in an attempt to reestablish flow. When these methods fail, more aggressive techniques are employed, such as sharp recanalization using the back end of wires, Teflon-coated wires, or Rosch–Uchida or Colapinto needles. However, utilization of transseptal needles, traditionally reserved for cardiac procedures, has rarely been described.

Methods Transseptal needle was utilized for balloon-assisted sharp recanalization after traditional wire and catheter techniques failed in revascularization of chronically occluded iliac veins.

Results Transseptal needle was utilized successfully in two cases in revascularization of chronically occluded central veins.

Conclusion Transseptal needle is a viable tool to add to the interventional radiologists' armamentarium in reestablishing flow in chronically occluded central veins.

Keywords
- sharp
- recanalization
- chronic

Introduction

Endovascular revascularization of occluded iliac veins can be challenging, especially if the occlusion is chronic, or associated with femoral venous occlusion or occlusion of the inferior vena cava (IVC). Associated extrinsic compression abnormalities such as May–Thurner syndrome or pelvic masses, and inflammatory disease-associated venous occlusions, can add additional challenges to the procedure. An uncomplicated chronic venous stenosis or short segment occlusion can be "crossed" with a soft, angled or straight teflon-coated guide wire.[1] However, long-segment occlusions with large collateral veins are often hard to cross due to buckling of the guidewire into the collaterals. Many techniques have been proposed to achieve success in crossing such venous occlusions. These include use of a triaxial system of catheters and sheaths to prevent buckling of the guidewire, intentional use of a looped guidewire, use of back end of the guidewire for better support and added force during guide wire manipulation, the use of sharp needles such as Rosch–Uchida needle or Colapinto needle, and intentional passage of guidewire in the venous subintimal space to reenter central to the venous

published online
May 18, 2021

DOI https://doi.org/10.1055/s-0041-1728996
ISSN 2457-0214

© 2021. Indian Society of Vascular and Interventional Radiology.
This is an open access article published by Thieme under the terms of the Creative Commons Attribution-NonDerivative-NonCommercial-License, permitting copying and reproduction so long as the original work is given appropriate credit. Contents may not be used for commercial purposes, or adapted, remixed, transformed or built upon. (https://creativecommons.org/licenses/by-nc-nd/4.0/).
Thieme Medical and Scientific Publishers Pvt. Ltd. A-12, 2nd Floor, Sector 2, Noida-201301 UP, India

occlusion using various assist devices such as "Outback" or "Pioneer" catheters.[2-10] Often times, many operators use these techniques in an incremental manner while evaluating the immediate complications and risk-benefit ratio.

Revascularization with the use of sharp needles is usually the last resort after failure of all other options.[1] Both Rosch–Uchida and Colapinto needles are designed for traversing the liver parenchyma during transjugular intrahepatic portosystemic shunt (TIPS).[11,12] The Colapinto needle is a slightly curved long 16G needle that requires a 7F or larger sheath and allows passage of a 0.035" guidewire through its central lumen. The Rosch–Uchida needle system has an outer curved cannula that is placed through a 10F sheath and a sheathed 19G needle that is inserted through the curved cannula. It allows passage of a 0.035" guidewire through the sheath after removal of the needle. The off-label use of such devices in vessels has been described with success but the risks remain high due to the large size of the needles. The use of sharp needle devices for venous recanalization can be supplemented by direct visualization of the needle entry into the targeted central vein, such as the IVC, using intravascular ultrasound (IVUS).[13] Additionally, the use of a balloon or a snare in the patent central vein can help guide the trajectory of the needle pass. However, such guidance may not be available or feasible, depending on the length of occlusion, and use of large needles in these circumstances can be associated with bleeding or injury to adjacent arterial structures.

Unlike Rosch–Uchida or Colapinto needles, the transseptal needle is a small device used for intravascular use to traverse the interatrial septum.[14] It requires a 6F sheath. The "needle" is not as sharp as the other needles described and allows a 0.025" guidewire through its lumen. This needle is also routinely used for crossing into the aorta during transcaval aortic valve repair. The occasional use of this needle for revascularization of thoracic central venous occlusion has been described.[15] In this report, we describe successful use of the combination of a transseptal needle and balloon assistance for revascularization of a chronic iliac venous occlusion.

Case Report

A 30-year-old woman presented with progressively increasing left lower extremity swelling and pain. She had prior history of deep venous thrombosis (DVT) of the distal IVC and left iliac vein approximately 9 months prior to presentation. She was treated initially with low-molecular weight heparin (LMWH, Lovenox) and transitioned to warfarin. Three months after the episode of the DVT, an attempt by another provider to recanalize the occluded left iliac vein was unsuccessful. She continued warfarin but progressive lower extremity swelling prompted a referral to us. CT venography demonstrated a long-segment occlusion of the left iliac vein with chronic, partially occlusive DVT in the left common femoral vein. The IVC was patent.

The left common femoral vein was accessed under ultrasound guidance and a 10F short sheath was placed. Venography confirmed occlusion of the left common iliac vein and severe stenosis of the left external iliac vein, with multiple abdominal wall collaterals (►**Fig. 1**). Using a combination of a 6F long sheath, 5F angled catheter and 0.035" angle Teflon-coated guidewire, the stenosis in the left external iliac vein was crossed. Multiple attempts to cross the left common iliac vein occlusion with angled guidewire, stiff angled guidewire, and back end of the guidewire were unsuccessful. Through a right internal jugular vein access, an IVUS catheter was advanced into the IVC to guide transseptal needle entry into it. A transseptal needle was advanced through the left femoral sheath. The needle could not be identified on IVUS due to its limited field of view. The IVUS catheter was exchanged for a 12 mm × 40 mm (Mustang) balloon, which was used as a target to advance the transseptal needle into the IVC. The trajectory of the transseptal needle relative to the balloon was confirmed on two orthogonal planes, and the needle was advanced into the balloon (►**Fig. 2**). A 0.018" guidewire was advanced in to the IVC. A cone-beam CT confirmed intravenous location of the wire. Serial angioplasty of left iliac veins was performed with 3 mm and 5 mm balloons. The 0.018" guidewire was exchanged for a 0.035" stiff Amplatz wire. Two overlapping 14 mm × 90 mm wall stents were placed in the left iliac veins. The stents were dilated to 12 mm using a 12 mm × 40 mm high pressure (Conquest) balloon. Posttreatment venography confirmed brisk flow through the iliac veins (►**Fig. 3**) The patient was discharged on a combination of acetyl salicylic acid (162 mg) and therapeutic LMWH. At 1 month, CT venography and duplex ultrasound confirmed

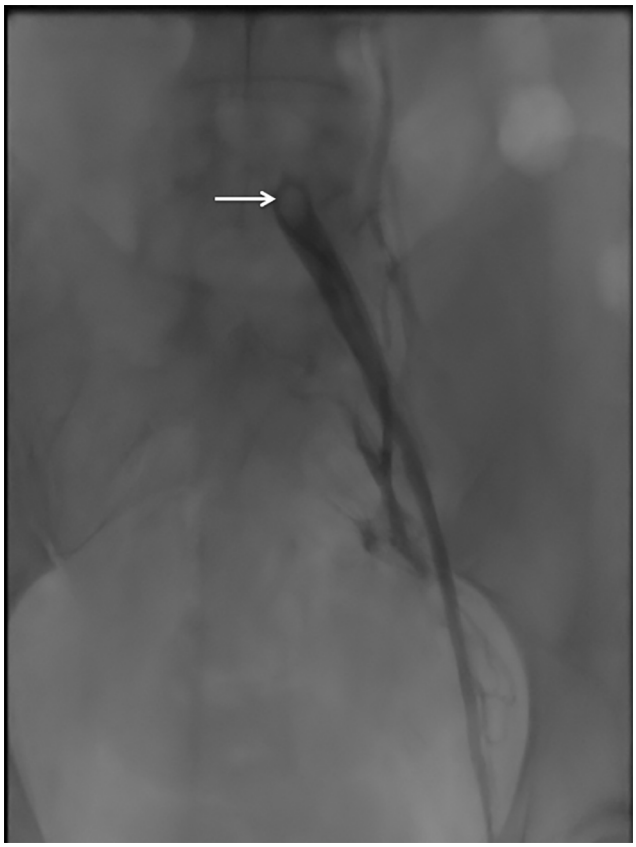

Fig. 1 Venogram through left common femoral vein access. Failure of contrast to progress beyond the left common iliac vein (arrow) is noted. Later images demonstrated opacification of abundant pelvic and abdominal wall collaterals.

 © 2021. Indian Society of Vascular and Interventional Radiology.

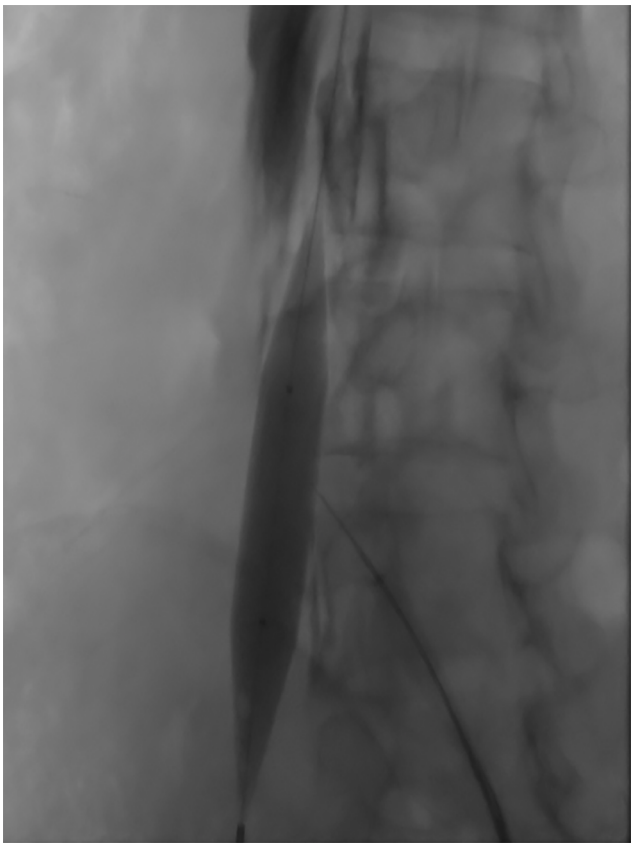

Fig. 2 Intraoperative fluoroscopic image at the level of the inferior vena cava (IVC) confluence. Transseptal needle placed through the left common femoral vein access is noted abutting the target 12 mm balloon within the IVC, just prior to perforating the target balloon.

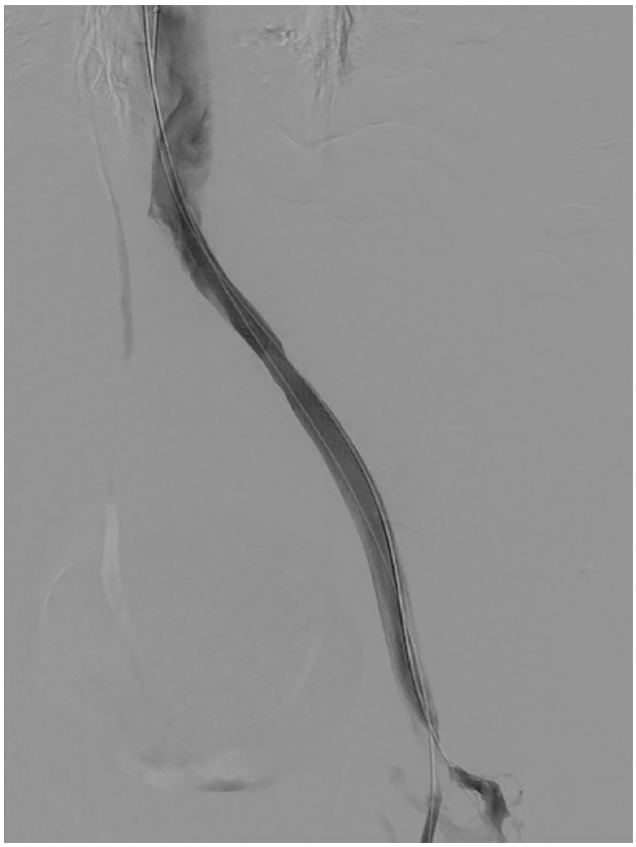

Fig. 3 Intraoperative fluoroscopic image centered on the left iliac veins. Venogram demonstrates brisk flow within the left iliac veins after sharp recanalization, endovascular stent placement, and subsequent balloon angioplasty.

patent iliac vein stent and residual nonobstructive chronic DVT in left common femoral vein. The patient developed a small thigh hematoma at 1 month which was surgically evacuated. At 2 month follow-up, the patient remained asymptomatic.

Discussion

Chronic iliac or iliocaval occlusion leads to chronic venous hypertension and valvular dysfunction. Patients present with symptoms of progressively worsening lower extremity edema, varicosities, and exercise intolerance. Longstanding chronic venous hypertension results in chronic venous stasis, lipodermosclerosis, and venous ulcer around the ankle and lower leg. In addition, the abdominal wall collaterals and varicose veins in lower extremities can be disfiguring and have the potential to bleed, owing to high-venous pressure. Revascularization of the occluded iliocaval veins has been shown to reduce symptoms and disease progression.

While traditional methods of crossing occluded vessels involved passing an angled or straight teflon-coated guide wire, sharp recanalization is usually performed with the back end of a guidewire or a long needle.[1] As venous occlusions tend to be more fibrotic, sharp recanalization is more often used for veins rather than arteries. Occluded iliac veins are often more difficult to revascularize due to their long-segment occlusions and three-dimensional course of the vessels as well as close proximity to the arteries. Previous techniques for revascularization of occluded iliac veins included unintentional subintimal or extraluminal passage of a guidewire and subsequent reentry in to the lumen of a patent proximal vein.[8,9] Using a target such as a snare or catheter or balloon while traversing the occlusion with a rigid end of the guidewire or a sharp needle allows improved chances of target vessel entry and decreased complications. Of all the targets used, an inflated balloon allows superior targeting by providing a larger target and more dilated vein. In addition, the entry of the needle or rigid wire into the vein can be confirmed when the balloon deflates. The balloon can also allow safe capturing of the wire for subsequent advancement into the target vein.

The use of a transseptal needle instead of Rosch–Uchida or Colapinto needles has distinct advantages. The smaller size of the needle and small caliber of the lumen may help decrease complications during accidental injury to the adjacent structures. Given the smaller diameter of the needle, the shape of the needle can be more easily changed to accommodate various venous configurations. The inner sharp wire can be changed to various floppy or rigid wires for further modulation of the needle for a desired outcome.

Despite the aggressive (use of rigid wire and needles) revascularization techniques described for chronic venous occlusions, the outcomes of such recanalization appear to

 © 2021. Indian Society of Vascular and Interventional Radiology.

be similar to those described without the use of these techniques for iliocaval veins and central veins. The reported complications are also rare.

In conclusion, we report the use of a transseptal needle and balloon targeting technique for revascularization of chronic iliac vein occlusion. This technique appears to be safe. This can be applied after failure of conventional techniques for revascularization and as an alternative to use of larger needles. As with any complex endovascular work, a good understanding of anatomy, preoperative planning, and expertise are essential to ensure good patient outcomes.

Conflict of Interest

None declared.

References

1 Horikawa M, Quencer KB. Central Venous Interventions. Tech Vasc Interv Radiol 2017;20(1):48–57

2 Ferral H, Bjarnason H, Wholey M, Lopera J, Maynar M, Castaneda-Zuniga WR. Recanalization of occluded veins to provide access for central catheter placement. J Vasc Interv Radiol 1996;7(5):681–685

3 Farrell T, Lang EV, Barnhart W. Sharp recanalization of central venous occlusions. J Vasc Interv Radiol 1999;10(2 Pt 1) : 149–154

4 Goo DE, Kim YJ, Choi DL, et al. Use of a rosch-uchida needle for recanalization of refractory dialysis-related central vein occlusion. Am J Roentgenol 2010;194(5):1352–1356

5 Gandhi AH, Wakefield TW, Williams DM. Recanalization of the intentionally interrupted inferior vena cava. J Vasc Surg 2015;62(3):747–749

6 Ito N, Isfort P, Penzkofer T, Grommes J, Greiner A, Mahnken A. Sharp recanalization for chronic left iliac vein occlusion. Cardiovasc Intervent Radiol 2012;35(4):938–941

7 Murphy TP, Webb MS. Percutaneous venous bypass for refractory dialysis-related subclavian vein occlusion. J Vasc Interv Radiol 1998;9(6):935–939

8 Porter D, Rundback JH, Miller S. Sharp recanalization using a subintimal reentry device, angioplasty, and stent placement for severely symptomatic iliofemoral deep venous thrombosis secondary to congenital aplasia of the inferior vena cava. J Vasc Interv Radiol 2010;21(11):1765–1769

9 Brountzos EN, Preza O, Kelekis A, Panagiotou I, Kelekis N. Recanalization of dialysis catheter-related subclavian vein occlusion using a re-entry device: report of two patients. Cardiovasc Intervent Radiol 2011;34(1):207–211

10 Gupta H, Murphy TP, Soares GM. Use of a puncture needle for recanalization of an occluded right subclavian vein. Cardiovasc Intervent Radiol 1998;21(6):508–511

11 Kalva SP, Salazar GM, Walker TG. Transjugular intrahepatic portosystemic shunt for acute variceal hemorrhage. Tech Vasc Interv Radiol 2009;12(2):92–101

12 Gaba RC, Khiatani VL, Knuttinen MG, et al. Comprehensive review of TIPS technical complications and how to avoid them. Am J Roentgenol 2011;196(3):675–685

13 Neglén P, Raju S. Intravascular ultrasound scan evaluation of the obstructed vein. J Vasc Surg 2002;35(4):694–700

14 Alkhouli M, Rihal CS, Holmes DR Jr. Transseptal techniques for emerging structural heart interventions. JACC Cardiovasc Interv 2016;9(24):2465–2480

15 Arabi M, Ahmed I, Mat'hami A, Ahmed D, Aslam N. Sharp central venous recanalization in hemodialysis patients: a single-institution experience. Cardiovasc Intervent Radiol 2016;39(6):927–934

 © 2021. Indian Society of Vascular and Interventional Radiology.