




Role of Diffuse Tensor Imaging in Predicting Outcomes of Decompressive Surgery in Degenerative Cervical Myelopathy—A Prospective Analysis

Neeraj Sharma¹  Rajesh Alugolu¹ Dinesh Gangapatnam¹ Mudumba Vijaya Saradhi¹

¹Department of Neurosurgery, Nizam's Institute of Medical Sciences, Hyderabad, Telangana, India

Indian J Neurosurg 2023;12:30–36.

Address for correspondence Rajesh Alugolu, MBBS, MS, MCh, Department of Neurosurgery, Nizam's Institute of Medical Sciences, Punjagutta, Hyderabad, Telangana, 500082, India (e-mail: drarajesh1306@gmail.com).

Abstract

Background Cervical spondylotic myelopathy is a common degenerative disorder of the cervical spine. Assessing the severity of the disease objectively remains a challenge. Advances in magnetic resonance imaging (MRI), especially diffusion tensor imaging (DTI), elucidate the damaged or compressed fiber tracts in the cord. This study is our endeavor to correlate the relationship between clinical features, radiological features with special reference to DTI, and surgical outcome in patients with degenerative cervical myelopathy.

Methods All consecutive patients of cervical spondylotic myelopathy and cord intensity changes in MRI, admitted and treated in the department of neurosurgery during the period of 2016 to 2018, were included and evaluated clinically and radiologically. The clinical evaluation included motor assessment scale (MAS), 30 meters walking, and hand grip. Radiological investigations included additional DTI in 3T MRI and clinical outcome was measured postoperatively after 12 months by modified Japanese Orthopedic Association (mJOA) recovery ratio and MAS scores.

Results The patients age ranged from 30 to 80 years and the mean age of the study population was 55.95 ± 10 years. Patients with fractional anisotropy (FA) < 0.5 had higher grade of Nurick, that is, grade 5 in 4.3%, grade 4 in 65.2%, and grade 3 in 27.1% compared with grade 5 in 0%, grade 4 in 23.5%, and grade 3 in 47.1% in FA > 0.5 . Mean mJOA recovery ratio in the group FA > 0.5 was 57.32 whereas it was 38.78 in FA < 0.5 .

Conclusion DTI serves as a potential biomarker for predicting the surgical outcome in degenerative cervical myelopathy cases and thereby making the surgical decision precise. FA can be a potential quantitative tool to predict the functional outcome following decompressive surgery for degenerative cervical myelopathy conditions, in particular lower FA values carries poor prognosis.

Keywords

- ▶ myelopathy
- ▶ functional
- ▶ anisotropy

article published online
December 15, 2021

DOI <https://doi.org/10.1055/s-0041-1727421>.
ISSN 2277-954X.

© 2021. Neurological Surgeons' Society of India. All rights reserved. This is an open access article published by Thieme under the terms of the Creative Commons Attribution-NonDerivative-NonCommercial-License, permitting copying and reproduction so long as the original work is given appropriate credit. Contents may not be used for commercial purposes, or adapted, remixed, transformed or built upon. (<https://creativecommons.org/licenses/by-nc-nd/4.0/>)
Thieme Medical and Scientific Publishers Pvt. Ltd., A-12, 2nd Floor, Sector 2, Noida-201301 UP, India

Introduction

Degenerative cervical myelopathy is a common disorder of the cervical spine and is the most common cause of cervical spinal cord dysfunction.¹ It is a progressive degenerative spine abnormality, causing cervical spinal cord damage.² It affects almost every person over 40 years, earlier or later.³ Pathogenesis of degenerative cervical myelopathy is composed of static and dynamic factors.⁴ Assessing the severity of the disease, objectively, remains a challenge.

Magnetic resonance imaging (MRI) of the cervical spine may show high signal intensity on T2W sequence at the most compressed part.⁵⁻⁸ However, the true prognostication is not feasible as the anatomical imaging is unable to quantify the damage as to temporary or permanent and its effect especially after surgical decompression.

Advances in MRI, especially diffusion tensor imaging (DTI), elucidate the damaged or compressed fiber tracts in the cord.⁹⁻¹² This study is our endeavor to correlate the relationship between clinical features, radiological features with special reference to DTI, and surgical outcome in patients with degenerative cervical myelopathy.

Materials and Methods

The present prospective study included all degenerative cervical myelopathy patients who attended the Department of Neurosurgery, Nizam's Institute of Medical Sciences, Hyderabad, Telangana, India, from September 2016 to October 2018 requiring surgical intervention. A total of 60 patients who met the defined inclusion criteria were included; however, those who deteriorated in the postoperative period ($n = 20$) were excluded from the study.

Inclusion Criteria

All symptomatic cervical myelopathy patients between 18 and 80 years with radiological changes in sagittal T2W imaging, with prolapsed intervertebral discs, ossified posterior longitudinal ligament, and ossified ligamentum flavum in whom the neurological level corroborated with the imaging findings, were included in the surgical cohort.

Exclusion Criteria

Patients with cervical trauma including acute or chronic injuries, spinal tumors, previous cranial surgeries, and those who deteriorated neurologically in the postoperative period ($n = 20$) were excluded from the study.

All patients with grade 2 and 3 myelomalacia changes on MRI requiring surgical intervention were evaluated. Clinical workup included: assessment of tone by Modified Ashworth score, hand grip force, Nurick grading, and modified Japanese Orthopedic Association (mJOA) score in the preoperative period and 6 months following surgery.

Radiological workup included assessment of signal intensity changes on T1W and T2W sequences of cervical spine MRI in sagittal planes. MRI contrast imaging did not add up to any added advantage for diagnosis and outcome of these patients. DTI was performed in the preoperative period in a 3T Siemens-

MAGNETOM Skyra (Germany) machine in all these cases with the following parameters: TR=2,790 ms, TE=83 ms, FOV=220 mm × 110 mm, matrix=160 × 160 pixels, slice thickness=3 mm, gap=0.3 mm, $b = 0$, $b = 800$ s/mm², number of slices=15, approximate time for scan was 4 minutes and 15 seconds. Fractional anisotropy (FA) values were obtained at the most stenosed level and at the relatively noncompressed cranial level (C1-C2).

Statistical Analysis

The continuous data are expressed as mean with standard deviation, while categorical data as frequency of occurrence and percentages. Data was analyzed using SPSS version 17.0 (SPSS, Inc., Chicago, Illinois, United States). Means and standard deviations were computed for continuous variables. Comparisons of categorical variables were performed using chi-square test and a p -value of < 0.05 was considered significant. Logistic regression was used when multivariate analysis was required.

Results

Demography

The mean age of the study group was 55.95 years (range 30–80 years). Apart from signs of myelopathy, 42.5% ($n = 17$) patients had radiculopathy, 30% ($n = 12$) had sphincter disturbances, and 70% ($n = 28$) had breathlessness. Single-level disease was noted in 16 patients (40%), 10 patients (25%) had two-level disease, 9 (22.5%) had three-level disease, and 5 (12.5%) patients had four-level disease (►Table 1). In 24 patients

Table 1 Demographics

		N
Age (y)	41–50	15
	51–60	70
	61–70	15
Gender	Male	35
	Female	05
Presenting symptom	Radiculopathy	17
	Sphincter disturbances	12
	Respiratory difficulty	28
Levels of disease	1 level	16
	2 levels	10
	3 levels	9
	> 4 levels	5
Disease causing myelopathy		
OPLL		20 (50%)
PIVD		20 (50%)
MRI changes		
Grade I	No signal change	$n = 0$
Grade II	Signal change only on T2W	$n = 36$
Grade III	Signal change on T1W and T2W	$n = 4$

Abbreviations: MRI, magnetic resonance imaging; OPLL, ossification of the posterior longitudinal ligament; PIVD, prolapsed intervertebral disc.

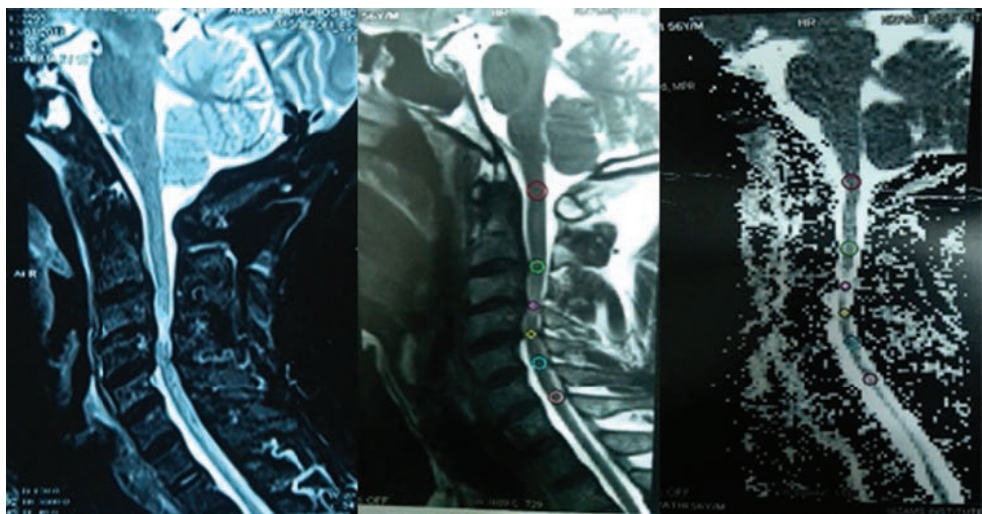


Fig. 1 A case having cervical ossification of the posterior longitudinal ligament (OPLL) with intense hyperintensity at C3-C4 level on T2 sequence, for which diffusion tensor imaging (DTI) has been done and region of interest (ROI) has been marked at various levels and fractional anisotropy (FA) mapping has been done.

surgery was done through posterior approach and anterior approach was followed in 16 patients, decision made on the basis of k-line drawn on plain radiograph.

Radiological Parameters

On MRI sagittal planes, signal intensity changes were graded as grade II (signal intensity changes on only T2) and grade III (both on T2, T1). Grade II MRI changes were present in both on T2 and T1 (→ Fig. 1), 36 patients (90%), and 4 patients (10%) had grade III changes in the spinal cord (→ Table 1). FA values were measured at the most compressed levels and at relatively noncompressed C1-C2 levels acting as a reference standard in all the patients. The mean FA value at C1-C2 ranged from 0.56 to 0.85. FA values (→ Fig. 1) at the diseased or most compressed segment was observed to be in the range of 0.29 to 0.76. We took FA 0.5 as the arbitrary limit and divided patients into two groups with FA ≤ 0.5 (23 patients) and FA > 0.5 (17 patients) and compared the results (→ Table 2).

Clinical Parameters

Tone was assessed by Modified Ashworth Scale. Preoperatively, motor assessment scale (MAS) ranged from 1 to 4 with mean of

Table 2 Fractional anisotropy values

	Mean	SD
FA at C1-C2	0.698	0.072
FA at diseased level	0.473	0.099

Abbreviations: FA, fractional anisotropy; SD, standard deviation.

1.72. Postoperative MAS ranged from 0 to 2 and mean decreased in the postoperative period to 0.82, which was statistically significant ($p < 0.001$). Hand grip force (kg) was assessed in both the hands by manual dynamometer and preoperatively it ranged from 28 to 80 kg in the right hand and 20 to 75 kg in the left hand. Postoperatively, grip ranged from 40 to 110 kg in both the hands and mean values were 75.75% in the right hand and 72.75% in the left hand and the improvement was statistically significant ($p < 0.001$). Respiratory status was assessed by single ball incentive spirometer, preoperative values ranged from 300 to 900 mL, mean volume was 610 mL and the postoperative values ranged from 600 to 1,200 mL, mean volume was 901 mL, the decrease is statistically significant ($p < 0.001$) (→ Table 3). Patients were subjected to 30 m walk and the time taken to

Table 3 Clinical parameters compared pre- and postoperatively

	Preoperative range	Mean	Postoperative range	Mean	p-Value
MAS score	1-4	1.72	0-2	0.82	< 0.001
Incentive spirometry	300-900 mL	610 mL	600-1,200 mL	901 mL	< 0.001
Hand grip	Right 28-80 kg Left 20-75 kg	Right 55.75 kg Left 54.50 kg	Right 40-110 kg Left 40-110 kg	Right 75.75 kg Left 72.75 kg	< 0.001

Abbreviation: MAS, motor assessment scale.
Note: p-Value was calculated using paired t-test.

completion (seconds) was recorded. Preoperatively, mean time was 77.85 seconds and the mean time in the postoperative period was 71.88 seconds and the improvement was not statistically significant ($p=0.56$).

Discussion

Management of degenerative cervical myelopathy is challenging because of multifactorial pathogenesis and variety of surgical approaches. Although imaging modalities like conventional MRI reveal the presence of signal intensity changes in T1W and T2W sequences which reflect cord damage, prognostication of the pathology and outcome by this is clearly uncertain. DTI parameters are more sensitive to detect early myelopathic changes much before its appearance on T2 sequence of conventional MRI.^{9,13,14} DTI can quantify the water molecule size and its direction of diffusivity which denotes the axonal fiber integrity in the cord. FA is the most commonly used quantitative tool for the dispersion of diffusion tensor

indices.^{12,15,16} An attempt has been made to formulate a comprehensive prognostication and quantify myelomalacia by conventional MRI and DTI.

Demography

Correlation between Age and Surgical Outcome

Degenerative cervical myelopathy is the most commonly acquired cause of spinal cord dysfunction among those aged over 55 years according to Crandall and Batzdorf.¹⁷ In the Naderi et al¹⁸ study of 27 patients with cervical spondylotic myelopathy (CSM) showed better neurological improvement in patients younger than 60 years. Holly and colleagues¹⁹ in his study confirmed age of the patient as one of the important prognostic factors. Fujiwara et al²⁰ in his study of 50 patients with cervical myelopathy, observed that there is negative correlation between advanced age at the time of surgery with recovery rate. In our study patients whose age was less than 40 years had better mJOA recovery ratios (→ **Table 4**).

Table 4 Review of literature stating role of MRI in cervical myelopathy and comparison with the present study

Literature	No. of patients	Correlation to age	Correlation with no. levels	Radiological findings	Correlation with FA values
Crandall and Batzdorf	$n = 62$	Cervical myelopathy is most common after 55 years	Two level involvement is most common		
Fujiwara et al	$n = 50$	Negative correlation between advanced age at the time of surgery and outcome	Better outcome in one or two level disease		
Yu	$n = 248$		Decrease in mean preoperative mJOA and NDI with increase in disease level		
Takahashi	$n = 99$			T2W signal changes had poor outcome than with no changes on MRI	
Uchida et al	$n = 148$			T1W change is the strongest contributor for outcome. β -coefficient 0.256	
Chaitanya Baban	$n = 46$			Sharp and focal changes on T2W had poor mJOA 1 year postoperatively	
Vedantam et al	$n = 44$				FA < 0.55 had low 12-month postoperative mJOA values
Present study	$n = 40$	Better mean mJOA recovery rate in < 40 years ($p = 0.222$)	With increase in level, there is decrease in mJOA, FIM and increase in NDI, Nurick grade	Grade II - low Nurick grade, low NDI, high mJOA scores Grade III-high Nurick grade, high NDI, low mJOA scores ($p < 0.05$)	FA < 0.5 has poor mJOA recovery rates. $p = 0.04$

Abbreviations: FA, fractional anisotropy; FIM, Functional Independence Measure; mJOA, modified Japanese Orthopedic Association; MRI, magnetic resonance imaging; NDI, Neck Disability Index.

Table 5 Correlation between number of levels and preop mJOA, Nurick, and FIM

Parameter	No. of levels	Mean	SD	f-Value	p-Value
mJOA	One level	10.94	2.98	0.337	0.799
	Two level	10.60	2.63		
	Three level	10.00	4.18		
	Four level	9.60	0.55		
Nurick	One level	2.81	0.75	2.59	0.068
	Two level	3.10	1.45		
	Three level	3.67	1.00		
	Four level	4.00	0.00		
FIM	One level	98.75	20.80	3.47	0.026
	Two level	84.90	14.43		
	Three level	67.67	33.08		
	Four level	77.00	30.52		

Abbreviations: FIM, Functional Independence Measure; mJOA, modified Japanese Orthopedic Association; SD, standard deviation.

Assessment of Signal Changes, FA Values, and Surgical Outcome

Correlation between the number of levels of disease and preoperative clinical status: With the increase in level of involvement of disease there is decrease in mJOA and Functional Independence Measure (FIM) scores and increase in Neck Disability Index (NDI) and Nurick grade which reflects the poor functional status in accordance with other studies.

Correlation between Preoperative Clinical Status and MR Signal Intensity Changes

Yukawa et al²¹ stated that T2W signal intensity changes represent reversible pathological changes to the intramedullary cord, whereas T1W changes represent irreversible damage to the cord. Uchida et al²² proposed that signal intensity changes are signs of chronic cord damage (► Table 4).

Correlation between Preoperative Clinical Status and DTI Metrics

DTI values particularly FA has a strong correlation with clinical parameters like mJOA, Nurick scale, etc. In our study, it was observed that patients with FA < 0.5 had higher grade of Nurick, that is, grade 5 in 4.3%, grade 4 in 65.2%, and grade 3 in 27.1% compared with grade 5 in 0%, grade 4 in 23.5%, and grade 3 in 47.1% in FA > 0.5. There was a statistically significant relation observed between FA < 0.5 and higher Nurick grade in preoperative period (p < 0.05). There was a significant increase in number of patients with lesser Nurick grade in patients with FA > 0.5 in the postoperative period than when compared with preoperative period (p < 0.05). In the group of FA > 0.5 the mean NDI decreased to 36.8 in the postoperative period compared with the preoperative period which was 54.9. In

the FA group < 0.5, the preoperative mean NDI was 45 and then it decreased in the postoperative period which was 30.43, but this decrease was not statistically significant (p > 0.05) (► Table 5). In the group of FA > 0.5, the preoperative mean FIM score was 94 and the postoperative mean FIM score was 100 compared with 79 and 92 in the pre- and postoperative period, respectively, in the FA < 0.5 group. But this was not statistically significant (► Table 5).

Correlation between Clinical Outcome and MR Signal Intensity Changes

Mean mJOA score in the preoperative period was 10.48 and mean score in the postoperative period was 12.80 and the increase was not statistically significant. Recovery rate was calculated by using pre- and postoperative mJOA values (► Table 6).

Hirabayashi method²³: Recovery rate

$$\frac{\text{Postop JOA} - \text{preop JOA}}{17 - \text{preop JOA}} \times 100\%$$

Recent study-reported clinical results were divided into four groups as follows: 75% or higher (excellent), 50 to 74% (good), 25 to 49% (fair), and less than 25% (poor).²⁴ Therefore, we defined a poor clinical outcome as a recovery rate less than 50% in this study.

- Recovery rate > 50% = good outcome
- Recovery rate ≤ 50% = poor outcome

Mean mJOA recovery ratio²⁵ in the study population was observed to be 46.66 ± 29.19. Mean mJOA recovery ratio in patients with grade II changes was 46.49 compared with 45 in patients with grade III changes. This is in accordance with various studies.

Table 6 Correlation of mJOA recovery ratio with demographic and radiological findings

	mJOA recovery ratio	p-Value	t-Value
Age < 40 years	66.67 ± 28.86	0.222	1.24
> 40 years	45.04 ± 29		
Grade II MRI findings	46.49 ± 29.96	0.871	0.164
Grade III MRI findings	45 ± 46.62	0.342	0.962
FA value < 0.5	38.78 ± 30.12	0.04	2.128
> 0.5	24.9 ± 21.28		

Abbreviations: FA, fractional anisotropy; mJOA, modified Japanese Orthopedic Association; MRI, magnetic resonance imaging.

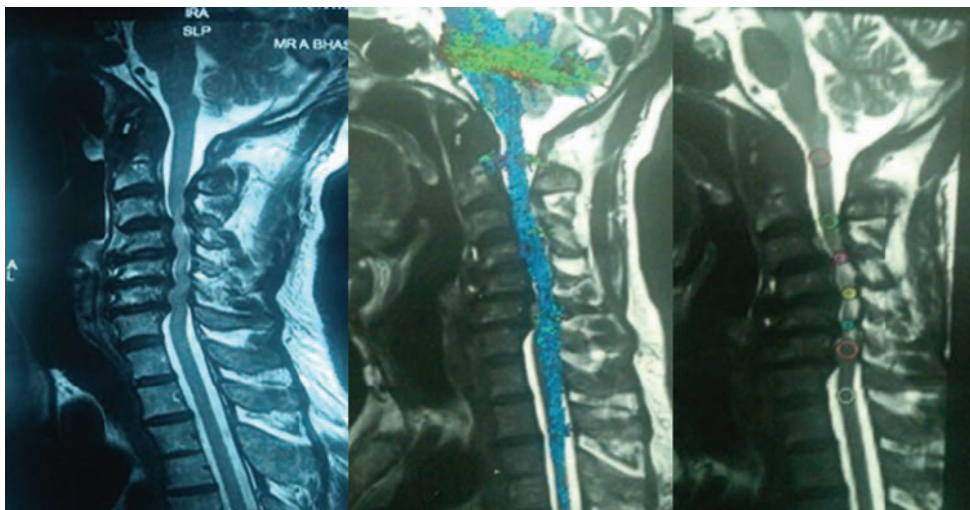


Fig. 2 A case having multiple level disco-ligamentous compression with intense hyperintensity at C3-C4, C4-C5, C5-C6, and C7 levels on T2 sequence, for which diffusion tensor imaging (DTI) has been done and region of interest (ROI) has been marked at various levels and fractional anisotropy (FA) mapping has been done.

Correlation between Clinical Outcome and DTI Metrics

In our study, the mean mJOA recovery ratio in the group FA > 0.5 was 57.32 whereas it was 38.78 in FA ≤ 0.5. So, here it is evident that the recovery ratio is better in FA > 0.5 and it is statistically significant. Various studies show similar findings.

Wen et al¹⁵ showed that patients with a high preoperative FA value were likely to achieve better functional recovery after surgery. Dong et al²⁶ studied FA values in 50 normal patients and 60 patients with CSM and he correlated preoperative and postoperative mJOA score and Nurick grades with DTI parameters, and found that the FA value was positively correlated with the mJOA score but negatively correlated with the Nurick grade.

Vedantam et al²⁷ found that FA at the level of maximal compression correlated positively with preoperative mJOA score. Preoperative FA correlated inversely with recovery throughout the postoperative period. This was statistically significant at 12-month postsurgery and nearly so at 6 and 24 months. Patients with preoperative FA < 0.55 had a statistically significant difference in outcome compared with FA > 0.55. They concluded that FA is an objective measure of function and could provide a basis for

prognosis. FA is particularly useful if preoperative values are less than 0.55.

Conclusion

In our study, we found that patients below 40 years of age had better functional outcome after surgery. Functional status is inversely related to the increasing levels of involvement of the disease. Patients with preoperative Nurick grade < 2 had better surgical outcome. Signal intensity changes on both T1W and T2W carries poor prognosis. FA can be a potential quantitative tool to predict the functional outcome following decompressive surgery for degenerative cervical myelopathy conditions, in particular lower FA values carries poor prognosis.

Authors' contributions

All authors were involved in the conceptualization, collection of data, DTI FA value calculation, surgery, and follow-up evaluation.

Funding

None.

Conflict of interest

None declared.

References

- 1 Epstein N. Ossification of the cervical posterior longitudinal ligament: a review. *Neurosurg Focus* 2002;13(02):ECP1
- 2 Fernández de Rota JJ, Meschian S, Fernández de Rota A, Urbano V, Baron M. Cervical spondylotic myelopathy due to chronic compression: the role of signal intensity changes in magnetic resonance images. *J Neurosurg Spine* 2007;6(01):17–22
- 3 Baron EM, Young WF. Cervical spondylotic myelopathy: a brief review of its pathophysiology, clinical course, and diagnosis. *Neurosurgery* 2007;60(1, Supp 1):S35–S41
- 4 Henderson FC Sr, Austin C, Benzel E, et al. Neurological and spinal manifestations of the Ehlers–Danlos syndromes. *Am J Med Genet C Semin Med Genet* 2017;175(01):195–211
- 5 Boden SD, McCowin PR, Davis DO, Dina TS, Mark AS, Wiesel S. Abnormal magnetic-resonance scans of the cervical spine in asymptomatic subjects. A prospective investigation. *J Bone Joint Surg Am* 1990;72(08):1178–1184
- 6 Kang Y, Lee JW, Koh YH, et al. New MRI grading system for the cervical canal stenosis. *AJR Am J Roentgenol* 2011;197(01):W134–40
- 7 Lyu RK, Tang LM, Chen CJ, Chen CM, Chang HS, Wu YR. The use of evoked potentials for clinical correlation and surgical outcome in cervical spondylotic myelopathy with intramedullary high signal intensity on MRI. *J Neurol Neurosurg Psychiatry* 2004;75(02):256–261
- 8 Matsuda Y, Miyazaki K, Tada K, et al. Increased MR signal intensity due to cervical myelopathy. Analysis of 29 surgical cases. *J Neurosurg* 1991;74(06):887–892
- 9 Demir A, Ries M, Moonen CT, et al. Diffusion-weighted MR imaging with apparent diffusion coefficient and apparent diffusion tensor maps in cervical spondylotic myelopathy. *Radiology* 2003;229(01):37–43
- 10 Jellison BJ, Field AS, Medow J, Lazar M, Salamat MS, Alexander AL. Diffusion tensor imaging of cerebral white matter: a pictorial review of physics, fiber tract anatomy, and tumor imaging patterns. *AJNR Am J Neuroradiol* 2004;25(03):356–369
- 11 Kang M, Anderer E, Elliott R, Kalthorn S, Cooper P, Frempong-Boadu A. Diffusion tensor imaging of the spondylotic cervical spinal cord: a preliminary study of quantifiable markers in the evaluation for surgical decompression. *Int J Head Neck Surg* 2011;5:01
- 12 Mamata H, Jolesz FA, Maier SE. Apparent diffusion coefficient and fractional anisotropy in spinal cord: age and cervical spondylosis-related changes. *J Magn Reson Imaging* 2005;22(01):38–43
- 13 Budzik JF, Balbi V, Le Thuc V, Duhamel A, Assaker R, Cotten A. Diffusion tensor imaging and fibre tracking in cervical spondylotic myelopathy. *Eur Radiol* 2011;21(02):426–433
- 14 Kara B, Celik A, Karadereler S, et al. The role of DTI in early detection of cervical spondylotic myelopathy: a preliminary study with 3-T MRI. *Neuroradiology* 2011;53(08):609–616
- 15 Wen CY, Cui JL, Liu HS, et al. Is diffusion anisotropy a biomarker for disease severity and surgical prognosis of cervical spondylotic myelopathy? *Radiology* 2014;270(01):197–204
- 16 Aota Y, Niwa T, Uesugi M, Yamashita T, Inoue T, Saito T. The correlation of diffusion-weighted magnetic resonance imaging in cervical compression myelopathy with neurologic and radiologic severity. *Spine* 2008;33(07):814–820
- 17 Crandall PH, Batzdorf U. Cervical spondylotic myelopathy. *J Neurosurg* 1966;25(01):57–66
- 18 Naderi S, Özgen S, Pamir MN, Özek MM, Erzen C. Cervical spondylotic myelopathy: surgical results and factors affecting prognosis. *Neurosurgery* 1998;43(01):43–49, discussion 49–50
- 19 Matz PG, Anderson PA, Holly LT, et al. Joint Section on Disorders of the Spine and Peripheral Nerves of the American Association of Neurological Surgeons and Congress of Neurological Surgeons. The natural history of cervical spondylotic myelopathy. *J Neurosurg Spine* 2009;11(02):104–111
- 20 Fujiwara K, Yonenobu K, Ebara S, Yamashita K, Ono K. The prognosis of surgery for cervical compression myelopathy. An analysis of the factors involved. *J Bone Joint Surg Br* 1989;71(03):393–398
- 21 Yukawa Y, Kato F, Yoshihara H, Yanase M, Ito K. MR T2 image classification in cervical compression myelopathy: predictor of surgical outcomes. *Spine* 2007;32(15):1675–1678, discussion 1679
- 22 Uchida K, Nakajima H, Sato R, et al. Multivariate analysis of the neurological outcome of surgery for cervical compressive myelopathy. *J Orthop Sci* 2005;10(06):564–573
- 23 Hirabayashi K, Miyakawa J, Satomi K, Maruyama T, Wakano K. Operative results and postoperative progression of ossification among patients with ossification of cervical posterior longitudinal ligament. *Spine* 1981;6(04):354–364
- 24 Maki S, Koda M, Kitamura M, et al. Diffusion tensor imaging can predict surgical outcomes of patients with cervical compression myelopathy. *Eur Spine J* 2017;26(09):2459–2466
- 25 Karpova A, Arun R, Davis AM, et al. Predictors of surgical outcome in cervical spondylotic myelopathy. *Spine* 2013;38(05):392–400
- 26 Dong F, Wu Y, Song P, et al. A preliminary study of 3.0-T magnetic resonance diffusion tensor imaging in cervical spondylotic myelopathy. *Eur Spine J* 2018;27(08):1839–1845
- 27 Vedantam A, Rao A, Kurpad SN, et al. Diffusion tensor imaging correlates with short-term myelopathy outcome in patients with cervical spondylotic myelopathy. *World Neurosurg* 2017;97:489–494