Article published online: 2021-11-24



# Rathke's Cleft Cyst Abscess—An Unusual Guest in The Sella

Piyush Lodha[1] Srinivas Rao P[1] Vijay Sheker Reddy Danda[1] Gollapudi Prakash Rao[2]

[1]Department of Endocrinology, Gandhi Medical College/Gandhi Hospital, Musheerabad, Secunderabad, Hyderabad, India
[2]Department of Neurosurgery, Gandhi Medical College/Gandhi Hospital, Musheerabad, Secunderabad, Hyderabad, India

**Address for correspondence** Vijay Sheker R. Danda, DM, Gandhi Medical College/Gandhi Hospital, Musheerabad, Secunderabad, Hyderabad 500003, India (e-mail: drdvsreddyendo@yahoo.com).

Indian J Neurosurg 2022;11:73–75

## Abstract

Abscess formation within a Rathke's cleft cyst (RCC) is extremely rare, particularly at a young age. We report the case of a young girl with abscess formation in RCC. A 21-year-old female presented with headache, vomiting, visual deterioration and features suggestive of hypopituitarism. She had bitemporal hemianopia with impairment of visual acuity. MRI revealed a cystic lesion in the sella with suprasellar extension and peripheral rim enhancement. On the basis of history and imaging, this was indistinguishable from more commonly encountered pituitary pathology. She underwent transsphenoidal decompression, which revealed yellowish purulent material that when cultured grew Staphylococcus epidermidis. Histological examination revealed numerous neutrophils and cyst wall lining with features characteristic of RCC. Postoperatively, she received antibiotics and replacement therapy for hypopituitarism. Three months later, she experienced deterioration in visual fields. Considering persistent disease, she underwent redo surgery which revealed similar findings. Postsurgery, pituitary MRI revealed an empty sella syndrome. Thereafter, follow-up for 1 year was stable with permanent diabetes insipidus and multiple pituitary hormone deficiency on supplementation. Although uncommon, we recommend considering RCC abscess as a differential diagnosis of a pituitary mass lesion, as predicting its presence can be difficult preoperatively. Persistent or recurrent disease is common in these cases, so timely diagnosis and adequate surgical drainage leads to lower morbidity and mortality.

**Keywords**
- Rathke's cleft cyst abscess
- pituitary mass lesion
- endoscopic transsphenoidal resection

Rathke's cleft cysts (RCCs) are benign cystic lesions that form between the anterior and posterior lobes of the pituitary gland from the remnants of the embryonic Rathke's pouch. Abscess formation in pituitary gland is rare, accounting for < 1% of all pituitary disease.[1] The pituitary abscesses can occur either as primary abscess, that is, in a previously healthy gland or secondary abscess, arising within existing lesions such as pituitary adenomas and craniopharyngiomas, or RCCs.[2] Abscess formation within a RCC is extremely rare, particularly at a young age. Around five cases have been reported in India. We report a case of abscess formation in RCC, presenting with local compressive symptoms and features of hypogonadism in an immunocompetent female.

A 21-year-old female presented with headache, vomiting, and visual deterioration of 4 weeks duration. She did not have fever, mental status changes and features of underlying immunocompromised condition, sinusitis, or previous pituitary pathology. She had history of amenorrhea for 2 months with regular cycles prior to it. Physical examination revealed features of hypogonadism including diminished axillary and pubic hair, with evidence of expressive galactorrhea. On neurologic examination, she had bilateral papilledema and

published online
November 24, 2021

**DOI** https://doi.org/10.1055/s-0041-1726600
**ISSN** 2277-954X


Thieme Medical and Scientific Publishers Pvt. Ltd. A-12, 2nd Floor, Sector 2, Noida-201301 UP, India

bitemporal hemianopia. Endocrine workup revealed hypopituitarism. The serum free thyroxine (FT4) concentration was 0.3 ng/dL (0.7–1.8ng/dL), thyroid-stimulating hormone (TSH) 0.94 µIU/mL (0.34–4.80 µIU/mL), cortisol 1.9 µg/dL (5–20µg/dL),andestradiol5pg/mL(>30pg/mL),withmarginally elevated prolactin levels, 74 ng/mL (3–27 ng/mL). MRI revealed a cystic lesion of 2 × 2 × 1.3 cm in the sella with suprasellar extension compressing the optic chiasma, which was isointense on T1 and T2, and peripheral rim enhancement on contrast administration (►**Fig. 1**). CT scan demonstrated a hypodense cystic lesion within the sella, without calcification, and with normal paranasal sinuses. The patient underwent transsphenoidal decompression, which revealed yellowish purulent material. The lesion was drained and the atypical appearance of the purulent material led to microbiological sampling that cultured Staphylococcus epidermidis. Histological examination of the lesion revealed numerous neutrophils, debris, and a cyst wall lined by ciliated pseudostratified columnar epithelium with goblet cells characteristic of RCC (►**Fig. 2**). Postoperatively, the patient was treated with intravenous (IV) antibiotics and supportive care. She developed diabetes insipidus (DI) and was started on oral desmopressin along with cortisol and thyroxine supplements. Three months later, she presented with further deterioration in visual fields. Considering the clinical and imaging findings, persistent disease was considered, and the patient underwent redo surgery, which revealed similar findings on histological examination. Thereafter, visual field improved and follow-up for 1 year was stable with permanent DI and multiple pituitary hormone deficiency.

Pituitary abscess is a rare but potentially life-threatening condition, and it accounts for less than 1% of all pituitary diseases.[1] Although the diagnosis of RCCs has become more common, abscess formation within RCC still remains rare and difficult to identify preoperatively. Although RCC abscess may occur spontaneously, predisposing factors include immunocompromised state, pituitary irradiation, surgery, or infarction. A primary abscess can spread via hematogenous route or by direct extension from abutting infections like meningitis, cavernous sinus thrombophlebitis, sphenoid sinusitis, or osteomyelitis.[1,3] This patient typically had no evidence of any predisposing factors. The clinical manifestations of pituitary abscesses are nonspecific, with most patients having features of raised intracranial tension and hypopituitarism. Systemic features such as fever, leukocytosis, and raised erythrocyte sedimentation rate (ESR) are seen in only one-third of patients, making the diagnosis difficult preoperatively.[4,5] Hyperprolactinemia and growth hormone (GH) deficiency are commonly associated with RCCs. In one series, it was observed that infected RCCs are larger in size and have more frequent pituitary dysfunction.[6]

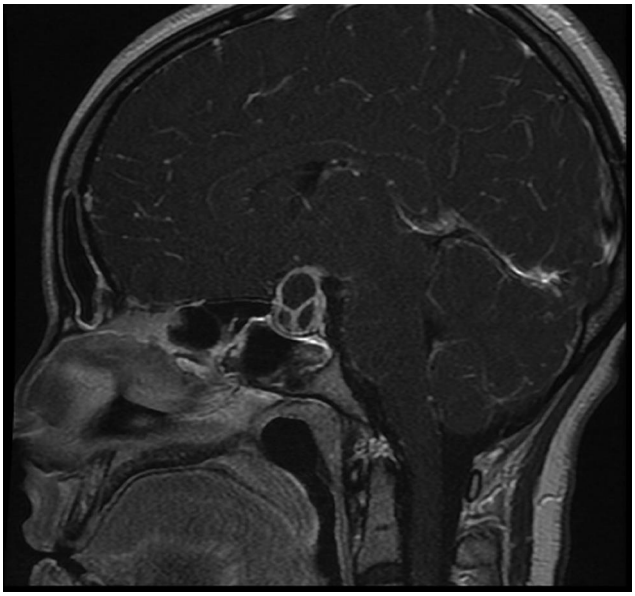

**Fig. 1** T1-weighted MRI image after contrast administration showing rim enhancement of the sellar cystic lesion.

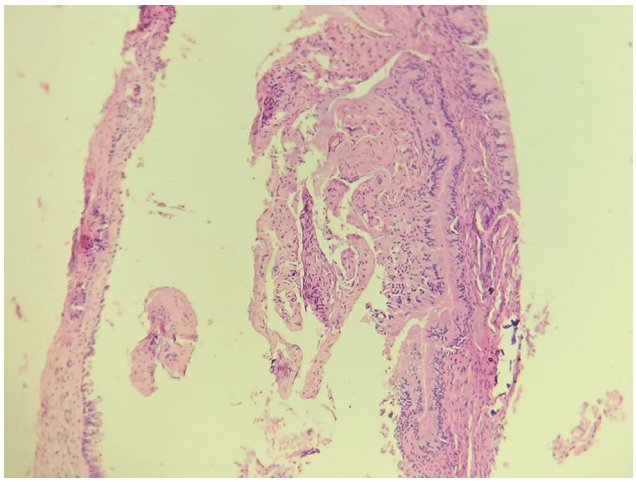

**Fig. 2** Histopathological examination of the lesion showing cyst wall, lined by ciliated pseudostratified columnar epithelium with goblet cells and neutrophils.

MRI remains the preferred modality for preoperative assessment of RCCs. The signal intensity of cyst contents demonstrates high variability on T1 and T2 sequences. Cyst contents can be clear in 35% of cysts so dark on T1 images, or proteinaceous and thicker in the 65% of cysts, appearing bright on T1 images.[6] In majority of cases, contrast administration demonstrates little or no enhancement of cyst wall or its contents, although a thin enhancing rim is seen in inflammatory lesions. However, these findings are not specific for RCC abscess. It is difficult to distinguish infected RCC from cystic pituitary adenomas or craniopharyngiomas solely by MRI.[6,7] As with most pituitary abscess, culture from RCC abscess is typically sterile, although organisms were grown in few cases reported earlier. The most common offending microbes are Staphylococcus, Streptococcus, and Acinetobacter.[8] The cyst wall in RCC contains columnar or cuboidal epithelium, often with ciliated or mucinous goblet cells, but reactive squamous metaplasia can occur and increases the risk of recurrence by four-fold.[6,8]

Surgical drainage by transsphenoidal approach, followed by microbiology guided antibiotic therapy, should be the standard treatment. Transsphenoidal surgery is preferred

over craniotomy, as it has the advantages of efficacy, safety, and minimal invasiveness. Although craniotomy can cause infectious substances to spill into cerebrospinal fluid (CSF), it can be considered, if the abscess is suprasellar or significant evacuation is considered difficult. RCC abscess is known to recur in 15 to 20%, usually several months or even years later. A close follow-up is advised along with a prolonged course of antibiotics to treat any residual infection and prevent the recurrence. The risk of recurrence is likely to decrease with time.[9]

Diagnostic difficulties in RCC abscess arise from absence of specific clinical features and no distinguishing radiological characteristics. It should be considered as one of the differential diagnosis in patients presenting with DI, hypopituitarism, and sellar cystic lesion with rim enhancement on MRI. Residual or recurrent disease is common in these cases, so timely diagnosis and adequate surgical drainage leads to lower morbidity and mortality.

**Conflict of Interest**

None declared.

## References


1 Vates GE, Berger MS, Wilson CB. Diagnosis and management of pituitary abscess: a review of twenty-four cases. J Neurosurg 2001;95(2):233–241

2 Dalan R, Leow MK. Pituitary abscess: our experience with a case and a review of the literature. Pituitary 2008;11(3):299–306

3 Su YH, Chen Y, Tseng SH. Pituitary abscess. J Clin Neurosci 2006;13(10):1038–1041

4 Komatsu F, Tsugu H, Komatsu M, et al. Clinicopathological characteristics in patients presenting with acute onset of symptoms caused by Rathke's cleft cysts. Acta Neurochir (Wien) 2010;152(10):1673–1678

5 Uchiyama T, Sakai K, Asanuma M, Aoyama T, Hongo K. Pituitary abscess manifesting as meningitis and photophobia associated with Rathke's cleft cyst in a child. Case report. Neurol Med Chir (Tokyo) 2011;51(6):455–459

6 Tate MC, Jahangiri A, Blevins L, Kunwar S, Aghi MK. Infected Rathke cleft cysts: distinguishing factors and factors predicting recurrence. Neurosurgery 2010;67(3):762–769

7 Wolansky LJ, Gallagher JD, Heary RF, et al. MRI of pituitary abscess: two cases and review of the literature. Neuroradiology 1997;39(7):499–503

8 Celikoglu E, Boran BO, Bozbuga M. Abscess formation in Rathke's cleft cyst. Neurol India 2006;54(2):213–214

9 Kim JE, Kim JH, Kim OL, et al. Surgical treatment of symptomatic Rathke cleft cysts: clinical features and results with special attention to recurrence. J Neurosurg 2004;100(1):33–40


 