









Determining the Borderline Anatomical Parameters for Better Functional Outcome of Colles Fracture: A Prospective Study*

Determinação dos parâmetros anatômicos limítrofes para melhor desfecho funcional da fratura de Colles: Um estudo prospectivo

Tapasa Kumar Panigrahi¹  Satyajee Ray¹  Manoranjan Mallik¹  Ramesh Chandra Maharaj¹ 
Jugaratna Khatua¹  Debi Prasad Nanda¹ 

¹ Department of Orthopedics, S. C. B. Medical College and Hospital, Cutack, Odisha, India

Address for correspondence Ramesh Chandra Maharaj, MBBS, M.S., Room no-13, SR Hostel, S. C. B. Medical College and Hospital, Cuttack, Odisha, India (e-mail: rameshchandramaharaj@gmail.com).

Rev Bras Ortop 2022;57(4):619–628.

Abstract

Objective The treatment of Colles fracture can deform the wrist. Some studies claim the resulting deformity rarely hinders daily activities, whereas others report the opposite; thus, anatomical reduction is desirable. Our objective was to analyze the anatomical and functional results of Colles fracture to find out the values of individual parameters corresponding to the best functional outcome.

Methods The present prospective study included 70 elderly patients with Colles fracture. All patients were managed conservatively. The anatomical parameters were evaluated by measuring dorsal angulation, radial inclination, and radial height, and they were assessed as per Stewart et al. The functional result was assessed by the Mayo wrist score. The results were analyzed using the chi-squared test of association, and a p -value < 0.001 was considered statistically significant and to examine strengths of associations; we computed odds ratios (ORs) with 95% confidence intervals (CI).

Results Excellent and good results were obtained in 68.5% of the cases anatomically and 78.5% functionally, which was statistically significant ($p = 0.0009$). Out of the three anatomical parameter dorsal angulation $< 10^\circ$ and loss of radial inclination $< 9^\circ$ showed statistically significant association with functional results ($p = 0.0006$), but loss of radial height < 6 mm did not ($p = 0.0568$), which became significant when loss of radial height was kept < 4 mm ($p = 0.00062$).

Keywords

- ▶ Colle's fracture
- ▶ conservative treatment/methods
- ▶ aged

* Work developed at the Department of Orthopedics, S.C.B. Medical College and Hospital, Cutack, Odisha, India.

received
July 29, 2020
accepted
October 28, 2020
published online
May 5, 2021

DOI <https://doi.org/10.1055/s-0041-1726062>.
ISSN 0102-3616.

© 2021. Sociedade Brasileira de Ortopedia e Traumatologia. All rights reserved.
This is an open access article published by Thieme under the terms of the Creative Commons Attribution-NonDerivative-NonCommercial-License, permitting copying and reproduction so long as the original work is given appropriate credit. Contents may not be used for commercial purposes, or adapted, remixed, transformed or built upon. (<https://creativecommons.org/licenses/by-nc-nd/4.0/>)
Thieme Revinter Publicações Ltda., Rua do Matoso 170, Rio de Janeiro, RJ, CEP 20270-135, Brazil

Resumo

Palavras-chave

- ▶ fratura de Colles
- ▶ tratamento conservador/métodos
- ▶ idoso

Conclusion Fractures with anatomical reduction have better functional results. The acceptable borderline anatomical parameters for obtaining excellent or good functional results are dorsal angulation $< 10^\circ$, loss of radial inclination $< 9^\circ$, and loss of radial height < 4 mm

Objetivo O tratamento da fratura de Colles pode deformar o pulso. Alguns estudos afirmam que essa deformidade raramente dificulta as atividades diárias, enquanto outros relatam o contrário; assim, a redução anatômica é desejável. Nosso objetivo foi analisar os resultados anatômicos e funcionais da fratura de Colles para descobrir os valores de parâmetros individuais correspondentes ao melhor desfecho funcional.

Métodos Este estudo prospectivo incluiu 70 pacientes idosos com fratura de Colles. Todos os pacientes foram tratados de forma conservativa. Os parâmetros anatômicos foram a angulação dorsal, a inclinação radial e a altura radial, avaliados de acordo com Stewart et al. O resultado funcional foi avaliado segundo a tabela de pontuação de pulso Mayo. Os resultados foram analisados por meio do teste de associação do qui-quadrado, considerando o valor de $p < 0,001$ estatisticamente significativo. A força das associações foi analisada por razões de possibilidades com intervalos de confiança de 95%.

Resultados Excelentes e bons resultados anatômicos e funcionais foram obtidos em 68,5% e 78,5% dos casos, respectivamente, com diferença estatística significativa ($p = 0,0009$). Dos três parâmetros anatômicos, a angulação dorsal inferior a 10° e a perda da inclinação radial inferior a 9° apresentaram associação estatisticamente significativa com os resultados funcionais ($p = 0,0006$), mas não a perda de altura radial inferior a 6 mm ($p = 0,0568$); no entanto, a perda da altura radial inferior a 4 mm foi associada de forma significativa aos desfechos funcionais ($p = 0,00062$).

Conclusão As fraturas com redução anatômica apresentam melhores desfechos funcionais. Os parâmetros anatômicos limítrofes aceitáveis para a obtenção de resultados funcionais excelentes ou bons são angulação dorsal inferior a 10° , perda da inclinação radial inferior a 9° e perda da altura radial inferior a 4 mm.

Introduction

Anatomically upper limb and that to hand and wrist is meant for precision. The singular anatomy of volar tilt, radial inclination, and radial height of the distal end of the radius gives the wrist the amazing freedom of movement necessary for precision work that sets the humans apart from the rest of the world. The disadvantage of the upright posture and of the high degree of movements is that the upper extremity is more prone to injury than the lower limbs.¹ Fractures involving the distal end of the radius are the most common and account for $\sim 17.5\%$ of all fractures.^{1,2} It has bimodal age distribution with one peak at 6 to 10 years and another peak at 60 to 70 years.² Elderly women are seven times more prone to this type of injury, which may be due to postmenopausal osteoporosis.³ The mode of injury is mostly due to simple fall with outstretched hands.⁴ The fracture pattern is typically distal metaphyseal, involving one inch from the distal end of radius with its classical dorsal comminution, dorsal angulation, dorsal displacement, radial displacement; this type of lesion is named Colles fracture, after Sir Abraham Colles, who first described it in 1814.⁴ Until today, conservative management with a cast below the elbow with wrist in a neutral to mild flexion position and ulnar deviation is accepted as standard treatment for elderly patients with low physical demands.⁵ The

healing process is usually accompanied by deformity, which may be skillfully treated in up to 60% of cases.^{6,7}

There is a discussion of whether this deformity impairs the functional outcome in aged patients or not. There are numerous publications regarding this but giving confusing messages. Most of them state Colles fracture does require special attention as the resulting deformity rarely damages the wrist function.^{5,8} Some say even small changes in the anatomical parameters of the distal end of the radius can lead to poor functional outcome in up to 17% of cases.⁹ Others say the functional outcome following Colles fracture is multifactorial and not necessarily anatomical reductions as deciding entity.¹⁰

Hence, this study was conducted to assess the anatomical and functional results of Colles fracture treated conservatively in elderly people and to evaluate the correlation between individual anatomical parameters and functional results to determine borderline values of each of them corresponding with a better functional outcome.

Material and Methods

After obtaining ethical committee approval and patients consent, the data were collected and analyzed prospectively

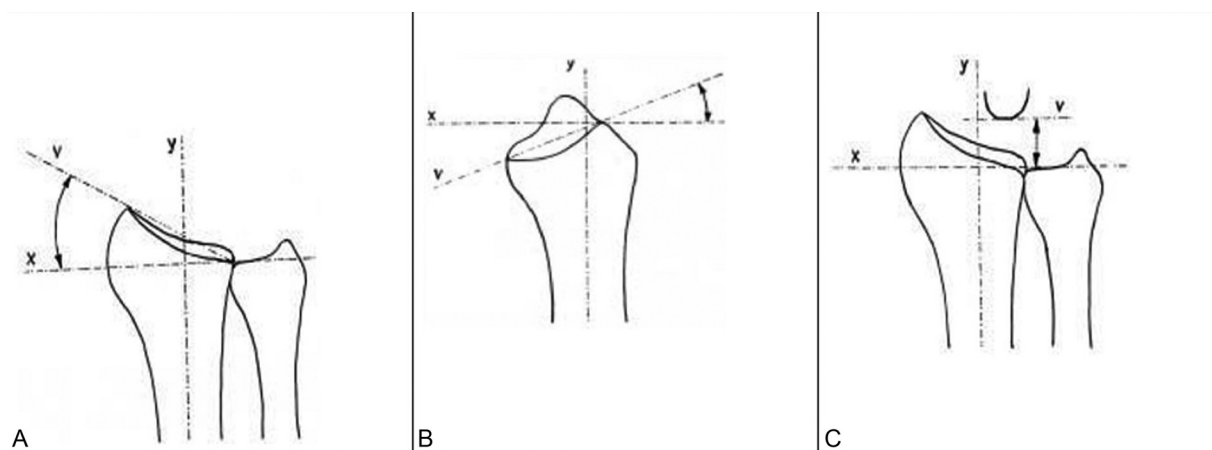


Fig. 1 Diagrammatic way of measurement of different anatomical parameters (A) Radial inclination measurement; (B) Palmar tilt measurement; (C) Radial length measurement.

for 70 patients with Colles fractures, who attended the Out Patient Department (OPD) and emergency care unit between May 2016 and May 2020. Patients between 60 and 80 years of age, with unilateral, extraarticular distal radius closed fractures were included in the present study; individuals with bilateral distal radius fracture, intraarticular fracture, and open fracture were excluded.

Posteroanterior (PA) and lateral views X-rays of both wrist (as case and control) were taken. The fractures were classified according to the *Arbeitsgemeinschaft für Osteosynthesefragen/Orthopedic Trauma Association (AOOTA)* classification (AO/OTA-2R3A2.2). A hematoma block (with 1 ml of 2% lignocaine) was given, followed by close manipulation, and cast under image intensifier.¹¹ After achieving acceptable anatomical reduction, the forearm was immobilized with a below-the-elbow cast for 4 weeks. Following cast removal, the patient underwent supervised physiotherapy to prevent stiffness and was then followed-up at 3 and 6 months and yearly for anatomical and functional evaluation. The anatomical parameters were measured radiologically by determining the radial inclination, dorsal angulation or palmar tilt and radial bone length.¹² (►Fig. 1) The MicroDicom software was used to calculate angles and lengths from the X-rays (►Fig. 2).

The anatomical results were assessed as per criteria established by Stewart et al.¹³ According to Stewart et al.,¹³ acceptable dorsal angulation was 10 degrees, acceptable loss of radial inclination was 9 degrees, and acceptable loss of radial bone length was 6 mm (►Table 1). The functional outcome was assessed with the Mayo wrist score measured at 6 months at the latest follow-up¹⁴ (►Table 1). A goniometer was used to measure the flexibility of the wrist joint of the healthy and the injured hand. A dynamometer was used to measure the grip strength.

The demographic data were measured with mean, range, and proportions. For comparing anatomical and functional outcomes, we used the chi-squared test of association using 2×2 tables in which the fields with excellent and good results and the fields with fair and poor results were combined. A p -value < 0.001 was considered statistically significant. To examine strengths of associations, we computed

odds ratios (ORs) with 95% confidence intervals (CIs) for the functional result in relation to the anatomic result.

Results

Of the 70 patients, 42 were female and 28 were male. The mean age was 66.3 ± 3.2 years (range, 60–80 years). In 42 patients, the fracture occurred in the dominant hand, and in 28 patients in the non-dominant hand. The anatomical parameters of the normal (control) hand are mentioned below (►Table 2).

The functional result was excellent in 43, good in 12, fair in 8, and poor in 7 patients. The anatomical result was excellent in 41, good in 7, fair in 10, and poor in 12 patients at 6 months, which was depicted in a 2×2 table that showed a statistically significant association ($p < 0.001$ [0.0009]) between the anatomical and functional results. (►Table 3 and ►Figure 3)

Comparing the individual anatomical parameters with functional results, there was a statistically significant association ($p < 0.001$) between the dorsal angulation and the functional results (chi-squared = 11.75, degree of freedom [DF] = 1, $p = 0.0006$, odds ratio [OR] = 7.67, 95% CI, 2.18–26.92) with 10° or less of dorsal angulation as a borderline value (►Table 3).

A statistically significant association ($p < 0.001$) was found between the loss of radial inclination and functional results (chi-squared = 11.77, DF = 1, $p = 0.0006$, OR = 7.67, 95% CI, 2.18–26.92), with 9° or less of loss of radial inclination as a borderline value (►Table 3).

A non-statistically significant association ($p > 0.001$ [0.01]) was found between the loss of radial height and functional results (chi-squared = 6.62, DF = 1, $p = 0.01$, OR = 4.57, 95% CI, 1.33–15.33), with 6 mm or less loss of radial height as a borderline value (►Table 3).

For estimating the borderline value for loss of radial height, a statistically significant association was found with the functional result (chi squared = 11.70, DF = 1, $p = 0.00062$, OR = 8.94, 95% CI, 2.23–35.84), with 4 mm or less of loss of radial height from the mean as a borderline value (►Table 3).

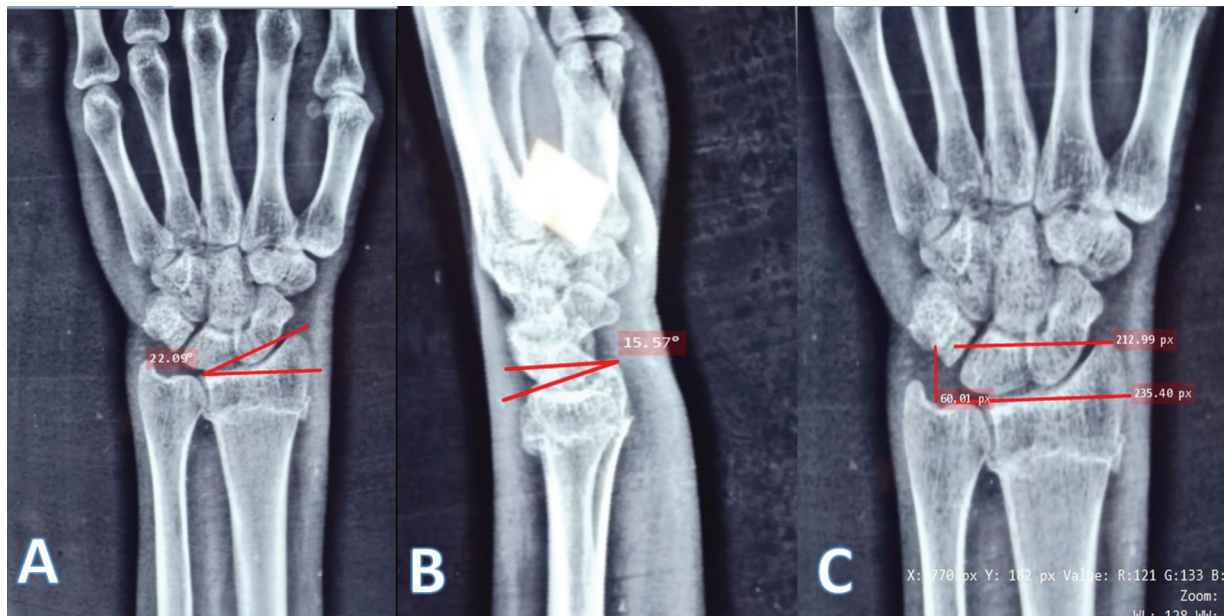


Fig. 2 Measurements taken using the MicroDicom software. (A) Radial inclination; (B) Dorsal angulation; (C) Radial height.

Table 1 Anatomical and functional scoring systems

Scoring system	Dorsal angle (degree)	Loss of radial length (mm)	Loss of radial angle (degree)	Score	Rating
1.1 Anatomical assessment of treatment results of radial bone fracture in a typical zone (Stewart et al.)	Neutral	0–3	0–4	0	[Rating: combined score dorsal angle, radial length, and radial angle; Excellent = 0; Good = 1–3; Fair = 4–6; Poor = 7–12]
	1–10	4–6	5–9	1	
	11–14	7–11	10–14	2	
	> 15	> 12	> 15	4	
1.2 Functional score by the Mayo wrist score	Category	Score	Finding		[*Total points 90–100 = Excellent; 80–89 = Good; 65–79 = Fair; < 65 = poor]
	Pain (25 points)	25	No pain		
		20	Mild pain with vigorous activities		
		20	Pain only with weather changes		
		15	Moderate pain with vigorous activity		
10		Mild pain with activities of daily living			
Satisfaction (25 points)	5	Moderate pain with activities of daily living			
	0	Pain at rest			
	25	Very satisfied			
Range of motion (25 points)	20	Moderately satisfied			
	10	Not satisfied, but working			
	5	Not satisfied, unable to work			
	0				
Grip strength (25 points)	25	100% of normal			
	15	75–99% of normal			
	10	50–74% of normal			
	5	25–49% of normal			
	0	0–24% of normal			

Table 2 The demographic profile and anatomical parameters of the normal hand

Patients (n)	70
Mean age (years)	66.3 ± 3.2 (60–80 years.)
Female patients	42 (60%)
Male patients	28 (40%)
Female: Male	3:2
Affected side: • Unilateral, dominant hand • Unilateral, non-dominant hand	42 28
Radiological parameter of control hand: • Radial inclination • Palmar angulation • Radial length	20–30° (25.6 ± 2.8 degree) 0–15° (7.9 ± 4.2 degree) 8–18 mm (13.4 ± 1.7 mm)

Discussion

The incidence of the Colles fracture was highest among the elderly in the 60 to 69 years age group (range 60–80). It was 3 times more common in women (42 [60%]) than men (28 [40%]). These findings were similar to those of Chung et al.,¹⁵

in which 86.7% were women with a mean age of 70.9 ± 8.9 years.

The normal morphometry of the distal radius measured from the normal wrist were: radial inclination mean of 25.6 ± 2.8° (20–30°), palmar tilt of 7.9 ± 4.2° (0–15°), and radial bone length of 13.4 ± 1.7 mm (8–18 mm). The morphometric data may vary as per geographical locations and races (► **Table 4**).^{11,16–18}

Comparing functional and anatomical results, the functional result was excellent or good in 55 (78.5%) and satisfactory or poor in 15 (21.5%) cases, whereas the anatomical results were excellent or good in 48 (68.5%) and satisfactory or poor in 22 (31.5%) elderly patients with Colles fracture treated non-operatively (► **Table 5**). The statistical analysis showed a significant correlation between them, with $p = 0.0009$, chi-squared = 10.99, OR = 7.17. This differs from the results obtained by Gartland and Werley, who obtained surprisingly good functional results despite poor repositioning and inadequate immobilization.⁶ Our results also differ from those reported by Finsen et al.¹⁰ and Chung et al.,¹⁵ who reported that precise restoration of the wrist anatomy is not associated with better functional outcome.^{10,15} Arrora et al.¹⁹ found that anatomic reconstruction did not convey any improvement in the range of motion or

Table 3 Statistical analysis of results with 2 × 2 tables

Sl.no	Parameters for comparison	2 × 2 tables		Results	Statistical significance	
3.1	Anatomical outcome with functional outcome	Anatomical result	Functional result (no. of patients)		Chi-square = 10.99, DF = 1, $p < 0.001$ (0.0009). Odds ratio = 7.17(95% CI 2.01–25.01)	Significant
			Excellent/Good	Fair/Poor		
		Excellent/Good	43	5		
	Fair/Poor	12	10			
3.2	(< 10°) loss of dorsal angulation with functional outcome	Dorsal angulation	Functional result (no. of patients)		Chi-squared = 11.75, DF = 1, $p < 0.001$ (0.0006) Odds ratio = 7.67(95% CI: 2.18–26.92)	Significant
			Excellent/Good	Fair/Poor		
		< 10°	46	6		
	> 10°	9	9			
3.3	(< 9°) loss of radial inclination with functional outcome	Loss of radial angle	Functional results (nr. of patients)		Chi-squared = 11.77, DF = 1, $p < 0.001$ (0.0006). Odds ratio = 7.67 (95% CI, 2.18–26.92)	Significant
			Excellent/Good	Fair/Poor		
		< 9°	41	4		
	> 9°	14	11			
3.4	(< 6 mm.) loss of radial height with functional outcome	Loss of radial height	Functional result (nr. of patients)		Chi-squared = 6.62, DF = 1, $P > 0.001$ (0.01). Odds ratio = 4.57 (95% CI, 1.33–15.33)	Not significant
			Excellent/Good	Fair/Poor		
		< 6 mm	44	7		
	> 6 mm	11	8			
3.5	(< 4 mm.) loss of radial height with functional outcome	Loss of radial height	Functional result(no of patients)		Chi-squared = 11.70, DF = 1, $p < 0.001$ (0.00062) odds ratio = 8.94 (95%CI: 2.23–35.84)	Significant
			Excellent/Good	Fair/Poor		
		< 4mm	38	3		
	> 4mm	17	12			

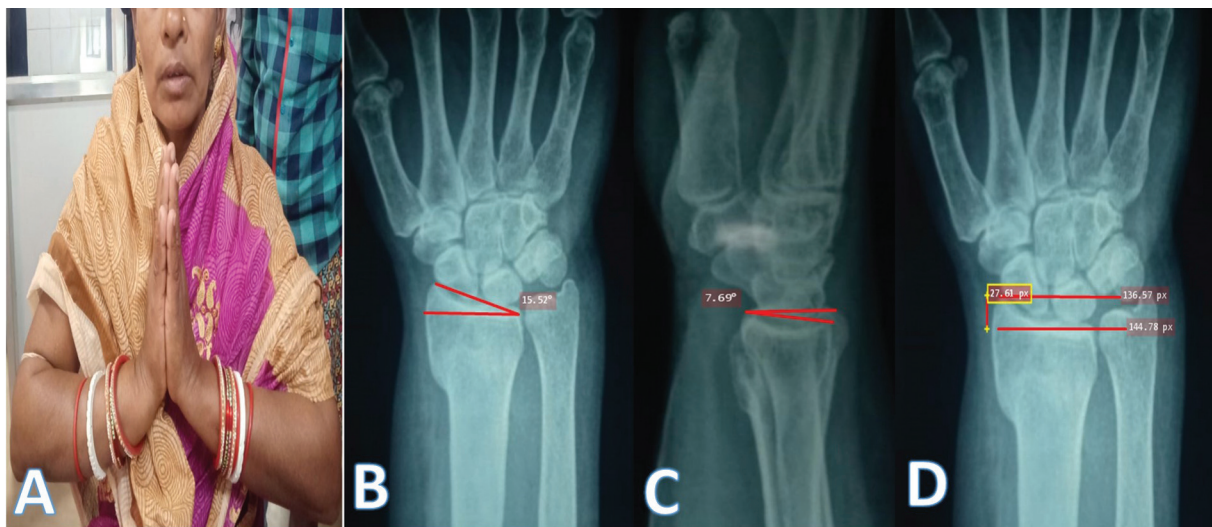

Fig. 3 Follow-up of Colles fracture of right wrist. (A) Clinical picture; (B) Radial inclination; (C) Dorsal tilt; (D) Radial height.

Table 4 Studies measuring morphometry of distal end radius

Source	Radial inclination	Palmar inclination	Radial bone length	Ulnar variance
Campbell 13 th ed. 2017 (p.2993) ¹⁶	20°	11°	12 mm	± 2 mm
Green operative hand surgery 7 th ed. (2017) ¹¹	23°	11°		-1 mm
Mishra et al. (2016) ¹⁷	23.27 ± 7.42° (11.3–42.1°)	10.7 ± 5.28° (1–16.9°)	11.31 ± 4.9 mm (7.1–30.4 mm)	0.66 ± 2.46 mm (-2.4 + 4.1 mm)
Dario et al. (2014) ¹⁸	21–25°	7–15°	10–13 mm	0.7– 4.1 mm
Present study	25.6 ± 2.8°(20–30°)	7.9 ± 4.2°(0–15°)	13.4 ± 1.7 mm (8–18 mm)	

better ability in the daily activities of the elderly. Anzarut et al.²⁰ and Young & Rayan²¹ also agreed that radiographic reduction was not associated with better functional outcome and obtained good function in cases in which the anatomical results were poor. However, few other authors reported a significant correlation between the anatomical and functional results, which agrees with this study, such as Kong et al.,²² who determined that satisfactory reduction is the first choice, as malalignment leads to decreased grip strengths, unsatisfactory appearance, and certain limitation of wrist movements. Slogaard et al.²³ found that the function was influenced by radiographic results; thus, it would make sense to improve the function by better reduction technique of the fracture and prevention of secondary displacements. Jenkins et al.²⁴ found that final recovery of the grip strength was related to the inclination of the articulate surface of the healed radius both coronal and sagittal planes, and loss of radial length appears to become an important determinant of long-term pain.

By studying the association of individual anatomical parameters with the functional results, the present study showed a significant association of dorsal angulation < 10° and loss of radial inclination of < 9° with functional results, ($p = 0.0006$, chi-squared = 11.75, OR = 7.67) but not with loss

of radial height < 6 mm, ($p = 0.01$). Instead, when loss of radial length was kept to < 4 mm, statistical significance was achieved ($p = 0.00062$, chi-squared = 11.70, OR = 8.94). (► **Table 6**) Stewart et al.,¹³ in his work on functional cast bracing for Colles fracture, found that fractures with dorsal angulation < 10 degrees, loss of radial inclination of < 9 degrees and loss of radial height < 6 mm had better functional outcome, irrespective of the methods of immobilization of casting or bracing. Altimissi et al.²⁵ reported unsatisfactory results with dorsal angulation > 15 degrees, loss of radial inclination of < 5 degrees and ulnar variance > 5 mm. Slogaard et al.²³ found that functional results were excellent or good with dorsal angulation < 10° and loss of radial height < 7 mm. Salmon and Patrick et al.²⁶ defined malunion in distal radius fracture with dorsal angulation > 10 degrees, loss of radial inclination of < 17 degrees and loss of radial height > 3 mm and ulnar variance > 1 mm. Fuji et al.²⁷ reported radial shortening of more than 6 mm may result in poor functional outcome. Smilovic et al.²⁸ defined borderline values as dorsal angulation ≤ 9 degrees, loss of radial inclination of ≤ 3 degrees, and loss of radial height ≤ 2 mm for achieving good function.

The limitation of this study is its small sample size ($n = 70$). It followed a bivariate analysis using the chi-Square

Table 5 Studies comparing anatomical and functional outcome of distal radius fractures

Author	Study	Results	Conclusion
Chung et al. (2020) ¹⁵	Assessment of Anatomic Restoration of Distal Radius Fractures Among Older Adults: A Secondary Analysis of a Randomized Clinical Trial	Data of 166 patients analyzed with 2-phase multivariable regression models only 2 of the 84 correlation coefficients calculated were statistically significant; grip strength with radial inclination and MHQ ADL score with ulnar variance.	They conclude that precise restoration of the wrist anatomy is not associated with better functional outcome.
Kong et al. (2019) ²²	The Necessity of Restoration of Radiologic Parameters by Closed Reduction in Elderly Patients with Distal Radius Fractures	Out of 96 patients 75 (78.1%) got acceptable reduction and 21 (21.9%) got poor reduction. A significant correlation was found between ulnar positive variance with grip strength ($r = 0.35$, $p = 0.03$) and dorsal angulation with wrist flexion ($r = 0.31$, $p = 0.02$)	They concluded that satisfactory reduction is the first choice as malalignment leads to decreased grip strengths, unsatisfactory appearance and certain limitation of wrist movements.
Finsen et al. (2013) ¹⁰	The relationship between displacement and clinical outcome after distal radius (Colles) fracture	Reviewed 260 patients. Though there exist a statistically significant association between functional and anatomical results by Bivariate analysis however multiple regression showed dorsal angulation, ulnar variance and radial inclination accounts only 11% of variability.	They concluded that final radiological alignment of distal radius fracture has minor influence on clinical outcome of Colles fracture.
Arrora et al. (2011) ¹⁹	A prospective randomized trial comparing nonoperative treatment with volar locking plate fixation for displaced and unstable distal radial fractures in patients sixty-five years of age and older	Prospectively analyzed 73 patients the range of motion, the level of pain, and the Patient-Rated Wrist Evaluation (PRWE) and Disabilities of the Arm, Shoulder and Hand (DASH) scores were not different between the operative and nonoperative treatment groups	Thus achieving anatomic reconstruction did not convey any improvement in range of motion or better ability of daily leaving activities in elderly.
Anzarut et al. (2004) ²⁰	Radiologic and patient-reported functional outcomes in an elderly cohort with conservatively treated distal radius fractures	Out of 74 patients 47 (69%) had acceptable radiographic outcome and 44 (59%) had satisfied functional result at 6 months.	Concluded that acceptable radiographic reduction was not associated with better functional outcome.
Young and Rayan et al. (2000) ²¹	Outcome following nonoperative treatment of displaced distal radius fractures in low-demand patients older than 60 years	Got 88% excellent or good functional results and 68% excellent or good anatomical results	Radiographic outcome did not correlate with the functional outcome.
Slogaard et al. (1988) ²³	Function after distal radius fracture	Functional results were excellent or good with dorsal angulation below 10° and loss of radial height < 7 mm.	Function was influenced by radiographic results. It is rational to improve the function results by better reduction technique of the fracture and prevention of secondary displacements.
Jenkins et al. (1988) ²⁴	Mal-union and dysfunction-in Colles fracture	Results of 61 patients. The anatomical parameters at union were: mean dorsal angulation of 9° (SD 12.1), mean loss of radial inclination 7.8° (SD 7.2°) and mean radial shortening of 4 mm (SD 3.9 mm). Loss of grip strength and loss of flexion were taken as the functional parameter. A multilinear regression analysis showed statistically significant correlation between grip strength and loss of radial inclination and dorsal angulation and same with loss of flexion but did not reach level of significance.	Final recovery of the grip strength was related to the inclination of the articulate surface of healed radius both coronal and sagittal plane. Loss of radial length appears to become important determinant of long-term pain.
Garland and Werely (1951) ⁶	Evaluation of healed Colles fractures	Good functional results (68.3%) achieved despite of poor radiological appearances.	The residual dorsal tilt more strongly associated with poor outcome than the loss of radial inclination or radial height or ulnar variance. However Cases showing more accurate reduction have best outcome.
Present study	Determining the borderline values of anatomical parameters for better functional outcome of Colles fracture. A prospective study	Of 70 patients excellent to good functional results was seen in 55 (78.55) and anatomically in 48 (68.5%) with a statistically significant correlation between them $p < 0.001(0.0009)$	Concludes anatomical reduction and maintaining the reduction is priority for better functional outcome.

Table 6 Studies estimating the values of individual anatomical parameters correlated to excellent or good functions results of distal radius fractures

Author	Study	Dorsal angulation	Loss of radial inclination	Loss of radial height	Ulnar variance	Remarks
Stewart et al. (1984) ¹³	Functional cast-bracing for Colles fractures: a comparison between cast-bracing and conventional plaster casts	< 10°	< 9°	< 6 mm		The anatomic results were not influenced by methods of immobilization but was related to efficacy of reduction.
Altimisji et al. (1986) ²⁵	Long term results of conservative treatment of fractures of the distal radius	> 15°	< 5°		> 5 mm (radio ulnar index)	No statistically significant relation between the final results and type of fracture. However unsatisfactory results reported with extreme values three radiographic parameters as mentioned.
Slogaraad et al. (1988) ²³	Function after distal radius fracture	< 10°		< 7 mm		Functional results were excellent or good with dorsal angulation below 10° and loss of radial height < 7 mm.
Salmon & Patrick et al. (1999) ²⁶	Prevention of malunion of distal radius fracture	> 10°	≤ 17°	> 3 mm	> 1 mm	They have taken these radiographic measurements to define malunion in distal radius fracture.
Fujik et al. (2002) ²⁷	Fractures of the distal end of radius in elderly patients: a comparative study of anatomical and functional results	3°		4 mm		Minor deformities as mentioned did not affect functional outcome. However radial shortening of more than 6 mm may result in poor functional outcome.
Smilovic et al. (2003) ²⁸	Conservative treatment of extra-articular Colles type fractures of the distal radius: prospective study	≤ 9°	≤ 3°	≤ 2 mm		There was significant association between anatomical and functional results. And borderline values for better functions were as mentioned.
Campbell 13 th ed. 2017 (p.2993) ¹⁶	Acceptable reduction of distal radius fracture	Neutral (0°)	No less than 10°		No more than 2mm of shortening relative to ulnar head	
Present study	Determining the borderline anatomical parameters for better functional outcome of	< 10°	< 9°	< 4 mm		Recommends anatomic reduction of the fracture with in the borderline limits of the individual

Table 6 (Continued)

Author	Study	Dorsal angulation	Loss of radial inclination	Loss of radial height	Ulnar variance	Remarks
	Colles' fracture. A prospective study					parameters as mentioned for achieving excellent to good functional results.

test and OR for data analysis, as distal radius fracture is influenced by multiple variables apart from fracture reduction, so a multivariable regression model of analysis would have been a better choice for statistical analysis. Anatomic reduction may not always be the only parameter for better function, as indicated by Cooney et al.,²⁹ who pointed out that soft-tissue injury was equally responsible for the resulting stiffness. This was not considered in the present study, which may have been a limitation.

The strength of the present study is that only a few other studies, such as the one by Smilovic et al.,²⁸ have been conducted for measuring the borderline values of anatomical parameters needed for good function. Therefore, we believe that further research with larger sample sizes and higher statistical analytic models would confirm the values found in this study.

Conclusion

Until today, the non-operative management of Colles fracture, especially in elderly patients, has remained as an acceptable modality of treatment; however, good function can be achieved with better anatomical reduction. The present study recommends acceptable borderline values of anatomical parameters as dorsal angulation < 10°, loss of radial inclination < 9°, and loss of radial height < 4 mm to achieve excellent or good functional results.

Financial Support

There was no financial support from public, commercial, or non-profit sources.

Conflict of Interests

The authors have no conflict of interests to declare.

Acknowledgment

I would like to thank all our patients who had participated in the study, I thank sisters, OT staff, data entry operators and colleagues for help and support. I express honor and gratitude for our Professor & Head of Department for his unparalleled support during the study. Lastly, I would like to bow down before the almighty for all the blessings showed up on me.

References

1 Court-Brown CM, Caesar B. Epidemiology of adult fractures: A review. *Injury* 2006;37(08):691–697

2 Brogren E, Petranek M, Atroshi I. Incidence and characteristics of distal radius fractures in a southern Swedish region. *BMC Musculoskelet Disord* 2007;8:48

3 Hesp R, Klenerman L, Page L. Decreased radial bone mass in Colles' fracture. *Acta Orthop Scand* 1984;55(05):573–575

4 Summers K, Fowles SM. Colles' Fracture. [Updated 2020 Jan 18]. In: StatPearls [Internet]. Treasure Island (FL): StatPearls Publishing; 2020 Jan-. Available from: <https://www.ncbi.nlm.nih.gov/books/NBK553071/>

5 Edward A. Perez. Fractures of the shoulder, arm and forearm. In: Frederick M, Azar MD, editors. *Campbell's operative orthopaedics*. 13th ed. Philadelphia: Elsevier; 2017:2994

6 Gartland JJ Jr, Werley CW. Evaluation of healed Colles' fractures. *J Bone Joint Surg Am* 1951;33-A(04):895–907

7 Mackenney PJ, McQueen MM, Elton R. Prediction of instability in distal radial fractures. *J Bone Joint Surg Am* 2006;88(09):1944–1951

8 Cassebaum WH. Colles' fracture; a study of end results. *J Am Med Assoc* 1950;143(11):963–965

9 Golden GN. Treatment and prognosis of Colles' fracture. *Lancet* 1963;1(7280):511–515

10 Finsen V, Rod O, Rød K, Rajabi B, Alm-Paulsen PS, Russwurm H. The relationship between displacement and clinical outcome after distal radius (Colles') fracture. *J Hand Surg Eur Vol* 2013; 38(02):116–126

11 Wolfe SW. Distal Radius Fractures. In: Wolfe SW, Pederson WC, Cohen Mark S, editors. *Green's Operative Hand Surgery*. 7th ed. Philadelphia: Elsevier; 2017:530

12 Bilić R, Ruzić L, Zdravković V, Boljević Z, Kovjanić J. Reliability of different methods of determination of radial shortening. Influence of ulnar and palmar tilt. *J Hand Surg [Br]* 1995;20(01): 97–101

13 Stewart HD, Innes AR, Burke FD. Functional cast-bracing for Colles' fractures. A comparison between cast-bracing and conventional plaster casts. *J Bone Joint Surg Br* 1984;66(05):749–753

14 Cooney WP, Bussey R, Dobyys JH, Linscheid RL. Difficult wrist fractures. Perilunate fracture-dislocations of the wrist. *Clin Orthop Relat Res* 1987;(214):136–147

15 Chung KC, Cho HE, Kim Y, Kim HM, Shauver MJWRIST Group. Assessment of Anatomic Restoration of Distal Radius Fractures Among Older Adults: A Secondary Analysis of a Randomized Clinical Trial. *JAMA Netw Open* 2020;3(01):e1919433

16 Perez EA. Fractures of the shoulder, arm and forearm. In: Azar FM, Canale ST, Beaty JH, editors. *Campbell's operative orthopaedics*. 13th ed. Philadelphia: Elsevier; 2017:2993

17 Mishra PK, Nagar M, Gaur SC, Gupta A. Morphometry of distal end radius in the Indian population: A radiological study. *Indian J Orthop* 2016;50(06):610–615

18 Dario P, Matteo G, Carolina C, et al. Is it really necessary to restore radial anatomic parameters after distal radius fractures? *Injury* 2014;45(Suppl 6):S21–S26

19 Arora R, Lutz M, Deml C, Krappinger D, Haug L, Gabl M. A prospective randomized trial comparing nonoperative treatment with volar locking plate fixation for displaced and unstable distal radial fractures in patients sixty-five years of age and older. *J Bone Joint Surg Am* 2011;93(23):2146–2153

- 20 Anzarut A, Johnson JA, Rowe BH, Lambert RG, Blitz S, Majumdar SR. Radiologic and patient-reported functional outcomes in an elderly cohort with conservatively treated distal radius fractures. *J Hand Surg Am* 2004;29(06):1121–1127
- 21 Young BT, Rayan GM. Outcome following nonoperative treatment of displaced distal radius fractures in low-demand patients older than 60 years. *J Hand Surg Am* 2000;25(01):19–28
- 22 Kong L, Kou N, Wang Y, Lu J, Tian D, Zhang B. The Necessity of Restoration of Radiologic Parameters by Closed Reduction in Elderly Patients with Distal Radius Fractures. *Med Sci Monit* 2019;25:6598–6604
- 23 Solgaard S. Function after distal radius fracture. *Acta Orthop Scand* 1988;59(01):39–42
- 24 Jenkins NH, Mintowt-Czyz WJ. Mal-union and dysfunction in Colles' fracture. *J Hand Surg Br* 1988;13(03):291–293
- 25 Altissimi M, Antenucci R, Fiacca C, Mancini GB. Long-term results of conservative treatment of fractures of the distal radius. *Clin Orthop Relat Res* 1986;(206):202–210
- 26 Salmon JM, Pattern S. Prevention of malunion of distal radius fracture. *J Bone Joint Surg Br* 1999;81(01):5
- 27 Fujii K, Henmi T, Kanematsu Y, Mishiro T, Sakai T, Terai T. Fractures of the distal end of radius in elderly patients: a comparative study of anatomical and functional results. *J Orthop Surg (Hong Kong)* 2002;10(01):9–15
- 28 Smilovic J, Bilic R. Conservative treatment of extra-articular Colles' type fractures of the distal radius: prospective study. *Croat Med J* 2003;44(06):740–745
- 29 Cooney WP III, Dobyns JH, Linscheid RL. Complications of Colles' fractures. *J Bone Joint Surg Am* 1980;62(04):613–619